ORIGINAL ARTICLE

Corpus Callosum Abnormalities in Psychopathic Antisocial Individuals

Adrian Raine, DPhil; Todd Lencz, PhD; Kristen Taylor, PhD; Joseph B. Hellige, PhD; Susan Bihrle, PhD; Lori Lacasse, BSc; Mimi Lee, BSc; Sharon Ishikawa, PhD; Patrick Colletti, MD

Context: Psychopathic antisocial individuals have previously been characterized by abnormal interhemispheric processing and callosal functioning, but there have been no studies on the structural characteristics of the corpus callosum in this group.

Objectives: To assess whether (1) psychopathic individuals with antisocial personality disorder show structural and functional impairments in the corpus callosum, (2) group differences are mirrored by correlations between dimensional measures of callosal structure and psychopathy, (3) callosal abnormalities are associated with affective deficits, and (4) callosal abnormalities are independent of psychosocial deficits.

Design: Case-control study.

Setting: Community sample.

Participants: Fifteen men with antisocial personality disorder and high psychopathy scores and 25 matched controls, all from a larger sample of 83 community volunteers.

Main Outcome Measures: Structural magnetic resonance imaging measures of the corpus callosum (volume estimate of callosal white matter, thickness, length, and genu and splenium area), functional callosal measures (2 divided visual field tasks), electrodermal and cardiovascular activity during a social stressor, personality measures of affective and interpersonal deficits, and verbal and spatial ability.

Results: Psychopathic antisocial individuals compared with controls showed a 22.6% increase in estimated callosal white matter volume ($P<.001$), a 6.9% increase in callosal length ($P=.002$), a 15.3% reduction in callosal thickness ($P=.04$), and increased functional interhemispheric connectivity ($P=.02$). Correlational analyses in the larger unselected sample confirmed the association between antisocial personality and callosal structural abnormalities. Larger callosal volumes were associated with affective and interpersonal deficits, low autonomic stress reactivity, and low spatial ability. Callosal abnormalities were independent of psychosocial deficits.

Conclusions: Corpus callosum abnormalities in psychopathic antisocial individuals may reflect atypical neurodevelopmental processes involving an arrest of early axonal pruning or increased white matter myelination. These findings may help explain affective deficits and previous findings of abnormal interhemispheric transfer in psychopathic individuals.

Arch Gen Psychiatry. 2003;60:1134-1142

From the Department of Psychology, University of Southern California, Los Angeles (Drs Raine, Taylor, Hellige, Bihrle, and Ishikawa and Mss Lacasse and Lee); the Department of Research, Hillside Hospital, Glen Oaks, Calif (North Shore–Long Island Jewish Health System) (Dr Lencz); and the Department of Radiology, University of Southern California School of Medicine (Dr Colletti).

An increasing body of knowledge from brain imaging research is implicating brain abnormalities in the etiology of psychopathic and antisocial behavior, including abnormalities of the prefrontal cortex,[1-3] temporal cortex,[3,4] hippocampus,[5] parahippocampal gyrus,[6] angular gyrus,[7] cingulate,[8] basal ganglia,[9] and amygdala.[6,10] The neurophysiologic basis of antisocial and psychopathic behavior is probably complex, with many interconnected brain structures likely to be involved in the regulation of impulsivity, emotional arousal, affect, and aggressive feelings. Interruption of the normal connectivity of these brain circuits is therefore likely to interfere with the normal brain processing that is critical to the regulation of affect.

Perhaps the single most important brain structure involved in connectivity is the corpus callosum. This structure orchestrates the complex interhemispheric regulation of attention, arousal, and emotion.[11,12] Callosal abnormality could have profound implications not only for cognition, affect, and emotion regulation but also for psychopathologic status. Increased callosal area or thickness has been found in several disorders that are thought to be neurodevelopmental or genetic, in-

©2003 American Medical Association. All rights reserved.
Downloaded From: http://jamanetwork.com/ on 05/24/2013

cluding schizophrenia,[13-16] childhood-onset schizophrenia,[17] schizotypal personality disorder,[18] developmental language disorder,[19] dyslexia,[20] Cohen syndrome,[21] velocardiofacial syndrome,[22] and neurofibromatosis.[23]

To date, to our knowledge, there has been no research on the structural characteristics of the corpus callosum in any antisocial or psychopathic group. However, some studies suggest that antisocial and violent offenders may have functional abnormalities of the corpus callosum and its associated white matter radiations as indicated by glucose metabolism measured by positron emission tomography,[7] increased nonspecific white matter abnormalities as assessed by magnetic resonance imaging,[24] and increased interhemispheric coherence as measured by electroencephalography.[25] Furthermore, structural callosal abnormalities could contribute to the reduced interhemispheric asymmetries of function previously found in psychopathic and antisocial groups as assessed by psychophysiologic and neuropsychologic tasks.[26-30]

The key question addressed by this study concerns whether psychopathic antisocial individuals in the community show structural abnormalities in the corpus callosum and its associated white matter compared with controls drawn from the same socioeconomic stratum. In addition to linear and area measures of the corpus callosum, the volume of the callosal body and its white matter interhemispheric radiations was also estimated. Because the single previous functional imaging study[7] in offenders observed reduced callosal glucose metabolism, it may be that antisocial individuals may have reductions in callosal size. Alternatively, reduced callosal glucose metabolism has been associated with increased callosal thickness and area,[31] and, consequently, increased callosal size may also be hypothesized. A second question concerns whether any structural callosal abnormalities are paralleled by functional callosal abnormalities as measured by divided visual field tasks. Third, are abnormalities in callosal structure paralleled by dimensional analyses on a larger unselected sample? Fourth, emotion deficits hallmarked by lack of emotional depth, poor interpersonal relations, and reduced autonomic stress reactivity are key features of psychopathy[32-34]; consequently, are callosal abnormalities particularly associated with these features? Fifth, are any observed callosal abnormalities independent of psychosocial risk factors for antisocial behavior?

METHODS

PARTICIPANTS

Eighty-three men were recruited from 5 temporary employment agencies.[2] Participants were unselected, except for the following exclusion criteria: age younger than 21 years or older than 45 years, nonfluency in English, history of epilepsy, claustrophobia, pacemaker, and metal implants. One man was excluded a priori because brain scanning revealed major atrophy of the right superior temporal gyrus.[2] All individuals who read a description of the study and wanted to participate were included. Full written informed consent was obtained from all participants in accordance with institutional review board procedures at the University of Southern California. This community recruitment strategy is novel but has the advantages of (1) sampling individuals at socioeconomical high risk of psychopathy and antisocial personality disorder and (2) allowing recruitment of a control group that is demographically matched to the experimental group.

From this sample, individuals meeting the criteria for *DSM-IV* antisocial personality disorder and scoring in the top third (23-40) of the distribution of scores on the revised Psychopathy Checklist[35] were assigned to the psychopathic antisocial group (n=15). Controls neither met *DSM-IV* criteria for antisocial personality disorder or conduct disorder nor scored in the bottom third (0-14) of revised Psychopathy Checklist scores (n=25). Full demographic, cognitive, physical, psychiatric, and antisocial measures in the 2 groups, and statistical comparisons, are given in **Table 1**.

DIAGNOSTIC, COGNITIVE, PHYSICAL, AND PSYCHOSOCIAL ASSESSMENT

All diagnoses were made using *DSM-IV* criteria[36] and were ascertained using the *Structured Clinical Interview for Axis I* DSM-IV *Disorders* (*SCID*)[37] and the *Structured Clinical Interview for* DSM-IV *Axis II Personality Disorders* (*SCID-II*).[38] Diagnoses were made by research assistants who had undergone a standardized training and quality assurance program for diagnostic assessment.[39] Schizophrenia-spectrum disorder was defined as schizotypal and paranoid personality disorders. Participants also completed an alcohol use questionnaire to assess the number of times alcohol was used in the past week and in the past month.[2]

Subtests of the Wechsler Adult Intelligence Scale–Revised[40] were used to estimate verbal IQ (vocabulary, arithmetic, and digit span), performance IQ (digit symbol and block design), and total IQ. Degree of right vs left hand preference was assessed using the abbreviated Oldfield Inventory,[41] with higher scores indicating greater right-handedness. History of head injury was defined as head trauma resulting in hospitalization. Ten demographic and psychosocial measures were derived from a structured psychosocial interview with the participant,[42] with social class measured using the Hollingshead classification system.[43] A physical examination was conducted after psychophysiologic testing to derive measures of height, weight, and head circumference.

PSYCHOPATHY AND CRIME ASSESSMENT

Psychopathy was assessed using the revised Psychopathy Checklist[35] supplemented by 5 sources of collateral data. Ratings were made by a PhD clinical graduate student trained and supervised by one of us (A.R.). A total score and scores on 3 subfactors of psychopathy—arrogant/deceptive, deficient affect, and impulsive/irresponsible—were derived.[44] Internal reliability (Cronbach α) was .90. The 5 collateral data sources for assessing psychopathy were (1) the Interpersonal Measure of Psychopathy,[45] which provides an interviewer's ratings of an individual's interpersonal behaviors, has demonstrated construct validity with the revised Psychopathy Checklist in a prison sample, and has been validated for use with nonincarcerated samples (ie, college students[45]); (2) self-reported crime as assessed by an adult extension[2] of the National Youth Survey self-report delinquency measure[46]; (3) criminal history transcripts obtained from the Department of Justice; and (4 and 5) data derived from, and behavioral observations made during, the *SCID* and the *SCID-II*.

To help minimize denial of self-reported crime by truly criminal offenders, a certificate of confidentiality was obtained from the Secretary of Health and Human Services. Under section 303 (a) of Public Health Act 42, the research investigators were protected from being subpoenaed by any federal,

©2003 American Medical Association. All rights reserved.
Downloaded From: http://jamanetwork.com/ on 05/24/2013

Table 1. Comparisons Between the Control and Psychopathic Antisocial Groups on Demographic, Antisocial, Psychiatric, and Cognitive and Physical Measures*

	Control Group (n = 25)	Psychopathic Antisocial Group (n = 15)	Statistic	*P* Value
Demographic Measures				
Age, y	28.8 (6.5)	31.6 (6.6)	$t = 1.3$	.20
Social class score	36.6 (11.0)	33.3 (8.1)	$t = 1.0$	.32
Ethnicity, % white	56	33	$\chi^2 = 1.9$	.16
Cognitive and Physical Measures				
Verbal IQ	98.4 (12.5)	100.4 (12.5)	$t = 0.5$	.62
Performance IQ	106.0 (17.2)	94.6 (15.5)	$t = 2.2$	.03
Total IQ	101.6 (15.2)	97.7 (13.7)	$t = 0.8$	.41
Handedness score	33.0 (10.9)	33.7 (10.9)	$t = 0.1$	.89
Height, cm	175.1 (7.0)	181.6 (7.8)	$t = 2.7$	.009
Weight, kg	78.4 (17.4)	83.7 (9.2)	$t = 1.1$	.27
Head circumference, cm	144.5 (3.6)	147.0 (4.6)	$t = 1.9$	.07
Whole-brain volume, cm^3	1101.6 (118.3)	1096.6 (95.8)	$t = 0.1$	.89
History of head injury, %	32	40	$\chi^2 = 0.6$	.73
Antisocial Measures				
Psychopathy scores				
Total	10.8 (3.0)	30.3 (5.3)	$t = 14.8$	<.001
Arrogant/deceptive	2.0 (1.44)	6.0 (1.46)	$t = 8.4$	<.001
Deficient affect	1.4 (1.15)	5.4 (1.59)	$t = 9.2$	<.001
Impulsive/irresponsible	3.64 (1.95)	8.13 (1.72)	$t = 7.3$	<.001
Antisocial personality disorder frequency count	2.92 (1.99)	11.20 (2.00)	$t = 12.7$	<.001
Psychiatric Measures				
Substance dependence, %	18	81	$\chi^2 = 16.9$	<.001
Cannabis dependence, %	11	50	$\chi^2 = 8.4$	.004
Alcohol dependence, %	14	56	$\chi^2 = 8.6$	.003
Alcohol use in past week, No.	0.6 (0.9)	1.7 (1.8)	$t = 2.3$	.03
Alcohol use in past month, No.	3.4 (4.7)	6.9 (7.2)	$t = 2.1$	.07
Schizophrenia spectrum disorder, %	12	40	$\chi^2 = 4.2$	.04

*Data are given as mean (SD) except where noted otherwise.

state, or local court in the United States to release the self-reported crime data.

PERSONALITY AND AUTONOMIC MEASURES

Lack of emotional and social depth was assessed using 3 self-report personality questionnaires: (1) the social closeness subscale of the Multidimensional Personality Questionnaire,[47] (2) the no close friends subscale of the Schizotypal Personality Questionnaire,[48] and (3) the blunted affect subscale of the Schizotypal Personality Questionnaire.[48] In addition, lack of remorse, the only item (scored on a 3-point scale) from the *SCID-II* definition of antisocial personality disorder that reflects lack of emotional or social depth, was also used as an indicator.

Autonomic activity (skin conductance and heart rate) were assessed during a social stressor while the participant gave a speech about his worst faults.[2] These measures have been previously reported in methodological detail in this sample.[2]

CALLOSAL FUNCTIONING

Degree of functional interhemispheric connectivity was assessed using a consonant-vowel-consonant trigram identification task[49,50] and a letter-matching task.[51] Full methodological details as used in the larger sample are provided in the article by Hellige et al.[52] Briefly, in the consonant-vowel-consonant task, participants were presented with a nonsense consonant-vowel-consonant stimulus in either the left or right visual field or in both fields simultaneously (bilateral condition). The callosal integration measure was the difference in accuracy between the bilateral condition and the better of the 2 individual visual field accuracy scores, with higher scores indicating greater integration.[49] In the letter-matching task, uppercase and lowercase letters that either matched (eg, A-a) or did not match (eg, A-b) were presented either within or between visuals fields. The callosal integration measure was defined as errors on within-field trials minus errors on between-field trials, with higher scores indicating increased integration.[51]

MAGNETIC RESONANCE IMAGING

Acquisition

Imaging procedures have been previously reported.[2] Briefly, structural magnetic resonance imaging was conducted on a 1.5-T scanner (model S15/ACS; Philips, Shelton, Conn). After an initial alignment sequence of 1 midsagittal and 4 parasagittal scans (spin-echo T1-weighted image acquisition: repetition time, 600 milliseconds; echo time, 20 milliseconds) to identify the anterior commissure–posterior commissure plane, 128 3-dimensional T1-weighted gradient-echo coronal images (repetition time, 34 milliseconds; echo time, 12.4 milliseconds; flip angle, 35°; overcontiguous slices, 1.7 mm; matrix, 256 × 256; and field of view, 23 cm) were taken directly orthogonal to the anterior commissure–posterior commissure line.

Callosal Measures

Three-dimensional brain images were reconstructed using a SPARC workstation (Sun Microsystems Inc, Santa Clara, Calif) and semi-

©2003 American Medical Association. All rights reserved.
Downloaded From: http://jamanetwork.com/ on 05/24/2013

automated software (CAMRA S200 ALLEGRO; Cedar Software Corp, Mississauga, Ontario, Canada) for gray matter–white matter–cerebrospinal fluid segmentation. Segmentation was performed using a thresholding algorithm, with the operator (masked to group membership and other nonbrain measures) applying a cutoff value to the signal-intensity histogram to optimally differentiate white matter from gray matter, areas of which were defined using an automated seeding algorithm on each slice. Callosal and whole-brain volume measures were derived from the original coronal slices, whereas callosal area and linear measures were derived from the reformatted midsagittal slice orthogonal to the coronal acquisition plane and identified using the fourth ventricle and the aqueduct of Sylvius as landmarks.

Callosal area and linear measurement procedures were adopted from previous studies.[53-55] A line was drawn between anterior and posterior points of the corpus callosum[54] to define callosal length. Perpendicular lines were then drawn to define the area of the genu as the anterior fourth and the area of the splenium as the posterior fifth (**Figure**, A). Callosal thickness was defined as the thickness of the corpus callosum at the midpoint of the length of the corpus callosum (Figure, A). Using coronal slices, an estimate of callosal and pericallosal white matter volume was obtained (Figure, B). On every coronal slice showing the body of the corpus callosum, the area of the corona radiata extending into each hemisphere, together with the body of the corpus callosum, was calculated by seeding white matter (see first paragraph of this section). Only white matter adjacent to and contiguous with the body of the corpus callosum was measured. Callosal volume was expressed as a function of whole-brain volume, whereas the genu and splenium areas were expressed as a function of total callosal area.

Whole-brain volume was defined as all cerebral cortex excluding the ventricles, pons, and cerebellum. The pons was excluded by drawing a straight line between the 2 innermost points that form the superior border. Colliculi were excluded when they were no longer attached to the cerebral hemispheres. For volume measures, areas on each slice were multiplied by slice thickness (1.7 mm) and summated to provide volumes. Interrater reliabilities (intraclass correlation coefficients) based on 27 scans (raters masked to each other's ratings and to group membership) were as follows: total brain volume, 0.99; estimated callosal and white matter volume, 0.72; genu, 0.95; splenium, 0.97; thickness, 0.55; and length, 0.99.

STATISTICAL ANALYSES

All analyses were conducted using statistical software (SPSS Inc, Chicago, Ill). Between-group *t* tests and χ^2 tests were used to assess group differences on antisocial, demographic, magnetic resonance imaging, personality, cognitive, and psychophysiologic variables. All tests of significance are 2-tailed. Effect sizes were calculated using η^2 (% variance accounted for) and Cohen d.[56] To obtain a single overarching measure of callosal structure, a principal component analysis was conducted to extract a first component with significant loadings from all variables and a factor score computed using the regression method (mean±SD, 0±1). To assess the overall relationship between corpus callosum structure and group, all callosal measures were first entered into a multivariate analysis of variance (MANOVA). Follow-up univariate F tests were then conducted to assess which specific callosal measures differentiated the groups. To control for confounds, multivariate analysis of covariance was used. Logistic regression was conducted to predict group membership from the callosal measures over and above psychosocial measures using the enter procedure, a classification cutoff value of 0.5, and with variance estimation assessed using the Nagelkerke statistic. Categorical group analyses were followed up with dimensional, correlational analyses conducted on the entire sample (N=83).

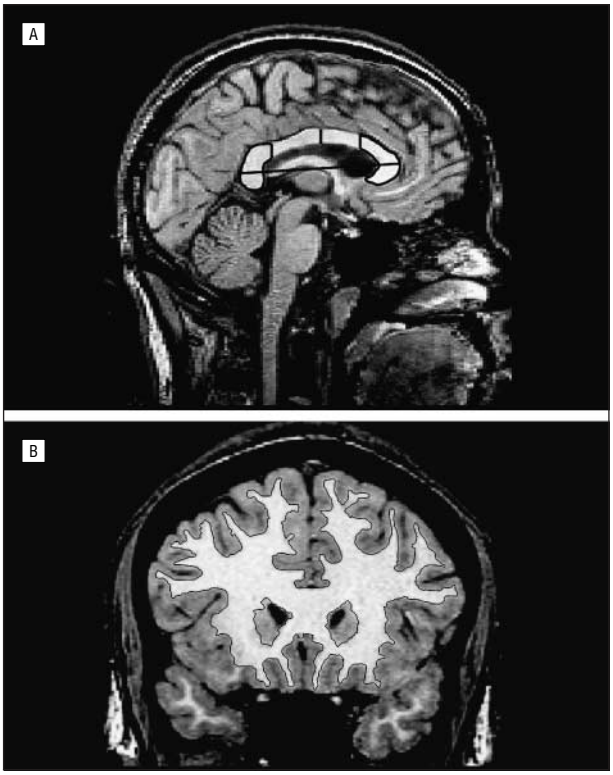

A, Midsagittal slice of the corpus callosum illustrating measurement of the length, thickness, and area of the genu and splenium. B, Coronal slice through the genu and the rostrum of the corpus callosum illustrating the volume estimate of the body of the corpus callosum and the corona radiata extending into each hemisphere.

RESULTS

CORPUS CALLOSUM STRUCTURE

A principal component analysis of the 5 callosal measures produced a first principal component accounting for 32.4% of the variance, with significant loadings from volume (0.54), length (0.58), thickness (–0.48), genu area (–0.40), and splenium area (0.78). High factor scores indicated increased volume, increased length, increased splenium area, reduced genu area, and reduced thickness. The psychopathic antisocial group (mean±SD, 0.59±0.98) scored significantly higher than controls (mean±SD, –0.31±0.97) on this factor (t=2.8, d=0.93; P=.009).

An omnibus MANOVA on callosal thickness, length, genu and whole-brain volume, splenium and whole-brain volume, and callosal white matter and whole-brain volume indicated an overall group difference ($F_{5,32}$=6.8, η^2=0.52; P<.001). Follow-up univariate F tests indicated that psychopathic antisocial individuals compared with controls had significantly increased callosal white matter and whole-brain volumes, increased callosal length, and reduced callosal thickness, but only a trend for a larger splenium (**Table 2**).

Groups differed most on estimated callosal volume (Table 2). It is possible that the increased length of the corpus callosum in the psychopathic antisocial group entirely accounts for the increase in white matter volume. After entry of callosal length as a covariate in an analysis of covariance, group difference in estimated callosal vol-

©2003 American Medical Association. All rights reserved.
Downloaded From: http://jamanetwork.com/ on 05/24/2013

Table 2. Callosal Structure and Function in the Psychopathic Antisocial and Control Groups*

	Control Group (n = 25)	Psychopathic Antisocial Group (n = 15)	$F_{1,36}$	*P* Value	η^2
		Callosal Structure			
White matter/whole-brain	0.31 (0.04)	0.38 (0.05)	22.4	<.001	0.38
Callosal length, mm	74.0 (4.9)	79.1 (4.0)	10.6	.002	0.23
Callosal thickness, mm	7.2 (1.9)	6.1 (0.8)	4.4	.04	0.11
Genu area/callosal area	0.34 (0.07)	0.32 (0.05)	0.7	.41	0.02
Splenium area/callosal area	0.27 (0.03)	0.30 (0.04)	3.3	.08	0.08
		Callosal Function			
Consonant-vowel-consonant task	1.77 (8.3)	7.64 (8.1)	4.9	.03	0.11
Letter-matching task	3.02 (4.0)	5.79 (4.1)	4.4	.04	0.10

*Data are given as mean (SD).

Table 3. Group Comparisons on Personality and Autonomic Measures*

	Control Group (n = 25)	Psychopathic Antisocial Group (n = 15)	t_{42}	*P* Value	d
		Personality Measures			
Social closeness score	14.0 (3.2)	11.9 (3.6)	2.1	.045	0.69
Blunted affect score	1.4 (1.5)	2.3 (1.9)	1.7	.09	0.56
No close friends score	2.0 (2.0)	3.1 (2.3)	1.6	.13	0.52
Lack of remorse score	1.00 (0.0)	2.31 (0.9)	8.0	<.001	3.7
		Autonomic Measures			
Skin conductance, μs	7.6 (3.2)	5.3 (2.4)	2.4	.02	0.78
Heart rate, bpm	78.5 (11.2)	69.5 (8.0)	2.8	.008	0.91

*Data are give as mean (SD).

ume remained significant ($F_{1,36}$=7.7; *P*=.009), indicating that increased callosal volume was not a function of increased callosal length.

Logistic regression using callosal measures to predict group membership was significant (χ^2_5=33.8; *P*<.001) and correctly classified 92% of the cases. Of the 2 controls who were misclassified as being psychopathic antisocial, one had the highest score in the control group on psychopathy (score, 14) and the other had the lowest skin conductance level during the stressor (2.19 microseconds). The one psychopathic antisocial individual misclassified as a control had the highest heart rate during the stressor (88 bpm) in their group.

PERSONALITY AND AUTONOMIC MEASURES

Although psychopathic antisocial individuals scored significantly lower than controls on self-reported social closeness, the effect of higher scores on blunted affect was only marginally significant, and the higher scores on no close friends was nonsignificant (**Table 3**). Consistent with the way groups were composed, psychopathic antisocial individuals were lacking remorse. As expected from previous findings,[2] psychopathic antisocial individuals showed significantly reduced skin conductance and heart rate activity during the social stressor (Table 3).

RELATIONSHIPS BETWEEN CALLOSAL MEASURES AND DIMENSIONAL MEASURES OF PSYCHOPATHY

The previous categorical findings were confirmed in a dimensional, correlational analysis using the entire sample. The strongest findings were found for the overall callosal factor score, with positive correlations for antisocial measures ranging from 0.35 to 0.51 (**Table 4**). In addition, increased callosal volume was significantly associated with blunted affect, lack of remorse, no close friends, lack of social closeness, reduced skin conductance and heart rate activity during the stressor, and, to a more limited extent, reduced spatial ability. Of the 5 contributing callosal measures, estimated callosal volume provided the most substantive contribution, with increased volume significantly associated with increased psychopathy, increased interpersonal deficits, reduced autonomic activity, and low spatial IQ. The association with psychopathy factors was most pronounced for deficient affect and least pronounced for arrogant/deceptive.

CALLOSAL FUNCTIONING

A MANOVA indicated group differences on the 2 interhemispheric communication measures ($F_{2,37}$=4.3, η^2=0.19; *P*=.02). The higher scores on both measures in the psychopathic antisocial group indicated greater hemispheric connectivity in this group compared with controls. However, in the enlarged sample (N=83), these functional measures correlated neither with structural callosal measures (*r*=–0.07 to 0.19; *P*>.07) nor with antisocial, personality, and psychophysiologic measures (*r*=–0.15 to 0.18; *P*>.10).

POTENTIAL CONFOUNDS

Because the psychopathic antisocial group had significantly higher rates of alcohol and substance dependence than controls (Table 1), these variables were entered together as covariates in a MANOVA containing structural and functional callosal measures. The main effect for group remained significant ($F_{7,28}$=3.9, η^2=0.51; *P*<.004). Because alcohol use is of particular concern

©2003 American Medical Association. All rights reserved.
Downloaded From: http://jamanetwork.com/ on 05/24/2013

Table 4. Intercorrelations Between Structural Callosal Measures and Antisocial, Personality, Autonomic, and Cognitive Measures in the Total Sample of 83 Participants

		Corpus Callosum Measures				
	Callosal Factor	Volume	Thickness	Length	Genu Area	Splenium Area
		Antisocial Measures				
Psychopathy						
Total	0.51*	0.35*	−0.21†	0.26‡	−0.14	0.22‡
Arrogant/deceptive	0.35*	0.16	−0.24‡	0.16	−0.09	0.17
Deficient affect	0.46*	0.34*	−0.20†	0.22‡	−0.14	0.19†
Impulsive/irresponsible	0.37*	0.23‡	−0.13	0.19†	−0.14	0.19†
Antisocial personality disorder	0.39*	0.26‡	−0.12	0.20†	−0.17	0.17
		Personality Measures				
No close friends	0.29§	0.27‡	−0.25§	0.01	−0.05	0.24‡
Social closeness	−0.23‡	−0.29§	0.24‡	−0.05	−0.02	−0.08
Blunted affect	0.31§	0.24‡	−0.33§	0.04	0.01	0.28§
Lack of remorse	0.42*	0.46*	−0.09	0.23‡	−0.01	0.11
		Autonomic Measures				
Skin conductance	−0.39*	−0.23‡	0.27‡	−0.08	0.12	−0.32§
Heart rate	−0.25‡	−0.04	0.19†	0.03	0.21†	−0.18
		Cognitive Measures				
Verbal IQ	−0.08	−0.19	−0.16	−0.13	0.07	0
Performance IQ	−0.21†	−0.25‡	0.10	−0.08	0.02	0
Total IQ	−0.18	−0.24‡	−0.06	−0.13	0.08	−0.05

*$P<.001$, 2-tailed test.
†$P<.10$, 2-tailed test.
‡$P<.05$, 2-tailed test.
§$P<.01$, 2-tailed test.

given its previous links to callosal abnormalities,[57] alcohol use measures were entered as covariates alongside alcohol dependence. The main effect for group remained significant ($F_{7,28}=5.6$, $\eta^2=0.59$; $P<.001$).

Similarly, because increased white matter volume has been observed in cannabis users,[58] cannabis could account for the observed relationships. However, after entry of cannabis abuse/dependence as a covariate, the main group effect remained significant ($F_{7,28}=5.3$, $\eta^2=0.57$; $P=.001$).

Because schizophrenia-spectrum disorders show callosal abnormalities,[14,18] and because psychopathic antisocial individuals had a higher rate of such disorders, they could be confounds. Consequently, diagnoses of schizotypal and paranoid personality disorder were simultaneously entered as covariates in the MANOVA. The main effect of group on callosal measures remained significant ($F_{7,28}=4.1$, $\eta^2=0.52$; $P=.003$).

To assess whether effects were independent of head circumference and IQ, these variables were entered as covariates. The main group effect remained significant ($F_{5,27}=8.0$, $\eta^2=0.60$; $P<.001$).

INDEPENDENCE FROM PSYCHOSOCIAL FACTORS

Psychosocial risk factors for antisocial behavior could account for the link between psychopathy and callosal structure and function. After entry of the 10 psychosocial risk factors as covariates in the MANOVA (physical abuse, sexual abuse, raised in an institution, raised by foster parents, parental criminality, early parental divorce, parental physical fights, parental verbal arguments, large family size, and low social class), the main effect remained significant ($F_{7,20}=3.9$, $\eta^2=0.59$; $P=.009$), indicating that the group findings were not attributable to these psychosocial processes.

Callosal structure and function measures also added to the prediction of psychopathic antisocial vs control group membership over and above psychosocial measures. In logistic regression, the 10 psychosocial risk factors accounted for 32.7% of the variance in group membership on block 1. After entry of the callosal measures on block 2, variance accounted for increased significance to 81.5% ($\chi^2_2=23.9$; $P<.001$).

COMMENT

To our knowledge, this study establishes for the first time the existence of a structural abnormality in the corpus callosum of psychopathic antisocial individuals. This group had a 22.6% increase in the volume of the corpus callosum and corona radiata compared with controls, a large effect size corresponding to $d=1.8$.[56] Callosi were 15.3% thinner ($d=0.7$) and 6.9% longer ($d=1.1$) in psychopathic antisocial individuals. These group differences were mirrored by dimensional, correlational findings in the larger sample of 83 men, with larger estimated callosal volumes associated with higher antisocial and psychopathy scores, especially with respect to affective psychopathic features and affective-social personality characteristics. Psychopathic antisocial individuals also showed significantly increased functional connectivity between the 2 hemispheres, but in this case categorical differ-

©2003 American Medical Association. All rights reserved.
Downloaded From: http://jamanetwork.com/ on 05/24/2013

ences were not reflected in dimensional analyses in the entire sample. These structural and functional callosal abnormalities could not be attributed to alcohol and substance use, psychosocial deficits, head injury, schizophrenia-spectrum disorder, or whole-brain volume, and neither could callosal volume effects be attributed to increased callosal length.

Callosal structural abnormalities, particularly increased length and volume, suggest the possibility that psychopathic antisocial personality may be partly neurodevelopmental. Research with monkeys,[59] cats,[60] and hamsters[61] has shown that approximately two thirds of callosal axons are eliminated postnatally through adulthood, with most of this pruning being to excitatory rather than inhibitory fibers.[62] Early arrest of this normal process of axonal pruning, therefore, could contribute to the increased callosal white matter volume and the functional overconnectedness of the hemispheres observed in the psychopathic antisocial group. Despite extensive postnatal axonal pruning in healthy individuals, recent brain imaging research[63,64] on children has documented major, rapid growth in the corpus callosum from early childhood to early adolescence presumably due to increased myelination of fibers that survive early elimination. Consequently, an abnormality in the myelination process involving overutilization of oligodendrocytes in the production of the myelin sheath could also partly explain callosal abnormalities in psychopathic antisocial individuals. Together, reduced retraction of inhibitory callosal fibers and increased myelination of axons could facilitate excitatory nerve conduction, which, in turn, could facilitate interhemispheric transfer and be consistent with the functional callosal findings of increased interhemispheric connectivity in psychopathic antisocial individuals.

A neurodevelopmental perspective of adult psychopathic antisocial personality is consistent with the facts that such behavior has its roots early in life,[65,66] unfolds relatively consistently during childhood and adolescence,[67,68] is relatively impervious to conventional treatments,[69,70] and is in part genetically determined.[71] In addition, psychosocial, demographic, and head injury measures could not account for structural callosal impairments in this group. As noted herein, a variety of other disorders that are neurodevelopmental in nature (eg, schizophrenia, schizotypal personality disorder, velocardiofacial syndrome, developmental language disorder, and dyslexia) are also characterized by increased callosal size. The fact that morphologic changes to the corpus callosum were complex, involving thinning and lengthening as well as increased white matter volume, tends to dictate against simple, nondevelopmental processes such as discrete trauma or degenerative disease processes.

The callosal structural abnormalities observed during this study may help account for the abnormal interhemispheric processing in psychopathic individuals repeatedly observed in multiple cross-laboratory studies.[26-29,72-77] The most commonly reported abnormalities in psychopathic individuals are reduced lateralization in P300 amplitudes,[29] verbal dichotic listening,[26-28] and visual event-related potentials.[30] Reduced lateralization could be a consequence of greater interhemispheric connectivity. In line with this proposition, greater interhemispheric connectivity was found herein for psychopathic antisocial individuals as assessed by divided visual field tasks. Our group[72] has previously hypothesized that prior findings of reduced lateralization may arise from a disturbance in the normal neurodevelopmental processes of hemispheric specialization. Atypical neurodevelopment of the corpus callosum could have wide-ranging effects on the interhemispheric regulatory processes that contribute to the affective, autonomic, cognitive, and antisocial characteristics that predispose to antisocial personality disorder and psychopathy.

A key feature of psychopathy is blunted affect, and low autonomic activity during emotional and social stressors is a well-replicated correlate of psychopathy.[32-34,78,79] Callosal white matter volume was significantly related to the deficient affect factor of psychopathy and, to a lesser extent, to the impulsive/irresponsible factor but not to the arrogant/deceptive factor. Similarly, autonomic and personality measures reflecting blunted affect, lack of social closeness, and no close friends were related to callosal abnormalities. Individuals who experience neurodevelopmental failure of the corpus callosum do not evidence gross psychiatric symptoms but do show deficits in social insight and self-perception,[80] deficits that also characterize psychopathic individuals.[35,81] As such, abnormal interhemispheric connectivity may partly account for the social, insight, autonomic, and emotion deficits observed in psychopathic individuals.

Low spatial IQ was observed in the psychopathic antisocial group and was additionally associated with increased estimated callosal volume. These associations are of interest for 3 reasons. First, agenesis of the corpus callosum and split-brain surgery have been associated with poor spatial ability.[82,83] Second, low spatial but not verbal ability early in life has been found to characterize lifelong antisocial individuals.[84] Third, the same correlation between increased estimated callosal volume and low spatial IQ has also been found in neurofibromatosis.[85] These findings, in turn, suggest that callosal abnormalities may account for the spatial deficits in psychopathic antisocial individuals and that increased callosal volume relative to normal is disadvantageous rather than beneficial.

Limitations of this study include the fact that because only men were studied, findings cannot currently be generalized to antisocial women. Group sizes were modest, although expanded analyses on the larger sample of 83 men indicate that the key results are reliable. Although group differences in callosal functioning were found in parallel with structural callosal deficits, these measures were not intercorrelated in the expanded sample, indicating that structural and functional deficits are found only at the level of pathological grouping. The volume estimate of callosal white matter includes pericallosal white matter, and so findings may not be entirely specific to callosal integrity. Alternatively, this volume measure loaded substantially (0.54) on the callosal factor, indicating that results were not driven exclusively or primarily by pericallosal white matter. Reliability for some callosal measures was modest, and, consequently, effect sizes may be underestimates of true effect sizes. Personality measures of affect, although supported by autonomic measures, also have their limitations.

©2003 American Medical Association. All rights reserved.
Downloaded From: http://jamanetwork.com/ on 05/24/2013

Finally, only an association has been shown between callosal deficits and psychopathic antisocial behavior, and causality cannot be assumed. Specifically, it is unlikely that callosal abnormalities directly cause antisocial psychopathic behavior in a one-to-one fashion and more likely they contribute to a breakdown in a wider network of regulatory interhemispheric cortical systems that regulate and control behavior. Thus, a critical question to be addressed in the future concerns how these individual brain deficits are networked and conspire to produce psychopathic antisocial behavior. Atypical neurodevelopment of the corpus callosum and consequent "faulty wiring" of the brain may be one of the contributory mechanisms to the development of psychopathic behavior, but alternative processes and the interplay with early psychosocial development influences should not be discounted. Future studies using diffusion tensor imaging to measure white matter integrity could help confirm and extend the present findings.

Submitted for publication May 7, 2002; final revision received May 9, 2003; accepted May 12, 2003.

This study was supported by Research Scientist Development Award K02 MH01114-01, Independent Scientist Award K02 MH01114-08, and grant 5 RO3 MH50940-02 from the National Institute of Mental Health, Bethesda, Md (Dr Raine), and by the Wacker Foundation, Dallas, Tex (Dr Raine).

We thank Jennifer Bobier, BA, Nicole Diamond, BA, Kevin Ho, BA, Blane Horvath, BSc, Rina Kadakia, Shari Mills, PhD, and Pauline Yaralian, PhD, for assistance with data collection and scoring.

Corresponding author: Adrian Raine, DPhil, Department of Psychology, University of Southern California, Los Angeles, CA 90089-1061 (e-mail: raine@usc.edu).

REFERENCES

1. Damasio A. *Descartes' Error: Emotion, Reason, and the Human Brain.* New York, NY: GP Putnam's Sons; 1994.
2. Raine A, Lencz T, Bihrle S, LaCasse L, Colletti P. Reduced prefrontal gray matter volume and reduced autonomic activity in antisocial personality disorder. *Arch Gen Psychiatry.* 2000;57:119-127.
3. Volkow ND, Tancredi LR, Grant C, Gillespie H, Valentine A, Nullani N, Wang GJ, Hollister L. Brain glucose metabolism in violent psychiatric patients: a preliminary study. *Psychiatry Res.* 1995;61:243-253.
4. Intrator J, Hare R, Stritzke P, Brichtswein K, Dorfman D, Harpur T, Bernstein D, Handelsman L, Schaefer C, Keilp J, Rosen J, Machac J. A brain imaging (single photon emission computerized tomography) study of semantic and affective processing in psychopaths. *Biol Psychiatry.* 1997;42:96-103.
5. Laakso MP, Vaurio O, Koivisto E, Savolainen L, Eronen M, Aronen HJ, Hakola P, Repo E, Soininen H, Tiihonen J. Psychopathy and the posterior hippocampus. *Behav Brain Res.* 2001;118:187-193.
6. Kiehl KA, Smith AM, Hare RD, Mendrek A, Forster BB, Brink J, Liddle PF. Limbic abnormalities in affective processing by criminal psychopaths as revealed by functional magnetic resonance imaging. *Biol Psychiatry.* 2001;50:677-684.
7. Raine A, Buchsbaum M, LaCasse L. Brain abnormalities in murderers indicated by positron emission tomography. *Biol Psychiatry.* 1997;42:495-508.
8. Siever LJ, Buchsbaum MS, New AS, Spiegel-Cohen J, Wei T, Hazlett EA, Sevin E, Nunn M, Mitropoulou V. d,l-Fenfluramine response in impulsive personality disorder assessed with [18F]fluorodeoxyglucose positron emission tomography. *Neuropsychopharmacology.* 1999;20:413-423.
9. Amen DG, Stubblefield M, Carmichael B, Thisted R. Brain SPECT findings and aggressiveness. *Ann Clin Psychiatry.* 1996;8:129-137.
10. Davidson RJ, Putnam KM, Larson CL. Dysfunction in the neural circuitry of emotion regulation: a possible prelude to violence. *Science.* 2000;289:591-594.
11. Cook ND. *The Brain Code: Mechanisms of Information Transfer and the Role of the Corpus Callosum.* London, England: Methuen & Co; 1986.
12. Kitterle FL. *Hemispheric Communication: Mechanisms and Models.* Hillsdale, NJ: Lawrence A Erlbaum Associates; 1995.
13. Coger RW, Serafetinides EA. Schizophrenia, corpus callosum, and interhemispheric communication: a review. *Psychiatry Res.* 1990;34:163-184.
14. Nasrallah HA, Andreasen NC, Coffman JA, Olson SC, Dunn VD, Erhardt JC, Chapman SM. A controlled magnetic resonance imaging study of corpus callosum thickness in schizophrenia. *Biol Psychiatry.* 1986;21:274-282.
15. Raine A, Harrison GN, Reynolds GP, Sheard C, Cooper JE, Medley I. Structural and functional characteristics of the corpus callosum in schizophrenics, psychiatric controls, and normal controls: a magnetic resonance imaging and neuropsychological evaluation. *Arch Gen Psychiatry.* 1990;47:1060-1064.
16. Narr KL, Thompson PM, Sharma T, Moussai J, Cannestra AF, Toga AW. Mapping morphology of the corpus callosum in schizophrenia. *Cereb Cortex.* 2000;10:40-49.
17. Jacobsen LK, Giedd JN, Rajapakse JC, Hamburger SD, Vaituzis AC, Frazier JA, Lenane MC, Rapoport JL. Quantitative magnetic resonance imaging of the corpus callosum in childhood onset schizophrenia. *Psychiatry Res.* 1997;68:77-86.
18. Downhill JE, Buchsbaum MS, Wei T, Spiegel-Cohen J, Hazlett EA, Haznedar MM, Silverman J, Siever LJ. Shape and size of the corpus callosum in schizophrenia and schizotypal personality disorder. *Schizophr Res.* 2000;42:193-208.
19. Preis S, Steinmetz H, Knorr U, Jaencke L. Corpus callosum size in children with developmental language disorder. *Brain Res Cogn Brain Res.* 2000;10:37-44.
20. Robichon F, Habib M. Abnormal callosal morphology in male adult dyslexics: relationships to handedness and phonological abilities. *Brain Lang.* 1998;62:127-146.
21. Kivitie-Kallio S, Autti T, Salonen O, Norio R. MRI of the brain in the Cohen syndrome: a relatively large corpus callosum in patients with mental retardation and microcephaly. *Neuropediatrics.* 1998;29:298-301.
22. Usiskin SI, Nicholson R, Krasnewich DM, Yah W, Lenane M, Wudarsky M, Hamburger SD, Rapoport JL. Velocardiofacial syndrome in childhood-onset schizophrenia. *J Am Acad Child Adolesc Psychiatry.* 1999;38:1536-1543.
23. Kayl AE, Moore BDI, Slopis JM, Jackson EF, Leeds NE. Quantitative morphology of the corpus callosum in children with neurofibromatosis and attention-deficit hyperactivity disorder. *J Child Neurol.* 2000;15:90-96.
24. Wong MTH, Lumsden J, Fenton GW, Fenwick PBC. Neuroimaging in mentally abnormal offenders. *Issues Criminol Legal Psychol.* 1997;27:49-58.
25. Evans JR, Park NS. Quantitative EEG findings among men convicted of murder. *J Neurother.* 1997;2:31-39.
26. Raine A, O'Brien M, Smiley N, Scerbo A, Chen CJ. Reduced lateralization in verbal dichotic listening in adolescent psychopaths. *J Abnorm Psychol.* 1990;99:272-277.
27. Hare RD, McPherson LM. Psychopathy and perceptual asymmetry during verbal dichotic listening. *J Abnorm Psychol.* 1984;93:141-149.
28. Hare RD, Jutai JW. Psychopathy and cerebral asymmetry in semantic processing. *Pers Individ Dif.* 1988;9:329-337.
29. Kiehl KA, Hare RD, Liddle PF, McDonald JJ. Reduced P300 responses in criminal psychopaths during a visual oddball task. *Biol Psychiatry.* 1999;45:1498-1507.
30. Shumskaya AA. Interhemispheric asymmetry of visual evoked potentials in psychopathies. *Neurosci Behav Physiol.* 1984;14:267-272.
31. Wu JC, Buchsbaum MS, Johnson JC, Hershey TG, Wagner EA, Teng C, Lottenberg S. Magnetic resonance and positron emission tomography imaging of the corpus callosum: size, shape and metabolic rate in unipolar depression. *J Affect Disord.* 1993;28:15-25.
32. Hare RD. Psychopathy and physiological activity during anticipation of an adversive stimulus in a distraction paradigm. *Psychophysiology.* 1982;19:266-271.
33. Patrick CJ, Zempolich KA, Levenston GK. Emotionality and violent behavior in psychopaths: a biosocial analysis. In: *Biosocial Bases of Violence.* New York, NY: Plenum Publishing Corp; 1997:145-161.
34. Herpertz SC, Werth U, Lucas G, Qunaibi M, Schuerkens A, Kunert HJ, Freese R, Flesch M, Mueller-Isberner R, Osterheider M, Sass H. Emotion in criminal offenders with psychopathy and borderline personality disorders. *Arch Gen Psychiatry.* 2001;58:737-745.
35. Hare RD, Harpur TJ, Hakstian AR, Forth AE. The revised Psychopathy Checklist: reliability and factor structure. *Psychol Assess.* 1990;2:338-341.
36. American Psychiatric Association. *Diagnostic and Statistical Manual of Mental Disorders, Fourth Edition.* Washington, DC: American Psychiatric Association; 1994.
37. First MB, Spitzer RL, Gibbon M, Williams JBW. *Structured Clinical Interview for Axis I* DSM-IV *Disorders (SCID, Version 2.0).* New York: New York State Psychiatric Institute; 1994.

©2003 American Medical Association. All rights reserved.
Downloaded From: http://jamanetwork.com/ on 05/24/2013

38. First MB, Spitzer RL, Gibbon M, Williams JBW, Benjamin L. *Structured Clinical Interview for* DSM-IV *Axis II Personality Disorders (SCID-II, Version 2.0)*. New York: New York State Psychiatric Institute; 1994.
39. Ventura J, Liberman RP, Green MF, Shaner A, Mintz J. Training and quality assurance with *Structured Clinical Interview for* DSM-IV *(SCID-I/P)*. *Psychiatry Res*. 1998;79:163-173.
40. Wechsler D. *Wechsler Adult Intelligence Scale–Revised*. San Antonio, Tex: Psychological Corp; 1981.
41. Bryden MP. Measuring handedness with questionnaires. *Neuropsychologia*. 1977; 15:617-624.
42. Raine A. Structural and functional brain imaging correlates of violence. Paper presented at: Panel on Imaging Disorders of Impulse Control, 36th Annual Meeting of the American College of Neuropsychopharmacology; December 11, 1997; Waikoloa, Hawaii.
43. Hollingshead AB. *Four Factor Index of Social Status*. New Haven, Conn: Yale University; 1975.
44. Cooke DJ, Michie C. Refining the construct of psychopath: towards a hierarchical model. *Psychol Assess*. 2001;13:171-188.
45. Kosson DS, Steuerwald BL, Forth AE, Kirkhart KJ. A new method for assessing the interpersonal behavior of psychopathic individuals: preliminary validation studies. *Psychol Assess*. 1997;9:89-101.
46. Elliott DS, Ageton S, Huizinga D, Knowles B, Canter R. *The Prevalence and Incidence of Delinquent Behavior: 1976-1980: National Youth Survey, Report No. 26*. Boulder, Colo: Behavior Research Institute; 1983.
47. Tellegen A, Lykken DT, Bouchard TJ, Wilcox KJ, Rich S, Segal NL. Personality similarity in twins reared apart and together. *J Pers Soc Psychol*. 1988;54:1031-1039.
48. Raine A. The SPQ: a scale for the assessment of schizotypal personality based on *DSM-III-R* criteria. *Schizophr Bull*. 1991;17:555-564.
49. Hellige JB, Taylor AK, Eng TL. Interhemispheric interaction when both hemispheres have access to the same stimulus information. *J Exp Psychol Hum Percept Perform*. 1989;15:711-722.
50. Hellige JB, Bloch MI, Cowin EL, Eng TL, Eviatar Z, Sergent V. Individual variation in hemispheric asymmetry: multitask study of effects related to handedness and sex. *J Exp Psychol Gen*. 1994;123:235-256.
51. Banich MT, Goering S, Stolar N, Belger A. Interhemispheric processing in left- and right-handers. *Int J Neurosci*. 1990;54:197-208.
52. Hellige JB, Taylor KB, Lesmes L, Peterson S. Relationships between brain morphology and behavioral measures of hemispheric asymmetry and interhemispheric interaction. *Brain Cogn*. 1998;36:158-192.
53. Clarke JM, Lufkin RB, Zaidel E. Corpus callosum morphometry and dichotic listening performance: individual differences in functional interhemispheric inhibition? *Neuropsychologia*. 1993;31:547-557.
54. Clarke JM, Zaidel E. Anatomical-behavioral relationships: corpus callosum morphometry and hemispheric specialization. *Behav Brain Res*. 1994;64:185-202.
55. Hines M, Chiu L, McAdams LA, Bentler PM, Lipcamon J. Cognition and the corpus callosum: verbal fluency, visuospatial ability, and language lateralization related to midsagittal surface areas of callosal subregions. *Behav Neurosci*. 1992; 106:3-14.
56. Cohen J. *Statistical Power Analysis for the Behavioral Sciences*. 2nd ed. Hillsdale, NJ: Lawrence A Erlbaum Associates; 1988.
57. Riikonen R, Salonen I, Verho S. Brain perfusion SPECT and MRI in foetal alcohol syndrome. *Dev Med Child Neurol*. 1999;41:652-659.
58. Wilson W, Mathew R, Turkington T, Hawk T, Coleman RE, Provenzale J. Brain morphological changes and early marijuana use: a magnetic resonance and positron emission tomography study. *J Addict Dis*. 2000;19:1-22.
59. LaMantia AS, Rakic P. Axon overproduction and elimination in the corpus callosum of the developing rhesus monkey. *J Neurosci*. 1990;10:2156-2175.
60. Bressoud R, Innocenti GM. Typology, early differentiation, and exuberant growth of a set of cortical axons. *J Comp Neurol*. 1999;406:87-108.
61. Halloran MC, Kalil K. Dynamic behaviors of growth cones extending to the corpus callosum of living cortical brain slices observed with video microscopy. *J Neurosci*. 1994;14:2161-2177.
62. Saugstad LF. The maturational theory of brain development and cerebral excitability in the multifactorially inherited manic depressive psychosis and schizophrenia. *Int J Psychophysiol*. 1994;18:189-203.
63. Thompson PM, Giedd JN, Woods RP, MacDonald D, Evans AC, Toga AW. Growth patterns in the developing brain detected by using continuum mechanical tensor maps. *Nature*. 2000;404:190-193.
64. Giedd JN, Blumenthal J, Jeffries NO, Rajapakse JC, Vaituzis AC, Liu H, Berry YC, Tobin M, Nelson J, Castellanos FX. Development of the human corpus callosum during childhood and adolescence: a longitudinal MRI study. *Prog Neuropsychopharmacol Biol Psychiatry*. 1999;23:571-588.
65. Caspi A, Moffitt TE, Newman DL, Silva PA. Behavioral observations at age 3 years predict adult psychiatric disorders. *Arch Gen Psychiatry*. 1996;53:1033-1039.
66. Moffitt TE. Adolescence-limited and life-course-persistent antisocial behavior: a developmental taxonomy. *Psychol Rev*. 1993;100:674-701.
67. Lynam DR. Early identification of chronic offenders: who is the fledgling psychopath? *Psychol Bull*. 1996;120:209-234.
68. Robins LN. A 70-year history of conduct disorder: variations in definition, prevalence, and correlates. In: Cohen P, Slomkowski C, Robins RN, eds. *Time, Place and Psychology*. Mahwah, NJ: Lawrence A Erlbaum Associates; 1999:37-56.
69. Rice ME. Violent offender research and implications for the criminal justice system. *Am Psychol*. 1997;52:414-423.
70. Seto MC, Barbaree HE. Psychopathy, treatment behavior, and sex offender recidivism. *J Interpers Violence*. 1999;14:1235-1248.
71. Cadoret RJ, Yates WR, Troughton E, Woodworth G. Genetic-environmental interaction in the genesis of aggressivity and conduct disorders. *Arch Gen Psychiatry*. 1995;52:916-924.
72. Raine A, Lencz T, Scerbo A. Antisocial personality: neuroimaging, neuropsychology, neurochemistry, and psychophysiology. In: Ratey JH, ed. *Neuropsychiatry of Behavior Disorders*. Oxford, England: Blackwell; 1995:50-78.
73. Pine DS, Bruder GE, Wasserman GA, Miller LS, Musabegovic A, Watson JB. Verbal dichotic listening in boys at risk for behavior disorders. *J Am Acad Child Adolesc Psychiatry*. 1997;36:1465-1473.
74. Day R, Wong S. Anomalous perceptual asymmetries for negative emotional stimuli in the psychopath. *J Abnorm Psychol*. 1996;105:648-652.
75. Hillbrand M, Langlan D, Nelson CW, Clark JE. Cerebral lateralization and aggression. *J Offend Rehabil*. 1994;21:81-90.
76. Convit A, Czobor P, Volavka J. Lateralized abnormality in the EEG of persistently violent psychiatric inpatients. *Biol Psychiatry*. 1991;30:363-370.
77. Shumskaya AA. Interhemispheric asymmetry of visual evoked potentials in psychopathies. *Neurosci Behav Physiol*. 1984;14:267-272.
78. Raine A. *The Psychopathology of Crime: Criminal Behavior as a Clinical Disorder*. San Diego, Calif: Academic Press; 1993.
79. Ishikawa SS, Raine A, Lencz T, Bihrle S, LaCasse L. Autonomic stress reactivity and executive functions in successful and unsuccessful criminal psychopaths from the community. *J Abnorm Psychol*. 2001;110:423-432.
80. Brown WS, Paul LK. Cognitive and psychosocial deficits in agenesis of the corpus callosum with normal intelligence. *Cogn Neuropsychiatry*. 2000;5:135-157.
81. Patrick CJ. Emotional processes in psychopathy. In: Raine A, Sanmartin J, eds. *Violence and Psychopathy*. New York, NY: Kluwer/Plenum; 2001:57-78.
82. Field M, Ashton R, White K. Agenesis of the corpus callosum: report of two preschool children and review of the literature. *Dev Med Child Neurol*. 1978;20:47-61.
83. Delis DC, Kramer JH, Kiefner MG. Visuospatial functioning before and after commissurotomy: disconnection in hierarchical processing. *Arch Neurol*. 1988;45: 462-465.
84. Raine A, Yaralian PS, Reynolds C, Venables PH, Mednick SA. Spatial but not verbal cognitive deficits at age 3 years in persistently antisocial individuals. *Dev Psychopathol*. 2002;14:25-44.
85. Moore BDI, Slopis JM, Jackson EF, De Winter AE, Leeds NE. Brain volume in children with neurofibromatosis type 1: relation to neuropsychological status. *Neurology*. 2000;54:914-920.

©2003 American Medical Association. All rights reserved.
Downloaded From: http://jamanetwork.com/ on 05/24/2013