OBSERVATION

Cutaneous Pigmentation After Photosensitivity Induced by Vandetanib Therapy

Heidi H. Kong, MD; Howard A. Fine, MD; Jere B. Stern, MD; Maria L. Chanco Turner, MD

Background: Photosensitivity has been reported in patients who were treated with vandetanib (ZD6474), an inhibitor of epidermal growth factor receptor, vascular endothelial growth factor receptor, and the RET (rearranged during transfection) kinases.

Observations: We describe the occurrence of cutaneous hyperpigmentation after photosensitivity in 2 patients who were treated with vandetanib. The pigmentation patterns were variable within and between patients. Biopsy specimens from different sites revealed variability in Perls and Fontana staining patterns.

Conclusions: These 2 cases highlight the unusual occurrence of cutaneous hyperpigmentation after vandetanib-associated photosensitivity, a reaction that demonstrates that medications are important causes of acquired photosensitivity and hyperpigmentation. Aggressive photoprotection may facilitate the resolution of diffuse hyperpigmentation. Dermatologists should endeavor to identify and report novel cutaneous adverse effects as new targeted therapies are developed.

Arch Dermatol. 2009;145(8):923-925

Drug-induced hyperpigmentation has been associated with the administration of minocycline hydrochloride, amiodarone hydrochloride, heavy metals, and antimalarial agents. With certain medications, photosensitivity may precede the development of cutaneous pigmentation, and the pigmentation may occur in a photodistributed pattern. Drug-induced pigmentation may also develop in areas of prior inflammation. The use of vandetanib (ZD6474, Zactima), an investigational antineoplastic agent targeting epidermal growth factor receptor (EGFR), vascular endothelial growth factor receptor (VEGFR), and RET (rearranged during transfection) kinases, has increased progression-free survival in studies of patients with refractory non–small cell lung cancer[1] and is being evaluated in other solid tumors, including brain, thyroid, breast, prostate, ovarian, and renal cancers. Vandetanib is an orally administered, generally well-tolerated drug; the most common adverse effects include diarrhea, rash, and QTc prolongation. We describe 2 patients with cutaneous photosensitivity and subsequent pigmentation related to treatment with vandetanib, which was administered in a phase 2 study (ClinicalTrials.gov Identifier: NCT00293566) involving patients with recurrent or progressive gliomas at the National Cancer Institute, Bethesda, Maryland.

Author Affiliations: Dermatology Branch (Drs Kong and Turner), Neuro-Oncology Branch (Dr Fine), and Laboratory of Pathology (Dr Stern), Center for Cancer Research, National Cancer Institute, National Institutes of Health, Bethesda, Maryland.

REPORT OF CASES

CASE 1

A 49-year-old white woman underwent vandetanib therapy for a recurrent brain tumor after prior treatments, including surgical resection, carmustine wafer insertion, electron beam irradiation, and temozolomide therapy. Two months after beginning vandetanib therapy, she presented with an eczematous dermatitis on the medial aspect of her thighs, intermittent pustules on the central part of her face, and photosensitivity. The eczematous dermatitis was controlled with the frequent use of bland emollients. The dermatology service was consulted 4 months later for new-onset skin changes. The patient had no history of minocycline or other tetracycline antibiotic use. Physical examination revealed a few pustules on the medial aspect of the cheeks; numerous pinpoint dark blue-gray perifollicular macules on the central part of the face, cheeks, and chin (**Figure 1**A); blue macules along a frontal scalp surgical scar (Figure 1B); and diffuse brownish macular pigmentation over the right cheek. Mucosal surfaces were unaffected. Dermatologic findings were not present in photographs of the patient taken before vandetanib therapy was initiated.

Histologic examination of a biopsy specimen from the diffuse brown macular pigmentation on the cheek demonstrated frequent pigmented macrophages in the

©2009 American Medical Association. All rights reserved.
Downloaded From: http://jamanetwork.com/ on 05/19/2013

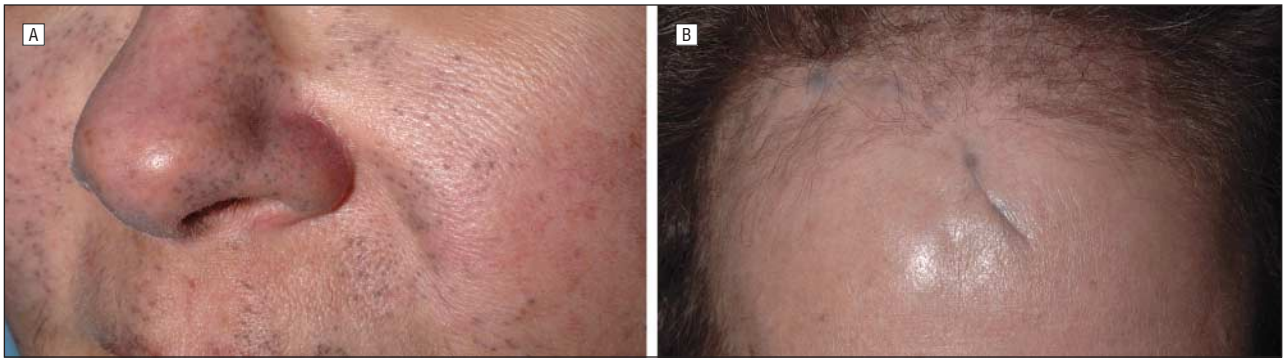

Figure 1. Clinical presentation of a patient receiving vandetanib therapy (case 1). A, Dark blue-gray perifollicular macules over the central part of the face. B, Blue macules scattered along a surgical scar on the forehead.

Figure 2. Clinical presentation of a patient receiving vandetanib therapy (case 2). A, Blue-gray pigmentation on the right side of the neck. B, Dark blue-gray pigmentation in anterior tibial scars.

papillary dermis (positive results on Fontana stain, negative results on Perls stain), while a biopsy specimen from a blue macule on the frontal scalp scar showed dense fibrosis and frequent pigmented macrophages throughout the dermis (positive results on Fontana and Perls stains). The dark perifollicular macules on the face were treated with a cream containing a low-potency steroid, retinoid, and hydroquinone, without improvement. The patient has continued taking vandetanib for more than 3 years; the diffuse brown pigmentation has faded with the use of sunscreen and sun avoidance; and the dark perifollicular macules and blue scar pigmentation persist.

CASE 2

A 59-year-old white woman began vandetanib therapy for progressive anaplastic astrocytoma, which had previously been treated with external beam irradiation and temozolomide therapy. She noted photosensitivity within 1 month, followed by progressive darkening of photoexposed skin. She had undergone no previous minocycline or other tetracycline antibiotic treatment. Initial dermatologic evaluation, which was performed after 10 months of vandetanib therapy, revealed diffuse blue-gray pigmentation of the forehead, nose, neck (**Figure 2**A), and dorsal distal area of the extremities; diffuse brown pigmentation of the cheeks and preauricular area; focal, dark blue-gray pigmentation in anterior tibial scars (Figure 2B); bluish pigmentation of the sclerae; focal brown pigmentation of the right inferior palpebral conjunctiva; and generalized xerosis with eczematous dermatitis in the axillae, antecubital fossae, and popliteal fossae. The diffuse brown and blue-gray pigmentation faded slightly after vandetanib therapy was temporarily discontinued because of unrelated minor skin cancer removal surgery but recurred after the resumption of vandetanib treatment despite strict photoprotection with sunscreens, sun avoidance, and protective clothing. Scleral pigmentation remained unchanged. The eczematous dermatitis was controlled with twice-daily applications of fluocinolone acetonide cream, 0.025%. Three biopsy specimens were obtained from sites with varied clinical morphological features: diffuse blue-gray pigmentation of the right side of the neck (positive results on Fontana and Perls stains), diffuse brown pigmentation in the preauricular area (positive results on Fontana and Perls stains), and a dark-blue macule in an anterior tibia scar (positive results on Fontana and Perls stains).

©2009 American Medical Association. All rights reserved.
Downloaded From: http://jamanetwork.com/ on 05/19/2013

Table. Dermatologic Findings Observed in Our Patients Treated With Vandetanib

Acneiform lesions
Delayed wound healing
Eczematous skin changes
Photosensitivity
Pigmentation
Blue macules of scars (Fontana+, Perls+)
Diffuse blue-gray pigmentation (Fontana+, Perls+)
Diffuse brown pigmentation (Fontana+, Perls+)
Perifollicular dark blue-gray macules (Fontana+, Perls–)

Abbreviations: +, positive stain result; –, negative stain result.

On histologic examination, all 3 biopsy specimens demonstrated frequent pigmented macrophages in the upper dermis, with a mild perivascular lymphocytic infiltrate.

COMMENT

Vandetanib inhibits VEGFR, EGFR, and RET kinases and is undergoing investigation as an antitumor treatment for several types of malignant neoplasms. Both of our patients developed cutaneous pigmentation following photosensitivity after undergoing vandetanib therapy. Although the varied morphological features of vandetanib-associated cutaneous pigmentation may resemble the clinical presentations associated with other drug-induced skin pigmentation, such as that induced by minocycline therapy, our 2 cases demonstrated features that were distinct from other medication-associated pigmentation.

Photosensitivity is a known adverse effect of vandetanib therapy, but hyperpigmentation is uncommon. Thirteen of 18 patients in a phase 1 dose-escalation trial for solid organ tumors developed rashes, including "acne" and photosensitivity.[2] Photosensitivity was demonstrated in 23% of Japanese patients with non–small cell lung cancer in a phase 2 trial; "rash" was observed in 53% of the patients; and dry skin was seen in 21%.[3] We have evaluated and managed cutaneous adverse effects in more than 30 patients who were taking vandetanib. In our experience, the photosensitivity associated with vandetanib therapy most commonly mimics an exaggerated sunburn, but patients have also presented with lichenoid reactions and pseudoporphyria.

Our patients developed cutaneous hyperpigmentation in areas that were subject to photosensitivity. Phototoxicity-induced hyperpigmentation has been associated with the use of a variety of medications, including amiodarone, chlorpromazine hydrochloride, desipramine hydrochloride, and colloidal silver. Pigmentation in our patients developed in photoexposed skin, prior scars, and sclerae. The perifollicular pigmentation on the face of patient 1 occurred in an unusual pattern. Although some of the clinical features were similar to minocycline-induced pigmentation, differences in staining patterns may be attributed to the heterogeneity of each medication.

In the vandetanib-treated patients who have been evaluated in our dermatology clinic, we have observed additional skin changes that may be related to the known targets of vandetanib (**Table**). Our patients have been affected by mild to moderate acneiform pustules and by eczematous skin changes in flexural areas, both known adverse effects of EGFR inhibitors.[4] Anti-VEGFR agents (eg, bevacizumab) can delay wound healing, and animals that were pretreated with vandetanib demonstrated reduced breaking strength of wounded skin,[5] explaining the delayed wound healing seen in a few of our patients.

The pathogenesis of drug-induced skin pigmentation is uncertain, but it may be the result of accumulation of the drug, drug metabolites, melanin, iron, or complexes of the drug and melanin in the skin.[6] For example, staining of the 2 biopsy specimens from prior scars demonstrated the presence of iron, which is likely related to hemosiderin. We recommend that patients who are receiving vandetanib be advised to wear sunscreens and protective clothing and to avoid sun exposure. In our experience, the use of sunscreens alone is not sufficient. In the 2 patients described herein, strict photoprotection improved the diffuse hyperpigmentation but did not affect the focal dark blue-gray pigmentation.

In general, patients with acquired cutaneous pigmentation or photosensitivity will seek the care of dermatologists. We report 2 cases involving unusual cutaneous hyperpigmentation after the occurrence of photosensitivity related to vandetanib therapy. As new targeted therapies are developed and introduced into the clinical setting, dermatologists will continue to play an important role in diagnosing and managing novel cutaneous adverse effects.

Accepted for Publication: January 28, 2009.
Correspondence: Heidi H. Kong, MD, Dermatology Branch, Center for Cancer Research, National Cancer Institute, Bldg 10, Room 12N238, 10 Center Dr, Bethesda, MD 20892 (konghe@mail.nih.gov).
Author Contributions: Drs Kong and Turner had full access to all the data in the study and take responsibility for the integrity of the data and the accuracy of the data analysis. *Study concept and design:* Kong, Stern, and Turner. *Acquisition of data:* Kong. *Analysis and interpretation of data*: Kong, Fine, Stern, and Turner. *Drafting of the manuscript*: Kong. *Critical revision of the manuscript for important intellectual content*: Kong, Fine, Stern, and Turner. *Administrative, technical, or material support*: Kong, Fine, Stern, and Turner. *Study supervision*: Kong, Stern, and Turner.
Financial Disclosure: None reported.
Funding/Support: This study was supported in part by the Intramural Research Program of the Center for Cancer Research, National Cancer Institute, National Institutes of Health.

REFERENCES

1. Heymach JV, Johnson BE, Prager D, et al. Randomized, placebo-controlled phase II study of vandetanib plus docetaxel in previously treated non small-cell lung cancer. *J Clin Oncol.* 2007;25(27):4270-4277.
2. Tamura T, Minami H, Yamada Y, et al. A phase I dose-escalation study of ZD6474 in Japanese patients with solid, malignant tumors. *J Thorac Oncol.* 2006;1(9):1002-1009.
3. Kiura K, Nakagawa K, Shinkai T, et al. A randomized, double-blind, phase IIa dose-finding study of vandetanib (ZD6474) in Japanese patients with non–small cell lung cancer. *J Thorac Oncol.* 2008;3(4):386-393.
4. Robert C, Soria JC, Spatz A, et al. Cutaneous side-effects of kinase inhibitors and blocking antibodies. *Lancet Oncol.* 2005;6(7):491-500.
5. Ko J, Ross J, Awad H, Hurwitz H, Klitzman B. The effects of ZD6474, an inhibitor of VEGF signaling, on cutaneous wound healing in mice. *J Surg Res.* 2005;129(2):251-259.
6. Dereure O. Drug-induced skin pigmentation: epidemiology, diagnosis and treatment. *Am J Clin Dermatol.* 2001;2(4):253-262.

©2009 American Medical Association. All rights reserved.
Downloaded From: http://jamanetwork.com/ on 05/19/2013