ORIGINAL INVESTIGATION

Evaluation of Functional and Malignant Adrenal Incidentalomas

Vanessa W. S. Ng, MRCP; Ronald C. W. Ma, FRCP; Wing-Yee So, MD; Kai Chow Choi, PhD; Alice P. S. Kong, FRCP; Clive S. Cockram, MD; Chun-Chung Chow, FRCP

Background: Adrenal incidentalomas are adrenal masses discovered inadvertently. We undertook this study to review the clinical characteristics of patients with adrenal incidentalomas who presented to a tertiary endocrine center in Hong Kong.

Methods: Retrospective review of all 139 cases of adrenal incidentalomas that were referred to the Endocrine Centre of the Prince of Wales Hospital between June 1, 2000, and May 31, 2007. We reviewed detailed patient history, physical examination findings, and symptoms and signs related to hormonal hypersecretion or malignant neoplasm and recorded clinical indications for performing diagnostic radiological imaging.

Results: Sixty-one patients (43.9%) had nonfunctional benign adrenal adenomas, 52 (37.4%) had functional lesions, 15 (10.8%) had malignant adrenal lesions, and the remaining 11 (7.9%) had varying adrenal disease. Among those with functional lesions, 27 (19.4%) had lesions that secreted excess cortisol; 12 (8.6%), lesions that secreted aldosterone; 12 (8.6%), lesions that secreted excess catecholamines; and 1 (0.7%), a lesion that demonstrated excess secretion of cortisol and aldosterone. Only 5 of the 27 patients with cortisol-secreting adrenal incidentalomas had symptoms or signs of excess cortisol levels at presentation.

Conclusions: Adrenal incidentaloma is a commonly encountered clinical problem. Functional or primary malignant adrenal incidentalomas can be detected at an earlier stage during hormonal and radiological evaluations, which provides an opportunity for further management.

Arch Intern Med. 2010;170(22):2017-2020

Author Affiliations:
Department of Medicine and Therapeutics, Prince of Wales Hospital, Chinese University of Hong Kong (Drs Ng, Ma, So, Kong, Cockram, and Chow), and Centre for Epidemiology and Biostatistics, School of Public Health and Primary Care (Dr Choi), Chinese University of Hong Kong, Hong Kong.

ADRENAL INCIDENTALOMAS are adrenal masses discovered inadvertently when radiological imaging is performed for reasons other than suspected adrenal disease.[1,2] Most adrenal incidentalomas are benign and nonfunctional. However, functional adrenal lesions secreting excess adrenal hormones, such as cortisol, aldosterone, catecholamine, sex hormones, or a combination of adrenal hormones, account for a significant proportion of cases, with increased morbidity if left untreated. Malignant adrenal lesions are uncommon and include primary adrenal cancers, adrenal metastases, or other rare malignant neoplasms. Although primary adrenal cancer is rare among the general population, early intervention when the carcinoma is small and still confined to the adrenal bed offers the best prognosis. It is therefore important to assess the functional status and malignant potential of every incidentally discovered adrenal lesion. We undertook this study to review the clinical characteristics of patients with adrenal incidentalomas who presented to a tertiary endocrine center in Hong Kong.

METHODS

STUDY PATIENTS

We conducted a retrospective review of all cases of adrenal incidentalomas that were referred to the Endocrine Centre of the Prince of Wales Hospital between June 1, 2000, and May 31, 2007. The Endocrine Centre is a tertiary referral center for adult patients (18 years or older) with endocrine disorders.

We included 139 consecutive patients with adrenal incidentalomas. All patients were ethnically Chinese. We reviewed detailed patient history and physical examination findings, including age, sex, body mass index, blood pressure, presence of hypertension and diabetes mellitus, and symptoms and signs related to hormonal hypersecretion or malignant neoplasm. Clinical indications for performing the diagnostic radiological imaging were recorded. All adrenal incidentalomas that were first detected by ultrasonography would subsequently be confirmed by computed tomography or magnetic resonance imaging.

©2010 American Medical Association. All rights reserved.

Downloaded From: http://jamanetwork.com/ on 05/19/2013

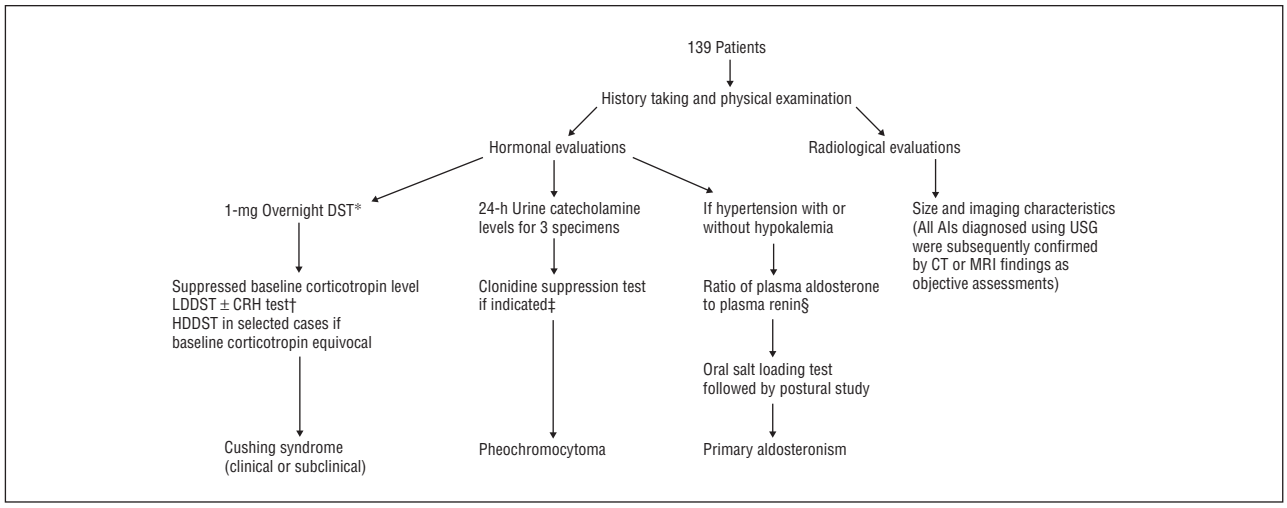

Figure 1. Evaluations for the 139 patients with adrenal incidentalomas. AIs indicates adrenal incidentalomas; CRH, corticotropin-releasing hormone; CT, computed tomography; DST, dexamethasone suppression test; HDDST, high-dose DST; LDDST, low-dose DST; MRI, magnetic resonance imaging; USG, ultrasonography. *An 8 AM plasma cortisol concentration of more than 1.8 μg/dL (to convert to nanomoles per liter, multiply by 27.588) under the 1-mg overnight DST is regarded as a positive test result. †Under the combined LDDST and CRH injection test, a plasma cortisol concentration of more than 1.4 μg/dL measured 15 minutes after the administration of CRH is defined as a positive diagnostic test result for Cushing syndrome. ‡Only performed in selected patients with borderline elevated or equivocal 24-hour urinary catecholamine levels. An overnight clonidine suppression test was used in this study. Patients received oral clonidine hydrochloride, 0.3 mg, immediately before sleep at 9 PM. Urinary catecholamine levels while awake (9 AM to 9 PM, before clonidine administration) and during sleep (9 PM to 9 AM, after clonidine administration) were measured. A ratio of the urinary level of noradrenaline to creatinine of less than 60 and a ratio of the urinary level of adrenaline to creatinine of less than 20 after sleep and clonidine administration are regarded as negative test results. §An ambulatory 9 AM ratio of the plasma aldosterone concentration (in nanograms per deciliter) to plasma renin activity (in nanograms per milliliter per hour) of 20 or higher with an aldosterone concentration of at least 15 ng/dL (to convert to picomoles per liter, multiply by 27.74) is defined as a positive screening result for primary aldosteronism in this study.

Evaluations for hormonal hypersecretion and the malignant potential of the incidentalomas were performed according to a standard protocol (**Figure 1**). Patients with benign nonfunctional incidentalomas were followed up every 6 to 12 months with repeated hormonal and radiological evaluations to assess any changes in the size and clinical characteristics of the incidentalomas over time.

STATISTICAL ANALYSIS

Data are presented as mean (SD) or number (percentage) of patients unless stated otherwise. Lesion size was log-transformed to correct for skewness in distribution. Univariate comparisons were made using the unpaired *t* test, Mann-Whitney test, χ^2 test, or Fisher exact test as appropriate. Statistical analyses were performed using commercially available software (SPSS, version 14.0; SPSS Inc, Chicago, Illinois).

RESULTS

We recruited 139 patients (53 men and 86 women) in this study. Most of the adrenal lesions were detected by computed tomography (79 lesions [56.8%]), followed by ultrasonography (54 [38.8%]) and magnetic resonance imaging (6 [4.3%]). The mean age of the patients was 57.4 (14.9) (range, 25.2-85.9) years. Nineteen patients were younger than 40 years, 53 were aged 40 to 60 years, 62 were aged 61 to 80 years, and 5 were 81 years or older. Sixty-six patients (47.5%) had adrenal incidentalomas located on the left side, whereas 18 (12.9%) had bilateral adrenal lesions. The median size of the incidentalomas was 2.5 (range, 0.8-19.8) cm; most ranged from 1.0 to 3.0 cm (**Figure 2**).

There were no statistically significant differences in baseline clinical characteristics between male and female patients in terms of age, presence of hypertension, diabetes mellitus, lateralization, or size of the adrenal lesions.

Sixty-one patients (43.9%) had nonfunctional benign adrenal adenomas, whereas 52 (37.4%) had functional lesions. Among these 52 patients, 27 (19.4%) had lesions that secreted excess cortisol, whereas 12 (8.6%) had lesions that secreted aldosterone, another 12 (8.6%) had lesions that secreted excess catecholamines, and 1 (0.7%) had a lesion that demonstrated excess secretion of cortisol and aldosterone. Only 5 of the 27 patients with cortisol-secreting adrenal incidentalomas had symptoms or signs of excess cortisol levels at presentation. Five of the 12 patients with pheochromocytomas had hypertension and 6 were asymptomatic at the time of diagnosis. Their pheochromocytomas were all confirmed by hormonal evaluation results and histological confirmation after tumor resection.

Fifteen patients had malignant adrenal lesions based on radiological characteristics and histological diagnoses. Six patients had primary adrenal carcinoma, 8 had adrenal metastases, and 1 had adrenal lymphoma. The size of the primary adrenal carcinomas ranged from 5.8 to 18.0 cm, whereas the size of the adrenal metastases ranged from 1.9 to 8.0 cm. For the patient with adrenal lymphoma, her adrenal lesion measured 6.3 cm.

For the 6 patients with primary adrenal cancer, 4 had nonfunctional adrenal carcinoma and 2 had cortisol-secreting adrenal cancer. Three patients developed lung or liver metastases and died 3 to 22 months after their first radiological imaging. One patient died of unrelated problems 17 months after adrenalectomy. Two patients had stage I primary adrenal cancer. They have been free of tumor recurrence for at least 5 years after adrenalectomy and at present undergo regular surveillance.

©2010 American Medical Association. All rights reserved.

Downloaded From: http://jamanetwork.com/ on 05/19/2013

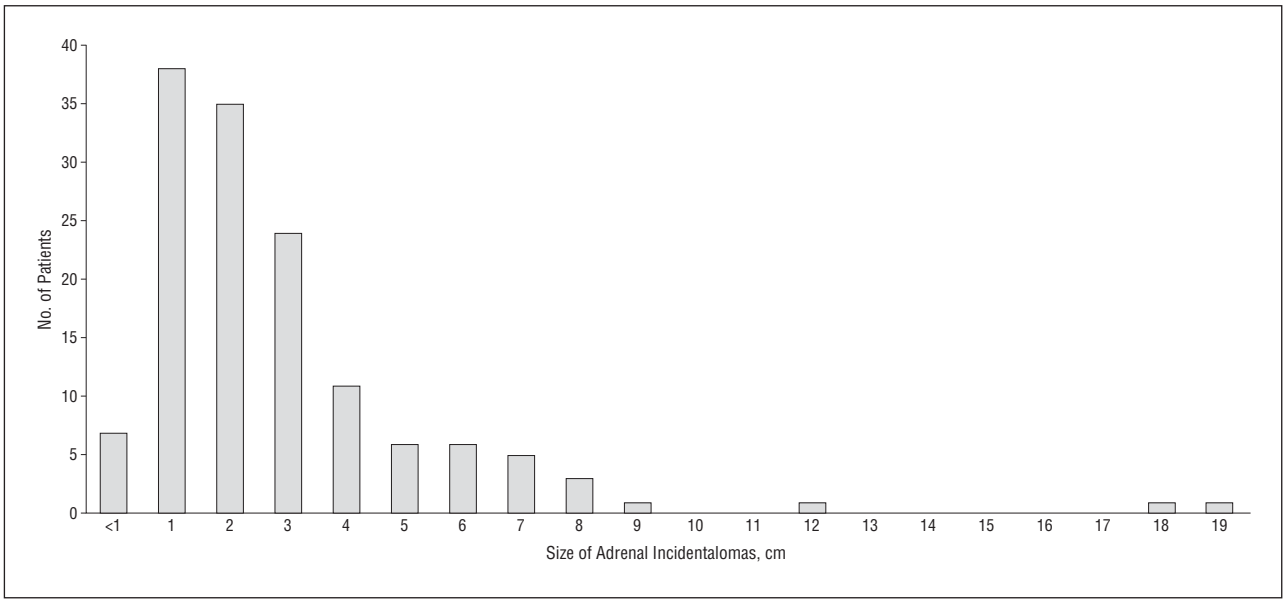

Figure 2. Size of the adrenal incidentalomas at the time of diagnosis. Seven patients had adrenal incidentalomas measuring less than 1 cm, including 3 with 0.8-cm lesions and 4 with 0.9-cm lesions.

For the remaining 11 patients, 2 had Cushing disease presenting as adrenal incidentaloma; 1, nonclassical congenital adrenal hyperplasia; 2, adrenal cysts; 3, adrenal myelolipoma; and 3, adrenal hemorrhage.

The **Table** summarizes the various clinical indications for performing the first radiological assessment, which led to the detection of these adrenal incidentalomas.

None of the benign nonfunctional adrenal incidentalomas became functional or malignant during a median follow-up of 30.2 (interquartile range, 18.2-52.1) months. Among these 61 patients, 2 had adrenal lesions decrease in size and 1 had an increase by more than 1 cm.

Table. Clinical Indications for Performing the First Radiological Assessment Leading to Detection of Adrenal Incidentalomas

Indication	No. (%) of Patients[a]
Liver/biliary tract abnormality	24 (17.3)
Renal/urinary tract abnormality	24 (17.3)
Abdominal pain	30 (21.6)
Abnormal chest radiography finding/chest symptoms	22 (15.8)
Vascular structures (eg, aortic dissection/aortic aneurysm)	14 (10.1)
Health check	7 (5.0)
Road traffic accident	4 (2.9)
Intra-abdominal abscess	6 (4.3)
Other	8 (5.8)
Total	**139** (100)

[a] Percentages may not total 100 because of rounding.

COMMENT

Adrenal incidentaloma is not rare. It has a prevalence of 3% to 4% among abdominal computed tomography series and is age dependent.[3,4] Adrenal incidentaloma is uncommon in persons younger than 30 years, with an estimated prevalence of 0.2%. However, its prevalence increases to 7% in persons 70 years or older.[2-4] In our study, most of the patients were in the fourth to eighth decades of life, with a female predominance. This pattern of age distribution reflects the greater number of radiological investigations carried out in older people and the prevalence of adrenal nodules that increases with age. The female predominance probably reflects the sex distribution of patients undergoing imaging procedures in Hong Kong because no sex differences in prevalence were found in a previous autopsy series.[3]

Functional adrenal incidentalomas accounted for 37.4% in our cohort. Cortisol-secreting adenoma is the most common functional lesion. Patients with subclinical Cushing syndrome have autonomous cortisol-secreting adenomas but lack the typical signs and symptoms of overt Cushing syndrome.[5,6] However, they may have the detrimental effects of subtle, continuous, endogenous, excess cortisol levels, including insulin resistance, diabetes mellitus, hypertension, osteoporosis, obesity, and thrombotic complications.[7-10] Among our patients with subclinical Cushing syndrome and hypertension, diabetes, or obesity, successful surgical treatment of the syndrome improved their blood pressure and diabetic control together with weight reduction.

Primary aldosteronism is the most common cause of secondary hypertension.[11,12] It accounts for up to 12% of all hypertensive patients.[13,14] In our cohort, primary aldosteronism accounted for 8.6% of the cases. For patients with aldosterone-producing adenomas, successful surgical removal resulted in normalization of hypokalemia and improvement in blood pressure control. Moreover, some of these patients could stop all their antihypertensive medication therapy postoperatively because their blood pressure normalized. These findings highlighted the importance of ruling out primary aldosteronism, a treatable cause

©2010 American Medical Association. All rights reserved.

Downloaded From: http://jamanetwork.com/ on 05/19/2013

of secondary hypertension, in every hypertensive patient with adrenal incidentaloma.

In this study, 12 patients were confirmed to have pheochromocytomas. Seven patients were normotensive and 6 were asymptomatic. Clinically silent pheochromocytomas could be a lethal disorder with an unpredictable course.[15,16] Lethal paroxysms and perioperative mortality can be as high as 50% for patients with unrecognized pheochromocytoma.[16,17] This highlights the need to exclude pheochromocytomas in every patient with adrenal incidentaloma, even if the patient is normotensive or asymptomatic and especially before contemplating adrenal biopsy or surgery.

Primary adrenal cancer and adrenal metastases are the 2 most common adrenal malignant neoplasms. Although primary adrenal cancer is extremely rare, with an incidence of 1 to 2 cases per 1 million persons,[18] it is associated with a high mortality rate and a very poor prognosis.

With the common use of radiological investigations, an increasing percentage of primary adrenal cancer is now discovered as incidentaloma.[5,19] Early recognition and surgical resection provide the only chance for cure and long-term survival in patients with primary adrenal cancers, as evidenced by the 2 patients in our study who had stage I primary adrenal cancer.

Our study has 2 major limitations. First, the sample size is relatively small, and the patients were recruited from a tertiary referral center. These limitations may explain why more functional and malignant adrenal incidentalomas were detected in this cohort compared with the general population because our patients included those with more complicated cases and multiple comorbidities. However, clinical series from various tertiary referral centers worldwide echo our findings that functional and malignant adrenal incidentalomas are not uncommon.[3,4]

In conclusion, adrenal incidentaloma is a commonly encountered clinical problem. Functional or primary malignant adrenal incidentalomas can be detected at an earlier stage during hormonal and radiological evaluations, which provides an opportunity for further management.

Accepted for Publication: June 7, 2010.
Correspondence: Ronald C. W. Ma, FRCP, Department of Medicine and Therapeutics, Chinese University of Hong Kong, Prince of Wales Hospital, 9/F Clinical Science Bldg, Shatin, Hong Kong (rcwma@cuhk.edu.hk).
Author Contributions: *Study concept and design:* Ng, Ma, and Chow. *Acquisition of data:* Ng, Ma, So, Kong, Cockram, and Chow. *Analysis and interpretation of data:* Ng, Ma, Choi, and Cockram. *Drafting of the manuscript:* Ng and Ma. *Critical revision of the manuscript for important intellectual content:* Ma, So, Choi, Kong, Cockram, and Chow. *Statistical analysis:* Choi. *Administrative, technical, and material support:* Ng, Ma, and So. *Study supervision:* Ma, Kong, Cockram, and Chow.
Financial Disclosure: None reported.
Additional Contributions: Linda W. M. Leung, Department of Medicine and Therapeutics, Prince of Wales Hospital, assisted in retrieving patients' records.

REFERENCES

1. Gross MD, Shapiro B. Clinical review 50: clinically silent adrenal masses. *J Clin Endocrinol Metab.* 1993;77(4):885-888.
2. Grumbach MM, Biller BM, Braunstein GD, et al. Management of the clinically inapparent adrenal mass ("incidentaloma"). *Ann Intern Med.* 2003;138(5):424-429.
3. Kloos RT, Gross MD, Francis IR, Korobkin M, Shapiro B. Incidentally discovered adrenal masses. *Endocr Rev.* 1995;16(4):460-484.
4. Young WF Jr. Management approaches to adrenal incidentalomas: a view from Rochester, Minnesota. *Endocrinol Metab Clin North Am.* 2000;29(1):159-185.
5. Mantero F, Terzolo M, Arnaldi G, et al; Study Group on Adrenal Tumors of the Italian Society of Endocrinology. A survey on adrenal incidentaloma in Italy. *J Clin Endocrinol Metab.* 2000;85(2):637-644.
6. Terzolo M, Reimondo G, Bovio S, Angeli A. Subclinical Cushing's syndrome. *Pituitary.* 2004;7(4):217-223.
7. Rossi R, Tauchmanova L, Luciano A, et al. Subclinical Cushing's syndrome in patients with adrenal incidentaloma: clinical and biochemical features. *J Clin Endocrinol Metab.* 2000;85(4):1440-1448.
8. Terzolo M, Pia A, Alì A, et al. Adrenal incidentaloma: a new cause of the metabolic syndrome? *J Clin Endocrinol Metab.* 2002;87(3):998-1003.
9. Torlontano M, Chiodini I, Pileri M, et al. Altered bone mass and turnover in female patients with adrenal incidentaloma: the effect of subclinical hypercortisolism. *J Clin Endocrinol Metab.* 1999;84(7):2381-2385.
10. Tauchmanovà L, Rossi R, Biondi B, et al. Patients with subclinical Cushing's syndrome due to adrenal adenoma have increased cardiovascular risk. *J Clin Endocrinol Metab.* 2002;87(11):4872-4878.
11. Fardella CE, Mosso L, Gómez-Sánchez C, et al. Primary hyperaldosteronism in essential hypertensives: prevalence, biochemical profile, and molecular biology. *J Clin Endocrinol Metab.* 2000;85(5):1863-1867.
12. Schwartz GL, Chapman AB, Boerwinkle E, Kisabeth RM, Turner ST. Screening for primary aldosteronism: implications of an increased plasma aldosterone/renin ratio. *Clin Chem.* 2002;48(11):1919-1923.
13. Rossi GP, Bernini G, Caliumi C, et al; PAPY Study Investigators. A prospective study of the prevalence of primary aldosteronism in 1125 hypertensive patients. *J Am Coll Cardiol.* 2006;48(11):2293-2300.
14. Gordon RD, Ziesak MD, Tunny TJ, Stowasser M, Klemm SA. Evidence that primary aldosteronism may not be uncommon: 12% incidence among antihypertensive drug trial volunteers. *Clin Exp Pharmacol Physiol.* 1993;20(5):296-298.
15. Kudva YC, Young WF Jr, Thompson GB, Grant CS, van Heerden JA. Adrenal incidentaloma: an important component of the clinical presentation spectrum of benign sporadic adrenal pheochromocytoma. *Endocrinologist.* 1999;9(2):77-80.
16. Krane NK. Clinically unsuspected pheochromocytomas: experience at Henry Ford Hospital and a review of the literature. *Arch Intern Med.* 1986;146(1):54-57.
17. Sutton MG, Sheps SG, Lie JT. Prevalence of clinically unsuspected pheochromocytoma: review of a 50-year autopsy series. *Mayo Clin Proc.* 1981;56(6):354-360.
18. Allolio B, Fassnacht M. Clinical review: adrenocortical carcinoma: clinical update. *J Clin Endocrinol Metab.* 2006;91(6):2027-2037.
19. Mansmann G, Lau J, Balk E, Rothberg M, Miyachi Y, Bornstein SR. The clinically inapparent adrenal mass: update in diagnosis and management. *Endocr Rev.* 2004;25(2):309-340.

©2010 American Medical Association. All rights reserved.

Downloaded From: http://jamanetwork.com/ on 05/19/2013