OBSERVATION

Neuropathy in a Human Without the *PMP22* Gene

Mario Andre Saporta, MD, PhD; Istvan Katona, MD; Xuebao Zhang, PhD; Helen P. Roper, MD; Louise McClelland, BSc; Fiona Macdonald, PhD; Louise Brueton, MD; Julian Blake, MD; Ueli Suter, PhD; Mary M. Reilly, MD; Michael E. Shy, MD; Jun Li, MD, PhD

Background: Haploinsufficiency of *PMP22* causes hereditary neuropathy with liability to pressure palsies. However, the biological functions of the PMP22 protein in humans have largely been unexplored owing to the absence of patients with PMP22-null mutations.

Objective: To investigate the function of PMP22 in the peripheral nervous system by studying a boy without the *PMP22* gene and mice without the *Pmp22* gene.

Design: The clinical and pathological features of a patient with a *PMP22* homozygous deletion are compared with those of *Pmp22*-null mice.

Setting: Clinical evaluation was performed at tertiary hospitals in the United Kingdom. Molecular diagnosis was performed at the West Midlands Regional Genetics Laboratory. Immunohistochemistry and electron microscopy analyses were conducted at Wayne State University, Detroit, Michigan. Analysis of the *Pmp22*+/– and null mice was performed at Vanderbilt University, Nashville, Tennessee.

Participant: A 7-year-old boy without the *PMP22* gene.

Results: Motor and sensory deficits in the proband were nonlength-dependent. Weakness was found in cranial muscles but not in the limbs. Large fiber sensory modalities were profoundly abnormal, which started prior to the maturation of myelin. This is in line with the temporal pattern of *PMP22* expression predominantly in cranial motor neurons and dorsal root ganglia during embryonic development, becoming undetectable in adulthood. Moreover, there were conspicuous maturation defects of myelinating Schwann cells; these defects were more significant in motor nerve fibers than in sensory nerve fibers.

Conclusions: Taken together, the data suggest that PMP22 is important for the normal function of neurons that express PMP22 during early development, such as cranial motor neurons and spinal sensory neurons. Moreover, PMP22 deficiency differentially affects myelination between motor and sensory nerves, which may have contributed to the unique clinical phenotype in the patient with an absence of PMP22.

Arch Neurol. 2011;68(6):814-821

Peripheral myelin protein 22 (PMP22) is encoded by the *PMP22* gene within the DNA segment of human chromosome 17p11.2. PMP22 is most abundantly expressed in the myelinating Schwann cells of peripheral nerves,[1] but its function is poorly understood.

During development, the transcription of *PMP22* in motor neurons shows a rostral-caudal pattern, with cranial motor nuclei first expressing the protein embryonically and with spinal motor neurons expressing it after birth. In contrast, *PMP22* transiently expresses in sensory neurons of cranial nuclei and dorsal root ganglia at embryonic stages, but the transcripts become undetectable in young adults.[2,3] The significance of this expression difference between sensory and motor neurons is unknown.

PMP22 is clinically important. Overexpression of *PMP22* causes Charcot-Marie-Tooth disease type 1A (CMT1A), the most common heritable neuropathy afflicting 1 in 5000 people. Heterozygous deletion of the *PMP22* causes a different disease, hereditary neuropathy with liability to pressure palsy (HNPP), which presents with transient, focal episodes of weakness or sensory loss. These HNPP nerves show focal excessive myelin folds (ie, the tomacula).[4] *Pmp22*-deficient (*Pmp22*+/–) mice recapitulate many abnormalities found in patients with HNPP, including the tomacula.[5] Although those findings are important, to our knowledge, the functional consequences of having no PMP22 have not been evaluated to date because no human patient with total absence of PMP22 has been described. We have evaluated

Author Affiliations are listed at the end of this article.

©2011 American Medical Association. All rights reserved.
Downloaded From: http://jamanetwork.com/ on 05/20/2013

Table 1. Primary Antibody List

Antibody	Manufacturer	Species Raised	Specific Antigen	Type	Titers
MBP	Ultraclone Ltd (Yarmouth, England)	Mouse	Purified MBP from human brain	Monoclonal IgG1	1:800
PGP9.5	AbD Serotec (Oxfordshire, England)	Rabbit	Human PGP9.5 from brain	Polyclonal IgG	1:1000
Lamin B (M-20) (catalog no. SC-6217)	Santa Cruz Biotechnology, Inc (Santa Cruz, CA)	Goat	C terminus of lamin B1 of mouse origin	Polyclonal IgG	1:100
PERP antibody (ab3945)	Abcam (Cambridge, England)	Rabbit	Amino acids 37-50 of mouse PERP	Polyclonal IgG	1:50

Abbreviations: MBP, myelin basic protein; PGP9.5, protein gene product 9.5.

such a patient, including his skin biopsy, and compared the results of our findings with those in *Pmp22*–/– mice.

METHODS

MOLECULAR ANALYSIS

A multiplex ligation-dependent probe amplification (MLPA) assay was used to characterize the segment deleted in chromosome 17p. A MLPA kit (SALSA P033B; MRC-Holland, Amsterdam, Netherlands) was used according to the manufacturer's protocol.[6] This kit contains 11 probes specific for sequences present in the CMT1A/HNPP region. There were 22 control probes interspersed throughout the genome, which were used for relative quantification purposes. More detailed information on probes, genes, and sequences can be found at http://www.mlpa.com/WebForms/WebFormMain.aspx.

IMMUNOHISTOCHEMISTRY STUDY ON HUMAN SKIN BIOPSIES AND MOUSE TISSUES

This technique has been described before.[7] In brief, skin biopsies were fixed in 4% paraformaldehyde for 30 minutes to 12 hours, embedded in optimal cutting temperature medium, and cut vertically (10- to 60-μm thickness). The sections were incubated with the primary antibodies (**Table 1**) overnight at 4°C, followed by incubation with the secondary antibodies overnight, and mounted onto the slides on the third day. The slides were examined using a laser confocal microscope (D-Eclipse C1 confocal system; Nikon Instruments Inc, Melville, New York).

ELECTRON MICROSCOPY

Skin biopsies and mouse tissue were fixed in 2.5% glutaraldehyde overnight, osmicated for 2 hours in 1% osmium tetroxide, dehydrated, and then embedded in epoxy resin. Tissue blocks were sectioned, trimmed, and examined by electron microscopy (Zeiss EM900; Carl Zeiss AG, Oberkochen, Germany).[7]

PMP22-DEFICIENT MICE AND GENOTYPING

The *Pmp22*–/– mouse was generated by using a homologous recombination technique to inactivate the *Pmp22* gene.[5] A breeding colony is maintained at the Vanderbilt University animal facility. The Animal Investigational Committee at the institution has approved the use of animals in our study. Genotypes were determined as described in previous publications.[5]

RESULTS

CLINICAL EVALUATION

The proband is a boy aged 7 years and 10 months who was first noticed to be floppy at the age of 4 months during a hospitalization for a nonrelated condition. He did not walk until 3 years of age. When he did walk, he walked with an unsteady gait. Currently, he requires a walker to take more than a few steps. His parents opine that he requires the walker because of unsteadiness rather than weakness. His parents first noted that he had difficulty using his fingers when he began school at 4 years of age. His grip was weak, and he began dropping objects. He currently cannot fasten buttons or close zippers, but he can write. He states that he has normal sensation in his feet, although he complains of occasional numbness in both hands.

During a neurological examination, he could ambulate with an ataxic, narrow-based gait, if his father held both of his hands. With someone holding his hands for balance, he could stand up on both his heels and his toes very easily. Cranial nerve testing revealed bilateral facial weakness with Bell signs confirming the lower motor neuron basis for this weakness. Mild bilateral ptosis was present. He had no visible muscle atrophy in the upper or lower extremities; for example, he had good bulk of extensor digitorum brevis muscles. He had very mild hammer toes but no overt pes cavus. His strength was full to confrontation in the proximal and distal muscles of both his upper and his lower extremities. He cooperated well with his sensory examination. There was bilateral, symmetric reduction of pinprick in the fingers and in the toes. In the upper limbs, vibration was normal, but in the lower limbs, it was reduced to the costal margins. In the upper limbs, joint position sense was normal, but in the lower limbs, it was reduced up to his ankles bilaterally. He had mild pseudoathetosis in both hands. Deep tendon reflexes were unobtainable.

Because of the patient's age, only a limited electrodiagnostic study was performed that revealed very prolonged distal motor latencies and a slow peroneal motor conduction velocity. The only sensory nerve tested was

©2011 American Medical Association. All rights reserved.
Downloaded From: http://jamanetwork.com/ on 05/20/2013

the sural nerve, and its response was unobtainable (**Table 2**). The proband's parents are first cousins, and both have symptoms and neurophysiologic findings consistent with HNPP (Table 2).[8]

Table 2. Neurophysiologic Findings in the Proband and His Parents

Parameter	Father	Mother	Proband
Median DML, ms	6.0	5.7	11.2
Ulnar DML, ms	3.8	4.6	NP
Peroneal DML, ms	7.1	8.0	5.8
Tibial DML, ms	7.0	6.7	10.7
Ulnar CV below-elbow, m/s	45.7	44.4	NP
Ulnar CV above-elbow, m/s	36.7	20.2	NP
Peroneal CV below-knee, m/s	39.0	37.0	12.6
Peroneal CV above-knee, m/s	40.0	40.6	NP

Abbreviations: CV, conduction velocity; DML, distal motor latency; NP, not performed.

MOLECULAR DIAGNOSIS

The results of the MLPA assay of the proband's DNA (**Figure 1**) revealed a homozygous deletion of a segment of at least 1.1 megabase (Mb) in chromosome 17p. This segment included all 5 exons of the *PMP22* gene, and the *TEKT3* and *FLJ* genes flanking the *PMP22* gene. Both copies of the *COX10* gene were spared. Analysis of the MLPA assay results of the proband parents' DNA revealed a heterozygous deletion of the same segment in both parents, confirming the diagnosis of HNPP.

ANALYSIS OF HUMAN SKIN BIOPSY SAMPLES

Glabrous skin biopsy samples were obtained from the index finger of the proband, as we have previously described.[7] The immunohistochemistry of the biopsy

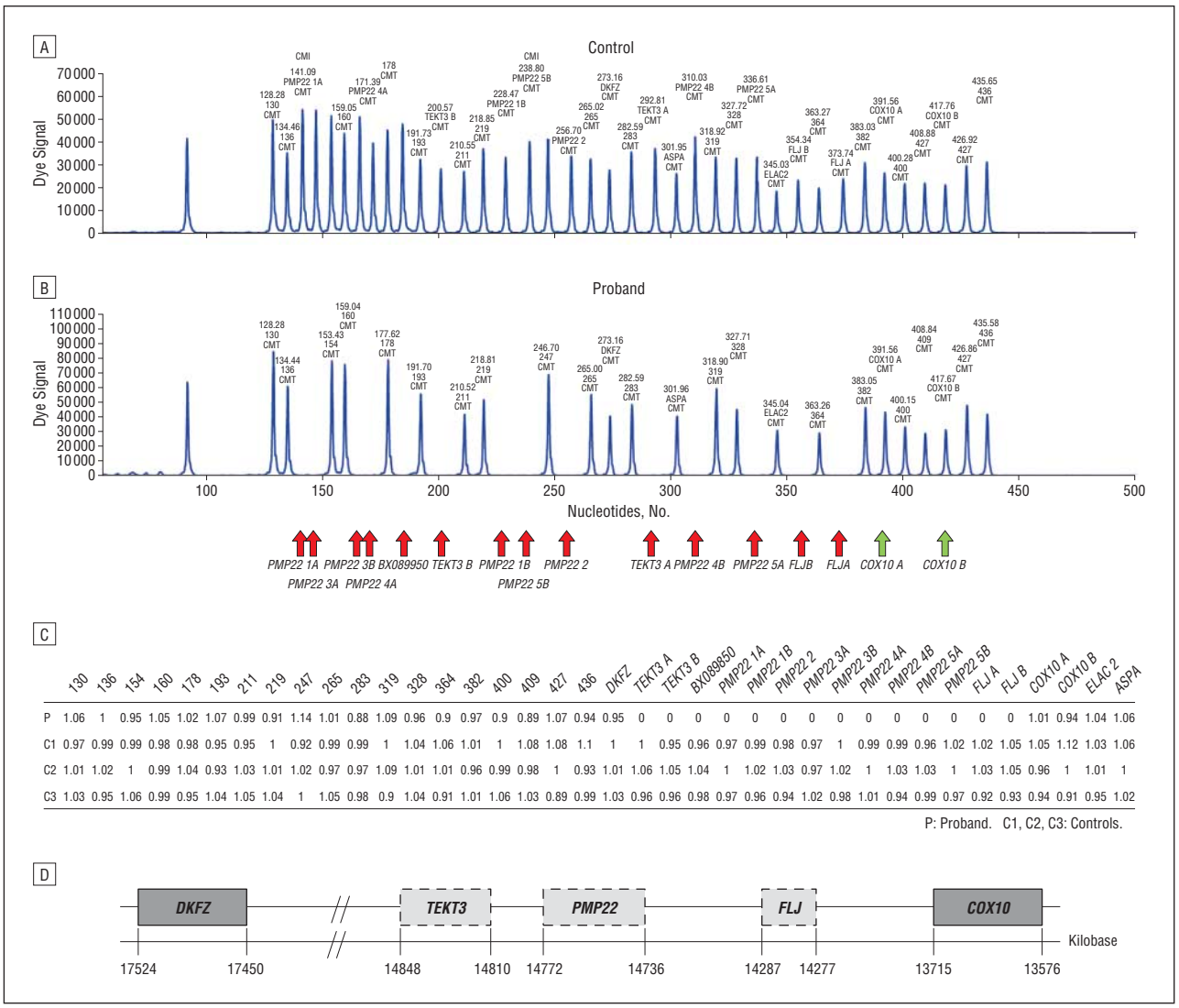

Figure 1. Results of the multiplex ligation-dependent probe amplification (MLPA) assay of the proband's DNA. *PMP22*, but not *COX10*, is absent in both alleles of the proband. MLPA analysis of a control (A) and the proband (B) revealed the absence of peaks corresponding to all 5 exons of *PMP22* (red arrows) in the proband. Peaks corresponding to *TEKT3*, *BX089850*, and *FLJ* were also absent in the proband, but *COX10* was retained in both alleles (green arrows). C, Ratios of the analyzed peaks (relative peak areas) compared with the normal controls. D, Schematic of the segment of chromosome 17p deleted in the proband.

©2011 American Medical Association. All rights reserved.
Downloaded From: http://jamanetwork.com/ on 05/20/2013

samples with antibodies against myelin basic protein and protein gene product 9.5 revealed a profound reduction in myelinated fiber density. In the few fibers positive for myelin basic protein staining, Schwann cells were surrounding axons positive for protein gene product 9.5 but did not form well-organized internodes or compact myelin (**Figure 2**A and B). In contrast, Schwann cells from control biopsy samples formed regular internodes, ensheathed by compact myelin (Figure 2C) as previously reported.[9] We next performed electron microscopy. We were unable to identify any compact myelin; rather, there were only Schwann-cell processes loosely wrapped around a space where the axon presumably has degenerated. In many cases, these Schwann cells form "onion bulb"–like structures, but axons usually were absent (**Figure 3**). Taken together, these changes were consistent with axonal loss. Schwann cells around degenerated axons were proliferative and were unable to form myelinating internodes along regenerating axons.

An additional finding was a striking redundancy of the basal lamina with several loose layers or empty pockets of the lamina around or nearby Schwann cells (Figure 3). Similar findings were also described in a recent model of *Pmp22*-null mice.[10] As with our patient, mouse skin biopsy samples showed a few myelinated nerve fibers (Figure 3). The redundancy of basal lamina was prominent in the biopsy samples from the mice (Figure 3).

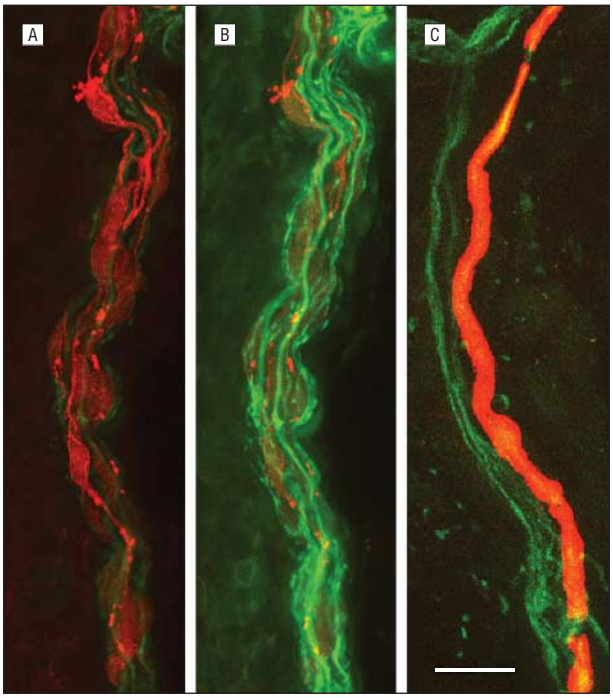

Figure 2. Abnormal internodes in skin biopsy samples from the 7-year-old patient without the *PMP22* gene. A and B, Immunohistochemistry using myelin basic protein (MBP) (red) and protein gene product 9.5 (PGP9.5) (green) antibodies reveals multiple MBP-positive Schwann cells (red) surrounding axons (green) without forming internodes in dermal myelinated fibers in the patient's skin sample. A, Red channel gain was artificially increased to highlight MBP-positive Schwann cells. B, Green channel gain was artificially increased to highlight PGP9.5-positive axons. C, A control skin biopsy sample discloses normal internode of dermal myelinated fibers flanked by MBP-negative regions corresponding to nodes of Ranvier (scale bar, 10 um).

DIFFERENTIAL EFFECT OF MYELINATION BETWEEN MOTOR AND SENSORY NERVE FIBERS IN *Pmp22*-NULL MICE

Because of the predominance of proprioception loss in our patient, we wondered whether PMP22 might be particularly important in sensory rather than motor myelinated nerve fibers. Our previous study[11] demonstrated that axonal loss affects both dorsal and ventral roots equally in *Pmp22*–/– mice at the ages of 10 to 13 months. However, a differential effect between sensory and motor nerves could still be present in younger mice. We analyzed both dorsal and ventral roots of 3 *Pmp22*–/– and 3 wild-type animals. There were a large number of immature Schwann cells that had established a 1:1 ratio with axons but did not form myelin in *Pmp22*–/– mice (**Table 3** and **Figure 4**). The immature Schwann cells failed to produce tomacula because tomacula can only form in myelinated internodes. This defect appeared particularly prominent in the ventral roots. All 3 mice showed abundant immature Schwann cells in the ventral roots. In the dorsal roots, the Schwann cells were either fully differentiated or differentiated the majority of the time. These findings are consistent with our previous observation.[11] In addition, we noticed a small group of swollen axons in the roots, consistent with the axonal loss shown in skin biopsy samples. Overall, as documented in our previous publication,[11] myelinated nerve fibers appeared significantly reduced. Taken together, the data suggest that PMP22 deficiency delays maturation of Schwann cells predominantly in motor nerve fibers.

Because PMP22 expresses in spinal sensory and motor neurons during early development, we questioned whether PMP22 deficiency affects the survival of these neurons. Terminal deoxynucleotidyl transferase–mediated biotin–deoxyuridine triphosphate nick-end labeling (TUNEL) staining was performed in mouse spinal cords and dorsal root ganglia. There was no increase of apoptosis. The mean (SD) number of TUNEL-positive spinal anterior horn cells was 0.33 (0.58) in 3 *wt* mice and 0.33 (0.58) in 3 *Pmp22*–/– mice. The mean (SD) number of TUNEL-positive dorsal root ganglion cells was 2.33 (2.52) in 3 *wt* mice and 2.67 (2.08) in 3 *Pmp22*–/– mice (eFigure 1, http://www.archneurol.com). In addition, we have examined the spinal cord and the dorsal root ganglion using semithin sections, hematoxylin-eosin staining, and immunohistochemistry with antibodies against nuclear envelope protein laminin B. No abnormality was detected in *Pmp22*–/– mice (eFigure 2).

COMMENT

This 7-year-old boy is the first reported patient unable to express any PMP22. This null mutation has revealed several features that have crucial implications for PMP22 functions. First, this patient presented with a predominantly large fiber sensory loss resulting in decreased proprioception and sensory ataxia. This differs from many length-dependent inherited neuropathies that present with symmetric distal sensory loss but with minimal sensory ataxia. Moreover, his motor deficits are also nonlength-

©2011 American Medical Association. All rights reserved.
Downloaded From: http://jamanetwork.com/ on 05/20/2013

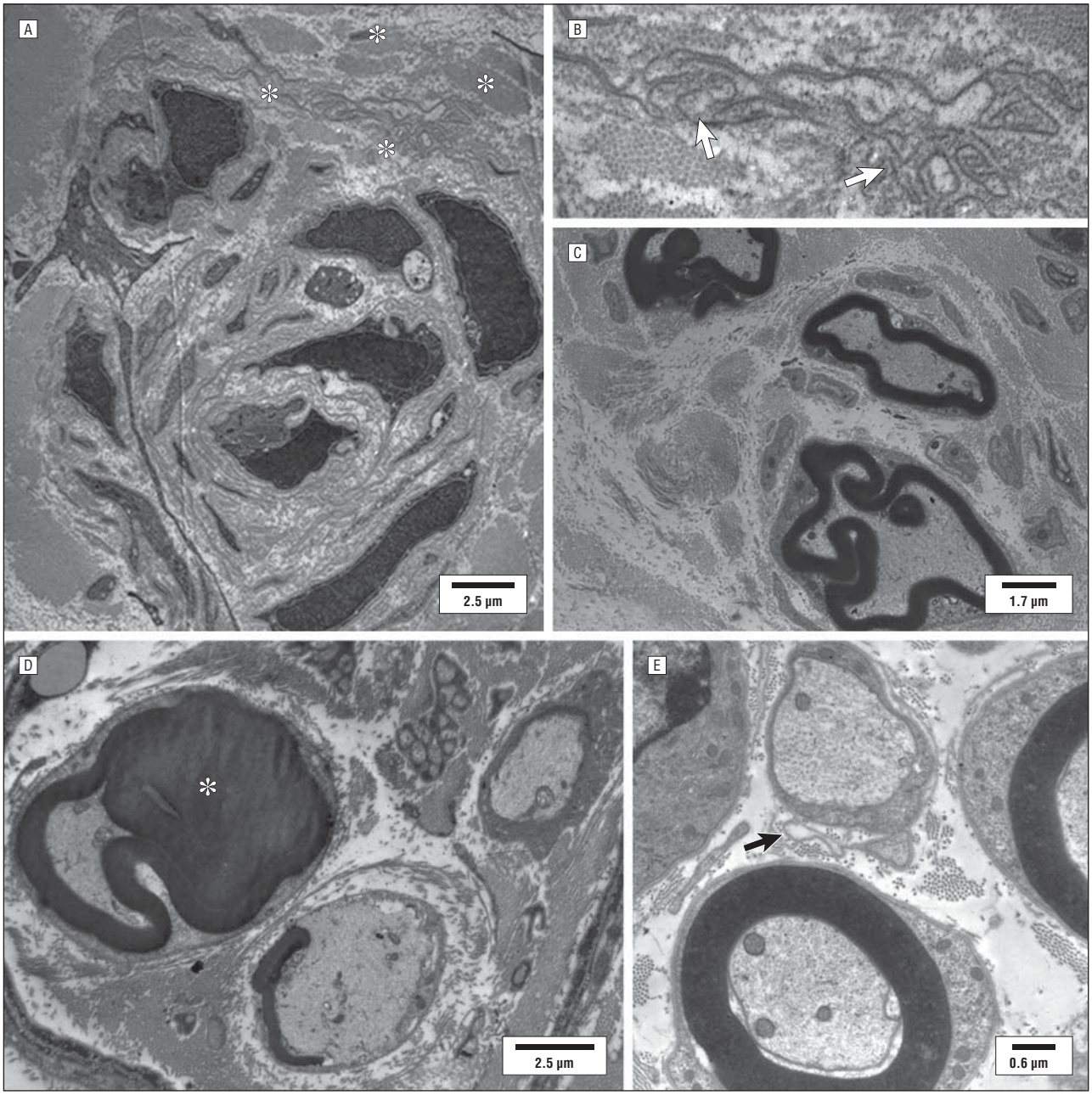

Figure 3. Axonal loss and basal lamina redundancy in skin biopsy samples from the 7-year-old patient without PMP22. A, Electron microscopic image of the patient's skin biopsy sample reveals Schwann-cell processes loosely wrapping around an area where the axon appears to have degenerated. The overall appearance resembles an onion bulb, which is circled by asterisks. B, The area that resembles an onion bulb is enlarged to reveal redundant basal lamina of the Schwann cells (arrows). C, A representative skin biopsy sample from a healthy control reveals the compacted myelin with normal thickness. D, Skin biopsy sample of a *Pmp22*–/– mouse reveals tomaculous formation (asterisk). Tomacula could not be identified in the patient's dermal nerves because the myelinated nerve fibers are degenerated. Two axons on the right side fail to form compact myelin. E, Electron microscopic image of a *Pmp22*–/– mouse's sciatic nerve reveals a number of relatively large axons devoid of compact myelin, as exemplified by the axon on the top. In contrast, an axon on the bottom has a comparable diameter to the one on the top, but its myelin is well formed. The excessive basal membrane redundancy is readily identifiable (arrow).

dependent. Although the muscles in his upper and lower limbs have normal strength, weakness was found in his cranial muscles. These features suggest a proximal pathology. This notion is supported by pathological changes in the spinal roots of *Pmp22*–/– mice. Our previous study[11] has also quantitatively demonstrated that axonal loss in *Pmp22*-null mice is more severe in roots than in distal nerves.

The pattern of sensory and motor deficits in the patient mirrors the expression pattern of PMP22 during development. Sensory loss and ataxia were severe, and cranial motor nerves were significantly affected in the patient. In contrast, functions related to spinal motor neurons were largely spared. Interestingly, PMP22 is highly expressed in the doral root ganglia sensory neurons and cranial motor neurons of rodents during embryonic development and decreases after birth.[2,3] However, expression of PMP22 in spinal motor neurons initiates only after P10 and persists until adulthood.[12,13] Taken together, these data suggest that transient expression of PMP22 in developing dorsal root ganglia and cranial motor neurons may be im-

©2011 American Medical Association. All rights reserved.
Downloaded From: http://jamanetwork.com/ on 05/20/2013

Table 3. Pathological Changes in *Pmp22–/–* Spinal Roots

Mouse No. (Age and Sex) and Slide No.	Root	Pathological Score[a]	
		Axonal Swelling	Amyelinated Axons
Mouse 1 (4-month-old female)			
18	Ventral	2+	2+
19	Ventral	2+	2+
16	Ventral	2+	2+
15	Ventral	0	3+
17	Ventral	1+	3+
11	Dorsal	2+	2+
8	Dorsal	2+	1+
7	Dorsal	2+	1+
9	Dorsal	2+	1+
10	Dorsal	2+	0
Mouse 2 (4-month-old female)			
D5	Ventral	2+	3+
C4	Ventral	1+	3+
C5	Ventral	1+	3+
D2	Ventral	3+	2+
C3	Ventral	2+	3+
B2	Dorsal	1+	0
B3	Dorsal	2+	1+
B6	Dorsal	2+	1+
Mouse 3 (2.5-month-old female)			
C6	Ventral	2+	3+
D2	Ventral	1+	1+
D5	Ventral	1+	1+
33	Dorsal	1+	0
B5	Dorsal	1+	0
B2	Dorsal	2+	0
B1	Dorsal	2+	0
A6	Dorsal	2+	0

[a]The scores are as follows: 0 indicates that there was no pathological change, 1+, that pathological change was observed in less than 5 myelinated fibers, 2+, that pathological change was observed in more than 5 fibers and readily detectable in all examined fields, and 3+, that there were numerous pathological changes in any examined field.

portant for the survival of these neurons during early development. Dysfunction of these neurons would manifest early when PMP22 is deficient. We speculate that the late expression of PMP22 in the spinal motor neurons makes these neurons less dependent on the protein during development. This notion is consistent with no spinal motor neuron loss observed in young *Pmp22–/–* mice.[14] However, PMP22-null spinal motor neurons may degenerate later in life. Alternatively, predominant sensory neuropathy could just be an individual variation of phenotype. These changes in the PMP22-null patient are not seen in patients with heterozygous deletion of *PMP22* (ie, HNPP),[4] suggesting that the absence of PMP22 produces phenotypes distinct from those in *PMP22* haploinsufficiency.

PMP22 function appears shifted after the early phase of development. Robust expression of PMP22 occurs in the peripheral nervous system along with the maturation of myelin during the first 3 weeks of development.[1] Deficiency of PMP22 causes numerous instances of tomacula in the myelinated nerve fibers of peripheral nerves. Axons encased by tomacula become constricted or deformed, which may impair the propagation of the action potential or disrupt axonal transport, leading to axonal degeneration.[5,15] We observed a profound delay of myelination that appears more severe in *Pmp22–/–* motor nerves than in *Pmp22–/–* sensory nerves. The second striking feature of this patient is that motor nerve conduction was extremely slow (in the range of 10 m/s). The Schwann cells in the spinal roots of *Pmp22–/–* mice are often immature and fail to form normal compact myelin. These amyelinated nerve fibers should alter the normal saltatory conduction of the action potential to continuous propagation, which would substantially reduce the conduction velocity. Finally, PMP22-deficient Schwann cells form shorter internodes, which may also slow conduction.[16,17]

A previous report[18] identified another 7-year-old boy who had a compound heterozygous mutation of *PMP22* in which there was a 1.5-Mb HNPP deletion in 1 allele and a smaller deletion of *PMP22* exons 2 and 3 in the other. The motor deficits of this child were more severe than that in our patient. It is possible that this patient is not expressing any PMP22 and that the differences between his and our patient's phenotypes simply represent phenotypic variability. Alternatively, truncated PMP22 from one of the alleles may cause "toxic" gain of function that leads to a more severe phenotype than if there was no PMP22 at all. Consistent with this hypothesis, a patient with the relatively benign *PMP22* T118M mutation[19] was much more severely affected when this was combined with the HNPP deletion on the other allele.[20]

We observed a striking redundancy of the basal lamina in our patient's skin biopsy sample. This redundancy has

©2011 American Medical Association. All rights reserved.
Downloaded From: http://jamanetwork.com/ on 05/20/2013

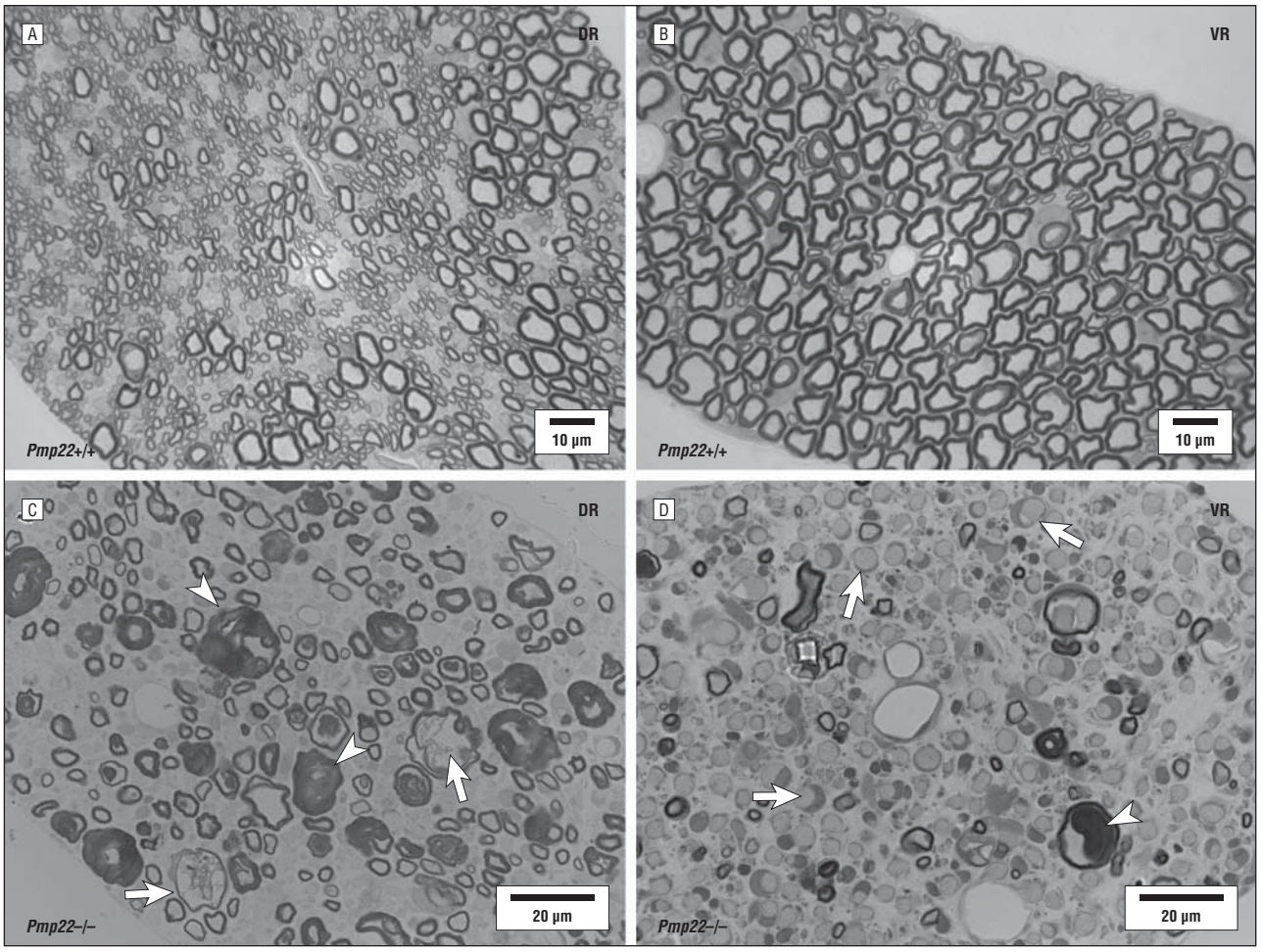

Figure 4. Delayed maturation of myelinating Schwann cells in the spinal roots of *Pmp22*–/– mice. A, Spinal roots were dissected from a 4-week-old mouse and processed for analysis of semithin sections. A dorsal root (DR) was visualized under an oil lens and revealed numerous myelinated nerve fibers with variable diameters. B, In contrast, the diameters of myelinated nerve fibers are relatively uniform in the ventral roots (VRs). Thus, Schwann cells are well differentiated to myelinate the axons when mice are this age. However, when *Pmp22*–/– VRs were examined when the mouse was 4 months of age, numerous myelinating Schwann cells still remained at an immature stage after establishing a 1:1 relationship with axons (arrows in D). Because most myelinating Schwann cells failed to form myelin, instances of tomacula were few in the VR (arrowhead in D). Overall, axonal density appeared comparable to the wild-type VR. C, In contrast, most myelinating Schwann cells have formed myelin in the DRs when mice are 4 months of age, and instances of tomacula were common (arrowheads). The axonal density of the myelinated nerve fibers appeared to be reduced. Some of the axons were swollen (arrows), suggesting axonal degeneration.

been identified in *Pmp22*–/– mice.[10] Amici et al[10] demonstrated a direct interaction between PMP22 and α6β4 integrin, a laminin receptor localized adjacent to the basal lamina. Beta-4 integrin levels are reduced in sciatic nerves of *Pmp22*-deficient mice, leading us to hypothesize that the abnormalities in the basal lamina are the result of decreased interactions between PMP22 and α6β4 integrin.[10] One function of PMP22, therefore, may be to stabilize the linkage between the extracellular matrix and the abaxonal surface of the myelin sheath.

Recently, we have demonstrated that there is a predisposition for *Pmp22*+/– mice to develop conduction block and focal constrictions of axons underneath tomacula, and that these developments may increase axial resistance to the propagation of the action potential.[15] Tomacula and axonal constrictions were predominantly localized at paranodes, which are important areas of interactions between the axon and myelin.[15] Therefore, PMP22 deficiency also appears to disrupt interactions between the adaxonal surface of myelin and the underlying axon. Taken together, these data suggest that an important role for PMP22 is to regulate myelin function at both the abaxonal surface, where it interacts with the extracellular matrix, and the adaxonal surface, where it interacts with the axon.

Accepted for Publication: November 17, 2010.
Author Affiliations: Department of Neurology, Wayne State University, Detroit, Michigan (Drs Saporta and Shy), and Department of Neurology and Neuroscience Program, Vanderbilt University School of Medicine (Drs Zhang and Li), and Tennessee Valley Healthcare System (Dr Li), Nashville; Institute of Neuropathology, RWTH Aachen University, Germany (Dr Katona); Department of Paediatrics, Birmingham Heartlands Hospital (Dr Roper), West Midlands Regional Genetics Laboratory (Drs McClelland and Macdonald), and Clinical Genetics Unit, Birmingham Women's NHS Foundation Trust (Dr Brueton), Birmingham, and Medical Research Council Centre for Neuromuscular Diseases, Department of Molecular Neurosciences, Institute of Neurology, University College London (Drs Blake and Reilly),

©2011 American Medical Association. All rights reserved.
Downloaded From: http://jamanetwork.com/ on 05/20/2013

England; and Department of Biology, Institute of Cell Biology, ETH Zurich, Switzerland (Dr Suter).
Correspondence: Jun Li, MD, PhD, Department of Neurology and Neuroscience Program, Vanderbilt University School of Medicine, AA0204F Medical Center North, 1161 21st Ave S, Nashville, TN 37232-2551 (jun.li.2@vanderbilt.edu).
Author Contributions: Drs Saporta and Katona contributed equally to this manuscript. *Study concept and design:* Saporta, Shy, and Li. *Acquisition of data:* Saporta, Katona, Zhang, Roper, McClelland, Macdonald, Brueton, Blake, Reilly, Shy, and Li. *Analysis and interpretation of data:* Saporta, Katona, Blake, Suter, Reilly, Shy, and Li. *Drafting of the manuscript:* Saporta, Katona, Roper, Brueton, Blake, Shy, and Li. *Critical revision of the manuscript for important intellectual content:* Saporta, Katona, Zhang, McClelland, Macdonald, Suter, Reilly, Shy, and Li. *Obtained funding:* Shy and Li. *Administrative, technical, and material support:* Saporta, Katona, Zhang, McClelland, Macdonald, Suter, and Li. *Study supervision:* Reilly and Li.
Financial Disclosure: None reported.
Funding/Support: This work is, in part, supported by grants from the Veterans Affairs (B6243R) and the National Institutes of Health (R01NS066927). Laboratory work by Dr Suter is supported by the Swiss National Science Foundation and the National Center for Competence in Research Neural Plasticity and Repair. This work was also supported by the Medical Research Council, the Muscular Dystrophy Campaign, and the National Institutes of Health (Dr Reilly).
Online-Only Material: The eFigures are available at http://www.archneurol.com.

REFERENCES

1. Jetten AM, Suter U. The peripheral myelin protein 22 and epithelial membrane protein family. *Prog Nucleic Acid Res Mol Biol*. 2000;64:97-129.
2. Parmantier E, Cabon F, Braun C, D'Urso D, Müller HW, Zalc B. Peripheral myelin protein-22 is expressed in rat and mouse brain and spinal cord motoneurons. *Eur J Neurosci*. 1995;7(5):1080-1088.
3. Parmantier E, Braun C, Thomas JL, Peyron F, Martinez S, Zalc B. PMP-22 expression in the central nervous system of the embryonic mouse defines potential transverse segments and longitudinal columns. *J Comp Neurol*. 1997;378(2):159-172.
4. Li J, Krajewski K, Lewis RA, Shy ME. Loss-of-function phenotype of hereditary neuropathy with liability to pressure palsies. *Muscle Nerve*. 2004;29(2):205-210.
5. Adlkofer K, Martini R, Aguzzi A, Zielasek J, Toyka KV, Suter U. Hypermyelination and demyelinating peripheral neuropathy in Pmp22-deficient mice. *Nat Genet*. 1995;11(3):274-280.
6. Schouten JP, McElgunn CJ, Waaijer R, Zwijnenburg D, Diepvens F, Pals G. Relative quantification of 40 nucleic acid sequences by multiplex ligation-dependent probe amplification. *Nucleic Acids Res*. 2002;30(12):e57.
7. Li J, Bai Y, Ghandour K, et al. Skin biopsies in myelin-related neuropathies: bringing molecular pathology to the bedside. *Brain*. 2005;128(pt 5):1168-1177.
8. Li J, Krajewski K, Shy ME, Lewis RA. Hereditary neuropathy with liability to pressure palsy: the electrophysiology fits the name. *Neurology*. 2002;58(12):1769-1773.
9. Saporta MA, Katona I, Lewis RA, Masse S, Shy ME, Li J. Shortened internodal length of dermal myelinated nerve fibres in Charcot-Marie-Tooth disease type 1A. *Brain*. 2009;132(pt 12):3263-3273.
10. Amici SA, Dunn WA Jr, Murphy AJ, et al. Peripheral myelin protein 22 is in complex with alpha6beta4 integrin, and its absence alters the Schwann cell basal lamina. *J Neurosci*. 2006;26(4):1179-1189.
11. Sancho S, Magyar JP, Aguzzi A, Suter U. Distal axonopathy in peripheral nerves of PMP22-mutant mice. *Brain*. 1999;122(pt 8):1563-1577.
12. Maier M, Berger P, Nave KA, Suter U. Identification of the regulatory region of the peripheral myelin protein 22 (PMP22) gene that directs temporal and spatial expression in development and regeneration of peripheral nerves. *Mol Cell Neurosci*. 2002;20(1):93-109.
13. Ohsawa Y, Murakami T, Miyazaki Y, Shirabe T, Sunada Y. Peripheral myelin protein 22 is expressed in human central nervous system. *J Neurol Sci*. 2006;247(1):11-15.
14. Nattkämper H, Halfter H, Khazaei MR, et al. Varying survival of motoneurons and activation of distinct molecular mechanism in response to altered peripheral myelin protein 22 gene dosage. *J Neurochem*. 2009;110(3):935-946.
15. Bai YH, Zhang XB, Katona I, et al. Conduction block in PMP22 deficiency. *J Neurosci*. 2010;30(2):600-608.
16. Amici SA, Dunn WA Jr, Notterpek L. Developmental abnormalities in the nerves of peripheral myelin protein 22-deficient mice. *J Neurosci Res*. 2007;85(2):238-249.
17. Court FA, Sherman DL, Pratt T, et al. Restricted growth of Schwann cells lacking Cajal bands slows conduction in myelinated nerves. *Nature*. 2004;431(7005):191-195.
18. Al-Thihli K, Rudkin T, Carson N, Poulin C, Melançon S, Der Kaloustian VM. Compound heterozygous deletions of PMP22 causing severe Charcot-Marie-Tooth disease of the Dejerine-Sottas disease phenotype. *Am J Med Genet A*. 2008;146A(18):2412-2416.
19. Shy ME, Scavina MT, Clark A, et al. T118M PMP22 mutation causes partial loss of function and HNPP-like neuropathy. *Ann Neurol*. 2006;59(2):358-364.
20. Roa BB, Garcia CA, Pentao L, et al. Evidence for a recessive PMP22 point mutation in Charcot-Marie-Tooth disease type 1A. *Nat Genet*. 1993;5(2):189-194.

©2011 American Medical Association. All rights reserved.
Downloaded From: http://jamanetwork.com/ on 05/20/2013