ORIGINAL ARTICLE

Follicular Variant of Papillary Thyroid Cancer

Encapsulated, Nonencapsulated, and Diffuse: Distinct Biologic and Clinical Entities

Sachin Gupta, MD; Oluyomi Ajise, MD; Linda Dultz, MD; Beverly Wang, MD; Daisuke Nonaka, MD; Jennifer Ogilvie, MD; Keith S. Heller, MD; Kepal N. Patel, MD

Objective: To examine genotypic and clinical differences between encapsulated, nonencapsulated, and diffuse follicular variant of papillary thyroid carcinoma (EFVPTC, NFVPTC, and diffuse FVPTC, respectively), to characterize the entities and identify predictors of their behavior.

Design: Retrospective medical chart review and molecular analysis.

Setting: Referral center of a university hospital.

Patients: The pathologic characteristics of 484 consecutive patients with differentiated thyroid cancer who underwent surgery by the 3 members of the New York University Endocrine Surgery Associates from January 1, 2007, to August 1, 2010, were reviewed. Forty-five patients with FVPTC and in whom at least 1 central compartment lymph node was removed were included.

Main Outcome Measures: Patients with FVPTC were compared in terms of age, sex, tumor size, encapsulation, extrathyroid extension, vascular invasion, central nodal metastases, and the presence or absence of mutations in *BRAF*, *H-RAS 12/13*, *K-RAS 12/13*, *N-RAS 12/13*, *H-RAS 61*, *K-RAS 61*, *N-RAS 61*, and *RET/PTC1*.

Results: No patient with EFVPTC had central lymph node metastasis, and in this group, 1 patient (4.5%) had a *BRAF* V600E mutation and 2 patients (9%) had *RAS* mutations. Of the patients with NFVPTC, none had central lymph node metastasis ($P > .99$) and 2 (11%) had a *BRAF* V600E mutation ($P = .59$). Of the patients with diffuse FVPTC, all had central lymph node metastasis ($P < .001$), and 2 (50%) had a *BRAF* V600E mutation ($P = .06$).

Conclusions: FVPTC consists of several distinct subtypes. Diffuse FVPTC seems to present and behave in a more aggressive fashion. It has a higher rate of central nodal metastasis and *BRAF* V600E mutation in comparison with EFVPTC and NFVPTC. Both EFVPTC and NFVPTC behave in a similar fashion. The diffuse infiltrative pattern and not just presence or absence of encapsulation seems to determine the tumor phenotype. Understanding the different subtypes of FVPTC will help guide appropriate treatment strategies.

Arch Otolaryngol Head Neck Surg. 2012;138(3):227-233

Cancer of the thyroid gland is the most common endocrine malignant tumor and accounts for most endocrine cancer–related deaths each year.[1] Well-differentiated thyroid cancer is usually associated with a good prognosis. The most common histologic type is papillary thyroid carcinoma (PTC).[1] Many subtypes of PTC have been described, of which classical PTC (cPTC) is the most common (80%). The follicular variant of PTC (FVPTC) is the second most common subtype, being found in 9% to 22.5% of patients with PTC.[2-5] The first histologic description of FVPTC was by Lindsay[6] in 1960, followed by Chen and Rosai[7] in 1977, and Rosai et al[8] in 1983. It is characterized as a tumor possessing both nuclear features typical of PTC (eg, nuclear clearing, grooves, and pseudoinclusions) and a follicular growth pattern.

FVPTC presents several diagnostic and management challenges. Most FVPTCs are encapsulated tumors, which are cytologically difficult to distinguish from benign follicular lesions such as follicular adenoma (FTA). Several studies highlight this by demonstrating the considerable interobserver variability involved with the diagnosis of FVPTC.[9,10] In addition to the encapsulated subtype (EFVPTC), there is also a nonencapsulated subtype of FVPTC (NFVPTC). These subtypes seem to be distinct both clinically and genetically. A study by Liu et al[11] showed that while EFVPTC rarely exhibited lymph node metastases (in 5% of cases), NFVPTC was associated with lymph node metastases in 65% of cases.

Author Affiliations: Departments of Otolaryngology–Head and Neck Surgery (Dr Gupta), Pathology (Drs Ajise, Wang, and Nonaka), and Surgery (Drs Dultz, Ogilvie, Heller, and Patel), New York University Langone Medical Center, New York, New York.

©2012 American Medical Association. All rights reserved.
Downloaded From: http://jamanetwork.com/ on 06/20/2013

They concluded that most EFVPTCs behave like an FTA or follicular thyroid carcinoma (FTC), whereas NFVPTCs behave like cPTC.

On a molecular level, Rivera et al[12] examined the oncogenic mutations present in EFPVTC and NFVPTC. They found that EFVPTC was similar to FTA and FTC, with a high rate of RAS mutations (36%), and no *BRAF* mutations (0%). In contrast, they found NFVPTC to be more similar to cPTC, with a significantly higher rate of *BRAF* mutations (26%) and a lower rate of *RAS* mutations (10%).

In addition to the encapsulated and nonencapsulated subtypes of FVPTC, Sobrinho-Simões et al[13] described the diffuse follicular variant of PTC (diffuse FVPTC). This variant occurred primarily in young females and was characterized on a histologic level by extensive, multinodular involvement of 1 or both lobes of the thyroid gland. The 8 patients in their series with diffuse FVPTC developed distant metastases in the lungs and/or bones with or without concurrent regional lymph node metastases. Diffuse FVPTC was further studied by Ivanova et al,[14] who found that patients with diffuse FVPTC had notably increased local, nodal, and vascular invasiveness compared with other patients with FVPTC. They concluded that diffuse FVPTC is a distinct tumor carrying a guarded prognosis that has to be appropriately diagnosed and treated.

The 2009 American Thyroid Association Guidelines[15] provide little direction for the surgical treatment of FVPTC. Recommendation 26 states that for patients with thyroid cancer larger than 1 cm, the initial surgical procedure should be a near-total or total thyroidectomy. Recommendation 27b states that elective (prophylactic) central-compartment neck dissection may be considered in patients with PTC and clinically uninvolved central neck lymph nodes, especially in patients with advanced primary tumors (T3 or T4).[15] It is important to note that these recommendations do not distinguish between cPTC and FVPTC, and they may not necessarily apply to all variants of PTC. We examined clinical and genotypic differences between the encapsulated, nonencapsulated, and diffuse subtypes of FVPTC to characterize the entities and identify predictors of their behavior, which may help guide their management.

METHODS

CLINICAL AND PATHOLOGIC ANALYSIS

The medical records of all 484 patients who underwent thyroid operations with a postoperative diagnosis of thyroid cancer at New York University (NYU) Langone Medical Center by the 3 members of NYU Endocrine Surgery Associates from January 1, 2007, through August 1, 2010, were reviewed. Indications for surgery included cytologic findings on fine-needle aspiration biopsy, symptomatic or enlarging multinodular goiter, and Graves disease. The extent of thyroidectomy (lobectomy vs total thyroidectomy) was determined by the operating surgeon based on preoperative evaluation, patient preference, and intraoperative findings. Central compartment lymph node sampling or central compartment dissection was performed if suspicious nodes were identified at the time of surgery, or electively at the discretion of the surgeon.

Of these patients, 103 with FVPTC were identified by 2 experienced thyroid pathologists (B.W. and D.N.). The diagnosis of FVPTC was made when nuclear characteristics of cPTC were present with a follicular growth pattern. From this group of 103 patients with FVPTC, 45 patients in whom at least 1 central compartment lymph node was removed were included in the study. Pathologic findings were reviewed for tumor size, the presence of encapsulation, extrathyroidal extension, vascular invasion, and central nodal metastases. These 45 patients were divided into our 3 study groups (those with EFVPTC, NFVPTC, and diffuse FVPTC).

MOLECULAR ANALYSIS

The presence of the *BRAF* V600E mutation, *RAS* (*H-RAS*, *K-RAS*, *N-RAS*) point mutations (codons 12, 13, and 61), and the *RET-PTC1* rearrangement were identified in excised surgical specimens by direct sequencing. For analysis of *BRAF* and *RAS* genes, DNA was extracted from 10-µm sections of paraffin-embedded tumor blocks using a commercial kit (Qiagen, Germantown, Maryland). The extracted DNA was quantified using a NanoDrop 2000c spectrophotometer (Thermo Fisher Scientific Inc). The *BRAF* gene was amplified with primers as previously described.[16-18] Codons 12/13 and 61 of *H-RAS*, *K-RAS*, and *N-RAS* genes were amplified using primers as previously described.[16-18] Polymerase chain reaction (PCR) was then performed in a 20-µL mixture containing primer, deoxyribonucleotide triphosphated (NTP), DNA polymerase, and genomic DNA. The PCR conditions consisted of initial denaturation at 95°C followed by 35 cycles of denaturation at 95°C for 30 seconds, annealing at 58°C for 40 seconds, and extension at 72°C for 40 seconds. The final extension step was performed at 72°C for 1 minute. The DNA PCR products' integrity was then evaluated using 2% agarose gel electrophoresis. The products were purified using a commercial PCR purification kit (Qiagen) according to the manufacturer's instructions. The purified PCR products were sequenced commercially (Genewiz, South Plainfield, New Jersey).

For analysis of the *RET-PTC1* rearrangement, RNA was extracted from 10-µm sections of each tumor's paraffin-embedded block using a commercial kit (Qiagen). The extracted RNA was quantified using a NanoDrop 2000c spectrophotometer (Thermo Fisher Scientific Inc). Complementary DNA (cDNA) was synthesized using 0.5 µg of extracted RNA and a commercial kit (Qiagen). Reverse transcriptase-polymerase chain reaction (RT-PCR) was performed in a 20-µL mixture containing primer, dNTP, DNA polymerase, and 500 ng of cDNA. Primers used for *RET-PTC1* have been described previously.[16,17] The RT-PCR conditions consisted of initial denaturation at 95°C followed by 35 cycles of denaturation at 95°C for 30 seconds, annealing at 58°C for 40 seconds, and extension at 72°C for 40 seconds. The RT-PCR products were then visualized using 2% agarose gel electrophoresis. The cDNA from the TPC-1 cell line served as a positive control for the *RET-PTC1* rearrangement. *RP1* was used in all reactions as a housekeeping gene.

STATISTICAL ANALYSIS

A 2-tailed Fisher exact test was used to assess the relationship between categorical variables. $P < .05$ was considered significant. This study was approved by the NYU Cancer Institute protocol review and monitoring committee and by the NYU institutional review board.

©2012 American Medical Association. All rights reserved.
Downloaded From: http://jamanetwork.com/ on 06/20/2013

Table 1. Clinical, Pathologic, and Molecular Characteristics of EFPVTC and NFVPTC

Characteristic	Patients, No. (%) EFPVTC (n=22)	NFVPTC (n=19)	*P* Value[a]
Age			
Median, y	47	52	
≤45	9 (41)	5 (26)	.51
>45	13 (59)	14 (74)	
Sex			
Female	16 (73)	16 (84)	.47
Male	6 (27)	3 (16)	
Tumor size, cm			
Median	1.7	0.9	
≤4	20 (91)	19 (100)	.49
>4	2 (9)	0	
Vascular invasion			
Absent	21 (95)	18 (95)	>.99
Present	1 (5)	1 (5)	
Extrathyroid extension			
Absent	22 (100)	19 (100)	>.99
Present	0	0	
Central nodal metastases			
Absent	22 (100)	19 (100)	>.99
Present	0	0	
Thyroid surgery			
Lobectomy	5 (23)	2 (11)	.42
Total thyroidectomy ± CLND	17 (77)	17 (89)	
BRAF V600E mutation			
Absent	21 (95)	17 (89)	.59
Present	1 (5)	2 (11)	
RAS mutations[b]			
Absent	20 (90)	19 (100)	.49
Present	2 (10)	0	

Abbreviations: CLND, central lymph node dissection; EFVPTC, encapsulated follicular variant of papillary thyroid carcinoma; NFVPTC, nonencapsulated follicular variant of papillary thyroid carcinoma.
[a] Fisher exact test, 2-tailed values.
[b] *RAS* mutations assessed include *H-RAS*, *K-RAS*, and *N-RAS* at codons 12, 13, and 61.

Table 2. Clinical, Pathologic, and Molecular Characteristics of EFPVTC + NFVPTC and Diffuse FVPTC

Characteristic	Patients, No. (%) EFPVTC + NFVPTC (n=41)	Diffuse FVPTC (n=4)	*P* Value[a]
Age			
Median, y	50	32	
≤45	14 (34)	3 (75)	.14
>45	27 (66)	1 (25)	
Sex			
Female	32 (78)	3 (75)	>.99
Male	9 (22)	1 (25)	
Tumor size, cm			
Median	1.2	2.4	
≤4	39 (95)	4 (100)	.50
>4	2 (5)	0	
Vascular invasion			
Absent	39 (95)	1 (25)	.003
Present	2 (5)	3 (75)	
Extrathyroid extension			
Absent	41 (100)	2 (50)	.006
Present	0	2 (50)	
Central nodal metastases			
Absent	41 (100)	0	<.001
Present	0	4 (100)	
Thyroid surgery			
Lobectomy	7 (17)	0	>.99
Total thyroidectomy ± CLND	34 (83)	4 (100)	
BRAF V600E mutation			
Absent	38 (93)	2 (50)	.06
Present	3 (7)	2 (50)	
RAS mutations[b]			
Absent	39 (95)	4 (100)	>.99
Present	2 (5)	0	

Abbreviations: CLND, central lymph node dissection; EFVPTC, encapsulated follicular variant of papillary thyroid carcinoma; NFVPTC, nonencapsulated follicular variant of papillary thyroid carcinoma.
[a] Fisher exact test, 2-tailed values.
[b] RAS mutations assessed include *H-RAS*, *K-RAS*, and *N-RAS* at codons 12, 13, and 61.

RESULTS

CLINICAL AND PATHOLOGIC ANALYSIS

A total of 45 cases were included in the study (22 cases of EFVPTC; 19, NFVPTC; and 4, diffuse FVPTC). **Table 1** compares the clinical and pathologic features of EFVPTC and NFVPTC. The 2 histologic subtypes seem to be identical. There were no significant differences in terms of age, sex, tumor size, vascular invasion, extrathyroid extension, central nodal metastasis, or extent of initial thyroid surgery between the 2 groups. Vascular invasion was present in only 1 patient in each group, and no patient in either group had extrathyroid tumor invasion or central lymph node metastases.

Table 2 compares the combined clinical and pathologic characteristics of EFVPTC and NFVPTC with those of diffuse FVPTC. Again, there were no significant differences in terms of age, sex, or tumor size. There were significant differences in vascular invasion ($P = .003$), extrathyroid extension ($P = .006$), and central lymph nodal metastases ($P < .001$). Note that whereas none of the patients with EFVPTC or NFVPTC had clinically palpable or radiograph evidence of lymph node metastasis in the central or lateral compartment, all 4 of the patients with diffuse FVPTC had clinically palpable and/or radiographic evidence of lymph node metastasis (31 of 50 central lymph nodes were positive for metastasis). All 4 patients with diffuse FVPTC (100%) had total thyroidectomy with central lymph node dissection.

Table 3. Central Lymph Nodes Sampled in EFVPTC and NFVPTC

Central Lymph Nodes, No.	Patients, No. (%) EFVPTC (n=22)	NFVPTC (n=19)
1	11 (50)	10 (53)
2-3	7 (32)	5 (26)
>3	4 (18)	4 (21)

Abbreviations: EFVPTC, encapsulated follicular variant of papillary thyroid carcinoma; NFVPTC, nonencapsulated follicular variant of papillary thyroid carcinoma.

©2012 American Medical Association. All rights reserved.
Downloaded From: http://jamanetwork.com/ on 06/20/2013

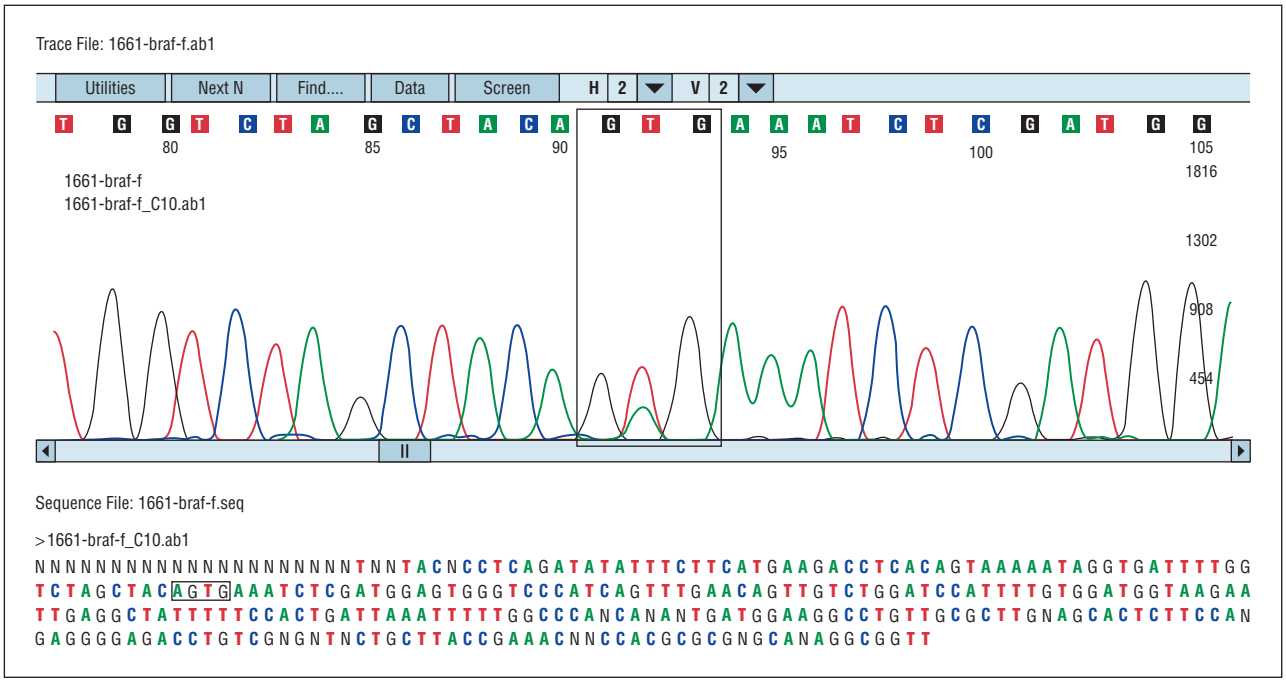

Figure 1. Gene sequencing tracing showing *BRAF* V600E mutation in a patient with nonencapsulated follicular variant of papillary thyroid carcinoma.

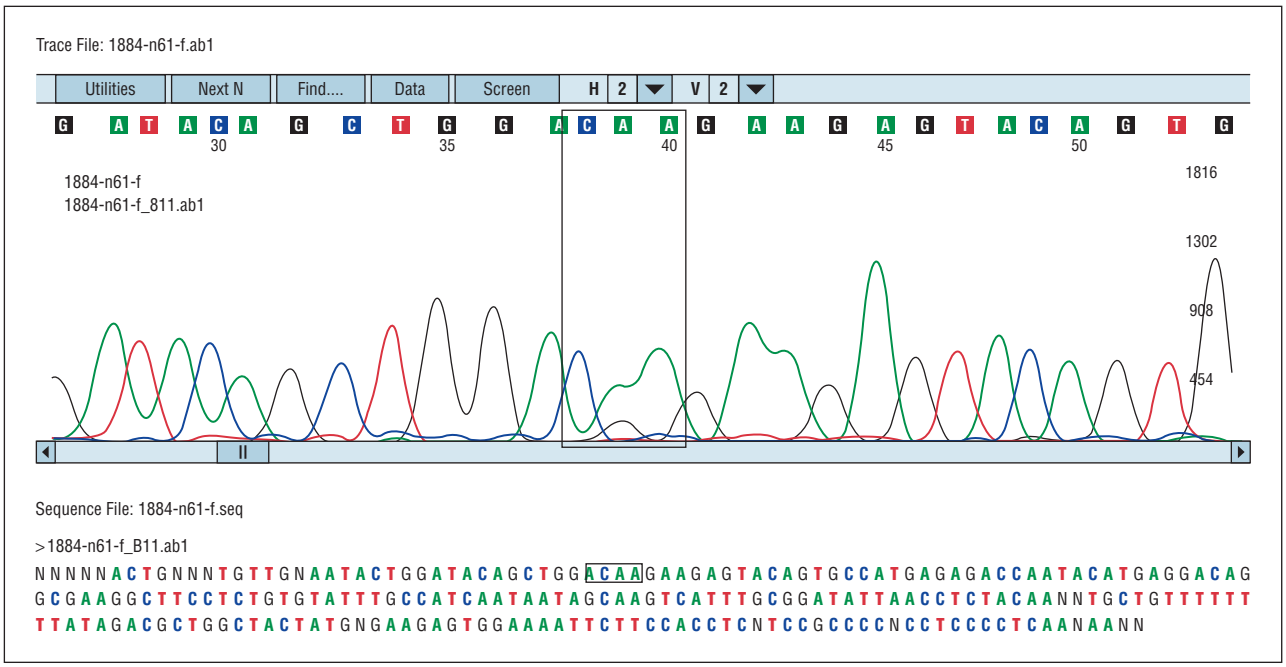

Figure 2. Gene sequencing tracing showing *N-RAS 61* mutation in a patient with nonencapsulated follicular variant of papillary thyroid carcinoma.

Table 3 details the distribution of central lymph nodes from patients with EFVPTC and NFVPTC. Patients with diffuse FVPTC were excluded from this analysis because they uniformly underwent total thyroidectomy with central lymph node dissection, resulting in 50 central lymph nodes evenly distributed among the 4 patients.

MOLECULAR ANALYSIS

Table 1 compares the molecular features of EFPVTC and NFVPTC. In the EFVPTC group of 22 patients, 1 patient (5%) had a *BRAF* V600E mutation (**Figure 1**), 1 patient (5%) had an *N-RAS 61* mutation (**Figure 2**), and 1 patient (5%) had a *K-RAS 61* mutation (**Figure 3**). In the NFVPTC group of 19 patients, 2 patients (11%) had a *BRAF* V600E mutation (**Figure 4**), whereas no patients had *RAS* mutations. The rates of *RAS* and *BRAF* V600E mutations between EFPVTC and NFVPTC were not statistically significant ($P = .49$ and $P = .59$, respectively).

Table 2 compares the combined molecular features of EFVPTC and NFVPTC with diffuse FVPTC. In the 4 patients with diffuse FVPTC, 2 patients (50%) had a *BRAF*

©2012 American Medical Association. All rights reserved.
Downloaded From: http://jamanetwork.com/ on 06/20/2013

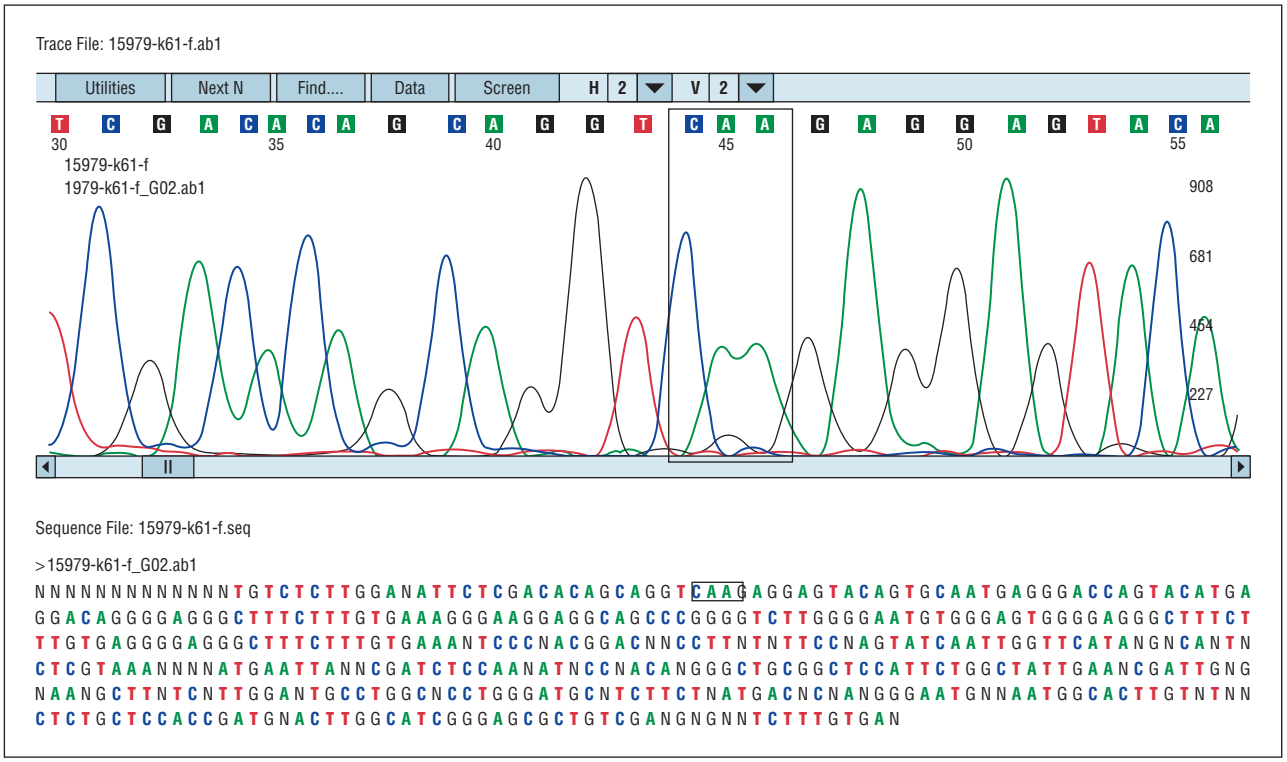

Figure 3. Gene sequencing tracing showing *K-RAS 61* mutation in a patient with nonencapsulated follicular variant of papillary thyroid carcinoma.

V600E mutation (Figure 4), whereas no patients had *RAS* mutations. The difference between the rates of *BRAF* V600E mutation in the 2 groups was not statistically significant ($P = .06$). No *RET/PTC1* mutations were seen in any of the patients in the study.

COMMENT

The treatment of papillary thyroid cancer is dependent on the biologic behavior of the tumor. The role of completion thyroidectomy, central neck dissection, and postoperative radioiodine (RAI) ablation to help prevent recurrent disease is all dependent on the malignant potential of the primary tumor. Previous studies[11,12] have shown that EFVPTC behaves less like cPTC and more like FTA/FTC, with a lower rate of *BRAF* V600E mutations and nodal metastases. NFVPTC, however, has been shown to behave more like cPTC, with a significantly higher rate of *BRAF* V600E mutations and nodal metastases.[12]

These previous studies, however, did not specifically separate patients with diffuse FVPTC from those with NFVPTC. This study shows that diffuse FVPTC is a distinct subtype of FVPTC with aggressive clinical and genotypic characteristics that are important to recognize for appropriate treatment. When diffuse FVPTC is specifically separated from NFVPTC, it seems that NFVPTC and EFVPTC have similar molecular profiles and clinical behavior with low rates of nodal metastases and *BRAF* V600E mutations. Previous studies may have overestimated differences between EFVPTC and NFVPTC by failing to recognize diffuse FVPTC as a distinct clinical entity.

In this study, no patients with EFVPTC or NFVPTC had central nodal metastases. Only the 4 patients with diffuse FVPTC, all of whom had clinically palpable and/or radiographic evidence of lateral and/or central nodal metastases, had pathologically positive central nodal metastases. When compared with patients with EFVPTC and NFVPTC, this was statistically significant ($P < .001$). The observed rate of nodal metastasis in diffuse FVPTC was higher than that reported in FTC (5%-10%), and similar to that reported for cPTC (45%-65%).[18] In addition, patients with diffuse FVPTC had a statistically significant increase in vascular invasion ($P = .003$) and extrathyroidal extension ($P = .006$) when compared with those with EFVPTC and NFVPTC. Although the comparisons were not statistically significant, they did not differ in terms of *BRAF* V600E mutation ($P = .06$). This is most likely due to the small cohort of patients with diffuse FVPTC. Further studies, with a larger number of patients with diffuse FVPTC, are necessary to better understand this entity at the molecular level.

The follicular variant of PTC is a unique tumor with distinct subtypes. These subtypes need to be considered in the treatment of patients with this tumor. Because of the absence of lymph node metastases in patients with EFVPTC and NFVPTC, more limited surgery may be possible in individuals with these entities. The need for RAI ablation in these patients should also be reconsidered. The risks of completion thyroidectomy (hypoparathyroidism, recurrent laryngeal nerve injury) and RAI ablation (salivary dysfunction, second primary) may outweigh the benefits in these patients. Patients with diffuse FVPTC, however, probably should be treated aggressively with total thyroidectomy, central-compartment neck dissection, and RAI ablation.

There are a few limitations to this study. First, this study includes patients who had various degrees of ini-

©2012 American Medical Association. All rights reserved.
Downloaded From: http://jamanetwork.com/ on 06/20/2013

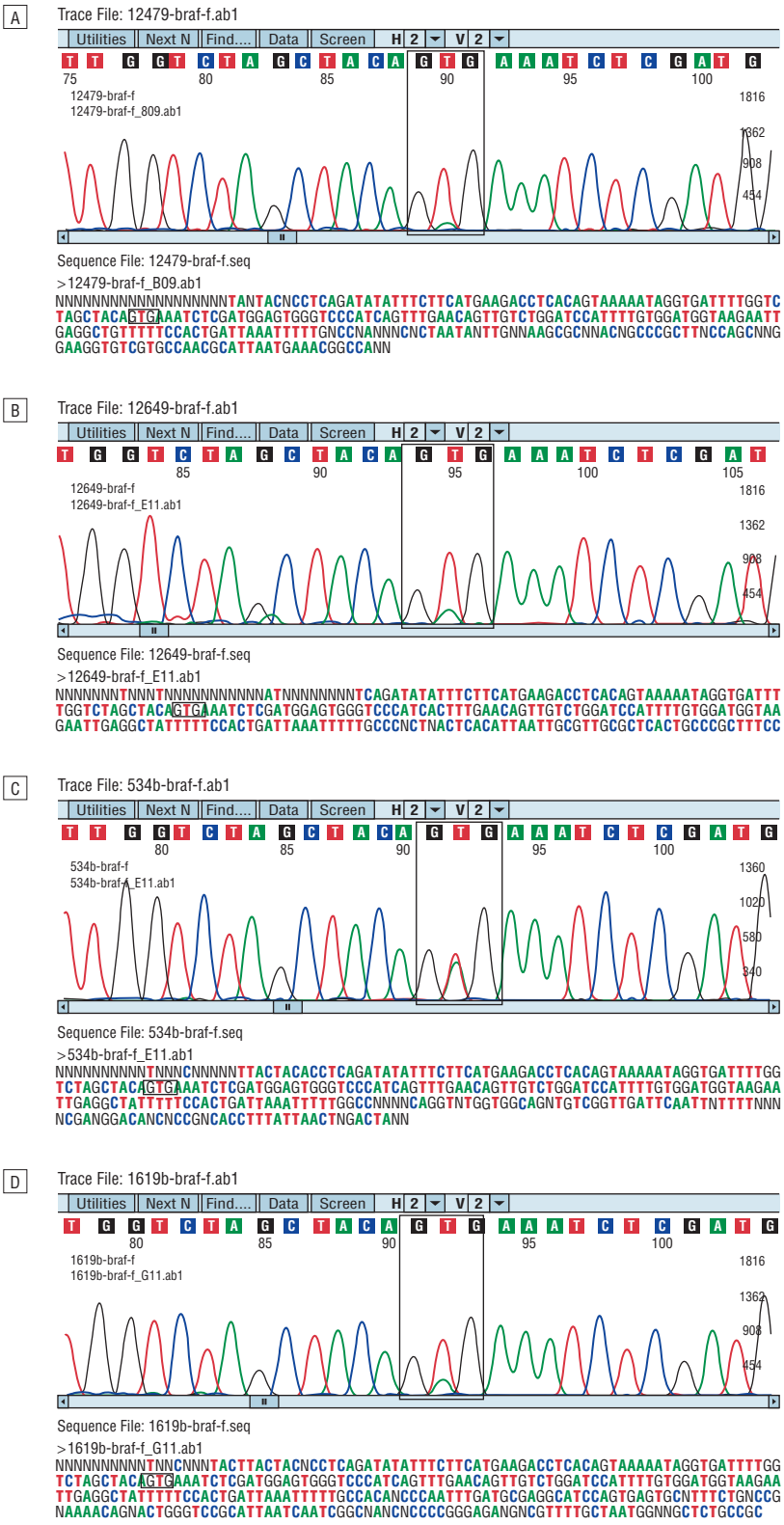

Figure 4. Gene sequencing tracings showing *BRAF* V600E mutations in patients with nonencapsulated follicular variant of papillary thyroid carcinoma and diffuse follicular variant of papillary thyroid carcinoma.

tial thyroid surgery, ranging from lobectomy to total thyroidectomy with central compartment neck dissection. Only patients with at least 1 central lymph node in the pathologic specimen were included. A total number of 145 central lymph nodes were evaluated. We feel that this number is likely representative of central nodal status in

©2012 American Medical Association. All rights reserved.
Downloaded From: http://jamanetwork.com/ on 06/20/2013

FVPTC, but since only a minority underwent formal central compartment neck dissection, it is possible that this study underestimates the incidence of central nodal metastasis in FVPTC. This may help account for the observed lower rates of central nodal metastasis in this study as compared with other studies of FVPTC.

In conclusion, this study supports the argument that FVPTC can be separated into distinct entities: EFVPTC, NFVPTC, and diffuse FVPTC. EFVPTC and NFVPTC seem to have clinical and genetic profiles more like FTA and FTC, whereas diffuse FVPTC has a clinical and genetic profile more like cPTC, with increased rates of *BRAF* V600E mutation and central nodal metastases. This study suggests that patients who undergo thyroid surgery for indeterminate lesions, for which the final pathologic findings reveal an EFVPTC or NFVPTC, with no evidence of diffuse infiltrative disease, are at low risk of harboring metastatic disease and may benefit from close observation instead of completion thyroid surgery and RAI ablation. Understanding the biology of the disease may help guide the treatment of these distinct entities.

Submitted for Publication: May 26, 2011; final revision received October 2, 2011; accepted December 5, 2011.
Correspondence: Kepal N. Patel, MD, Department of Otolaryngology–Head and Neck Surgery, New York University Langone Medical Center, 530 First Ave, Ste 6H, New York, NY 10016 (kepal.patel@nyumc.org).
Author Contributions: Drs Gupta and Patel had full access to all the data in the study and take responsibility for the integrity of the data and the accuracy of the data analysis. *Study concept and design:* Gupta, Ajise, Wang, Nonaka, Ogilvie, Heller, and Patel. *Acquisition of data:* Gupta, Ajise, Dultz, Wang, Ogilvie, Heller, and Patel. *Analysis and interpretation of data:* Gupta, Ajise, Ogilvie, Heller, and Patel. *Drafting of the manuscript:* Gupta, Ajise, and Dultz. *Critical revision of the manuscript for important intellectual content:* Wang, Nonaka, Ogilvie, Heller, and Patel. *Statistical analysis:* Gupta and Dultz. *Administrative, technical, and material support:* Gupta, Ajise, Wang, Nonaka, Ogilvie, Heller, and Patel. *Study supervision:* Wang, Ogilvie, Heller, and Patel.
Previous Presentation: This study was given as an oral presentation at the American Head and Neck Society 2011 Annual Meeting; April 28, 2011; Chicago, Illinois.
Additional Contributions: We acknowledge the Tissue Acquisition and Biorepository Core at the NYU Langone Medical Center, which is supported by the NYU Cancer Institute Center Support grant and National Institutes of Health/National Cancer Institute 5 grant P30CA16087-31.

REFERENCES

1. Patel KN, Singh B. Molecular Advances in the Diagnosis and Treatment of Thyroid Cancer. In: Terris D, Gourin C, eds. *Thyroid and Parathyroid Diseases: Medical and Surgical Management*. New York, NY: Thieme; 2008.
2. Passler C, Prager G, Scheuba C, et al. Follicular variant of papillary thyroid carcinoma: a long-term follow-up. *Arch Surg*. 2003;138(12):1362-1366.
3. Carcangiu ML, Zampi G, Pupi A, Castagnoli A, Rosai J. Papillary carcinoma of the thyroid: a clinicopathologic study of 241 cases treated at the University of Florence, Italy. *Cancer*. 1985;55(4):805-828.
4. Tielens ET, Sherman SI, Hruban RH, Ladenson PW. Follicular variant of papillary thyroid carcinoma: a clinicopathologic study. *Cancer*. 1994;73(2):424-431.
5. Sebastian SO, Gonzalez JM, Paricio PP, et al. Papillary thyroid carcinoma: prognostic index for survival including the histological variety. *Arch Surg*. 2000;135(3):272-277.
6. Lindsay S. *Carcinoma of the Thyroid Gland: A Clinical and Pathologic Study of 293 Patients at the University of California Hospital*. Springfield, IL: Charles C Thomas Publisher; 1960.
7. Chem KT, Rosai J. Follicular variant of thyroid papillary carcinoma: a clinicopathologic study of six cases. *Am J Surg Pathol*. 1977;1(2):123-130.
8. Rosaí J, Zampi G, Carcangiu ML. Papillary carcinoma of the thyroid: a discussion of its several morphologic expressions, with particular emphasis on the follicular variant. *Am J Surg Pathol*. 1983;7(8):809-817.
9. Chan JK. Strict criteria should be applied in the diagnosis of encapsulated follicular variant of papillary thyroid carcinoma. *Am J Clin Pathol*. 2002;117(1):16-18.
10. Lloyd RV, Erickson LA, Casey MB, et al. Observer variation in the diagnosis of follicular variant of papillary thyroid carcinoma. *Am J Surg Pathol*. 2004;28(10):1336-1340.
11. Liu J, Singh B, Tallini G, et al. Follicular variant of papillary thyroid carcinoma: a clinicopathologic study of a problematic entity. *Cancer*. 2006;107(6):1255-1264.
12. Rivera M, Ricarte-Filho J, Knauf J, et al. Molecular genotyping of papillary thyroid carcinoma follicular variant according to its histological subtypes (encapsulated vs infiltrative) reveals distinct *BRAF* and *RAS* mutation patterns. *Mod Pathol*. 2010;23(9):1191-1200.
13. Sobrinho-Simões M, Soares J, Carneiro F, Limbert E. Diffuse follicular variant of papillary carcinoma of the thyroid: report of eight cases of a distinct aggressive type of hyroid tumor. *Surg Pathol*. 1990;3(theme issue):189-203.
14. Ivanova R, Soares P, Castro P, Sobrinho-Simões M. Diffuse (or multinodular) follicular variant of papillary thyroid carcinoma: a clinicopathologic and immunohistochemical analysis of ten cases of an aggressive form of differentiated thyroid carcinoma. *Virchows Arch*. 2002;440(4):418-424.
15. Cooper DS, Doherty GM, Haugen BR, et al; American Thyroid Association (ATA) Guidelines Taskforce on Thyroid Nodules and Differentiated Thyroid Cancer. Revised American Thyroid Association management guidelines for patients with thyroid nodules and differentiated thyroid cancer. *Thyroid*. 2009;19(11):1167-1214.
16. Vasko V, Ferrand M, Di Cristofaro J, Carayon P, Henry JF, de Micco C. Specific pattern of *RAS* oncogene mutations in follicular thyroid tumors. *J Clin Endocrinol Metab*. 2003;88(6):2745-2752.
17. Xu L, Zhou JL, Cohen M, Bar-Sagi D, Patel KN. *Spry2* expression correlates with *BRAF* mutation in thyroid cancer. *Surgery*. 2010;148(6):1282-1287.
18. Zhu Z, Gandhi M, Nikiforova MN, Fischer AH, Nikiforov YE. Molecular profile and clinical-pathologic features of the follicular variant of papillary thyroid carcinoma: an unusually high prevalence of *ras* mutations. *Am J Clin Pathol*. 2003;120(1):71-77.

©2012 American Medical Association. All rights reserved.
Downloaded From: http://jamanetwork.com/ on 06/20/2013