Image of the Month

Lawrence Huan, BS; Bernard M. Jaffe, MD; Emad Kandil, MD

A 21-YEAR-OLD MAN HAD A 2-YEAR HISTORY of persistent hypertension, poorly controlled with doxazosin mesylate and nicardipine hydrochloride. He reported episodic diaphoresis and headaches at rest on a daily basis. The patient was otherwise healthy with no neurological symptoms, palpitations, constipation, abdominal pain, or other gastrointestinal complaints. He also denied fever, weight loss, cough, hemoptysis, bone pain, or other symptoms suggestive of metastatic disease. His physical examination was normal and he had no palpable neck masses. His plasma electrolyte levels and urinalysis results were normal during routine visits to his primary care physician. He had a normal electrocardiograph and no apparent cardiac anomalies.

The patient's laboratory workup included normal plasma aldosterone (5.9 ng/dL; normal, <21 ng/dL) and renin (2.0 ng/mL; normal, 1.9-3.7 ng/mL) levels. His free plasma metanephrine level was shown to be elevated (2.92 nmol/L; normal, <0.89 nmol/L). His 24-hour urine catecholamine excretion rate revealed elevated norepinephrine (501 µg/24 h; normal, 15-80 µg/24 h) but normal dopamine (327 µg/24 h; normal, 65-400 µg/24 h) and epinephrine (12 µg; normal, <20.0 µg) levels. His plasma catecholamine level showed normal dopamine (37 pg/mL [to convert to picomoles per liter, multiply by 6.528]; normal, <142 pg/mL) and epinephrine (43 pg/mL [to convert to picomoles per liter, multiply by 5.459]; normal, <99 pg/mL) levels with an elevated level of norepinephrine (2560 pg/mL [to convert to picomoles per liter, multiply by 5.911]; normal, <142 pg/mL). Iodine 123–labeled metaiodobenzylguanidine scintigraphy (**Figure 1**) and computed tomographic scan of the abdomen and pelvis (**Figure 2**) were performed.

Author Affiliations: Department of Surgery, Tulane University School of Medicine, New Orleans, Louisiana.

What Is the Diagnosis?

A. Metastatic adrenal pheochromocytoma
B. Paraganglioma
C. Ganglioneuroma
D. Glomus tumor

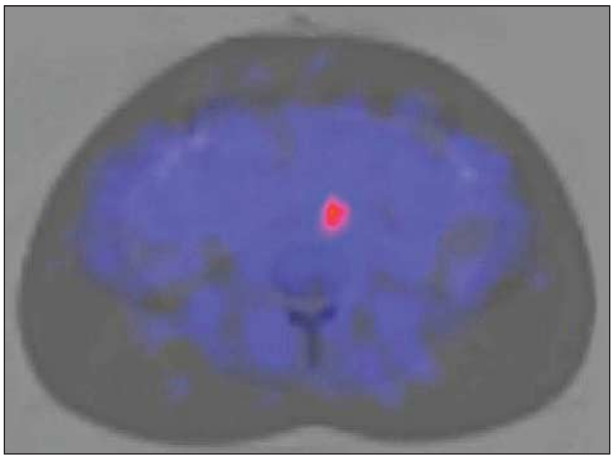

Figure 1. Metaiodobenzylguanidine scintigraphy showing increased uptake in the region of the aortic bifurcation.

Figure 2. Computed tomographic scan cut of the abdomen with a 2.5-cm mass adjacent to the aorta, immediately inferior to the origin of the inferior mesenteric artery (IMA).

©2011 American Medical Association. All rights reserved.
Downloaded From: http://jamanetwork.com/ on 05/24/2013