Image of the Month

Stephen J. Huddleston, MD, PhD; Ying Wei Lum, MD; James H. Black III, MD; Avedis Meneshian, MD

A 73-YEAR-OLD MAN PRESENTED WITH HEMOPtysis after undergoing left-sided video-assisted thoracoscopic surgery (VATS) with evacuation of hematoma and decortication. The patient had a history of endovascular abdominal aortic aneurysm repair complicated by a type II endoleak requiring endovascular embolization of an ascending lumbar artery branch and the inferior mesenteric artery. The patient subsequently developed a descending thoracic aortic intramural hematoma that was managed medically. However, 1 week later, he returned with an acute type B aortic dissection and contained rupture with hemothorax on the left side. On postoperative day 5, after thoracic endovascular aortic replacement, he was returned to the operating room for left-sided VATS decortication. After an uneventful postoperative course, he was discharged from the hospital, but he returned 6 days later with syncope and hypotension. An intravenous contrast-enhanced computed tomograph demonstrated a recurrent hemothorax on the left side. Aortography was performed with endovascular stent graft placement from the distal aspect of the previous descending aortic stent graft to the celiac artery. Completion aortography demonstrated no extravasation of contrast, and left-sided VATS evacuation of hematoma and decortication was performed again 4 days later. The patient had an uneventful postoperative course and was discharged from the hospital on postoperative day 7. He returned 9 days later with 2 episodes of hemoptysis, normal vital signs, and a hemoglobin level of 9.2 g/dL (to convert hemoglobin to grams per liter, multiply by 10.0). Computed tomography demonstrated a 3.0 × 2.5-cm hyperdense collection in the left lateral lung likely in the superior segment of the lower lobe adjacent to the fissure (**Figure 1**). The density enhanced with the blood pool and did not change between arterial and delayed images. Surrounding hyperdense clot suggested recent hemorrhage.

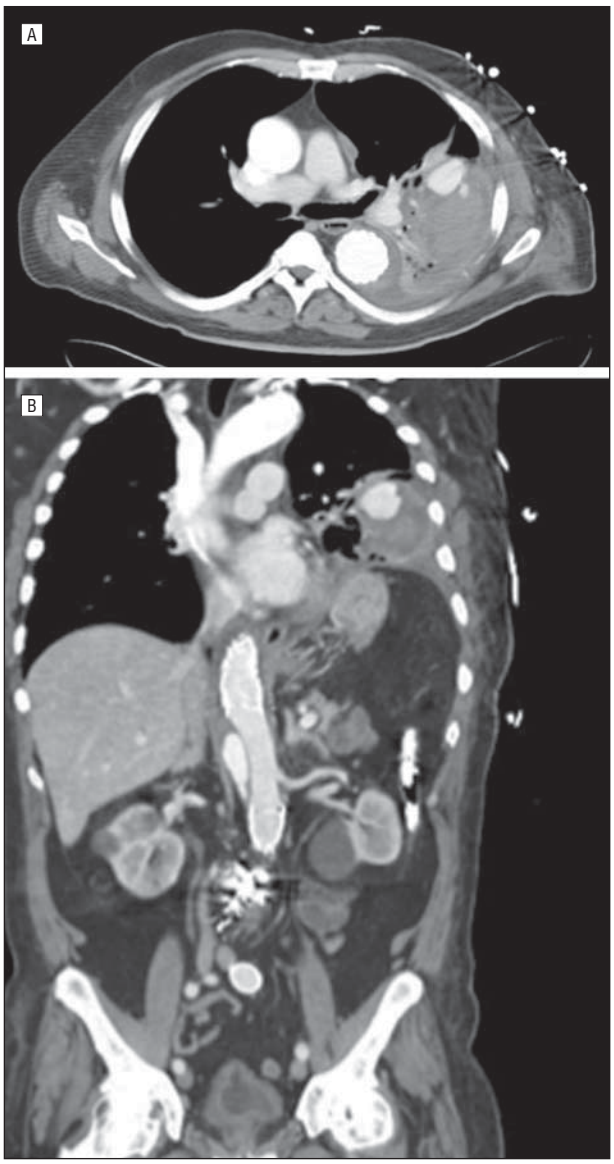

Figure 1. Axial (A) and coronal (B) images of computed tomographs of the chest demonstrating a 3.0 × 2.5-cm hyperdense lesion in the superior segment of the left lung.

What Is the Diagnosis?

A. Bronchial artery hemorrhage
B. Pulmonary artery pseudoaneurysm
C. Type II endoleak
D. Aortopulmonary collateral vessel

Author Affiliations: Divisions of Cardiac Surgery (Dr Huddleston), Vascular Surgery (Drs Wei Lum and Black), and Thoracic Surgery (Dr Meneshian), Department of Surgery, The Johns Hopkins Hospital, Baltimore, Maryland.

©2011 American Medical Association. All rights reserved.
Downloaded From: http://jamanetwork.com/ on 06/19/2013