ORIGINAL ARTICLE

Spectrum of Thoracic Outlet Syndrome Presentation in Adolescents

Kevin Chang, BA; Emma Graf; Kylie Davis; Jasmine Demos, CRNP; Taylor Roethle; Julie Ann Freischlag, MD

Objective: To study the outcomes of children with thoracic outlet syndrome (TOS) treated surgically with transaxillary first-rib resection and scalenectomy (FRRS).

Design: A retrospective database review.

Setting: The Johns Hopkins Medical Institutions.

Patients: Patients 18 years or younger who had undergone FRRS.

Interventions: All patients underwent FRRS. Patients with venous TOS underwent venography 2 weeks postoperatively.

Main Outcomes Measures: For patients with venous TOS, good outcomes included patent subclavian veins. For patients with neurogenic and arterial TOS, good outcomes included relief of pain and discomfort.

Results: Thirty-five adolescents, including 14 male and 21 female patients, presented with TOS. Of these, 18 had venous symptoms, 9 had neurogenic symptoms, and 8 had arterial symptoms. Seventeen of the 18 patients with venous TOS had thrombosis. At postoperative venography, 13 patients required dilation of a stenotic vein, 2 had patent veins, and 2 had chronically occluded veins. All 18 patients had patent veins, but 1 had persistent ipsilateral neurogenic symptoms. Physical therapy before FRRS had failed in all 9 patients with neurogenic TOS. Five of the 8 patients with arterial TOS presented with abnormal ribs. Two had episodes of embolization, and 1 had an occluded radial artery. None had an axillosubclavian aneurysm. All 8 patients underwent FRRS; 3 also required removal of the fused cervical rib. All 35 patients had a favorable follow-up period.

Conclusions: Adolescents present more frequently with venous and arterial TOS than do adults. However, in nearly all adolescent patients, treatment with FRRS leads to a rapid return to full activity.

Arch Surg. 2011;146(12):1383-1387

Thoracic outlet syndrome (TOS) is a rare clinical disorder that can manifest with neurogenic, venous, or arterial symptoms. Treatment algorithms are complex and controversial, especially in the neurogenic form, and the diagnosis and treatment can be particularly difficult in children. The outcomes in patients with TOS have typically been studied in adults. However, more adolescents are being diagnosed as having TOS and are being referred for treatment options. We believe that there is a need to better understand the presentations and outcomes in the adolescent population.

See Invited Critique at end of article

In our practice, adolescents with TOS present in a number of ways. Adolescent patients with venous TOS can present with subclavian vein thrombosis, most frequently as an acute episode of unilateral arm swelling and discoloration. These symptoms are predominantly associated with a history of vigorous physical activity but can also be associated with an underlying hypercoagulable disorder.[1,2] Adolescent patients with neurogenic TOS can present with pain and numbness caused by compression of the brachial plexus by the anterior scalene muscle, the first rib, or anomalous fibrous bands.[1] The anatomical compression is often a result of trauma or repetitive motion injuries.[1] Arterial TOS is rare, and patients often present with acute or chronic ischemia of the arm. Adolescent patients have a high prevalence of bony abnormalities, such as cervical or rudimentary ribs, similar to those seen in adults with arterial TOS.[3]

It was the purpose of this study to report our experience with 35 adolescent patients who presented to us with symp-

Author Affiliations: Department of Surgery, The Johns Hopkins University School of Medicine, Baltimore, Maryland.

©2011 American Medical Association. All rights reserved.
Downloaded From: http://jamanetwork.com/ on 06/19/2013

toms of venous, neurogenic, or arterial TOS and underwent transaxillary first-rib resection and scalenectomy (FRRS) as part of the treatment plan.

METHODS

DATA SOURCE

A retrospective review of a prospectively acquired database was performed. Patient data for the adolescent patients were compiled from December 1, 2004, through May 30, 2010. This database has institutional review board approval to follow the outcomes of patients undergoing FRRS at The Johns Hopkins Medical Institutions. The database includes demographics, initial presentation, trauma or repetitive activity history, hypercoagulable workup, previous therapies, postoperative complications, and follow-up information on the 35 adolescent patients, 18 years or younger, who had undergone transaxillary FRRS for treatment of TOS. This prospective database is maintained by The Johns Hopkins Department of Vascular and Endovascular Surgery. Additional information was obtained from the electronic medical record.

PATIENT SELECTION CRITERIA

Patients were included in this study if they were 18 years or younger and if they returned for regular follow-up after FRRS. Patients were diagnosed as having venous and arterial TOS using duplex scans and the presence of symptoms consistent with compression, thrombosis, or ischemia. Patients were diagnosed as having neurogenic TOS if they had symptoms of prolonged pain, weakness, numbness, or tingling in the neck, shoulder, or arm and had a history of trauma and repetitive motion injury or if they experienced symptomatic relief with scalene block with lidocaine hydrochloride.

SURGICAL MANAGEMENT

Patients referred to our institution with venous and arterial TOS all underwent preoperative duplex scanning but received no interventions before FRRS. Patients with neurogenic TOS underwent at least 8 weeks of physical therapy before consideration for FRRS. All patients underwent FRRS through a transaxillary approach. Patients with venous TOS underwent venography at 2 weeks postoperatively to assess the patency of the subclavian vein. Those with greater than 50% stenosis underwent balloon dilation and anticoagulation therapy, those with chronic occlusion received anticoagulation therapy consisting of warfarin sodium alone, and those with patent veins (<50% stenosis) received no further interventions. All patients also received postoperative physical therapy. Follow-up included clinic visits at 1, 3, and 6 months and 1 and 2 years postoperatively. In addition to an assessment of symptoms in all patients, follow-up testing for patients with venous or arterial symptoms included duplex scans at all postoperative visits to assess flow velocity and vessel patency.

RESULTS

Review of the database revealed 35 adolescents who had undergone transaxillary FRRS at 18 years or younger, including 14 male and 21 female patients. Two patients had contralateral first ribs removed prophylactically owing to subclavian vein compression while they were still younger than 18 years. Therefore, a total of 37 FRRS operations were performed in 35 adolescent patients. The mean age at the time of operation was 16.5 (range, 10-18) years.

VENOUS TOS

Subclavian vein thrombosis or compression was the most common presentation in our group of adolescent patients referred for FRRS. We treated 10 female and 8 male patients with venous TOS with a mean age of 16.8 (range, 10-18) years. For many of these patients, high-intensity athletics, including swimming, hockey, soccer, football, basketball, baseball, and weight training, or repetitive motion activities, including prolonged computer use and daily outdoor chores such as raking leaves, were implicated as the cause of their symptoms. In addition, 3 adolescent patients had documented hypercoagulable disorders, 2 patients had factor V Leiden, and 1 patient had protein S deficiency, which likely contributed to the development of symptoms. Among the patients with no history of high-intensity athletics or prolonged repetitive motion activities, 7 underwent testing for clotting disorders; the results were negative.

At local hospitals before referral, 9 patients received thrombolysis at the time of the initial thrombosis and 1 patient underwent a mechanical thrombectomy during an initial venogram. The other 7 patients with thrombosis received only anticoagulation without venography or thrombolysis. One patient did not have thrombosis but had mottling of the arm with activity and received no intervention before referral. Of the 17 patients with thrombosis, 4 had a pulmonary embolism as part of their initial presentation at local hospitals. None of these 4 patients were found to have hypercoagulable disorders or additional thrombi.

All 18 patients who presented with venous TOS underwent transaxillary FRRS. Patients were symptomatic for a mean of 3 months (range, 2 days to 2 years) before the operation. For patients who underwent thrombolysis or thrombectomy at local hospitals, there was a mean of 4 months (range, 2 days to 2 years) from the preoperative intervention to FRRS. No postoperative complications of pneumothorax, bleeding, or nerve injury occurred. All 18 patients underwent venography at 2 weeks postoperatively as per our protocol. The venograms showed that 13 subclavian veins had greater than 50% stenosis and required balloon dilation (**Figure 1**). These 13 patients subsequently received warfarin therapy for a mean of 3.5 (range, 0-8) months. One of these patients has protein S deficiency and will receive lifelong anticoagulation therapy. Three patients had widely patent subclavian veins and 2 had chronically occluded veins (verified by venography). One patient with a chronically occluded subclavian vein experienced recanalization at 4 months postoperatively while receiving warfarin therapy (noted on a duplex scan). The other patient with a chronically occluded vein did not experience recanalization while receiving anticoagulation therapy. The second patient has factor V deficiency and is being treated with lifelong warfarin therapy but experiences no pain, swelling, or discoloration of the affected arm.

To prevent thrombosis, 2 patients with venous thrombosis underwent contralateral FRRS, 1 year after ipsilat-

©2011 American Medical Association. All rights reserved.
Downloaded From: http://jamanetwork.com/ on 06/19/2013

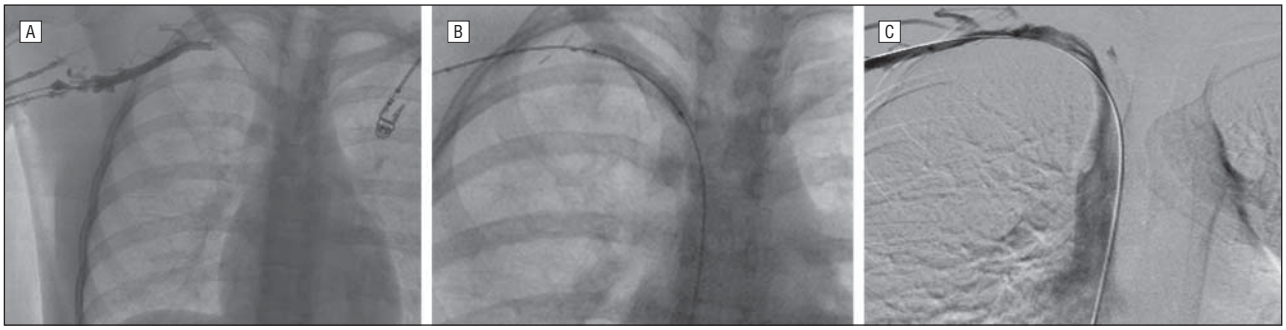

Figure 1. Postoperative venograms in 3 patients with venous thoracic outlet syndrome. A, A patient with subclavian vein stenosis. B, A patient undergoing dilation for a stenotic right subclavian vein. C, A patient with a patent subclavian vein immediately after dilation by means of balloon angioplasty.

eral FRRS, for subclavian vein compression (confirmed by a duplex scan). Venography was performed 2 weeks postoperatively and demonstrated widely patent veins.

All patients with venous TOS underwent a course of physical therapy for 2 to 6 weeks after their operation. Mean follow-up for these 18 patients with 20 first-rib resections was 22.5 (range, 2-73) months. All veins were patent on follow-up duplex scans except for 1 that remains chronically occluded. One patient, who now has a patent vein but had neurogenic and venous symptoms before the operation, continues to have persistent neurogenic symptoms ipsilateral to the FRRS and is being treated conservatively with physical therapy and pain management. All other patients with venous TOS treated with FRRS are asymptomatic and have had no recurrence of swelling, discoloration, or pain in the affected arm.

NEUROGENIC TOS

Nine adolescents, including 8 female patients and 1 male patient with a mean age of 15 (range, 13-18) years, had neurogenic TOS. Seven patients were involved in physical activities, including swimming, soccer, basketball, volleyball, lacrosse, and baseball, whereas 2 were avid violin players. One patient had a cervical rib fused to the first rib, visible on a chest radiograph. Two patients were homeschooled because of debilitating pain that prevented them from engaging in normal activities at school. None of the 9 patients responded to initial management with physical therapy. Surgical treatment was indicated because of persistent symptoms of pain, tingling, and weakness in the affected arm and neck; the inability to perform overhead activities; and tenderness of the scalene muscles. Three patients underwent a preoperative anterior scalene block with lidocaine to determine whether surgical treatment was the most effective intervention. All 3 had relief of symptoms with lidocaine block. The other 6 patients did not receive scalene blocks because they had histories of trauma or repetitive motion injuries and had symptoms of pain, numbness, and weakness in their arm, neck, and shoulder in a distribution characteristic of neurogenic TOS. With a combination of history and physical findings consistent with neurogenic TOS, we had a high diagnostic suspicion and were comfortable proceeding with FRRS without an additional invasive procedure, lidocaine block, for diagnosis. Patients were symptomatic for a mean of 15 (range, 7-24) months before the operation, a delay in surgical management largely secondary to late referrals after failed courses of pain management. All 9 patients underwent FRRS. There were no postoperative complications except for a small pneumothorax in one patient that required placement of a chest tube overnight. All patients underwent 8 to 12 weeks of physical therapy after FRRS. All patients had relief from neurogenic symptoms and regained strength and range of motion during the follow-up period, a mean of 15 (range, 8-27) months. All 9 patients returned to baseline physical activity during the follow-up period. The 2 patients who had been homeschooled because of pain and discomfort had significant relief of symptoms and returned to school after physical therapy.

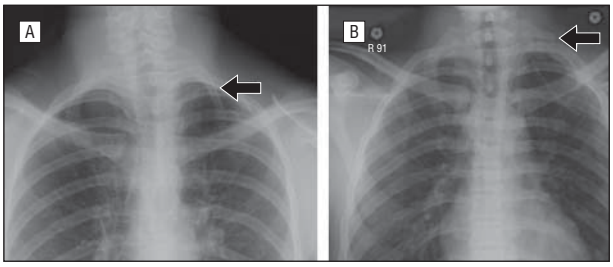

Figure 2. Preoperative chest radiographs of 2 patients with arterial thoracic outlet syndrome. A, A patient with a cervical rib fused to the first rib (arrow). B, A rudimentary rib (arrow).

ARTERIAL TOS

Eight adolescents, including 3 female and 5 male patients with a mean age of 16 (range, 12-18) years, presented with arterial TOS and symptoms of pain, weakness, and discoloration of the affected arm consistent with arterial compression and ischemia. At initial presentation to local hospitals, 2 patients had probable episodes of arterial embolization, as evidenced by symptoms of ischemia, and 1 of the 2 patients had a nonpalpable radial pulse as a result. After presentation, we noted that 3 patients had cervical ribs and 2 patients had rudimentary ribs (visible on chest radiographs; **Figure 2**). One patient had dual compression of the artery and vein (verified by a duplex scan). Patients were symptomatic for a mean of 12 months (range, 2 days to 9 years) before the operation. All 8 patients underwent FRRS, and the 3 patients with cervical ribs fused to the first rib had both ribs

©2011 American Medical Association. All rights reserved.
Downloaded From: http://jamanetwork.com/ on 06/19/2013

removed during FRRS. No patient had an axillosubclavian aneurysm (verified by duplex scanning or other imaging), and no patient required arterial replacement. Postoperatively, 4 patients had small pneumothoraces requiring a chest tube to be placed overnight. In the patient with dual compression of the artery and vein, the subclavian vein thrombosed postoperatively and the patient received anticoagulation therapy. The vein was patent at 3 months postoperatively, as seen on a duplex scan. Patients were followed up for a mean of 5 (range, 1-12) months, and all 8 patients had resolution of arterial symptoms without recurrence during the follow-up period.

COMMENT

Recently, a few series[3-6] have documented surgical treatment of TOS in children. Before these studies, only case reports were available in the literature.[7-16] These case reports emphasized the unusual anatomy found in some children presenting with TOS, including abnormal first ribs, cervical ribs, fractured ribs, and abnormal tendon insertions. Those reports emphasized the need for chest radiography in adolescent patients to identify those with unusual ribs. Six of our patients had similar anomalies, including 4 cervical ribs fused to the first rib and 2 rudimentary ribs, both causing arterial compromise.

In the past decade, the reported series of children with TOS describe patients with similar presentations who have undergone treatments similar to those received by the patients in our series. These reports also observed that vascular presentations are more common in children than in adults. In a report from 2003, Vercellio and colleagues[4] treated 8 children with TOS between 1998 and 2003. Of the 4 boys and 4 girls, 6 patients had venous thrombosis and 2 had neurogenic symptoms. No patient had arterial compromise. A cervical rib was noted in 1 patient with neurogenic TOS. Eighteen months after presentation, 6 of the 7 patients who underwent surgery were asymptomatic and 1 had subclavian vein rethrombosis and edema of the arm. One patient was not treated surgically because she was thought to have Klippel-Trénaunay syndrome.

Arthur and colleagues[3] reported on their series of 25 adolescent patients treated between 1993 and 2005. Their patient population consisted of 18 girls (72%) with a mean age of 15.3 years. In addition, 13 of their patients (52%) presented with venous (11 patients) or arterial (2 patients) complications of TOS. Four patients in their series had cervical ribs; these were removed during surgery in 2 patients and left in the other 2 because the ribs were small and did not contribute to compression.

Maru and colleagues[5] described 12 adolescent patients treated between 1994 and 2006. Similarly, 8 patients (67%) were girls, and 8 patients (67%) had venous thrombosis or arterial compromise as their presenting symptom. Three patients had cervical ribs, including 1 with bilateral cervical ribs, and the cervical ribs were resected along with the first rib in all 3 patients.

In another group of teenagers described by Rigberg and Gelabert,[6] 18 patients were treated surgically for TOS between 1994 and 2005. Their patient population consisted of predominantly female patients (15 patients [85%]). Furthermore, 12 of the 18 patients had neurogenic symptoms and only 6 had venous thrombosis. No patient presented with arterial compromise. One patient with venous TOS had a cervical rib. This distribution of predominantly neurogenic symptoms is uncommon and could be attributed to the older age (13-19 years) of the population studied. We also had a similar predominance of female patients (21 of the 35 patients [60%]). This may be explained by the smaller thoracic outlet seen in young women. However, our series demonstrated a higher incidence of venous and arterial TOS in adolescent patients (26 of the 35 patients [74%]).

The most frequently used operative approach in children and adolescents has been the transaxillary approach, which is the method we used in all 35 of our patients and 37 operations. We were also able to resect the fused cervical rib by using this approach. Maru and colleagues[5] primarily used the supraclavicular approach for their patients. One patient in that group had a subclavian aneurysm that had to be resected and replaced. Complications were few in all the reported series, and patients demonstrated good results.

Stansby and Lambert[17] have previously emphasized that adolescent patients need to "earn their surgery." In other words, surgical intervention in children should be performed for relief of symptoms. However, 1 year after their first FRRS, we performed contralateral, prophylactic FRRS on 2 patients who were asymptomatic on the contralateral side because their physical activities placed them at high risk for subclavian vein thrombosis and their duplex scans showed markedly decreased flow velocity in the subclavian vein in abduction. No studies to date have commented on the efficacy of prophylactic first-rib resection. We believe that patients who have had previous effort thrombosis and who continue with physical activities that increase their risk for thrombosis should be treated proactively with surgery, especially if they have had a favorable outcome of their first FRRS. In the setting of high-risk activities, we use decreased flow velocity on a duplex scan in arm abduction as a sign of compression of the vein, which is the insult that leads to effort thrombosis. Waiting 1 year for contralateral FRRS allows the patient to recover function of the ipsilateral arm and allows us to accurately assess the long-term outcome of the first operation. We had 2 additional patients who did not receive contralateral FRRS and were not included in this study; they had decreased flow in the contralateral arm and thrombosis of their contralateral subclavian vein at 1 year and 5 years after ipsilateral FRRS. However, without literature supporting prophylactic first-rib resection or outcomes data in a large cohort of patients who have undergone prophylactic FRRS, we agree with Stansby and Lambert[17] that FRRS should generally be reserved for symptom relief. Thus, we use prophylactic resection sparingly and only in high-risk patients with evidence of compression. Although both of our patients who received prophylactic FRRS had favorable outcomes and continued with high-intensity physical activity without complications, further evidence is needed before a conclusion can be drawn concerning the utility of prophylactic FRRS.

©2011 American Medical Association. All rights reserved.
Downloaded From: http://jamanetwork.com/ on 06/19/2013

CONCLUSIONS

We find that adolescents with TOS present more frequently with venous and arterial symptoms than do adults with TOS. In the adolescent who presents with venous thrombosis, our adult venous thrombosis protocol—FRRS and postoperative venography at 2 weeks with possible balloon dilation or anticoagulation therapy—allows for rapid resolution of symptoms and return to baseline activity levels. The adolescents with arterial TOS should be treated aggressively, as in the adult patient, to prevent complications such as axillosubclavian aneurysms from developing later. We also find that the adolescent with neurogenic TOS should initially be treated conservatively with physical therapy and pain management before undergoing FRRS for symptom relief. However, we find that aggressive surgical management in adolescents with all forms of TOS yields excellent outcomes and a rapid return to normal activity.

Accepted for Publication: June 14, 2011.
Correspondence: Kevin Chang, BA, Department of Surgery, The Johns Hopkins University School of Medicine, 720 Rutland Ave, Ross 759, Baltimore, MD 21205 (kchang29@jhmi.edu).
Author Contributions: *Study concept and design:* Chang, Graf, Davis, Demos, Roethle, and Freischlag. *Acquisition of data:* Chang, Graf, Davis, Demos, Roethle, and Freischlag. *Analysis and interpretation of data:* Chang, Graf, Davis, Demos, Roethle, and Freischlag. *Drafting of the manuscript:* Chang, Graf, Davis, Demos, Roethle, and Freischlag. *Critical revision of the manuscript for important intellectual content:* Chang, Graf, Davis, Demos, Roethle, and Freischlag. *Statistical analysis:* Chang, Graf, Davis, Demos, Roethle, and Freischlag. *Administrative, technical, and material support:* Roethle. *Study supervision:* Chang and Roethle.
Financial Disclosure: None reported.
Disclaimer: Dr Freischlag is the editor of the *Archives of Surgery*. She was not involved in the editorial evaluation or decision to accept this article for publication.
Previous Presentation: This study was presented as a poster at the annual meeting of the Society for Vascular Surgery; June 11-13, 2010; Boston, Massachusetts.

REFERENCES

1. Braun RM. Thoracic outlet syndrome: a primer on objective methods of diagnosis. *J Hand Surg Am*. 2010;35(9):1539-1541.
2. Brandão LR, Williams S, Kahr WH, Ryan C, Temple M, Chan AK. Exercise-induced deep vein thrombosis of the upper extremity, II: a case series in children. *Acta Haematol*. 2006;115(3-4):221-229.
3. Arthur LG, Teich S, Hogan M, Caniano DA, Smead W. Pediatric thoracic outlet syndrome: a disorder with serious vascular complications. *J Pediatr Surg*. 2008;43(6):1089-1094.
4. Vercellio G, Baraldini V, Gatti C, Coletti M, Cipolat L. Thoracic outlet syndrome in paediatrics: clinical presentation, surgical treatment, and outcome in a series of eight children. *J Pediatr Surg*. 2003;38(1):58-61.
5. Maru S, Dosluoglu H, Dryjski M, Cherr G, Curl GR, Harris LM. Thoracic outlet syndrome in children and young adults. *Eur J Vasc Endovasc Surg*. 2009;38(5):560-564.
6. Rigberg DA, Gelabert H. The management of thoracic outlet syndrome in teenaged patients. *Ann Vasc Surg*. 2009;23(3):335-340.
7. Martins RS, Siqueira MG. Cervical rib fracture: an unusual etiology of thoracic outlet syndrome in a child. *Pediatr Neurosurg*. 2007;43(4):293-296.
8. DiFiore JW, Reid JR, Drummond-Webb J. Thoracic outlet syndrome in a child: transaxillary resection of anomalous first rib. *J Pediatr Surg*. 2002;37(8):1220-1222.
9. Reid JR, Morrison SC, DiFiore JW. Thoracic outlet syndrome with subclavian aneurysm in a very young child: the complementary value of MRA and 3D-CT in diagnosis. *Pediatr Radiol*. 2002;32(1):22-24.
10. Ozçakar L, Malas FU, Erol O. A 17-year-old girl with a small left hand: thoracic outlet syndrome is on the agenda. *Clin Pediatr (Phila)*. 2008;47(1):80-82.
11. Lee TS, Hines GL. Cerebral embolic stroke and arm ischemia in a teenager with arterial thoracic outlet syndrome: a case report. *Vasc Endovascular Surg*. 2007;41(3):254-257.
12. Roche-Nagle G, Ryan R, Barry M, Brophy D. Effort thrombosis of the upper extremity in a young sportsman: Paget-Schroetter syndrome. *Br J Sports Med*. 2007;41(8):540-541.
13. Okamoto H, Kawai K, Hattori S, et al. Thoracic outlet syndrome combined with carpal tunnel syndrome and Guyon canal syndrome in a child. *J Orthop Sci*. 2005;10(6):634-640.
14. Cağli K, Ozçakar L, Beyazit M, Sirmali M. Thoracic outlet syndrome in an adolescent with bilateral bifid ribs. *Clin Anat*. 2006;19(6):558-560.
15. Simovitch RW, Bal GK, Basamania CJ. Thoracic outlet syndrome in a competitive baseball player secondary to the anomalous insertion of an atrophic pectoralis minor muscle: a case report. *Am J Sports Med*. 2006;34(6):1016-1019.
16. Dintaman J, Watson C, Fox CJ, Hoover N, Roberts S, Gillespie DL. Case of adolescent with Paget-Schroetter syndrome and underlying thrombophilia due to an elevated lipoprotein (A). *Pediatr Blood Cancer*. 2007;49(7):1036-1038.
17. Stansby G, Lambert D. Thoracic outlet syndrome in children and young adults. *Eur J Vasc Endovasc Surg*. 2009;38(5):565-566.

©2011 American Medical Association. All rights reserved.
Downloaded From: http://jamanetwork.com/ on 06/19/2013