ORIGINAL ARTICLE

Emergent Repair of Acute Thoracic Aortic Catastrophes

A Comparative Analysis

Peter A. Naughton, MD; Michael S. Park, MD; Mark D. Morasch, MD; Heron E. Rodriguez, MD; Manuel Garcia-Toca, MD; C. Edward Wang, PhD; Mark K. Eskandari, MD

Objective: To provide a contemporary institutional comparative analysis of expedient correction of acute catastrophes of the descending thoracic aorta (ACDTA) by traditional direct thoracic aortic repair (DTAR) or thoracic endovascular aortic repair (TEVAR).

Design: Single-center retrospective review (April 2001-January 2010).

Setting: Academic medical center.

Patients: One hundred patients with ACDTA treated with either TEVAR (n=76) or DTAR (n=24). Indications for repair included ruptured degenerative aneurysm (n=41), traumatic transection (n=27), complicated acute type B dissection (n=20), penetrating ulcer (n=4), intramural hematoma (n=3), penetrating injury (n=3), and embolizing lesion (n=2).

Main Outcome Measures: Demographics and 30-day and late outcomes were analyzed using multivariate analysis over a mean follow-up of 33.8 months.

Results: Among the 100 patients, mean (SD) age was 58.5 (17.3) years (range, 18-87 years). Demographics and comorbid conditions were similar between the 2 groups, except more patients in the DTAR group had prior aortic surgery ($P=.02$) and were older ($P=.01$). Overall 30-day mortality was significantly better among the TEVAR group (8% vs 29%; $P=.007$). Incidence of postoperative myocardial infarction, acute renal failure, stroke, and paraplegia/paresis was similar between the 2 treatment groups (TEVAR, 5%, 12%, 8%, and 8% vs DTAR, 13%, 13%, 9%, and 13%, respectively). Major respiratory complications were lower in the TEVAR group (16% vs 48%; $P<.05$). Mean length of hospital stay was also shorter after TEVAR (13.5 vs 16.3 days; $P=.30$). Independent predictors of patient mortality included age ($P=.004$) and DTAR ($P=.001$).

Conclusion: Patients presenting with ACDTA are best treated with TEVAR whenever feasible.

Arch Surg. 2012;147(3):243-249

Acute catastrophes of the descending thoracic aorta (ACDTA) incorporate a heterogenous group of pathologies including complicated acute type B dissection (cTBD), ruptured degenerative aneurysm, and blunt traumatic injury, as well as more uncommon entities such as penetrating ulcers and intramural hematomas.[1-5] The incidence of patients with ACDTA surviving until hospitalization has increased.[6] In most cases, emergency surgical intervention represents the only option to enable survival.[7-9] Traditional direct thoracic aortic repair (DTAR) is a significant surgical challenge and can be associated with mortality rates up to 45% in addition to alarmingly high complications of major morbidity: paraplegia, stroke, cardiac failure, renal failure, and prolonged respiratory compromise.[10,11]

See Invited Critique at end of article

In the elective setting, thoracic endovascular aortic repair (TEVAR) has emerged as a feasible, less invasive alternative to open repair for degenerative aneurysms, penetrating ulcers, and intramural hematomas.[12-14] In the emergency setting, TEVAR is particularly attractive because of the possibility to facilitate expedient control of life-threatening hemorrhage and provision of rapid restoration of end-organ perfusion while obviating the need for a thoracotomy, aortic cross-clamping, single-lung ventilation, and systemic anticoagulation.[15] Several small case series without a comparative cohort have demonstrated early success with this approach for ACDTA.[1-5,16] Typically, cen-

Author Affiliations: Division of Vascular Surgery (Drs Naughton, Park, Morasch, Rodriguez, Garcia-Toca, and Eskandari) and Department of Surgery (Dr Wang), Northwestern University Feinberg School of Medicine, Chicago, Illinois.

©2012 American Medical Association. All rights reserved.
Downloaded From: http://jamanetwork.com/ on 05/21/2013

ters have opted for TEVAR in the acute setting among patients deemed unsuitable or unfit for open repair.[17] We have chosen TEVAR as our preferred approach for most ACDTA over the last several years while phasing out DTAR and, as such, provide a contemporary comparative analysis of the outcomes at a single institution.

METHODS

A retrospective review was conducted of all patients who underwent open and endovascular intervention for ACDTA between April 2001 and January 2010 at Northwestern Memorial Hospital, Chicago, Illinois. Emergency procedures were defined as those performed within 24 hours of presentation. Indication for intervention included ruptured degenerative aneurysm (n=41); blunt traumatic transection (n=27); cTBD with end-organ ischemia, large pseudoaneurysm, and/or intractable pain (n=20); symptomatic penetrating ulcer (n=4); symptomatic intramural hematoma (n=3); penetrating injury (n=3); and embolizing lesion (n=2). During this period, a total of 169 patients underwent TEVAR, of which 76 (45%) had ACDTA. A total of 24 patients underwent DTAR for ACDTA. Data collection was performed according to approved institutional review board protocols.

THORACIC ENDOVASCULAR AORTIC REPAIR

All patients underwent computed tomography angiogram to assess suitability for TEVAR. Thoracic endovascular aortic repair was performed as previously described.[18,19] Endovascular procedures were completed in a fully functional operating angiosuite equipped with a fixed fluoroscopic unit (Allura Xper FD20; Philips). All procedures were performed under general anesthesia. Access was achieved via either traditional femoral arterial open exposure in 32 patients (42%), entirely percutaneous access using the suture-mediated closure "preclose" technique in 38 patients (50%), or open iliac artery conduit in 6 patients (8%).[20] Prophylactic lumbar spinal drains were placed in 12 patients (16%) for indications previously outlined.[21] Intravascular ultrasonography was frequently used intraoperatively among patients with cTBD to differentiate the true and false lumens as well as to identify aortic side branch patency.[22]

Implanted stent graft devices included the GORE TAG stent grafts (n=41) (W. L. Gore & Associates), Excluder proximal aortic extension cuffs (n=25) (W. L. Gore & Associates), AneuRx proximal aortic extension cuffs (n=1) (Medtronic), Talent thoracic stent grafts (n=1) (Medtronic), or custom-made stent grafts (n=8) constructed of 5-cm-long stents (Cook-Z stents; Cook Medical) covered with ironed woven fabric (Cooley Veri-Soft; Boston Scientific Corp) delivered via a 22F delivery system.[21] During our initial experience involving patients who received custom-made devices, brief adenosine-induced cardiac arrest was used to assist accurate proximal stent graft deployment.[21] This technique was abandoned with commercially manufactured stent grafts.

DIRECT THORACIC AORTIC REPAIR

On transfer to the operating room, a double-lumen endotracheal intubation was performed. Access to the descending thoracic aorta was achieved via a left posterolateral thoracotomy through the fifth intercostal space. All open thoracic aortic repairs were performed with left heart bypass assistance and full-dose systemic anticoagulation.

FOLLOW-UP PROTOCOL

All patients had an initial stay in the intensive care unit until they were deemed suitable for discharge to the regular ward. Major stroke was defined as any central neurological deficit that persisted beyond 24 hours. Acute renal failure was defined as any increase in the creatinine level greater than 3.0 mg/dL with or without the need for dialysis. Respiratory failure was defined as postoperative pneumonia, prolonged intubation beyond the fifth postoperative day, or need for tracheostomy. Myocardial infarction was defined by at least 2 of the following criteria: typical chest pain lasting 20 minutes or more; serum levels of creatine kinase, creatine kinase MB, or troponin at least twice the upper limit of the normal range; and new Q wave on at least 2 adjacent derivations or predominant R waves in V1 (R wave $\geq$1 mm $>$S wave in V1). All patients treated by TEVAR had clinical examination and computed tomography angiogram at 1 month, 6 months, 1 year, and annually thereafter to evaluate for stent graft migration, collapse, endoleaks, thrombosis of false lumen, regression, or growth of the aneurysmal sac. Patients who underwent DTAR were clinically reevaluated at 1 month, 6 months, and annually.

OUTCOMES

The predefined primary outcome variables compared endovascular and open surgical techniques for mortality, stroke, paraplegia, myocardial infarction, acute renal failure, pulmonary complications, and reintervention.[23] Data for patient characteristics by age, sex, race, chronic obstructive pulmonary disease, chronic renal disease, diabetes mellitus, history of myocardial infarction, malignancy, peripheral vascular disease, and length of stay were also collected for secondary analysis.

STATISTICAL ANALYSES

Baseline patient characteristics and postoperative outcomes between the DTAR and TEVAR groups were compared using the 2-sample *t* test for continuous variables and the χ^2 or Fisher exact test (for small sample sizes or highly imbalanced table cells) for categorical data. Data were summarized using descriptive statistics (eg, means and standard deviation for continuous variables; count and frequency for categorical variables). Kaplan-Meier survival curves were fitted for the open thoracic aorta repair (DTAR) and TEVAR cohorts and patient survival was compared using the log-rank test. Multivariate Cox proportional hazards models were conducted to identify independent risk factors of postoperative mortality. The hazard ratio estimates were based on simultaneous analysis of all predicated variables. Assumption of proportionality was tested using a log-minus-log plot and was met. Statistical significance was determined at an α level of .05. All statistical analyses were conducted using SAS version 9.2 (SAS Institute Inc).

RESULTS

DEMOGRAPHICS

Among the 100 patients, mean (SD) age was 58.5 (17.3) years (range, 18-87 years) and 63% were men. Demographics and comorbid conditions were similar between the TEVAR and DTAR groups, except more patients in the DTAR group had prior aortic surgery (P=.02) and were older (P=.01) (**Table 1**).

©2012 American Medical Association. All rights reserved.
Downloaded From: http://jamanetwork.com/ on 05/21/2013

Table 1. Sample Characteristics (Including All Patients)

Patient Characteristic	No. (%) Total (N = 100)	DTAR (n = 24)	TEVAR (n = 76)	*P* Value
Age, y, mean (SD)	58.5 (17.3)	66.7 (14.9)	55.9 (18.3)	.01[a,b]
Male	63 (63)	14 (58)	49 (64)	.59[c]
Prior aortic surgery	16 (16)	8 (33)	8 (11)	.02[b,c]
COPD	12 (12)	3 (13)	9 (12)	>.99[c]
Hypertension	7 (7)	2 (8)	5 (7)	.67[c]
Diabetes mellitus	10 (10)	4 (17)	6 (8)	.25[c]
Smoking	52 (52)	12 (50)	40 (53)	.82[c]
Intraoperative complication	21 (21)	4 (17)	17 (22)	.55[c]

Abbreviations: COPD, chronic obstructive pulmonary disease; DTAR, direct thoracic aortic repair; TEVAR, thoracic endovascular aortic repair.
[a] *t* Test.
[b] Significant.
[c] χ^2 Test or Fisher exact test.

Table 2. Postoperative Outcomes (Including All Patients)

Postoperative Variable	No. (%) Total (N = 100)	DTAR (n = 24)	TEVAR (n = 76)	*P* Value
Length of stay, d, mean (SD)	14.2 (11.2)	16.3 (12.7)	13.5 (10.7)	.30[a]
In-hospital complication				
Stroke	8 (8)	2 (9)	6 (8)	.86[b]
Spinal ischemia	9 (9)	3 (13)	6 (8)	.43[b]
Myocardial infarction	7 (7)	3 (13)	4 (5)	.35[b]
Acute renal failure	12 (12)	3 (13)	9 (12)	.88[b]
Respiratory	23 (23)	11 (48)	12 (16)	.004[b,c]
Other severe/moderate complications	35 (35)	20 (83)	15 (20)	<.001[b,c]
Reoperation for TAA repair	25 (25)	7 (29)	18 (24)	.59[b]
30-d mortality	13 (13)	7 (29)	6 (8)	.007[b,c]
Total death	37 (37)	16 (67)	21 (28)	.001[b,c]

Abbreviations: DTAR, direct thoracic aortic repair; TAA, thoracic aortic aneurysm; TEVAR, thoracic endovascular aortic repair.
[a] *t* Test.
[b] χ^2 Test or Fisher exact test.
[c] Significant.

PROCEDURAL RESULTS

A total of 76 patients underwent technically successful TEVAR. Endovascular interventions performed included stent graft deployment alone (n=57; 75%); stent graft deployment combined with left subclavian artery revascularization (n=18; 22%); and stent graft deployment and arch repair with elephant trunk (n=1; 1%). An average of 2.2 stent grafts were implanted to treat the underlying pathology. Revascularization of a major arterial vessel was performed at the time of TEVAR in 20 patients: 16 carotid-subclavian artery transpositions, 2 carotid-subclavian artery bypasses, 1 ilioceliac artery bypass, and 1 aortic arch debranching. Following TEVAR for cTBD, 4 patients underwent diagnostic laparoscopy or laparotomy to assess for intestinal ischemia. Two additional patients developed delayed left arm arterial insufficiency 6 months or more after the index procedure, which was corrected with elective left subclavian revascularization.

Among the 24 patients treated with DTAR, only 7 (29%) had a lumbar spinal drain inserted. Open repair was successfully achieved in all patients with a standard interposition prosthetic graft. One patient with a ruptured degenerative aneurysm following cTBD also underwent open fenestration at the time of the index procedure. One patient required a femoral-femoral artery bypass to alleviate acute limb ischemia noted at the conclusion of the DTAR.

IN-HOSPITAL/30-DAY COMPLICATIONS

Postoperative outcomes including morbidity and mortality are outlined in **Table 2**. The incidence of major respiratory complications was higher in the DTAR group (48% vs 16%; $P=.004$). Moderate to severe complications were more common in the DTAR group (83% vs 20%, $P<.001$); in the DTAR group, these complications included bleeding (n=4), wound infection (n=3), sepsis (n=3), limb ischemia (n=2), intestinal ischemia (n=2), deep vein thrombosis (n=1), graft aortic occlusion (n=1), and temporary recurrent laryngeal palsy (n=1). Most importantly, the overall 30-day mortality was substantially less in the TEVAR group as compared with the DTAR group (8% vs 29%; $P=.007$). Patients in the

©2012 American Medical Association. All rights reserved.
Downloaded From: http://jamanetwork.com/ on 05/21/2013

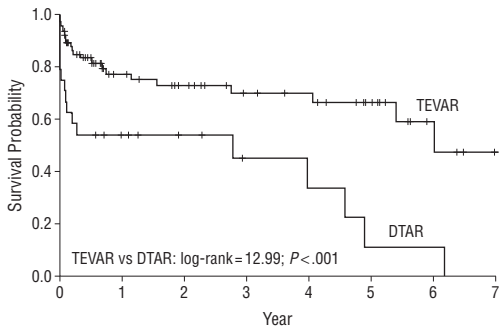

TEVAR (n=7)						
No. at risk	36	29	22	20	13	5
Survival	77.5	73.0	70.0	70.0	66.5	59.1
SE	5.2	5.8	6.3	6.3	6.9	9.3
DTAR (n=24)						
No. at risk	10	7	4	3	1	1
Survival	54.2	54.2	45.1	33.9	11.3	11.3
SE	10.2	10.2	11.8	13.2	10.2	10.2

Figure. Kaplan-Meier patient survival curve, thoracic endovascular aortic repair (TEVAR) vs direct thoracic aortic repair (DTAR).

TEVAR group had significantly higher 1-, 3-, and 5-year survival than the DTAR group (**Figure**).

REINTERVENTION

Nineteen patients (25%) in the TEVAR group required surgical reintervention: 9 procedures were performed during the initial hospitalization and 10, during follow-up (**Table 3**). In total, 13 patients required aortic reintervention, 7 patients were treated by endovascular technique with deployment of additional stent grafts, and 6 patients required conversion to open aortic repair. Indications for endovascular reintervention included persistent type 1a endoleak (n=4), early stent graft collapse and type 1a endoleak (n=2), and type 3 endoleak (n=1). Indications for open reintervention included retrograde type A dissection 5 days post-TEVAR; type 1a endoleak persisting 2 weeks post-TEVAR requiring arch debranching and deployment of additional stent grafts; repair of symptomatic infrarenal abdominal aortic aneurysm; retrograde dissection of the ascending aorta 6 months after TEVAR; abdominal aortic aneurysm repair 6 months after TEVAR; progressive aneurysmal degeneration of a type 4 thoracoabdominal aneurysm following cTBD that required open repair 7 months after TEVAR; and progressive aneurysmal degeneration from the aortic arch to the aortic bifurcation in a patient who 2 years previously underwent TEVAR for cTBD.

Six patients (25%) in the DTAR group required 9 surgical reinterventions. Seven procedures were performed during the initial hospitalization and 2, during follow-up (**Table 4**).

LONG-TERM SURVIVAL

The overall mortality was 67% for DTAR vs 28% for TEVAR ($P=.001$). Patients in the TEVAR group had significantly higher 1-, 3-, and 5-year survival than the DTAR group (Figure). Age and DTAR were independent risk factors for mortality (**Table 5**).

COMMENT

Acute catastrophes of the descending thoracic aorta are a diverse array of life-threatening conditions. Early diagnosis and intervention are crucial to survival. Emergency endovascular intervention is viewed as an appealing alternative to open repair because of the theoretic benefits of expedient hemorrhagic control, avoidance of a thoracotomy, and minimization of systemic anticoagulation.[15] As technological improvements in the development and placement of commercially available TEVAR devices for the treatment of aortic aneurysms have grown, we have transitioned our approach to ACDTA from traditional open repair to endovascular repair.[18,24] This change is based on other case series and our own success over the last decade as demonstrated in this analysis.

While, to our knowledge, no randomized controlled studies have compared open repair with endovascular treatment for ACDTA, encouraging results have been previously reported when choosing TEVAR as a first-line therapy.[1-5] For instance, Cambria et al[1] provided a multicenter review of ACDTA treated with TEVAR as compared with contemporary published results of open repair. They demonstrated early benefits of TEVAR with a combined stroke and 30-day mortality rate of 13.6% vs 29.9% for open repair. Unfortunately, this review was from 14 different institutions over a 2-year period and analyzed 59 patients without a comparative cohort. In the same year, Kaya et al[3] published their results of 113 consecutive patients treated with TEVAR at 7 different European referral centers. Their hospital mortality rate was a respectable 8% with an associated 5% stroke and 1% spinal ischemia rate. In a single-center comparative study of TEVAR with open repair for acute thoracic aortic rupture, Doss et al[16] reported that the perioperative mortality was significantly less in the TEVAR group compared with the patients treated by open repair (3.1% vs 17.8%) (n=60; $P<.05$).

Published data are available to support the early success of TEVAR as a treatment option for each of the different pathologic conditions that ACDTA encompasses. Notable studies demonstrating the benefits of TEVAR for ruptured degenerative aneurysm include Jonker et al,[25] in which a total of 87 patients treated in 7 centers showed a 30-day mortality of 18.4%. Indeed, a meta-analysis of open vs endovascular repair for ruptured degenerative aneurysm was published showing a 19% 30-day mortality for TEVAR compared with 33% for patients treated with open repair.[2] As a treatment option for cTBD, the International Registry of Acute Aortic Dissection reported an in-hospital mortality of 11.6% for patients with cTBD treated by endovascular intervention compared with 33.9% in patients treated by open surgical repair ($P=.002$).[7] Several articles exist purporting the utility of TEVAR for blunt aortic injury.[8,26] We have previously published a comparative meta-analysis of TEVAR vs open surgery for traumatic transection and demonstrated that mortality was significantly lower in the TEVAR group (7.6% vs 15.2%; $P=.008$) as were rates of paraplegia (0% vs 5.6%; $P<.001$) and stroke (0.85% vs 5.3%; $P=.003$).[27] Lastly, Piffaretti et al[28] showed in a series of 11 patients with pen-

©2012 American Medical Association. All rights reserved.
Downloaded From: http://jamanetwork.com/ on 05/21/2013

Table 3. Reinterventions for TEVAR

Patient No.	Interval	Indication for Original TEVAR	Indication for Reintervention	Reintervention
1	1 d	TT	Type 1a endoleak/collapse of TEVAR	Deployment of additional stent graft
2	1 d	RDA	Abdominal compartment syndrome	Laparotomy
3	3 d	cTBD	Neck hematoma	Neck wound exploration, evacuation of hematoma
4	3 d	TT	Ischemic lower limb	Thrombectomy, above-knee amputation
5	5 d	cTBD	Symptomatic retrograde dissection of aortic arch/ascending aorta	Open aortic arch and root repair/replacement
6	6 d	cTBD	Persistent type 1a endoleak/collapse of TEVAR	Deployment of additional stent graft/carotid-subclavian bypass and embolization of left subclavian artery
7	14 d	RDA	Persistent type 1a endoleak	Open aortic arch debranching and TEVAR
8	14 d	cTBD	Symptomatic infrarenal AAA	Open AAA repair
9	16 d	cTBD	Groin lymphocele	Groin wound exploration
10	3 mo	RDA	Type 1a endoleak	Deployment of additional stent graft
11	6 mo	RDA	Ascending thoracic aortic dissection	Open aortic root repair
12	6 mo	IM	Arm ischemia	Subclavian transposition
13	7 mo	cTBD	Symptomatic type 4 thoracoabdominal aneurysm	Open aortic repair
14	8 mo	TT	Subclavian steal	Subclavian transposition
15	9 mo	IM	Type 3 endoleak	Deployment of additional stent graft
16	13 mo	RDA	Type 1a endoleak	Deployment of additional stent graft
17	26 mo	cTBD	Type 1a endoleak	Deployment of additional stent graft
18	36 mo	cTBD	Aneurysmal degeneration of dissected thoracic and abdominal aorta	Open repair of thoracic and abdominal aorta
19	41 mo	cTBD	Type 1a endoleak	Deployment of additional stent graft

Abbreviations: AAA, abdominal aortic aneurysm; cTBD, complicated acute type B dissection; IM, intramural hematoma; RDA, ruptured degenerative aneurysm; TEVAR, thoracic endovascular aortic repair; TT, traumatic transection.

Table 4. Reinterventions for DTAR

Patient No.	Interval	Indication for Original DTAR	Indication for Reintervention	Reintervention
1	1 d	RDA	Bleeding	Laparotomy
2	2 d	RDA	Ischemic bowel	Laparotomy/SMA thromboembolectomy
3	2 d	RDA	Hemorrhage	Thoracotomy
4	3 d	RDA	Lower limb ischemia	Axillobifemoral bypass
5	7 d	RDA	Intestinal ischemia	Laparotomy/SMA thromboembolectomy
6	11 d	cTBD	Wound infection	Thoracotomy/wound washout
7	14 d	RDA	Intestinal ischemia	Laparotomy
8	2 y	cTBD	Graft infection/mycotic aneurysm	Carotid-subclavian transposition and TEVAR
9	4 y	RDA	Aneurysm of ascending thoracic aorta in patient with Marfan syndrome	Aortic root replacement

Abbreviations: cTBD, complicated acute type B dissection; DTAR, direct thoracic aortic repair; RDA, ruptured degenerative aneurysm; SMA, superior mesenteric artery.

etrating ulcers of the thoracic aorta that endovascular intervention is feasible and well tolerated by patients.

This current comparative series showed that TEVAR was associated with a significantly lower 30-day mortality rate as compared with DTAR (7.9% vs 29.2%; $P = .007$). While endovascular intervention offers an appealing alternative to open repair, desirable results can only be achieved by appropriate preoperative planning and technical expertise. Challenges facing endovascular intervention include the following: 2-cm proximal and distal landing zones necessary to achieve fixation and seal; a lack of disease-specific endograft designs enabling flexible delivery with durable seal and attachment; access restrictions; risk of stroke and spinal ischemia; and need for long-term surveillance. In our experience, nearly 25% of patients needed revascularization of a major trunk vessel at the time of TEVAR deployment to facilitate the proximal seal and attenuate the risk of new neurological events, thus adding to the complexity of the procedure. Importantly, with the introduction of commercially available stent grafts, our incidence of new neurological events has decreased. Four of the 8 patients who received custom-made stent grafts experienced stroke or spinal ischemia. This higher stroke risk for the patients receiving custom-made stent grafts is believed to be due to larger, less conformable delivery systems and air entrapment within the

©2012 American Medical Association. All rights reserved.
Downloaded From: http://jamanetwork.com/ on 05/21/2013

Table 5. Cox Regression Model on Patient Mortality (Including All Patients)

Predictor	Hazard Ratio (95% CI)	*P* Value
Group (DTAR vs TEVAR)	3.34 (1.67-6.68)	.001[a]
Age	1.04 (1.01-1.06)	.004[a]
Sex (female vs male)	0.68 (0.34-1.38)	.29
Prior aortic surgery	0.89 (0.37-2.11)	.79
COPD	0.63 (0.22-1.81)	.39
Hypertension	2.25 (0.79-6.41)	.13
Diabetes mellitus	0.48 (0.14-1.64)	.24
Smoking	0.98 (0.50-1.94)	.95
Intraoperative complication	1.19 (0.52-2.71)	.68

Abbreviations: COPD, chronic obstructive pulmonary disease; DTAR, direct thoracic aortic repair; TEVAR, thoracic endovascular aortic repair.
[a] Significant.

constrained stent graft.[29,30] The incidence of spinal ischemia (8%) in the TEVAR group was high. Certain risk factors for spinal ischemia existed in these 6 patients: 2 had custom-made stent grafts deployed, 1 patient with ruptured descending thoracic aneurysm presented cardiovascularly unstable and was noted to be paraplegic on presentation, and 2 patients had a prior open abdominal aortic aneurysm. Despite our policy for a low threshold to prophylactically insert lumbar drains and left subclavian revascularization in addition to establishing relative hypertension postoperatively to facilitate spinal perfusion, our incidence was higher than registry-based studies.[1-3] Similar to Doss et al,[16] this study also demonstrates the major shortcoming of TEVAR: 25% of TEVAR patients required reintervention.

This study has several limitations. First, ACDTA are a diverse group of pathologies and each condition has specific issues that need to be considered at the time of initial management and intervention. Patients with traumatic transection are typically younger patients with significant concomitant injuries. In consideration of these characteristics, our policy is to avoid full intraoperative anticoagulation and excessive oversizing of stent grafts. Garcia-Toca et al[8] previously reported that 84% of traumatic transection patients treated by TEVAR did not require systemic intraoperative anticoagulation. This approach allows a more timely treatment of aortic injury in patients with associated head injury or other sites of potential bleeding. Alternatively, cTBD affects older patients and treatment is aimed not only at preventing exsanguination from the aortic injury but also at enabling rapid reversal of organ malperfusion.[11] Even within this group of patients, our treatment policy varies. In patients with rupture of the aorta, we tend to cover a longer segment of the thoracic aorta with the stent graft; in patients with malperfusion, we deploy a shorter stent graft to attain the proximal seal, and further intervention with additional stent graft deployment is determined by angiographic results.[22] Careful consideration is necessary to find a balance between attempts to induce thrombosis of the false lumen and diminish the risk of spinal ischemia reported with excessive length of stent grafts.[31] Alternative endovascular techniques, including percutaneous fenestration or provisional extension to induce complete attachment after stent graft placement, may also be used.[31] Long-term surveillance is particularly necessary in patients with persistent flow in the false lumen as this may undermine the long-term durability of the repair and necessitate reintervention.

A second limitation is that the retrospective nature of the study prevents us from recognizing and appreciating the potential of selection bias. Our preference of TEVAR over DTAR may result in only patients unsuitable for endovascular intervention undergoing open repair. In addition, patients in the open repair group were older and had a higher incidence of previous aortic repair, both of which are risk factors for adverse events.[1,10]

Our experience confirms that prompt endovascular intervention enables rapid and acceptable treatment of ACDTA. Preoperative planning and technical expertise are essential in achieving optimal results. Improvements in stent graft design offer hope in improving durability of results and increasing the number of patients suitable for endovascular intervention. Thoracic endovascular aortic repair should be considered the first-line treatment for patients with ACDTA.

Accepted for Publication: September 27, 2011.
Correspondence: Mark K. Eskandari, MD, Division of Vascular Surgery, Northwestern University, 676 N St Clair, Ste 650, Chicago, IL 60611 (meskanda@nmh.org).
Author Contributions: *Study concept and design:* Naughton, Rodriguez, Garcia-Toca, and Eskandari. *Acquisition of data:* Naughton, Park, Morasch, and Garcia-Toca. *Analysis and interpretation of data:* Naughton, Park, Morasch, Rodriguez, Wang, and Eskandari. *Drafting of the manuscript:* Naughton, Park, and Garcia-Toca. *Critical revision of the manuscript for important intellectual content:* Naughton, Morasch, Rodriguez, Wang, and Eskandari. *Statistical analysis:* Naughton, Park, Morasch, and Wang. *Obtained funding:* Naughton. *Administrative, technical, and material support:* Naughton, Park, Morasch, and Garcia-Toca. *Study supervision:* Naughton, Morasch, Rodriguez, and Eskandari.
Financial Disclosure: Dr Morasch receives honoraria for serving as a training course director for W. L. Gore & Associates and as a consultant for King Pharmaceuticals. Dr Rodriguez has received honoraria from W. L. Gore & Associates, Medtronic, and Abbott as a speaker. Dr Eskandari serves as a paid consultant for Harvard Clinical Research.
Funding/Support: A stipend for Dr Park is partially supported by National Institutes of Health grant 5T32HL094293.

REFERENCES

1. Cambria RP, Crawford RS, Cho JS, et al; GORE TAG Investigators. A multicenter clinical trial of endovascular stent graft repair of acute catastrophes of the descending thoracic aorta. *J Vasc Surg.* 2009;50(6):1255-1264.
2. Jonker FH, Trimarchi S, Verhagen HJ, Moll FL, Sumpio BE, Muhs BE. Meta-analysis of open versus endovascular repair for ruptured descending thoracic aortic aneurysm. *J Vasc Surg.* 2010;51(4):1026-1032.
3. Kaya A, Heijmen RH, Rousseau H, et al. Emergency treatment of the thoracic aorta: results in 113 consecutive acute patients (the Talent Thoracic Retrospective Registry). *Eur J Cardiothorac Surg.* 2009;35(2):276-281.
4. Pitton MB, Herber S, Schmiedt W, Neufang A, Dorweiler B, Düber C. Long-term

©2012 American Medical Association. All rights reserved.
Downloaded From: http://jamanetwork.com/ on 05/21/2013

follow-up after endovascular treatment of acute aortic emergencies. *Cardiovasc Intervent Radiol*. 2008;31(1):23-35.
5. Caronno R, Piffaretti G, Tozzi M, et al. Emergency endovascular stent-graft treatment for acute thoracic aortic syndromes. *Surgery*. 2006;140(1):58-65.
6. Davies MG, Younes HK, Harris PW, et al. Outcomes before and after initiation of an acute aortic treatment center. *J Vasc Surg*. 2010;52(6):1478-1485.
7. Tsai TT, Fattori R, Trimarchi S, et al; International Registry of Acute Aortic Dissection. Long-term survival in patients presenting with type B acute aortic dissection: insights from the International Registry of Acute Aortic Dissection. *Circulation*. 2006;114(21):2226-2231.
8. Garcia-Toca M, Naughton PA, Matsumura JS, et al. Endovascular repair of blunt traumatic thoracic aortic injuries: seven-year single-center experience. *Arch Surg*. 2010;145(7):679-683.
9. Johansson G, Markström U, Swedenborg J. Ruptured thoracic aortic aneurysms: a study of incidence and mortality rates. *J Vasc Surg*. 1995;21(6):985-988.
10. Schermerhorn ML, Giles KA, Hamdan AD, Dalhberg SE, Hagberg R, Pomposelli F. Population-based outcomes of open descending thoracic aortic aneurysm repair. *J Vasc Surg*. 2008;48(4):821-827.
11. Svensson LG, Kouchoukos NT, Miller DC, et al; Society of Thoracic Surgeons Endovascular Surgery Task Force. Expert consensus document on the treatment of descending thoracic aortic disease using endovascular stent-grafts. *Ann Thorac Surg*. 2008;85(1)(suppl):S1-S41.
12. Fairman RM, Criado F, Farber M, et al; VALOR Investigators. Pivotal results of the Medtronic Vascular Talent Thoracic Stent Graft System: the VALOR trial. *J Vasc Surg*. 2008;48(3):546-554.
13. Matsumura JS, Cambria RP, Dake MD, Moore RD, Svensson LG, Snyder S; TX2 Clinical Trial Investigators. International controlled clinical trial of thoracic endovascular aneurysm repair with the Zenith TX2 endovascular graft: 1-year results. *J Vasc Surg*. 2008;47(2):247-257.
14. Makaroun MS, Dillavou ED, Wheatley GH, Cambria RP; Gore TAG Investigators. Five-year results of endovascular treatment with the Gore TAG device compared with open repair of thoracic aortic aneurysms. *J Vasc Surg*. 2008;47(5):912-918.
15. Dake MD, Miller DC, Semba CP, Mitchell RS, Walker PJ, Liddell RP. Transluminal placement of endovascular stent-grafts for the treatment of descending thoracic aortic aneurysms. *N Engl J Med*. 1994;331(26):1729-1734.
16. Doss M, Wood JP, Balzer J, Martens S, Deschka H, Moritz A. Emergency endovascular interventions for acute thoracic aortic rupture: four-year follow-up. *J Thorac Cardiovasc Surg*. 2005;129(3):645-651.
17. Patel HJ, Williams DM, Upchurch GR Jr, Dasika NL, Deeb GM. A comparative analysis of open and endovascular repair for the ruptured descending thoracic aorta. *J Vasc Surg*. 2009;50(6):1265-1270.
18. Brown KE, Eskandari MK, Matsumura JS, Rodriguez H, Morasch MD. Short and midterm results with minimally invasive endovascular repair of acute and chronic thoracic aortic pathology. *J Vasc Surg*. 2008;47(4):714-722.
19. Peterson BG, Eskandari MK, Gleason TG, Morasch MD. Utility of left subclavian artery revascularization in association with endoluminal repair of acute and chronic thoracic aortic pathology. *J Vasc Surg*. 2006;43(3):433-439.
20. Morasch MD, Kibbe MR, Evans ME, et al. Percutaneous repair of abdominal aortic aneurysm. *J Vasc Surg*. 2004;40(1):12-16.
21. Peterson BG, Longo GM, Matsumura JS, et al. Endovascular repair of thoracic aortic pathology with custom-made devices. *Surgery*. 2005;138(4):598-605.
22. Naughton PA, Garcia-Toca M, Matsumura JS, et al. Complicated acute type B thoracic aortic dissections: endovascular treatment for visceral malperfusion and pseudoaneurysms. *Vasc Endovascular Surg*. 2011;45(3):219-226.
23. Chaikof EL, Blankensteijn JD, Harris PL, et al; Ad Hoc Committee for Standardized Reporting Practices in Vascular Surgery of the Society for Vascular Surgery/American Association for Vascular Surgery. Reporting standards for endovascular aortic aneurysm repair. *J Vasc Surg*. 2002;35(5):1048-1060.
24. Melissano G, Bertoglio L, Kahlberg A, et al. Evaluation of a new disease-specific endovascular device for type B aortic dissection. *J Thorac Cardiovasc Surg*. 2008;136(4):1012-1018.
25. Jonker FH, Verhagen HJ, Lin PH, et al. Outcomes of endovascular repair of ruptured descending thoracic aortic aneurysms. *Circulation*. 2010;121(25):2718-2723.
26. Demetriades D, Velmahos GC, Scalea TM, et al. Diagnosis and treatment of blunt thoracic aortic injuries: changing perspectives. *J Trauma*. 2008;64(6):1415-1418.
27. Tang GL, Tehrani HY, Usman A, et al. Reduced mortality, paraplegia, and stroke with stent graft repair of blunt aortic transections: a modern meta-analysis. *J Vasc Surg*. 2008;47(3):671-675.
28. Piffaretti G, Tozzi M, Lomazzi C, et al. Penetrating ulcers of the thoracic aorta: results from a single-centre experience. *Am J Surg*. 2007;193(4):443-447.
29. Dake MD, Miller DC, Mitchell RS, Semba CP, Moore KA, Sakai T. The "first generation" of endovascular stent-grafts for patients with aneurysms of the descending thoracic aorta. *J Thorac Cardiovasc Surg*. 1998;116(5):689-703.
30. Demers P, Miller DC, Mitchell RS, et al. Midterm results of endovascular repair of descending thoracic aortic aneurysms with first-generation stent grafts. *J Thorac Cardiovasc Surg*. 2004;127(3):664-673.
31. Nienaber CA, Kische S, Zeller T, et al. Provisional extension to induce complete attachment after stent-graft placement in type B aortic dissection: the PETTICOAT concept. *J Endovasc Ther*. 2006;13(6):738-746.

INVITED CRITIQUE

Thoracic Aortic Endovascular Aneurysm Repair for Acute Thoracic Aortic Catastrophes

The Need for Subgroup Analysis

Thoracic aortic endovascular aneurysm repair is now the treatment of choice for those with suitable anatomy. As vascular surgeons have become more familiar with this technique, they have used it for the treatment of ACDTA as an off-label application.

Naughton et al[1] should be commended for critically comparing their experience of TEVAR and open repair of ACDTA. Indeed, their results are on par with large industry-sponsored cohorts and published meta-analyses.[2-4]

As Naughton et al state, ACDTA encompasses a diverse group of disease processes. Outcomes for traumatic transections, typically seen in younger patients, are quite different from those for cTBDs or ruptured degenerative aneurysms. However, subgroup analysis is not performed within the article, and all ACDTA are lumped into a single category, leading to the already well-known conclusion that TEVAR is associated with decreased mortality compared with open repair.

The American Association for the Surgery of Trauma published the first prospective multicenter trial for the treatment of traumatic aortic injuries, with the surprising finding of no difference in paraplegia between open repair and TEVAR.[5] While a randomized trial comparing open and endovascular treatment of ACDTA is unlikely to occur, a prospective study of all ACDTA, similar to that of the American Association for the Surgery of Trauma, is necessary to

©2012 American Medical Association. All rights reserved.
Downloaded From: http://jamanetwork.com/ on 05/21/2013