OBSERVATION

Trigeminal Neuropathic Pain in a Patient With Progressive Facial Hemiatrophy (Parry-Romberg Syndrome)

Michele Viana, MD; Christine M. Glastonbury, MD; Till Sprenger, MD; Peter J. Goadsby, PhD, DSc

Background: We reviewed the literature on published cases of progressive facial hemiatrophy (Parry-Romberg syndrome) to identify possible pathophysiological mechanisms of the syndrome.

Objective: To describe the somatosensory phenotype of a previously unreported patient with progressive facial hemiatrophy and facial pain.

Design: Case report and 4-month follow-up period.

Setting: University-based tertiary referral headache center.

Patient: A 37-year-old woman with progressive facial hemiatrophy and strictly left-sided facial pain over 12 years.

Intervention: Greater occipital nerve blockade with lidocaine, 2% (2 mL), and methylprednisolone sodium phosphate (80 mg).

Main Outcome Measures: Trigeminal sensory phenotype on quantitative sensory testing using thermal threshold and Von Frey hairs. The case report includes patient photographs, neuroimaging, and neurophysiological findings.

Results: On the left side, there was continuous pain in V_1 and V_2 and intermittent sharp shooting pains in V_3. The sensory examination showed areas on the left side with pinprick hyperalgesia, cold and heat hyperalgesia, and dynamic mechanical allodynia. The pain in V_1 and V_3 and the allodynia dramatically improved after greater occipital nerve blockade. In the cases reported in the literature, a constant component of the pain was always part of the phenotype, and positive or negative trigeminal sensory signs were frequently described.

Conclusions: The phenotype of our patient suggests neuropathic pain involving all 3 branches of the trigeminal nerve, and the patient fulfills newly defined stricter criteria for neuropathic pain. Similar to our case, phenotypes of the other published cases seem to agree with trigeminal neuropathic pain rather than trigeminal neuralgia specifically.

Arch Neurol. 2011;68(7):938-943

Author Affiliations: Headache Group, Department of Neurology (Drs Viana, Sprenger, and Goadsby), and Department of Radiology (Dr Glastonbury), University of California, San Francisco; Headache Center, Department of Neurology, Eastern Piedmont University, Novara, Italy (Dr Viana); and Division of Neuroradiology and Department of Neurology, University Hospital Basel, Basel, Switzerland (Dr Sprenger).

Facial hemiatrophy (Parry-Romberg syndrome) is a rare disorder characterized by progressive hemiatrophy of the skin and soft tissue of the face and in some cases results in atrophy of muscles, cartilage, and the underlying bony structures. This atrophic process commonly appears during the first or early in the second decade of life. The clinical picture varies widely in the degree of onset, duration, and involvement. The natural history of the disorder often involves an active progressive phase (2-10 years), followed by a phase when the atrophy stabilizes. The distribution of atrophic changes generally follows the pattern of sensory innervation of 1 or all 3 branches of the trigeminal nerve on 1 side.[1] Facial hemiatrophy can go along the forehead with a linear scleroderma en coup de sabre.[2] Also described in facial hemiatrophy are neurological symptoms, including migraine, epilepsy, facial palsy, facial pain, and complications of the eye, hair, skin, teeth, tongue, larynx, and jaw.[3] Although facial hemiatrophy has been clinically reported for more than 150 years,[4,5] the origin of the syndrome remains unknown. Suggested causes include infectious agents,[6] trauma,[7] heredity,[8] or autoimmunity.[9] Cervical sympathetic dysfunction[10,11] and trigeminal neurovasculitis[12] have also been implicated as being involved in the pathogenesis. To date, no effective treatments have been identified.

We describe the somatosensory phenotype of a previously unreported patient with facial hemiatrophy and facial pain. We believe that detailed phenotyp-

©2011 American Medical Association. All rights reserved.
Downloaded From: http://jamanetwork.com/ on 05/20/2013

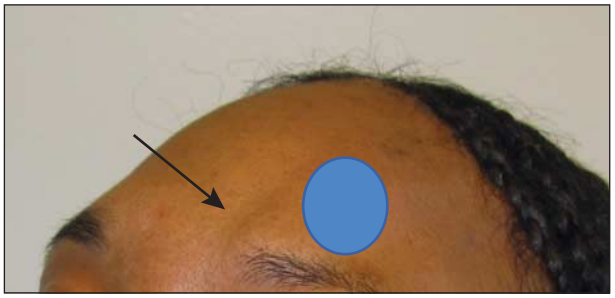

Figure 1. Patient's forehead shows a linear furrow, which represents the coup de sabre lesion (arrow). The area of pinprick hyperalgesia is marked in blue and is located next to the atrophic change.

Figure 2. Patient's face shows left-sided soft-tissue wasting.

ing may be the key to understanding the underlying trigeminal mechanisms and correctly classifying the pain associated with this syndrome. We review the literature on published cases of facial hemiatrophy in which at least part of the somatosensory phenotype has been reported and attempt to identify possible pathophysiological mechanisms of the syndrome.

REPORT OF A CASE

A 37-year-old African American right-handed woman was seen with a history of strictly left-sided facial pain over approximately 12 years. The pain began as left-sided jaw stiffness whereby she could not easily close her mouth. On presentation, she described 3 components of her pain that differed in their location, pain characteristics, triggering, and response to medication. First, a continuous pulling sensation of severe pain was in the V_1 distribution next to a coup de sabre lesion (**Figure 1**). The pain radiated toward the left parietal area from this region. Second, an area of continuous dull and achy pain was located in the lateral V_2 distribution. She rated the intensity of pain in both areas (V_1 and V_2) as undulating between 6 and 10 on a 11-point Verbal Rating Scale. Third, she described shooting pains with an electrical sensation in V_3 lasting for seconds. She rated this pain as 10 on the Verbal Rating Scale. The patient would typically experience 3 shooting pains in succession about every other day. Over the years, she had gradual loss of soft tissue, including the masticator muscle bulk on the left side, which led to visible facial asymmetry and to slight left-sided chewing weakness. There was no nausea, photophobia, phonophobia, or osmophobia associated with the pain, nor did movement aggravate the pain. She gave no history of pain-related cranial autonomic symptoms or visual, sensory, motor, or aphasic aura. Chewing on the left side could exacerbate the constant pain about 1 hour later.

At age 27 years, she had a single episode of a severe 2-day headache with photophobia and phonophobia. No such episodes had occurred thereafter.

On physical examination, the patient was well and weighed 83 kg. There was atrophy of the soft tissue over the left cheek and zygomatic arch, mild depression of the nasolabial fold, and a frontal coup de sabre (**Figure 2**). In the cranial nerves, there was no trigeminal sensory loss to light touch. There was a left-sided circular area with pinprick hyperalgesia having a diameter of about 2.5 cm over the V_1 distribution just next to the coup de sabre lesion. Dynamic mechanical allodynia was noted in V_2. Thermal testing over V_2 demonstrated normal cold and warm detection thresholds bilaterally and no paradoxical heat sensations. However, left-sided cold and heat hyperalgesia was observed. There were no signs of windup as tested with repetitive stimuli applying stiff Von Frey hairs on the left side or right side in the V_2 distribution. Corneal reflexes were symmetrical. No other pathological findings were noted.

When first seen, the patient was taking lamotrigine (300 mg/d) for pain relief. This improved the frequency of the brief shooting pains in V_3 but did not relieve the other pain components. In the past, she had tried carbamazepine (up to 1200 mg/d) without benefit. Similarly, rofecoxib and nonsteroidal anti-inflammatory drugs were ineffective. She took acetaminophen and hydrocodone for hand pain and meloxicam (7.5 mg) for shoulder pain, which did not affect the facial pain. Neither metoprolol (12.5 mg twice a day) nor lisinopril (20 mg), both taken for paroxysmal supraventricular tachycardias and hypertension, relieved the head pain. She was also on a regimen of estradiol acetate after a hysterectomy and oophorectomy and used an insulin pump (insulin aspart [ribosomal DNA origin]) for type 1 diabetes mellitus diagnosed about 20 years earlier. She had never had a head or neck injury.

Magnetic resonance images were initially obtained that demonstrated subtle facial asymmetry with volume loss but normal signal intensity in the muscles of mastication on the left side compared with the right side (**Figure 3**). In addition, there was asymmetry of all the salivary glands on the left side, as well as significant asymmetry of the subcutaneous and deep fat on the left side of the face compared with the right. No appreciable asym-

©2011 American Medical Association. All rights reserved.
Downloaded From: http://jamanetwork.com/ on 05/20/2013

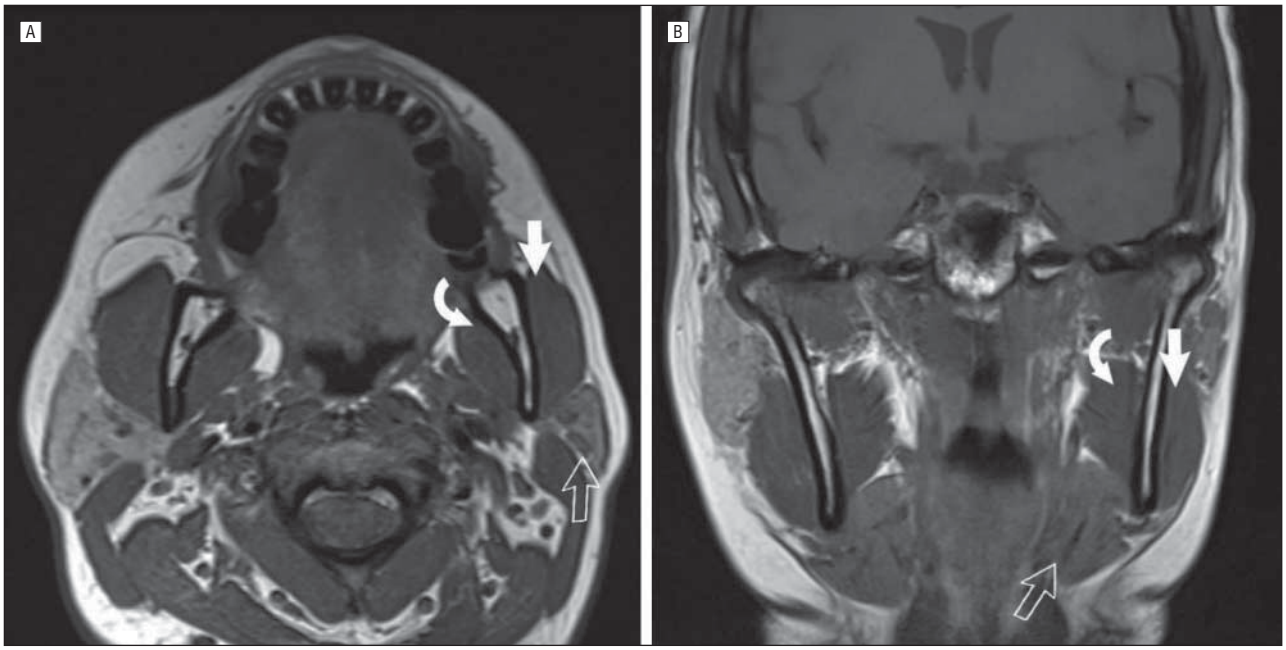

Figure 3. Axial (A) and coronal (B) T1-weighted magnetic resonance images of the patient's face show subtly smaller volume of the left masseter muscle (arrow) and, to a lesser extent, the left medial pterygoid muscle (curved arrow) compared with the right side. Note also the atrophic left parotid gland (A, open arrow) and left submandibular gland (B, open arrow). More obvious in both planes is the loss of subcutaneous and deep facial fat, resulting in a flattened contour on the left side of the face.

metry of the bony facial structures was noted. The brainstem and the course of the left fifth cranial nerve were normal on high-resolution T1-weighted, T2-weighted, and postcontrast imaging.

The patient's facial nerve compound muscle action potentials were normal and symmetrical. Normal results were also found on needle electromyographic studies, including the left orbicularis oris, masseter, and frontalis muscles.

We performed a greater occipital nerve (GON) blockade with lidocaine, 2% (2 mL), and methylprednisolone (80 mg). The pulling pain in V_1, the allodynia in V_2, and the shooting pains in V_3 dramatically improved for 4 months after GON blockade.

COMMENT

Progressive facial hemiatrophy, also known as Parry-Romberg syndrome, is characterized by slowly progressive atrophy of 1 side of the face, primarily involving the subcutaneous tissues and fat.[13] There have been reports of associated neurological complications, such as epilepsy,[14] trigeminal neuralgia,[15] facial pain and migraine,[16] facial palsy,[17] and ipsilateral cerebral hemiatrophy.[18] The exact prevalence of nervous system involvement is unknown; in cases involving pain, the phenotype was rarely described in detail. It has been estimated that facial hemiatrophy is associated with neurological abnormalities in 10%[19] to 20%[20] of cases, although no epidemiological data are available. A 2003 Internet survey assessed the prevalence of symptoms, complications, and response to treatment among a large group of patients with facial hemiatrophy.[3] The investigators recorded neurologic disturbances at higher relative and absolute prevalences than aforedescribed: 52% of patients were reported to have migrainelike pain, and 46% had some type of facial pain, which was always ipsilateral to the facial atrophy. Facial pain was defined as ranging from a dull ache to electric shock–like pain. No further details on the pain were provided. Data were collected using a Web interface, and no medical history was taken by a physician.

We describe herein a patient with progressive facial hemiatrophy and strictly left-sided facial pain. There was continuous pain in V_1 and V_2 and intermittent sharp shooting pains in V_3. The clinical examination showed areas with pinprick hyperalgesia, cold and heat hyperalgesia, and dynamic mechanical allodynia, indicating peripheral and central sensitization. No structural lesions were found. The phenotype suggests neuropathic pain involving all 3 branches of the trigeminal nerve, and the patient fulfills newly defined stricter criteria for neuropathic pain.[21] The continuous pain and the absence of trigger factors for the additional intermittent shooting pains are not typical for trigeminal neuralgia, which is defined as paroxysmal attacks of electric shocklike pains affecting 1 or more divisions of the trigeminal nerve that may develop spontaneously or be evoked by trivial stimuli in specific facial or intraoral areas, without any clinically evident neurological deficit.[22] However, the finding of shooting pains in V_3 that are distinct from the pain in V_1 and V_2 is similar to trigeminal neuralgia, although the underlying causal mechanisms of pain in all 3 trigeminal branches are probably the same, and a broader diagnosis of trigeminal neuropathic pain could cover all aspects. Indeed, in a previous study[23] of 23 patients with trigeminal neuro-

©2011 American Medical Association. All rights reserved.
Downloaded From: http://jamanetwork.com/ on 05/20/2013

Table. Characteristics of Patients With Facial Hemiatrophy

Source	Patient Age, y	Age at Onset of PRS, y	Pain			Coup de Sabre	Affected Side	Positive and Negative Sensory Signs
			Character	Duration	Localization			
Present study	37	25	Pulling pain Dull Shooting, stabbing, electrical	Constant Constant Series of few seconds every couple of days	V_1 V_2 (maximum), V_3 V_3	Yes	Left	Left-sided pinprick hyperalgesia in V_1, mechanical allodynia, cold and heat hyperalgesia in V_2
Kumar et al,[15] 2009	32	Childhood	Sharp stabbing Headache NOS	Intermittent NOS Persistent	Left-sided (NOS) Left-sided (NOS)	No	Left	"No sensory deficits were found"
Drummond et al,[16] 2006	30	NOS	Jabbing neuralgic and tingling sensation	Continuous	Cheek and angle of jaw	No	Right	Hypoesthesia (light touch, warm, cold), hyperalgesia (pressure, heat), V_1 and V_2
Brito et al,[25] 1997 (in Portuguese; authors describe another patient with classic trigeminal neuralgia, probably unrelated to facial hemiatrophy)	33	25	Muscle painful spasms (cramps)	Frequent NOS	V_3	No	Right	None
Auvinet et al,[26] 1989 (in French)	65	56	Pain (NOS), then dysesthesias, paresthesias	Unclear from case description whether continuous or intermittent	Left hemiface (NOS), pronounced retro-orbitally	Yes	Left	Two areas of hypoesthesia in V_1, cold paresthesias and "feeling of dry and cardboard-like skin" on left hemiface

Abbreviations: NOS, not otherwise specified; PRS, Parry-Romberg syndrome.

pathic pain, the authors found an intermittent pain component in up to 25% of patients. Alternatively, a concomitant primary stabbing headache, which is frequently associated with other facial or head pain syndromes, may be considered for the V_3 pain, although this type of pain typically affects the first division of the trigeminal nerve.[22] Chronic migraine is unlikely because the patient did not report typically associated symptoms, such as nausea, photophobia, phonophobia, or movement aggravation, along with the left-sided facial pain.[24] The patient recalled a single migrainelike attack in the past, which was unrelated to the ongoing facial pain. According to standard criteria, a diagnosis of migraine cannot be made on the basis of a single attack,[22] although the description suggests some underlying tendency in our patient. Trigeminal autonomic cephalalgia or hemicrania continua is unlikely because of absent cranial autonomic symptoms and the particular phenotype that is reported herein.[22] Because our patient has had a diagnosis of type 1 diabetes mellitus for 20 years, we also considered diabetic neuropathy, but the patient did not show the typical pattern of ocular diabetic neuropathy as described herein (ie, pain around the eye and the forehead, possibly with ocular cranial nerve palsy, as described under *International Classification of Headache Disorders* code 13.14 [ocular diabetic neuropathy]).[22] Moreover, we had no other evidence in our patient of diabetic neuropathy clinically or electrophysiologically.

In 2006, a single case of facial hemiatrophy with detailed clinical and physiological phenotyping of the head and facial pain was reported.[16] The authors performed a complete sensory examination, as well as trigeminal and cervical sympathetic nerve tests. A diagnosis of migraine was made, and additional "continuous jabbing neuralgic pain" was described, which was referred to as "trigeminal neuralgia." However, the current *International Classification of Headache Disorders* criteria define code 13.1.2 (symptomatic trigeminal neuralgia) as "paroxysmal attacks of pain lasting from a fraction of a second to two minutes,"[22] which is not in clear agreement with the previous case report[16] or with the overall presentation of our patient.

Another description of a patient with facial hemiatrophy and facial pain, diagnosed as having trigeminal neuralgia, was published by Kumar et al.[15] The case was well documented, included head measurements, and showed patient photographs before and after the onset of the disease. However, no specific clinical description of the pain was included in the case report. The patient experienced head and facial pain (persistent and intermittent), but no further details were provided (**Table**).

Other than these 2 cases, no other detailed descriptions of patients having trigeminal pain associated with facial hemiatrophy are available in the English-language literature to date. Two patients were described in a Portuguese article[25]; the first was a case of classical trigeminal neuralgia (probably unrelated to facial hemiatrophy), which resolved after neurovascular decompression, while the second case comprised a painful sensation with ipsilateral muscle spasms or cramps (Table).

Another case was reported in the French literature.[26] Again, the sensory phenotype was incompletely described (Table).

©2011 American Medical Association. All rights reserved.
Downloaded From: http://jamanetwork.com/ on 05/20/2013

We also found descriptions in patients with progressive hemifacial atrophy of migrainelike headaches[11] and of sensory impairment in the territory of the trigeminal nerve.[17] In 2009, a case of facial hemiatrophy manifesting as status migrainosus, without any other positive or negative sensory signs of trigeminal involvement, was reported.[20]

Regarding possible pathophysiological mechanisms of the pain in our patient and in related cases, electron microscopy has demonstrated lymphocytic infiltrates in neurovascular bundles and abnormalities of vascular endothelium and basal membranes as possible causes of neuropathy in patients with facial hemiatrophy.[12] It has been hypothesized that the pathogenesis of facial hemiatrophy involves chronic cell-mediated vascular injury and incomplete endothelial regeneration along branches of the trigeminal nerve (lymphocytic neurovasculitis).[27] This concept supports the view that patients with facial hemiatrophy have a neuropathic disorder. Notably, our patient had a positive response to GON blockade: continuous pain in V_1 and allodynia in V_2 resolved, and shooting pain in V_3 decreased dramatically in frequency. It is believed that the effectiveness of GON blockade in head pain syndromes results from the fact that second-order neurons in the trigeminal-cervical complex receive convergent input from the GON and from the trigeminal nerve.[28] In our patient, sensitization was likely a key factor that had caused her pain to continue, and GON blockade may have reduced sensitization of such neurons. This is also supported by the sensory examination in our patient demonstrating pinprick hyperalgesia, cold and heat hyperalgesia, and dynamic mechanical allodynia, indicating peripheral and central sensitization.

Facial hemiatrophy is a self-limiting condition in terms of atrophy but not of pain, and there is no cure. A multidisciplinary approach to treatment is useful, as patients can experience a multitude of symptoms. Besides esthetic improvement, symptomatic treatment should aim at reducing the burden of neurological symptoms, including pain.[29] Furthermore, a correct diagnosis and classification according to the underlying mechanism are fundamental in determining which treatment approach may be promising in patients with this condition, for which controlled clinical studies are unlikely to be conducted.

In summary, progressive facial hemiatrophy is a rare disorder that can be associated with neurological complications. Among these, facial pain seems to be one of the most frequent, although few case reports detail the phenotype. The pain does not seem consistent with criteria for symptomatic trigeminal neuralgia in most of the published cases, as the chief symptom is typically continuous pain. In our view, the best term to classify the illustrated combination of continuous plus intermittent pain with additional positive sensory signs in the trigeminal distribution, as described in our patient and the other noted cases, is *trigeminal neuropathic pain*. A more detailed description of the phenotype among future patients with facial hemiatrophy will better define the underlying mechanisms and help determine the best therapeutic options.

Accepted for Publication: December 17, 2010.
Correspondence: Peter J. Goadsby, PhD, DSc, Headache Group, Department of Neurology, University of California, San Francisco, 1701 Divisadero St, Ste 480, San Francisco, CA 94143-1675 (pgoadsby@headache.ucsf.edu).
Author Contributions: *Study concept and design:* Viana, Sprenger, and Goadsby. *Acquisition of data:* Viana, Glastonbury, Sprenger, and Goadsby. *Analysis and interpretation of data:* Viana, Glastonbury, Sprenger, and Goadsby. *Drafting of the manuscript:* Viana, Sprenger, and Goadsby. *Critical revision of the manuscript for important intellectual content:* Viana, Glastonbury, and Goadsby. *Administrative, technical, and material support:* Sprenger and Goadsby. *Study supervision:* Goadsby.
Financial Disclosure: None reported.
Additional Contributions: We are grateful to the patient for allowing us to report the case.

REFERENCES

1. Mazzeo N, Fisher JG, Mayer MH, Mathieu GP. Progressive hemifacial atrophy (Parry-Romberg syndrome): case report. *Oral Surg Oral Med Oral Pathol Oral Radiol Endod*. 1995;79(1):30-35.
2. Lehman TJ. The Parry Romberg syndrome of progressive facial hemiatrophy and linear scleroderma en coup de sabre: mistaken diagnosis or overlapping conditions? *J Rheumatol*. 1992;19(6):844-845.
3. Stone J. Parry-Romberg syndrome: a global survey of 205 patients using the Internet. *Neurology*. 2003;61(5):674-676.
4. Romberg HM. *Throphoneurosen: Klinische Ergebnisse*. Berlin, Germany: Forstner; 1846.
5. Parry CH. *Collection From Unpublished Papers*. London, England: Underwood; 1825.
6. Hickman JW, Sheils WS. Progressive facial hemiatrophy: report of a case with marked homolateral involvement. *Arch Intern Med*. 1964;113(113):716-720.
7. Fry JA, Alvarellos A, Fink CW, Blaw ME, Roach ES. Intracranial findings in progressive facial hemiatrophy. *J Rheumatol*. 1992;19(6):956-958.
8. Duymaz A, Karabekmez FE, Keskin M, Tosun Z. Parry-Romberg syndrome: facial atrophy and its relationship with other regions of the body. *Ann Plast Surg*. 2009;63(4):457-461.
9. Garcia-de la Torre I, Castello-Sendra J, Esgleyes-Ribot T, Martinez-Bonilla G, Guerrerosantos J, Fritzler MJ. Autoantibodies in Parry-Romberg syndrome: a serologic study of 14 patients. *J Rheumatol*. 1995;22(1):73-77.
10. Lonchampt P, Emile J, Pélier-Cady MC, Cadou B, Barthelaix A. Central sympathetic dysregulation and immunological abnormalities in a case of progressive facial hemiatrophy (Parry-Romberg disease). *Clin Auton Res*. 1995;5(4):199-204.
11. Cory RC, Clayman DA, Faillace WJ, McKee SW, Gama CH. Clinical and radiologic findings in progressive facial hemiatrophy (Parry-Romberg syndrome). *AJNR Am J Neuroradiol*. 1997;18(4):751-757.
12. Pensler JM, Murphy GF, Mulliken JB. Clinical and ultrastructural studies of Romberg's hemifacial atrophy. *Plast Reconstr Surg*. 1990;85(5):669-676.
13. Archambault L, Fromm NK. Progressive facial hemiatrophy: report of three cases. *Arch Neurol Psychiatry*. 1932;54:75-79.
14. Donley DE. Facial hemiatrophy associated with epilepsy: reported of one case. *J Nerv Ment Dis*. 1935;82:33-39.
15. Kumar AA, Kumar RA, Shantha GP, Aloogopinathan G. Progressive hemi facial atrophy—Parry Romberg syndrome presenting as severe facial pain in a young man: a case report. *Cases J*. 2009;2:6776.
16. Drummond PD, Hassard S, Finch PM. Trigeminal neuralgia, migraine and sympathetic hyperactivity in a patient with Parry-Romberg syndrome. *Cephalalgia*. 2006;26(9):1146-1149.
17. Asher SW, Berg BO. Progressive hemifacial atrophy: report of three cases, including one observed over 43 years, and computed tomographic findings. *Arch Neurol*. 1982;39(1):44-46.
18. Restivo DA, Milone P. Teaching Neuro*Images*: progressive facial hemiatrophy (Parry-Romberg syndrome) with ipsilateral cerebral hemiatrophy. *Neurology*. 2010;74(3):e11 http://www.neurology.org/content/74/3/e11.long. Accessed April 11, 2011.
19. Blaszczyk M, Królicki L, Krasu M, Glinska O, Jablonska S. Progressive facial hemi-

©2011 American Medical Association. All rights reserved.
Downloaded From: http://jamanetwork.com/ on 05/20/2013

atrophy: central nervous system involvement and relationship with scleroderma en coup de sabre. *J Rheumatol*. 2003;30(9):1997-2004.
20. Menascu S, Padeh S, Hoffman C, Ben-Zeev B. Parry-Romberg syndrome presenting as status migrainosus. *Pediatr Neurol*. 2009;40(4):321-323.
21. Treede RD, Jensen TS, Campbell JN, et al. Neuropathic pain: redefinition and a grading system for clinical and research purposes. *Neurology*. 2008;70(18):1630-1635.
22. Headache Classification Committee of the International Headache Society. *The International Classification of Headache Disorders* (second edition). *Cephalalgia*. 2004;24:1-160.
23. Eide PK, Rabben T. Trigeminal neuropathic pain: pathophysiological mechanisms examined by quantitative assessment of abnormal pain and sensory perception. *Neurosurgery*. 1998;43(5):1103-1110.
24. Olesen J, Bousser MG, Diener HC, et al; Headache Classification Committee. New appendix criteria open for a broader concept of chronic migraine. *Cephalalgia*. 2006;26(6)(suppl 1):742-746.
25. Brito JC, Holanda MM, Holanda G, da Silva JA. Progressive facial hemiatrophy (Parry-Romberg disease): report of two cases associated with trigeminal neuralgia and cramps [in Portuguese]. *Arq Neuropsiquiatr*. 1997;55(3A):472-477.
26. Auvinet C, Glacet-Bernard A, Coscas G, Cornelis P, Cadot M, Meyringnac C. Parry-Romberg progressive facial hemiatrophy and localized scleroderma: nosologic and pathogenic problems [in French]. *J Fr Ophtalmol*. 1989;12(3):169-173.
27. Goldberg-Stern H, deGrauw T, Passo M, Ball WS Jr. Parry-Romberg syndrome: follow-up imaging during suppressive therapy. *Neuroradiology*. 1997;39(12):873-876.
28. Goadsby PJ, Bartsch T. On the functional neuroanatomy of neck pain. *Cephalalgia*. 2008;28(suppl 1):1-7.
29. Pinheiro TP, Silva CC, Silveira CS, Botelho PC, Pinheiro MG, Pinheiro JdeJ. Progressive hemifacial atrophy—case report. *Med Oral Patol Oral Cir Bucal*. 2006;11(2):E112-E114. http://www.medicinaoral.com/pubmed/medoralv11_i2_p112.pdf. Accessed April 11, 2011.

Announcement

Trial Registration Required. As a member of the International Committee of Medical Journal Editors (ICMJE), *Archives of Neurology* will require, as a condition of consideration for publication, registration of all trials in a public trials registry (such as http://ClinicalTrials.gov). Trials must be registered at or before the onset of patient enrollment. The trial registration number should be supplied at the time of submission.

For details about this new policy, and for information on how the ICMJE defines a clinical trial, see the editorials by DeAngelis et al in the September 8, 2004 (2004;292:1363-1364) and June 15, 2005 (2005;293:2927-2929) issues of *JAMA*. Also see the Instructions to Authors on our Web site: www.archneurol.com.

©2011 American Medical Association. All rights reserved.
Downloaded From: http://jamanetwork.com/ on 05/20/2013