RESEARCH LETTER

Ultrastructural Mitochondrial Abnormalities in Patients With Sporadic Amyotrophic Lateral Sclerosis

A large number of neurodegenerative diseases are caused by impairment of mitochondrial function.[1] Mutations in genes that encode proteins responsible for the shape and dynamics of mitochondria have been associated with some genetic neurodegenerative diseases, which implies that mitochondrial shape plays an important role in the health of neurons and muscle.[2]

Neurons are highly dependent on mitochondria because they have high energy demands and are unable to switch to glycolysis when mitochondrial oxidative phosphorylation is impaired. An ultrastructural hallmark of the synapse is the abundance of mitochondria, which are essential to maintaining calcium homeostasis and adequate levels of adenosine triphosphate (critical for nerve transmission). Neurons have extraordinarily long cellular processes, and tight control of mitochondrial dynamics facilitates the distribution of active mitochondria to dendrites and axon terminals. Higgins et al[3] described vacuolated mitochondria in the early phases of motor neuron degeneration in transgenic mice with familial amyotrophic lateral sclerosis (ALS) and the *SOD1* gene; they found that mutant *SOD1* extends the outer mitochondrial membrane and expands the intermembrane space.

Much less is known about the involvement of mitochondria in muscle of patients with ALS. Defects of the mitochondrial respiratory chain have been described in several patients with ALS. Comi and colleagues[4] described a patient with early-onset and rapidly progressive motor neuron disease who harbored a heteroplasmic microdeletion of the mitochondrial DNA (mtDNA)–encoded subunit I of cytochrome-*c* oxidase (COX). Finsterer[5] described a mother and 2 daughters with symptoms compatible with ALS. All 3 patients showed COX-negative muscle fibers, ultrastructurally abnormal mitochondria, and no mutations in *SOD1*, but they all harbored 3 mtDNA mutations, one in the transfer RNA^{Ile} gene, one in the cytochrome *b* gene, and one in the adenosine triphosphatase 6 gene.[5]

Recently, we reviewed the muscle biopsy specimens from 50 patients with typical sporadic ALS.[6] Histochemical data showed variably severe COX deficiency in 23 of the 50 patients (46%). Of these 23 patients, 7 (30%) showed severe deficiency (>10 COX-negative fibers of 100), and in these 7 patients, the biochemical defect of respiratory chain enzymes paralleled the histochemical defect.[6]

Methods. To verify and extend our histochemical and biochemical data, we have now examined ultrastructurally the muscle biopsies from the 7 patients with severe

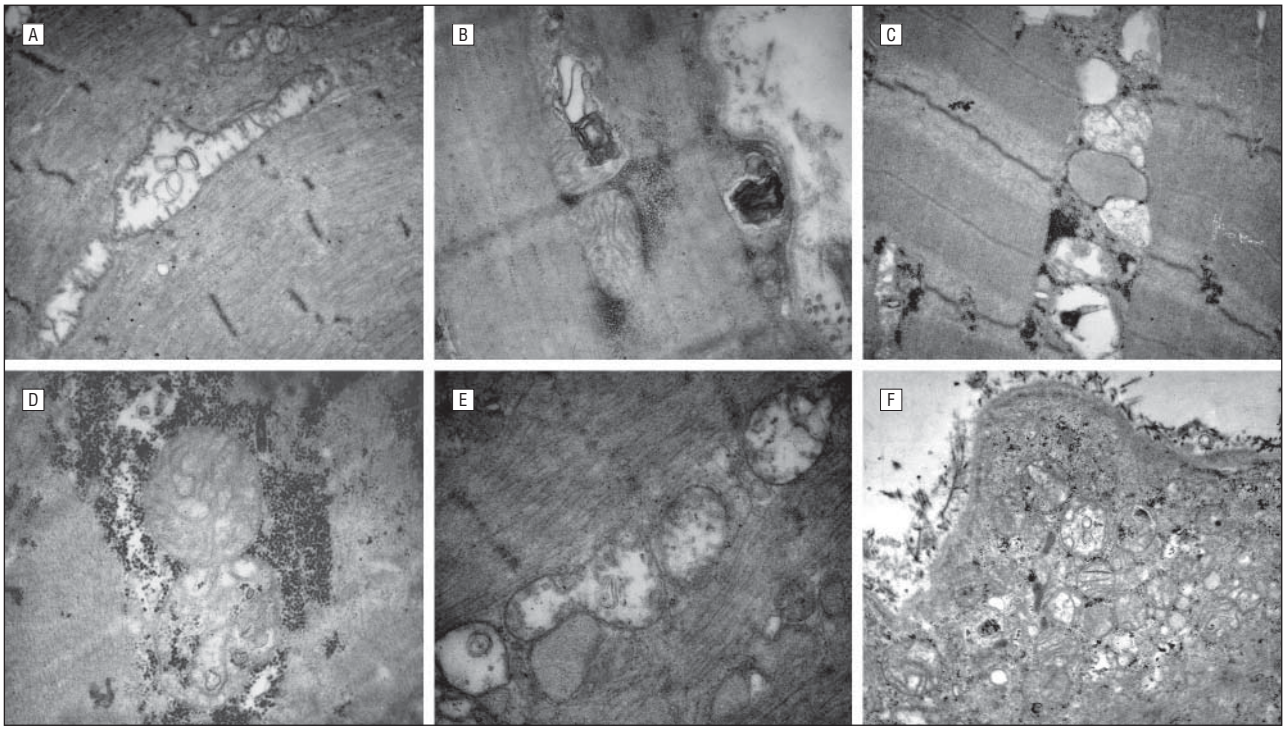

Figure. Electron micrographs of swollen mitochondria characterized by dilatation and disruption of the cristae (×12 000 [A, C, and D] and ×20 000 [B, D, and E]). B, Two mitochondria with multilamellar whorls.

©2011 American Medical Association. All rights reserved.
Downloaded From: http://jamanetwork.com/ on 05/19/2013

oxidative defects. We fixed small blocks of muscle in 2.5% glutaraldehyde and postfixed them in 2% osmium tetroxide for 1 hour. After dehydration, the specimens were embedded in epoxide resin. Ultrathin sections were cut and stained with uranyl acetate and lead citrate, then examined in a Zeiss electron microscope. For each patient, we investigated multiple longitudinal and transverse sections.

Results. We found ultrastructural mitochondrial abnormalities in 6 patients. The derangement of mitochondrial ultrastructure included disruption of the cristae and dilution of the matrix. In some cases, the mitochondria with abnormal cristae and matrices were also greatly increased in size (giant mitochondria). Also, some of the giant mitochondria showed a normal aspect. In a few mitochondria, the cristae were converted to bizarre multilamellar whorls (**Figure**). These ultrastructural findings support the concept that dysfunction of the oxidative metabolism may play an important role in the pathogenic pathway in sporadic ALS.

Laura Napoli, PhD
Veronica Crugnola, MD
Costanza Lamperti, MD, PhD
Vincenzo Silani, MD
Salvatore Di Mauro, MD
Nereo Bresolin, MD
Maurizio Moggio, MD

Author Affiliations: Department of Neurological Sciences, "Dino Ferrari" Center, Milan University, Foundation Istituto de Ricovero e Cura a Carattere Scientifico (IRCCS) Ca' Granda Ospedale Maggiore Policlinico (Drs Napoli, Bresolin, and Moggio), Department of Neurology and Neurorehabilitation, Istituto Auxologico Italiano IRCCS, Ospedale San Giuseppe, Piancavallo Verbania (Dr Crugnola), Unit of Molecular Neurogenetics, The Foundation "Carlo Besta" Institute of Neurology–IRCCS (Dr Lamperti), and Department of Neurology and Laboratory of Neuroscience, "Dino Ferrari" Center, Università Studi Milano, IRCCS Istituto Auxologico Italiano (Dr Silani), Milan, Italy; and Department of Neurology, Columbia University Medical Center, New York, New York (Dr Di Mauro).
Correspondence: Dr Moggio, Department of Neurological Sciences, "Dino Ferrari" Center, Milan University, Foundation IRCCS Ca' Granda Ospedale Maggiore Policlinico, Padiglione Ponti, via Francesco Sforza 35, 20122 Milan, Italy (maurizio.moggio@unimi.it).
Author Contributions: *Study concept and design:* Crugnola, Bresolin, and Moggio. *Acquisition of data:* Napoli. *Analysis and interpretation of data:* Napoli, Crugnola, Lamperti, Silani, Di Mauro, and Moggio. *Drafting of the manuscript:* Crugnola, Lamperti, and Silani. *Critical revision of the manuscript for important intellectual content:* Napoli, Crugnola, Silani, Di Mauro, Bresolin, and Moggio. *Statistical analysis:* Napoli. *Obtained funding:* Bresolin. *Administrative, technical, and material support:* Napoli and Lamperti. *Study supervision:* Crugnola, Silani, Di Mauro, Bresolin, and Moggio.
Financial Disclosure: None reported.

1. Bossy-Wetzel E, Barsoum MJ, Godzik A, Schwarzenbacher R, Lipton SA. Mitochondrial fission in apoptosis, neurodegeneration and aging. *Curr Opin Cell Biol*. 2003;15(6):706-716.
2. Chan DC. Mitochondrial dynamics in disease. *N Engl J Med*. 2007;356(17):1707-1709.
3. Higgins CM, Jung C, Xu Z. ALS-associated mutant SOD1G93A causes mitochondrial vacuolation by expansion of the intermembrane space and by involvement of SOD1 aggregation and peroxisomes. *BMC Neurosci*. 2003;4:16.
4. Comi GP, Bordoni A, Salani S, et al. Cytochrome c oxidase subunit I microdeletion in a patient with motor neuron disease. *Ann Neurol*. 1998;43(1):110-116.
5. Finsterer J. Mitochondriopathy mimicking amyotrophic lateral sclerosis. *Neurologist*. 2003;9(1):45-48.
6. Crugnola V, Lamperti C, Lucchini V, et al. Mitochondrial respiratory chain dysfunction in muscle from patients with amyotrophic lateral sclerosis. *Arch Neurol*. 2010;67(7):849-854.

COMMENTS AND OPINIONS

Central Nervous System Problems With Eosinophilia

Sethi and Schmidley[1] comment in their report of 3 cases of cerebral infarcts in the setting of eosinophilia that neurological problems in hypereosinophilic syndrome (HES) include stroke, neuropathy, and encephalopathy. They note that the strokes are small and occur in the arterial border zones but may progress. Specifically, they comment that generalized encephalopathy occurs in a small percentage of patients with HES,[2] producing behavioral disturbances and upper motor neuron signs. An early report showed that 3 patients with encephalopathy had multiple lesions in the border zones, worsened with higher eosinophil counts, and improved with treatment.[3] Sethi and Schmidley speculate that HES encephalopathy is due to multiple small cerebral artifacts.

There is a clear alternative explanation for the encephalopathy. We studied a patient with cerebrospinal fluid (CSF) eosinophilia who had reversible dementia and HES and suggested an explanation for the encephalopathy. In 1933, Gordon[4] noted that neurotoxic effects from eosinophil-laden lymph node preparations after intracerebral inoculation produced encephalopathy, termed the *Gordon phenomenon*. In our case, computed tomography of the head showed periventricular white matter hypodensities, while magnetic resonance imaging (MRI) revealed confluent, increased signal around the ventricles.[5]

The literature cites several reports of encephalopathy with HES in which confusion, delusions, psychosis, or coma occurred.[6] Although possible mechanisms of cerebral injury include direct eosinophil infiltration or sludging of cells in small vessels, a direct toxic effect of eosinophil-derived neurotoxin has been invoked.[7,8] In our patient with CSF eosinophilia, the steroid-induced improvement in encephalopathy and dementia with reversal of CSF eosinophilia lends support to a Gordon phenomenon in humans.

Peter W. Kaplan, MB, BS, FRCP(UK)

Author Affiliation: Department of Neurology, Johns Hopkins Bayview Medical Center, Baltimore, Maryland.

©2011 American Medical Association. All rights reserved.
Downloaded From: http://jamanetwork.com/ on 05/19/2013