OBSERVATION

Reduced Uptake of FDOPA PET in End-stage Liver Disease With Elevated Manganese Levels

Susan R. Criswell, MD; Joel S. Perlmutter, MD; Jeffrey S. Crippin, MD; Tom O. Videen, PhD; Stephen M. Moerlein, PhD; Hubert P. Flores, MS; Angela M. Birke, BA; Brad A. Racette, MD

Objective: To investigate whether manganese toxicity secondary to end-state liver disease is associated with nigrastriatal dysfunction as measured by 6-[^{18}F]fluoro-L-DOPA (FDOPA) positron emission tomographic (PET) imaging.

Design: Observational case report.

Setting: The Movement Disorder Center at Washington University, St Louis, Missouri.

Patient: An individual with manganese toxicity secondary to end-stage liver disease. His FDOPA PET was compared with those of 10 idiopathic Parkinson disease patients and 10 age- and sex-matched healthy controls.

Main Outcome Measure: The average estimated net FDOPA uptake by Patlak graphical analysis for caudate, anterior putamen, and posterior putamen.

Results: The FDOPA uptake for the patient with secondary manganese toxicity was reduced across all regions by more than 2 SDs compared with healthy controls: caudate (reduced 24.7%), anterior putamen (28.0%), and posterior putamen (29.3%). The ratio of uptake between the caudate/posterior putamen was 0.99 and was different from that of idiopathic Parkinson disease patients, in whom the greatest reduction of FDOPA was in the posterior putamen (mean [SD] ratio, 1.65 [0.41]).

Conclusions: Reduce striatal uptake of FDOPA uptake indicates dysfunction of the nigrostriatal pathways in manganese toxicity secondary to end-stage liver disease. The pattern of striatal involvement with equal reduction of FDOPA uptake in the caudate compared with posterior putamen appears different from those previously reported in individuals with occupational manganese toxicity and idiopathic Parkinson disease and may be specific to manganese toxicity secondary to end-stage liver disease.

Arch Neurol. 2012;69(3):394-397

Author Affiliations:
Departments of Neurology (Drs Criswell, Perlmutter, Videen, and Racette, Mr Flores, and Ms Birke), Radiology (Drs Perlmutter, Videen, and Moerlein), Anatomy and Neurobiology (Dr Perlmutter), and Medicine (Dr Crippin) and Programs in Occupational Therapy (Dr Perlmutter) and Physical Therapy (Dr Perlmutter), Washington University School of Medicine, and American Parkinson Disease Association Advanced Center for Parkinson Research (Drs Criswell, Perlmutter, Videen, and Racette), St Louis, Missouri.

Manganese (neurotoxicity is characterized by progressive parkinsonism, dystonia, and neuropsychiatric features. Although initial reports focused on the clinical syndrome associated with occupational exposures,[1] individuals with end-stage liver disease (ESLD) are also at risk for manganese neurotoxicity secondary to impaired biliary clearance.[2] While the parkinsonian features of manganese neurotoxicity overlap with idiopathic Parkinson disease (IPD), some argue that these clinical syndromes are entirely separable.[3] Thus, the relationship between manganese toxicity and IPD remains controversial. Functional imaging of the dopaminergic system can provide evidence for the underlying pathophysiology of parkinsonian disorders and explore the relationships between IPD and manganese neurotoxicity. In particular, 6-[^{18}F]fluoro-L-DOPA (FDOPA) positron emission tomography (PET) can provide information about the integrity of the nigrostriatal dopaminergic pathway.[4] However, previous studies of individuals with elevated manganese levels have revealed conflicting results, including preferentially reduced uptake in the posterior putamen similar to IPD[5] and a unique pattern primarily affecting the caudate.[6]

REPORT OF A CASE

A 52-year-old man with a history of alcoholic cirrhosis was evaluated for liver transplantation 4 months after a diagnosis of hepatitis B and the development of esophageal varices, ascites, and jaundice. Results from a liver biopsy confirmed the diagnosis of cirrhosis. His medications at the time of examination included furosemide, lamivudine, phytonadione, potas-

©2012 American Medical Association. All rights reserved.
Downloaded From: http://jamanetwork.com/ on 05/25/2013

sium chloride, propranolol, aldactone, and thiamine hydrochloride. He had no history of neuroleptic use. He endorsed a remote history of intravenous drug abuse and heavy alcohol consumption but stopped 5 years prior to presentation. There was no family history of neurologic disease, and he denied any occupational exposure to manganese. He complained of a mild tremor of 2 months' duration. However, neurologic examination demonstrated mild parkinsonism with masked facies, symmetric action and postural tremor, bradykinesia, and rigidity. His gait was normal. A video-based blinded rating of the Unified Parkinson Disease Rating Scale motor, subsection 3 (UPDRS3),[7] examination at the time of imaging was 12. (Rigidity examination was not blinded.) His Modified Mini-Mental State score was 94 of 100.[8] The patient was offered a trial of levodopa but declined.

Hepatitis B HBe antibody was nonreactive while the HBe antigen was reactive with a HBV DNA polymerase chain reaction quantitative viral load of 273 000. His Model for End-Stage Liver Disease[9] score was 11, ceruloplasmin level was 32.9 mg/dL (reference range, 18.0-46.0 mg/dL), and serum manganese level was 301.39 nmol/L (reference 50-150 nmol/L). (To convert ceruloplasmin to milligrams per liter, multiply by 10.)

REFERENCE PATIENTS

The FDOPA results from our ESLD patient were compared with those of 10 male IPD patients and 10 healthy male controls who were recruited through the Movement Disorders Center at Washington University. Reference patients were age matched to the ESLD patient (±10 years). The IPD patients had probable Parkinson disease according to the criteria proposed by Gelb et al.[10] Controls were required to have no history of neurological disease and were excluded for a total UPDRS3 score higher than 3 or rest, postural, or action tremor score greater than 1.

This study was approved by the Washington University School of Medicine Human Research Protection Office, and all participants signed a written consent form.

NEUROIMAGING STUDIES

A high-resolution, 3-dimensional, magnetization-prepared rapid gradient echo (MPRAGE) image was acquired using a Siemens 3.0T Trio scanner. A reviewer blinded to the clinical status of the patient outlined volumes of interest in the caudate, globus pallidus, anterior, and posterior putamen and occipital (control) regions on the MPRAGE images. Manganese exposure is associated with increased T1 signal within the globus pallidus, and the intensity of the signal is traditionally measured in terms of a pallidal index defined as the ratio of T1 signal in the globus pallidus to a white matter reference region. Pallidal indices were calculated from the MPRAGE images as previously described.[2]

The PET imaging was acquired using an EXACT HR+ scanner (Knoxville, Tennessee) and coregistered with the MPRAGE image using the protocol previously described.[6] Decay-corrected regional PET counts were extracted from dynamic PET images using the magnetic resonance imaging–defined volumes of interest. Net FDOPA uptake (K_i) was computed using Patlak graphical analysis of the time-activity data from 24 to 94 minutes postinjection reflecting levodopa transport, neuronal decarboxylase activity, and dopamine storage capacity.[11]

Table. FDOPA PET K_i[a] Values for an ESLD Patient, IPD Patients, and Controls

Patient	Caudate	Anterior Putamen	Posterior Putamen
1 Patient with ESLD	0.0084	0.0080	0.0085
10 Patients with IPD, mean (SD)	0.0094 (0.0014)	0.0074 (0.0013)	0.0059 (0.0012)
10 Controls, mean (SD)	0.0111 (0.0012)	0.0111 (0.0010)	0.0120 (0.0021)

Abbreviations: ESLD, end-stage liver disease; FDOPA, 6-[^{18}F]fluoro-L-DOPA; IPD, idiopathic Parkinson disease; K_i, net FDOPA uptake; PET, positron emission tomography.
[a] These values are given as mean (SD) values in minutes^{-1}.

RESULTS

The MPRAGE T1-weighted sequence demonstrated increased signal in the bilateral globus pallidi in the ESLD patient. The pallidal index was elevated at 133.75 (reference range, 96.38-101.26). The average estimated FDOPA-PET K_i for each region (left- and right-sided averaged) is reported in the **Table** for the ESLD patient, IPD patients (mean [SD] age, 49.5 [7.0] years, mean UPDRS3 scores 19.7 [11.2]), and controls (mean age, 48 [15] years; mean UPDRS3 scores, 1.35 [1.16]). The FDOPA uptake for the ESLD patient was reduced across all volumes by more than 2 SDs compared with healthy controls: caudate (reduced 24.7%), anterior putamen (28.0%), and posterior putamen (29.3%) (Table). The ratio of uptake between the caudate/posterior putamen was 0.99, indicating that FDOPA uptake was equally affected across regions. This pattern of regional uptake differed from IPD patients, in whom the greatest reduction of FDOPA was in the posterior putamen as demonstrated by a mean (SD) caudate/posterior putamen ratio of 1.65 (0.41). The composite image from our patient and a representative control and an IPD patient are depicted in the **Figure**.

COMMENT

There are limited and conflicting data on dopaminergic function in individuals with manganese exposure and clinical parkinsonism. Initial studies of manganese toxicity reported normal FDOPA uptake and suggested the associated parkinsonism arose from postsynaptic dopaminergic dysfunction.[12] However, our recent FDOPA PET studies in occupational manganese toxicity associated with welding exposure demonstrate significantly reduced uptake in the caudate,[6] suggesting presynaptic dysfunction may be an important part of the pathophysiology of manganese toxicity. In the only previously available case report on a patient with ESLD and elevated blood man-

©2012 American Medical Association. All rights reserved.
Downloaded From: http://jamanetwork.com/ on 05/25/2013

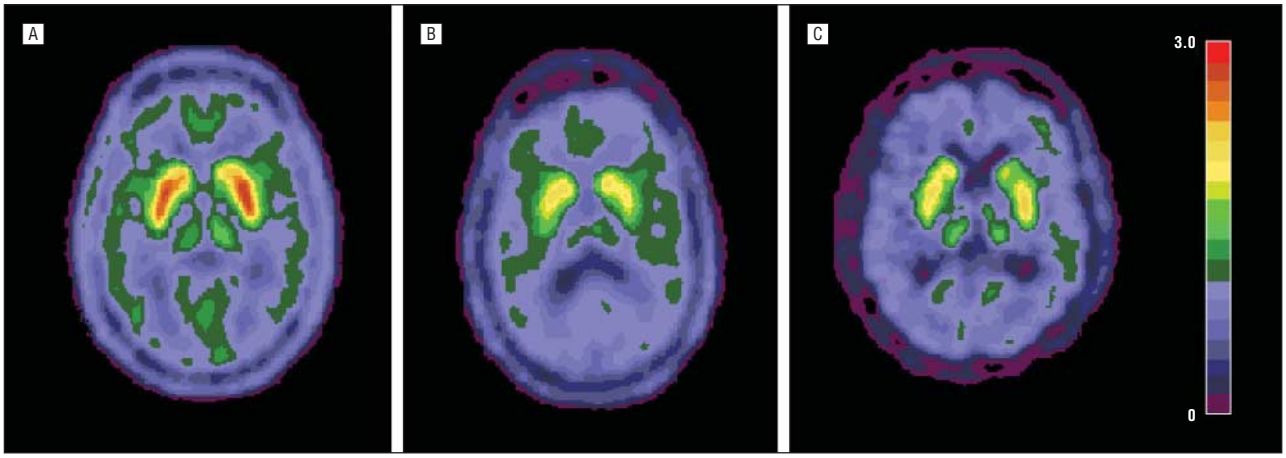

Figure. 6-[^{18}F]fluoro-L-DOPA (FDOPA) positron emission tomographic composite images of decay-corrected counts from 24 to 94 minutes from a representative control (A), an idiopathic Parkinson disease (IPD) patient (B), and an end-stage liver disease (ESLD) patient (C) normalized to the reference region. FDOPA uptake is equally reduced across regions in the ESLD patient in comparison with the control, whereas the posterior putamen is the most affected region in the IPD patient.

ganese, FDOPA uptake was globally reduced, with posterior putamen more affected than caudate.[5] This patient had moderate to severe parkinsonism with some features atypical for IPD, including severe, early gait impairment, and relatively symmetry parkinsonism on examination. Nevertheless, coexisting IPD could not be excluded as an etiology, and an autopsy was not obtained. In the current report, we describe an individual with ESLD and mild signs of symmetric parkinsonism. Elevated serum manganese levels and increased signal in the globus pallidus on T1-weighted imaging confirm exposure to manganese. Reduced striatal uptake of FDOPA in this patient again suggests presynaptic dysfunction of the nigrostriatal pathways secondary to manganese toxicity.

The caudate-putaminal ratio, which is simple to calculate, provides an objective measure of the striatal pattern of involvement. Interestingly, the pattern of relatively homogenous involvement throughout the striatum in our ESLD patient with a caudate/posterior putamen ratio of 0.99 appears to be distinct from the predominately posterior putamen pattern demonstrated in both the previous ESLD report[5] and our reference IPD patient (mean [SD] caudate/posterior putamen ratio, 1.65 [0.41]). Moreover, the pattern in our ESLD patient also differs from our recent findings in occupational manganese neurotoxicity. In that FDOPA PET study, 20 asymptomatic welders with manganese exposure demonstrated a significant reduction in FDOPA uptake in the caudate. We calculated the mean (SD) caudate/posterior putamen ratio of FDOPA uptake in that cohort as 0.82 (0.13).[6] We have only a single patient with ESLD, so this difference compared with our findings in the welders may reflect a chance finding. If confirmed in additional ESLD patients, the 2 patterns in manganese exposed patients could reflect a difference in the severity of disease between asymptomatic welders, the current mildly symptomatic ESLD patient, and the severely affected previous liver patient. Alternatively, this pattern may be specific to manganese toxicity secondary to ESLD, but these preliminary hypotheses require further study including more patients with symptomatic manganese toxicity. The abnormal FDOPA striatal uptake in this individual with ESLD demonstrates presynaptic nigrostriatal deficiency secondary to manganese toxicity that seems to follow a different pattern from that typically found in IPD.

Accepted for Publication: May 27, 2011.
Correspondence: Susan R. Criswell, MD, Washington University School of Medicine, 660 S Euclid Ave, Box 8111, St Louis, MO 63110 (criswells@neuro.wustl.edu).
Author Contributions: *Study concept and design:* Criswell and Racette. *Acquisition of data:* Criswell, Crippen, Moerlein, and Birke. *Analysis and interpretation of data:* Criswell, Perlmutter, Videen, Moerlein, Flores, Birke, and Racette. *Drafting of the manuscript:* Criswell. *Critical revision of the manuscript for important intellectual content:* Criswell, Perlmutter, Videen, Moerlein, Flores, Birke, and Racette. *Statistical analysis:* Criswell and Flores. *Obtained funding:* Racette. *Administrative, technical, and material support:* Perlmutter, Videen, Moerlein, Flores, and Birke. *Study supervision:* Perlmutter, Moerlein, and Racette.
Financial Disclosure: Dr Criswell has received research support from Merck (principal investigator [PI], Chiltern (subinvestigator), Teva (PI), and Medivation (PI). Dr Perlmutter serves on the scientific advisory boards of the American Parkinson Disease Association (APDA), the Dystonia Medical Research Foundation, the Missouri Chapter of the Dystonia Medical Research Fund, and the Greater St Louis Chapter of the APDA, and serves as an editorial board member of *Neurology*; has received travel expenses and/or honoraria for lectures or educational activities not sponsored by industry (University of Maryland, Toronto Western Hospital, Long Island Jewish Medical Center, Movement Disorders Society, American Academy of Neurology); has received honoraria from Ceregene for travel to lecture; has received honoraria from the Parkinson Disease Study Group for grant reviews; and has received partial fellowship support for fellows from Medtronic Inc; and has received research support from

©2012 American Medical Association. All rights reserved.
Downloaded From: http://jamanetwork.com/ on 05/25/2013

Express Scripts. Ms Birke holds common share positions in Merck and in Bristol-Meyers Squibb. Dr Racette has received research support from Teva (PI), Eisai (PI), and Solvay (PI); and has received research support from Schwarz (PI), Solstice (PI), Eisai (PI), Allergan (PI), and Neurogen (PI).

Funding/Support: This work was supported by the Michael J. Fox Foundation; National Institutes of Health grants R01 ES013743, K24 ES017765, KL2 RR024994, P42ES04696, 5T32NS007205-27, RO1 NS41509, RO1 NS058714, NCRR UL1 RR024992, and NS057105; the American Parkinson Disease Association (APDA) Advanced Research Center at Washington University; the Greater St Louis Chapter of the APDA; the McDonnell Center for Higher Brain Function; and the Barnes-Jewish Hospital Foundation (Elliot Stein Family Fund and Jack Buck Fund for Parkinson Disease Research).

REFERENCES

1. Rodier J. Manganese poisoning in Moroccan miners. *Br J Ind Med*. 1955;12(1):21-35.
2. Spahr L, Butterworth RF, Fontaine S, et al. Increased blood manganese in cirrhotic patients: relationship to pallidal magnetic resonance signal hyperintensity and neurological symptoms. *Hepatology*. 1996;24(5):1116-1120.
3. Jankovic J. Searching for a relationship between manganese and welding and Parkinson's disease. *Neurology*. 2005;64(12):2021-2028.
4. Yee RE, Irwin I, Milonas C, et al. Novel observations with FDOPA-PET imaging after early nigrostriatal damage. *Mov Disord*. 2001;16(5):838-848.
5. Racette BA, Antenor JA, McGee-Minnich L, et al. [18F]FDOPA PET and clinical features in parkinsonism due to manganism. *Mov Disord*. 2005;20(4):492-496.
6. Criswell SR, Perlmutter JS, Videen TO, et al. Reduced uptake of [^{18}F]FDOPA PET in asymptomatic welders with occupational manganese exposure. *Neurology*. 2011;76(15):1296-1301.
7. Fahn S, Elton RL; Members of UPDRS Development Committee. Unified Parkinson's disease rating scale. In: Fahn S, Marsden CD, Goldstein M, Calne DB, eds. *Recent Developments in Parkinson's Disease*. New York, NY: Macmillan; 1987:153-163.
8. Teng EL, Chui HC. The Modified Mini-Mental State (3MS) examination. *J Clin Psychiatry*. 1987;48(8):314-318.
9. Kamath PS, Wiesner RH, Malinchoc M, et al. A model to predict survival in patients with end-stage liver disease. *Hepatology*. 2001;33(2):464-470.
10. Gelb DJ, Oliver E, Gilman S. Diagnostic criteria for Parkinson disease. *Arch Neurol*. 1999;56(1):33-39.
11. Heiss WD, Hilker R. The sensitivity of 18-fluorodopa positron emission tomography and magnetic resonance imaging in Parkinson's disease. *Eur J Neurol*. 2004;11(1):5-12.
12. Wolters EC, Huang CC, Clark C, et al. Positron emission tomography in manganese intoxication. *Ann Neurol*. 1989;26(5):647-651.

©2012 American Medical Association. All rights reserved.
Downloaded From: http://jamanetwork.com/ on 05/25/2013