REVIEW ARTICLE

The Perforated Duodenal Diverticulum

Chad M. Thorson, MD; Pedro S. Paz Ruiz, MD; Rosiane A. Roeder, MD; Danny Sleeman, MD; Victor J. Casillas, MD

Objective: To perform a literature review of perforated duodenal diverticulum with attention to changes in management.

Data Sources: We searched PubMed for relevant studies published from January 1, 1989, through August 1, 2011. In addition, we identified and reviewed 4 cases at our institution.

Study Selection: Search phrases were *perforated duodenal diverticulum* and *duodenal diverticulitis*.

Data Extraction: Patient demographics, clinical characteristics, radiologic findings, treatment, and outcomes were obtained.

Results: We reviewed 39 studies producing 57 cases, which were combined with the 4 at our institution for a total of 61 patients. The addition of 2 previous series revealed a total of 162 patients in the world literature. Perforations were most commonly located in the second or third portion of the duodenum (60 of 61 cases [98%]), and the most frequent cause was diverticulitis (42 of 61 [69%]). There has been a dramatic improvement in the preoperative diagnosis of perforated diverticula. Only 13 of 101 reported cases (13%) were correctly diagnosed before 1989, and 29 of 61 (48%) in the present series were identified with radiologic examinations. Most patients in the current series (47 of 61) underwent operative treatment for their perforation, although 14 underwent successful nonoperative management. Complications were reported in 17 of 47 patients in the surgical group (36%), whereas only 1 complication was seen in patients undergoing nonoperative management. Mortality in the surgical group was 6% (3 of 47), and no deaths were reported in the nonoperative group.

Conclusions: Perforation of a duodenal diverticulum is rare, with only 162 cases reported in the world literature. Nonoperative management has emerged as a safe, practical alternative to surgery in selected patents.

Arch Surg. 2012;147(1):81-88

Pierre Jean Baptiste Chomel,[1] a French pathologist, provided the first description of a duodenal diverticulum in 1710. The prevalence has been found to be as high as 22% in autopsy series, but most cases are asymptomatic. Perforation is a rare complication of duodenal diverticula. Until 1989, only 101 cases of perforated duodenal diverticula were reported in the literature. Juler et al[2] published a collection of 56 cases in 1969, followed by 45 additional cases reported by Duarte et al[3] in 1992. Most were treated surgically, with complications commonly encountered. The purpose of this review is to present 4 cases of perforated diverticula that underwent nonoperative management at our institution. In addition, we reviewed case reports and case series published in 1989 or later to provide an update of the world literature on the subject.

See Invited Critique at end of article

Author Affiliations: Dewitt Daughtry Family Department of Surgery (Drs Thorson, Roeder, and Sleeman) and Department of Radiology (Drs Paz Ruiz and Casillas), University of Miami Miller School of Medicine, Miami, Florida.

METHODS

This study was fully approved by the University of Miami institutional review board. Four patients were treated for a perforated duodenal diverticulum at our institution from January 1, 2009, through June 30, 2010. Inpatient medical records and radiologic films were reviewed. A comprehensive systematic literature review was conducted to identify all cases of perforated duodenal diverticula reported since the series by Duarte et al.[3] We identified a total of 39 articles. When combined with our 4 cases, 61 patients were included in the analysis. Information about demographics, clinical presentation, radiologic findings, treatment, and outcomes were obtained from the literature. Data were compiled using a spreadsheet application (Microsoft Excel; Microsoft Corporation) and statistical analyses were performed using commercially available software (SPSS, version 18.0; SPSS, Inc) with a significance level set at .05. Dichotomous variables

©2012 American Medical Association. All rights reserved.
Downloaded From: http://jamanetwork.com/ on 05/22/2013

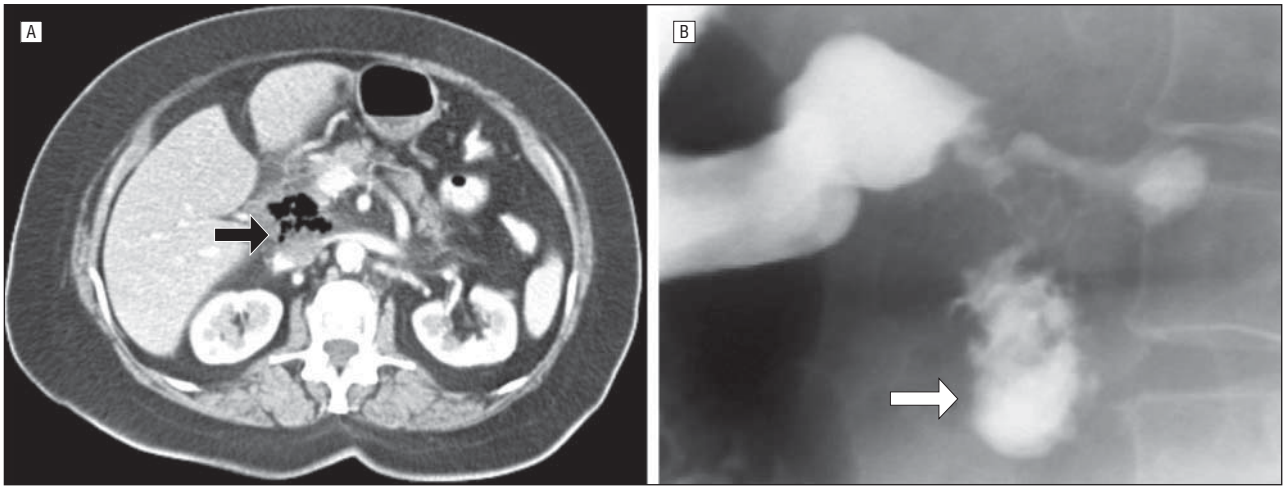

Figure 1. Radiologic images in a 72-year-old woman in the present series. A, Axial computed tomographic image of perforated duodenal diverticulum demonstrated by complex collection with fluid and gas (arrow) surrounding the second and third portion of the duodenum. B, Upper gastrointestinal tract series demonstrates an outpouching (arrow) in the medial aspect of the second portion of the duodenum.

Figure 2. Perforated duodenal diverticulum in a 62-year-old man with a 1-day history of abdominal pain in the present series. Axial computed tomographic image revealing fluid and gas (arrow) near the third portion of the duodenum and associated fat stranding (arrowheads).

were assessed using χ^2 analysis or the Fisher exact test when appropriate.

REPORT OF CASES

CASE 1

A 72-year-old woman presented to the emergency department with a 4-hour history of epigastric and right upper quadrant pain. The pain was associated with episodes of increased intensity that were relieved with vomiting. Medical history included hypertension, hyperlipidemia, and cholecystectomy. In addition, the patient had a history of pancreatitis 3 years previously due to ampullary fibrosis and treatment with endoscopic retrograde cholangiopancreatography and sphincterotomy. Results of the examination revealed tenderness without evidence of peritonitis. In the emergency department, she developed a fever of 39.0°C. Laboratory tests revealed an elevated leukocyte count of 15.4×10^3 cells/μL (to convert to cells $\times 10^3$ cells per liter, multiply by 0.001), but results were otherwise normal. A plain abdominal radiograph revealed no abnormalities. Owing to the history of ampullary fibrosis, abdominal ultrasonography was performed, revealing normal ductal structure without dilation or stones. Computed tomography (CT) with oral and intravenous contrast showed a complex collection containing extraluminal air and fluid (**Figure 1**A). The collection was located superior to the second portion of the duodenum, associated with thickening of the duodenal wall, retroperitoneal fat stranding, and absence of contrast extravasation. The presumptive diagnosis was a contained perforated duodenal ulcer. The patient was admitted to the acute care surgical service for intravenous antibiotics and bowel rest. An upper gastrointestinal tract (GI) series with barium was obtained during the hospital stay. Findings included an outpouching measuring $2.8 \times 3.4 \times 2.6$ cm in the medial aspect of the duodenum consistent with a duodenal diverticulum (Figure 1B). The patient improved with antibiotic therapy, total parenteral nutrition, and bowel rest and was discharged on hospital day 13 without complications.

CASE 2

A 62-year-old man presented to the emergency department with an 8-hour history of abdominal pain located in the right flank and back. He denied fever, nausea, and vomiting. Medical history included hypertension and diabetes mellitus. Surgical history was significant for an exploratory laparotomy after a motor vehicle crash leading to splenectomy. Results of the examination revealed tenderness in the right upper quadrant and costo-

©2012 American Medical Association. All rights reserved.
Downloaded From: http://jamanetwork.com/ on 05/22/2013

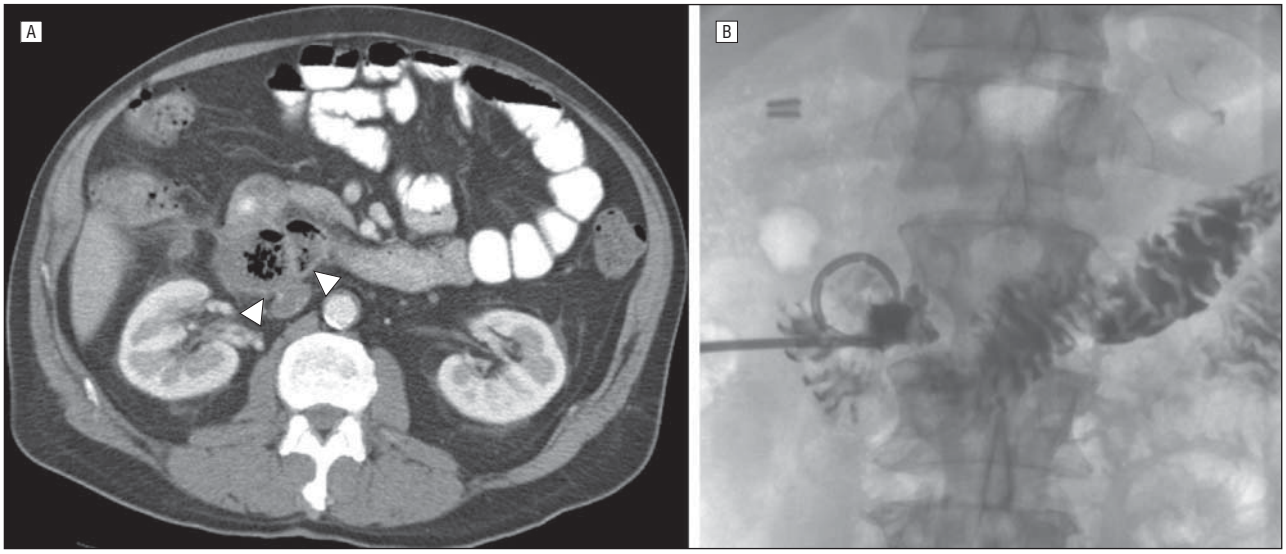

Figure 3. Radiographic images in a 62-year-old man in the present series. A, Suspected duodenal perforation denoted by retroperitoneal air (arrowheads). B, Abscessogram demonstrating diverticulum near the second portion of the duodenum without active contrast extravasation.

phrenic angle with absence of peritoneal signs. Initial non–contrast-enhanced CT was performed (renal stone protocol), revealing inflammatory mesenteric stranding in the head of the pancreas. Acute pancreatitis was suspected. Laboratory test results included an elevated white blood cell count at 13.4×10^3 cells/μL. Abdominal ultrasonography showed a hypoechoic structure measuring 4.0×2.3 cm in the pancreatic neck. The hepatobiliary surgical service was consulted owing to a suspected infected pancreatic pseudocyst or a cystic neoplasm. A follow-up CT with oral and intravenous contrast revealed an extraluminal collection measuring 6.0×1.8 cm inferior to the third portion of the duodenum containing air and contrast medium (**Figure 2**). The patient was admitted with suspected retroperitoneal perforation of a duodenal ulcer and was treated with intravenous antibiotics and bowel rest. A subsequent upper GI series demonstrated a duodenal diverticulum measuring $6.0 \times 2.0 \times 3.0$ cm near the head of the pancreas with extravasation of contrast. The patient improved without complications and was discharged on hospital day 13.

CASE 3

A 56-year-old woman with a history of hypertension and gastroesophageal reflux disease presented to an outside hospital with a 1-week history of epigastric pain, nausea, vomiting, and anorexia. Results of the workup revealed a possible duodenal perforation, and the patient was transferred to our institution for continued care. On arrival, the patient complained of mild abdominal discomfort. She was afebrile. Examination results revealed a tender abdomen without peritonitis. Laboratory findings included a white blood cell count within the reference range. Review of the CT scan from the outside hospital showed perforation of the second and third portion of the duodenum with extraluminal air and fluid. She was admitted with suspected duodenal perforation but, given the location, perforation of an inflamed diverticulum was also suspected. The patient received intravenous antibiotics and bowel rest. Results of an upper GI series confirmed a diverticulum along the medial aspect of the second portion of the duodenum. She continued to receive total parenteral nutrition for 14 days before transition to a regular diet and was discharged on hospital day 18.

CASE 4

A 62-year-old man presented to the emergency department after a 2-week history of epigastric pain diagnosed as colitis while on vacation in Mexico. He was afebrile, denied nausea or vomiting, and had a white blood cell count of 7.5×10^3 cells/μL. On examination, he demonstrated epigastric tenderness without peritoneal signs. He underwent contrast-enhanced CT of the abdomen, which revealed a 6.3×4.5–cm abscess posterior to the second portion of the duodenum, inferior to the pancreatic head (**Figure 3**A). He was admitted to the general surgical service with suspected contained duodenal perforation. He underwent conservative management with bowel rest, total parenteral nutrition, intravenous antibiotic therapy, and percutaneous drainage for 4 weeks. An abscessogram performed 1 week later demonstrated a cavity connecting with the second portion of the duodenum, and results of an upper GI series confirmed the presence of a duodenal diverticulum in this location (Figure 3B). The remainder of the hospital course was uneventful.

REVIEW OF LITERATURE

HISTORY AND CAUSES

The duodenum follows the colon as the second most common place for diverticula.[4] They were first described by Chomel[1] in 1710. The prevalence of duodenal diverticula depends on the mode of diagnosis, present in 5% to 10% of barium radiographic series and 22% of autopsy findings.[5-7] Primary congenital diverticula are extremely rare and are composed of all layers of the intes-

©2012 American Medical Association. All rights reserved.
Downloaded From: http://jamanetwork.com/ on 05/22/2013

tinal wall. The most frequent type is secondary acquired pseudodiverticula, which contain only mucous and serous layers. They are pulsion diverticula resulting from a combined defect in the duodenal wall and increased intraluminal pressure.[6] As with colonic diverticula, herniation of the mucosa occurs at sites where the muscularis layer is weakened by the passage of blood vessels.[3,8] The distribution of duodenal diverticula is not uniform, with most occurring along the pancreatic or mesenteric border in the second or third portions of the duodenum.[5] Most are within 2.5 cm of the ampulla of Vater and therefore are referred to as *parivaterian diverticula*.[8]

Prevalence increases with age and is 10% to 27% in patients older than 50 years.[6] The average age in the present series was 64 (range, 32-94) years (**Table 1**). Previous studies state that there is no sex predilection,[8] although 41 patients (67%) in our series were female.

CLINICAL PRESENTATION

Duodenal diverticula produce symptoms in 5% to 10% of cases, which may arise from inflammation of the diverticulum, compression of biliopancreatic structures, hemorrhage, or perforation.[3,9-11,47] Compared with their colonic counterparts, duodenal diverticula are believed to be less common sites of inflammation because of their larger size, more rapid intraluminal flow, and smaller bacterial count.[48] Perforation of a diverticulum is one of the most rare and potentially serious complications, first reported in an autopsy by Bassett[49] in 1907. It is thought to occur because of the thin wall present in most diverticula and is most commonly seen along the medial wall of the second portion of the duodenum within 2 cm of the ampulla of Vater.[12,50] **Table 2** summarizes the location and causes of perforation in the literature. Perforation arose from diverticula located in the second or the third portion of the duodenum in 60 of 61 cases (98%). Consistent with the previous literature,[2,3] the most common cause of perforation of a duodenal diverticulum is diverticulitis, seen in 42 patients (69%) in the present series. When all 3 series were combined (Table 2),[2,3] the most common cause was diverticulitis, seen in 62% of patients, followed by enterolithiasis (10%), iatrogenic (5%), ulceration (5%), trauma (4%), and foreign body (2%).

The clinical presentation varies greatly and requires a high index of suspicion. Symptoms attributed to a perforated duodenal diverticulum are vague and nonspecific and are often mistaken for other intra-abdominal processes, such as cholecystitis, pancreatitis, peptic ulcer disease, colitis, or retrocecal appendicitis.[48] The most challenging of the differential diagnoses is perforated duodenal ulcer, which can also result in extraluminal gas and fluid. A distinguishing feature is the location of perforation because most ulcers involve the duodenal bulb, whereas diverticula affect more distal portions.[12]

In the present series, the most common presenting symptom was abdominal pain, seen in 50 patients (82%). Pain eventually developed in nearly every patient (58 patients [98%]), and other commonly occurring symptoms were fever (20 [33%]) and nausea/vomiting (24 [34%]). Results of a physical examination revealed tenderness in 49 patients (80%), leukocytosis in 26 (43%), and peritonitis in 21 (34%). There was no significant difference in clinical presentation of those undergoing operative vs nonoperative management. Pain was present in all 47 patients (100%) undergoing operative vs 13 of 14 (93%) undergoing conservative management ($P=.20$), and tenderness on examination was seen in 40 of 41 (98%) vs 9 of 10 (90%) ($P=.36$). Although the observed rate of peritonitis was higher in surgical patients (21 of 41 patients [51%] vs 1 of 8 [13%]), the result was not statistically significant ($P=.06$).

METHOD OF DIAGNOSIS

Radiologic imaging has been traditionally disregarded as a useful tool in the diagnosis of perforated duodenal diverticulum. Until 1989, only 13 of the reported 101 cases received a correct preoperative diagnosis.[3] In most cases, plain abdominal radiographs did not demonstrate intra-abdominal, retroperitoneal, or paraduodenal air.[3] Upper GI series are able to effectively identify the diverticulum in 80% of cases but are unable to demonstrate extravasation of contrast in most.[13] Ultrasonography has been used in conjunction with CT but has limited utility as a sole diagnostic modality.[14] The use of multisection helical CT scanners has improved radiologic diagnosis owing to its ability to detect small amounts of gas and fluid in the retroperitoneum. Although some advocate repeated CT or ultrasonographic examination to confirm resolution of the inflammatory process,[13,51] many patients, including the 4 at our institution, have undergone successful management without repeated radiologic examinations.

Of the 57 patients who received a diagnostic imaging test as the initial examination, 26 (46%) underwent plain abdominal radiography; 24 (42%), CT; 6 (11%), abdominal ultrasonography; and 1 (2%), an upper GI series. Computed tomographic scans were used most commonly overall, with 52 patients (85%) receiving one for diagnostic purposes during their hospitalization. The use of varied diagnostic modalities likely reflects the complexity of presentation and the inability to distinguish perforated duodenal diverticula from other intra-abdominal processes. In addition, the diagnosis is not uniformly clear, with only 16 patients (26%) in the present series receiving a correct diagnosis at the time of admission (**Table 3**). This finding represents an improvement over previous series, however, because an accurate diagnosis was obtained with the use of radiologic findings in 29 patients (48%) (Table 1).

TREATMENT

Once a perforated duodenal diverticulum has been diagnosed, traditional management has been surgical. Stapled or hand-sewn diverticulectomy (1- or 2-layer closure) with drainage of the retroperitoneal space is the most commonly used repair and was performed in 23 of the 47 operative cases in our series (49%). Use of an omental patch as reinforcement,[15,16] laparoscopic diverticulectomy,[17,52,53] and isolated drainage of retroperitoneum were also reported. More advanced surgical treatment, such as Whipple procedures, were required when significant

©2012 American Medical Association. All rights reserved.
Downloaded From: http://jamanetwork.com/ on 05/22/2013

Table 1. Reported Cases of Perforated Duodenal Diverticulum, 1989-2011

Source	Sex/ Age, y	Chief Presenting Symptom	Location in Duodenum Portion	Method of Diagnosis	Treatment	Complications
Present study	F/72	Pain	Second	UGI	Bowel rest, antibiotics[a]	None
	M/62	Pain	Second	UGI	Bowel rest, antibiotics[a]	None
	F/56	Pain	Second	UGI/CT	Bowel rest, antibiotics[a]	None
	M/62	Pain	Second	UGI	Bowel rest, antibiotics[a]	None
Metcalfe et al,[16] 2010	M/58	Pain	Second/third	OR	Diverticulectomy, omental patch	Wound dehiscence
Lee et al,[17] 2010	F/61	Pain	Second	OR	Laparoscopic diverticulectomy	None
Volchok et al,[20] 2009	F/52	Pain	Second	OR	Diverticulectomy	None
Park et al,[21] 2009	F/69	Pain	Second	ERCP/CT	Diverticulectomy	None
López-Zárraga et al,[6] 2009	F/44	Pain	Second	OR	Diverticulectomy	Papilla obstruction, hepaticojejunostomy
Ames et al,[12] 2009	F/52	Pain	Third	OR	OR, not discussed	Prolonged course in 1 patient and 2 deaths overall
	M/46	Pain	Second	OR	OR, not discussed	
	M/71	Pain	Second	OR	OR, not discussed	
	F/57	Pain	Second	UGI	Bowel rest, antibiotics[a]	
	M/73	Pain	Second	CT	Bowel rest, antibiotics[a]	
	F/64	Bleeding	Second	CT	Bowel rest, antibiotics[a]	
	F/60	Bleeding	Third	OR	OR, not discussed	
	F/90	Pain	Third	OR	OR, not discussed	
Schnueriger et al,[18] 2008	M/68	Pain	Fourth	OR	Duodenectomy, duodenojejunostomy	None
	F/70	Pain	Second/third	CT	Pyloric-sparing Whipple	None
	X	Pain	Third	ERCP	PTC tube, bowel rest, antibiotic[a]	None
Martinez-Cecilia et al,[10] 2008	F/85	Pain	Second	UGI	Bowel rest, antibiotics[a]	RP collection
Guinier and Kovacs,[22] 2008	F/91	Pain	Second	CT	Diverticulectomy, gastrojejunostomy	None
Chen et al,[23] 2008	M/53	Pain	Second	OR	Abscess drainage, jejunostomy	None
Huang et al,[19] 2007	F/63	Pain	Second	CT/UGI	Diverticulectomy	None
Andromanakos et al,[24] 2007	M/62	Pain	Second	UGI	Diversion (antrectomy with gastroenteric anastomosis)	None
Valenzuela Martínez et al,[25] 2006	F/73	Pain	Second	OR	Diverticulectomy	Prolonged course
Safioleas et al,[26] 2006	M/68	Pain	Second	OR	Drainage, gastrojejunostomy, cholecystojejunostomy	None
Castellví et al,[27] 2006	M/50	Pain	Third	OR	Pyloric exclusion, gastrojejunostomy	Multisystem organ failure, fistula
Papalambros et al,[28] 2005	F/45	Fever	Third	OR	Diverticulectomy, right hemicolectomy	None
Miller et al,[13] 2005	F/94	Pain	Third	CT	Primary closure, diversion (pyloric exclusion, gastrojejunostomy)	Sepsis, pneumonia
	F/56	Pain	Second	CT		None
	M/63	Malaise	Second	CT/UGI	Bowel rest, antibiotics[a]	None
Marhin and Amson,[15] 2005	F/58	Pain	Second	CT	Diverticulectomy, omental patch	None
	F/61	Pain	Second	CT	Bowel rest, antibiotics[a]	None
Lee et al,[29] 2005	F/74	Pain	Second	OR	Roux-en-Y duodenojejunostomy	None
Bergman et al,[30] 2005	F/62	Pain	Second	CT	Diverticulum inversion	None
Yokomuro et al,[31] 2004	F/68	Pain	Second	OR	Primary closure	None
Sakurai et al,[11] 2004	F/81	Pain	Second	UGI	Diverticulectomy	Minor bile leakage
Yarze,[32] 2002	F/89	Pain	Second	ERCP	Diverticulectomy	None
Franzen et al,[33] 2002	M/59	Pain	Second	OR	Diverticulectomy	None
Atmani et al,[34] 2002	F/83	Trauma	Second	CT/UGI	Diverticulectomy, lateral duodenostomy, T tube	None
	F/68	Pain	Second	OR		Sepsis, pneumonia
Gulotta et al,[35] 2001	M/42	Pain	Second	OR	Diverticulectomy, gastrojejunostomy	None
Eeckhout et al,[9] 2000	F/49	Pain	Second	CT	Bowel rest, antibiotics, percutaneous drain[a]	None
Tsukamoto et al,[36] 1999	F/85	Pain	Second	OR	Diverticulectomy	None
	F/66	Pain	Second	EGD	Endoscopic lithotomy, percutaneous drain[a]	None
Rao,[37] 1999	M/50	Pain	Third	CT	OR	X
Poostizadeh et al,[38] 1997	F/78	Pain	Second/third	OR	Diverticulectomy, gastrostomy	Death: ruptured PA
Ido et al,[14] 1997	F/41	Pain	Second	US	Diverticulectomy	None
Cavanagh,[39] 1996	M/71	Jaundice	Second	Fluoro	Malecot drainage in diverticulum	PE, thrombophlebitis
Berki,[40] 1995-1996	M/72	Pain	Second	Autopsy	Appendectomy, drainage	Death
Mehdi et al,[41] 1994	F/69	Pain	Second	OR	Diverticulectomy	Sepsis/death
	M/51	Shock	Third	OR	Diverticulectomy	Sepsis/shock
Guglielmi et al,[42] 1993	F/33	Trauma	Second	OR	Diverticulectomy, diversion	RP collection
	F/92	Pain	Second	OR		Pneumonia
Elder and Stevenson,[43] 1993	F/73	Dyspnea	Second	ERCP	Stent removal[a]	None
Umbricht-Sprüngli et al,[44] 1992	F/63	Pain	Second	OR	Cholecystectomy, T tube, drainage	Recurrence
Pugash et al,[45] 1990	F/74	Pain	Second	OR	Aspiration/drainage	None
	F/63	Pain	Second	OR	Drainage, T tube	None
Steinman et al,[46] 1989	M/32	Pain	Third	OR	Drainage	None
	F/45	Shock	Second/third	OR	Drainage	High-output fistula

Abbreviations: CT, computerized tomography; EGD. esophagogastroduodenoscopy; ERCP, endoscopic retrograde cholangiopancreatography; Fluoro, fluoroscopy; OR, operating room; PA, pulmonary artery; PE, pulmonary embolism; PTC, percutaneous transhepatic cholangiogram; RP, retroperitoneum; UGI, upper gastrointestinal tract series; US, ultrasonography; X, unknown.

[a] Indicates nonoperative management.

©2012 American Medical Association. All rights reserved.

Downloaded From: http://jamanetwork.com/ on 05/22/2013

Table 2. Causes of Perforation in 162 Cases of Perforated Duodenal Diverticula

Cause	Series, No. (%) of Cases[a]			
	Juler et al[2]	Duarte et al[3]	Present Series	All
Diverticulitis	40 (71)	19 (40)	42 (69)	**101** (62)
Enterolithiasis	6 (11)	7 (15)	4 (7)	**17** (10)
Iatrogenic	0	0	9 (15)	**9** (5)
Ulceration	9 (16)	0	0	**9** (5)
Trauma	0	1 (2)	5 (8)	**6** (4)
Foreign body	1 (2)	1 (2)	1 (2)	**3** (2)
Not specified	0	19 (40)	0	**19** (12)
Total	**56** (100)	**47** (100)[b]	**61** (100)	**164** (100)[b]

[a] Percentages have been rounded and might not total 100.
[b] Two patients had more than 1 cause specified.

Table 3. Admission/Preoperative Diagnosis in 61 Cases

Diagnosis	No. (%) of Cases
Perforated duodenal diverticulum	16 (26)
Duodenal perforation	12 (20)
Biliary	5 (8)
Perforated viscous	4 (7)
Acute abdomen	2 (3)
Appendicitis	2 (3)
Other/not specified	20 (33)

perforation and surrounding tissue destruction were present.[18,54] Evidence of whether a gastric diversion procedure such as pyloric exclusion, gastroenteric anastomosis, or tube duodenostomy is necessary to protect the closure is incomplete.[19] Regardless of the operative strategy used, careful attention should be directed to the location of the diverticulum with respect to the biliary system. This is accomplished by placing a Fogarty balloon catheter into the duodenum via a choledochotomy or cholecystotomy, enabling the surgeon to safely identify the ampulla of Vater.[13,20]

Shackleton[55] first reported nonoperative management of perforated duodenal diverticulum in 1963. Only 5 other cases were reported from 1963 to 1989,[4,55-57] and 2 of these patients had duodenocolic fistulas.[57] Conservative management was initially reserved for patients at high risk for surgical intervention, such as those with advanced age and/or significant comorbid conditions. In the present series, 14 patients (23%) were successfully treated without operative intervention (Table 1). Nonoperative management included bowel rest with or without nasogastric suction, intravenous fluid hydration, intravenous antibiotic therapy, and initiation of total parenteral nutrition when a prolonged course was anticipated. If necessary, percutaneous catheter drainage for significant intra-abdominal abscess can be pursued as adjunctive treatment.[58]

The clinical condition and hemodynamic stability of the patient should guide therapeutic management. Patients presenting in extremis with peritoneal signs and intra-abdominal sepsis should be taken promptly for operative intervention.[13] Most patients will present with less impressive clinical signs. Initiation of bowel rest, intravenous hydration, and parenteral antibiotics should be prompt, with close clinical observation and frequent physical examination to detect evidence of disease progression. In the case of deterioration or diagnostic uncertainty, operative treatment must be used.

OUTCOMES

The mortality rate in the original series of perforated duodenal diverticula from 1907 to 1969 was 34%,[2] with a decrease to 13% from 1969 to 1989.[3] There were 5 total deaths in our series, for a mortality rate of 8%. The management strategy was not identifiable in 2 patients who died,[12] and the remaining 3 deaths were in patients who underwent surgical management. The progressive decrease in mortality since 1907 may represent improvement in perioperative care, development of broad-spectrum antibiotics, advances in diagnostic tests, and/or increased awareness of this rare entity. Other complications, such as duodenal fistulas, intra-abdominal abscesses, sepsis, and wound infections, occurred in nearly half the patients before 1989.[2,3] In the present series, complications were reported in 20 of 61 (33%). In the subset of patients undergoing nonoperative management, only 1 complication was reported with development of an intra-abdominal abscess treated successfully with percutaneous drainage. Unfortunately, because diverticular perforations were identified from case reports and small case series, long-term outcome data were unavailable.

CONCLUSIONS

Although duodenal diverticula are common entities, sequelae such as perforation remain rare complications, with only 162 cases reported in the world literature. A high index of suspicion is required for timely correct diagnosis because signs and symptoms often mimic other intra-abdominal processes. Although nonoperative management was initially reserved for patients with advanced age and significant comorbid conditions, improvements in critical care have allowed nonoperative management to be a practical alternative to surgery in selected patients.

Accepted for Publication: July 20, 2011.

©2012 American Medical Association. All rights reserved.
Downloaded From: http://jamanetwork.com/ on 05/22/2013

Correspondence: Chad M. Thorson, MD, Dewitt Daughtry Family Department of Surgery, Ryder Trauma Center, University of Miami Miller School of Medicine, Room T245, 1850 NW Ninth Ave, Miami, FL 33136 (cthorson@med.miami.edu).

Author Contributions: *Study conception and design:* Thorson, Sleeman, and Casillas. *Acquisition of data:* Thorson, Paz Ruiz, and Casillas. *Analysis and interpretation of data:* Thorson and Roeder. *Drafting of manuscript:* Thorson, Paz Ruiz, and Casillas. *Critical revision of the manuscript for important intellectual content:* Thorson, Paz Ruiz, Roeder, Sleeman, and Casillas. *Statistical analysis:* Thorson. *Study supervision:* Sleeman and Casillas.

Financial Disclosure: None reported.

Additional Contributions: Reginald Pereira, BS, Jeremy Olloqui, BS, and Michael Roeder, BA, provided translation of non-English articles.

REFERENCES

1. Chomel J. Report of a case of duodenal diverticulum containing gallstones. *Hist Acad R Sci Paris*. 1710:48-50.
2. Juler GL, List JW, Stemmer EA, Connolly JE. Perforating duodenal diverticulitis. *Arch Surg*. 1969;99(5):572-578.
3. Duarte B, Nagy KK, Cintron J. Perforated duodenal diverticulum. *Br J Surg*. 1992; 79(9):877-881.
4. Van Beers B, Trigaux JP, De Ronde T, Melange M. CT findings of perforated duodenal diverticulitis. *J Comput Assist Tomogr*. 1989;13(3):528-530.
5. Jones TW, Merendino KA. The perplexing duodenal diverticulum. *Surgery*. 1960; 48:1068-1084.
6. López Zárraga F, Saenz De Ormijana J, Diez Orive M, et al. Abdominal pain in a young woman (2009: 8b). *Eur Radiol*. 2009;19(11):2783-2786.
7. Ackermann W. Diverticula and variations of the duodenum. *Ann Surg*. 1943;117 (3):403-413.
8. Cattell RB, Mudge TJ. The surgical significance of duodenal diverticula. *N Engl J Med*. 1952;246(9):317-324.
9. Eeckhout G, Vanstiphout J, Van Pottelbergh I, et al. Endoscopic treatment of a perforated duodenal diverticulum. *Endoscopy*. 2000;32(12):991-993.
10. Martinez-Cecilia D, Arjona-Sanchez A, Gomez-Alvarez M, et al. Conservative management of perforated duodenal diverticulum: a case report and review of the literature. *World J Gastroenterol*. 2008;14(12):1949-1951.
11. Sakurai Y, Miura H, Matsubara T, Imazu H, Hasegawa S, Ochiai M. Perforated duodenal diverticulum successfully diagnosed preoperatively with abdominal CT scan associated with upper gastrointestinal series. *J Gastroenterol*. 2004;39 (4):379-383.
12. Ames JT, Federle MP, Pealer KM. Perforated duodenal diverticulum: clinical and imaging findings in eight patients. *Abdom Imaging*. 2009;34(2):135-139.
13. Miller G, Mueller C, Yim D, et al. Perforated duodenal diverticulitis: a report of three cases. *Dig Surg*. 2005;22(3):198-202.
14. Ido K, Agata H, Toshimitsu K, Kimura K, Suzuki T. Preoperative diagnosis of perforated duodenal diverticulum with ultrasonography. *J Clin Ultrasound*. 1997; 25(3):149-153.
15. Marhin WW, Amson BJ. Management of perforated duodenal diverticula. *Can J Surg*. 2005;48(1):79-80.
16. Metcalfe MJ, Rashid TG, Bird RleR. Isolated perforation of a duodenal diverticulum following blunt abdominal trauma. *J Emerg Trauma Shock*. 2010;3(1): 79-81.
17. Lee HH, Hong JY, Oh SN, Jeon HM, Park CH, Song KY. Laparoscopic diverticulectomy for a perforated duodenal diverticulum: a case report. *J Laparoendosc Adv Surg Tech A*. 2010;20(9):757-760.
18. Schnueriger B, Vorburger SA, Banz VM, Schoepfer AM, Candinas D. Diagnosis and management of the symptomatic duodenal diverticulum: a case series and a short review of the literature. *J Gastrointest Surg*. 2008;12(9):1571-1576.
19. Huang RY, Romano AE, Stone ME, Nathanson N. Diagnosis and treatment of a perforated duodenal diverticulum. *Emerg Radiol*. 2007;13(5):285-287.
20. Volchok J, Massimi T, Wilkins S, Curletti E. Duodenal diverticulum: case report of a perforated extraluminal diverticulum containing ectopic pancreatic tissue. *Arch Surg*. 2009;144(2):188-190.
21. Park H, Song J, Lee B, Yoon D, Lee D. Perforated duodenal diverticulitis caused by retained common bile duct stone in the diverticulum. *Am J Gastroenterol*. 2009; 104(1):248-249.
22. Guinier D, Kovacs R. Spontaneous perforation of a retroperitoneal duodenal diverticulum [in French]. *J Chir (Paris)*. 2008;145(3):287-288.
23. Chen CF, Wu DC, Chen CW, Hsieh JS, Chen CY, Wang JY. Successful management of perforated duodenal diverticulitis with intra-abdominal drainage and feeding jejunostomy: a case report and literature review. *Kaohsiung J Med Sci*. 2008; 24(8):425-429.
24. Andromanakos N, Filippou D, Skandalakis P, Kouraklis G, Kostakis A. An extended retroperitoneal abscess caused by duodenal diverticulum perforation: report of a case and short review of the literature. *Am Surg*. 2007;73(1):85-88.
25. Valenzuela Martínez MJ, Bonasa E, Sánchez JM, et al. Traumatic perforation of a duodenal diverticulum [in Spanish]. *Cir Esp*. 2006;80(4):224-226.
26. Safioleas M, Stamatakos MK, Mouzopoulos GJ, et al. Pancreatic abscess due to perforation of duodenal diverticulum. *Chirurgia (Bucur)*. 2006;101(5):523-524.
27. Castellví J, Pozuelo O, Vallet J, et al. Perforated duodenal diverticulum [in Spanish]. *Cir Esp*. 2006;80(3):174-175.
28. Papalambros E, Felekouras E, Sigala F, et al. Retroperitoneal perforation of a duodenal diverticulum with colonic necrosis: report of a case. *Zentralbl Chir*. 2005; 130(3):270-273.
29. Lee VT, Chung AY, Soo KC. Mucosal repair of posterior perforation of duodenal diverticulitis using Roux loop duodenojejunostomy. *Asian J Surg*. 2005;28 (2):139-141.
30. Bergman S, Koumanis J, Stein LA, Barkun JS, Paraskevas S. Duodenal diverticulum with retroperitoneal perforation [case report]. *Can J Surg*. 2005;48 (4):332.
31. Yokomuro S, Uchida E, Arima Y, et al. Simple closure of a perforated duodenal diverticulum: "a case report." *J Nihon Med Sch*. 2004;71(5):337-339.
32. Yarze JC. Duodenoscopic diagnosis of perforated periampullary diverticulitis [letter]. *Am J Gastroenterol*. 2002;97(3):769.
33. Franzen D, Gürtler T, Metzger U. Solitary duodenal diverticulum with enterolith as a rare cause of acute abdomen [in German]. *Swiss Surg*. 2002;8(6):277-279.
34. Atmani A, Lachachi F, Sodji M, et al. Perforated juxta-papillary duodenal diverticula: two cases [in French]. *Gastroenterol Clin Biol*. 2002;26(3):285-288.
35. Gulotta G, Agosta G, Romano G. Perforated duodenal diverticulum: report of a case [in Italian]. *Chir Ital*. 2001;53(2):255-258.
36. Tsukamoto T, Ohta Y, Hamba H, et al. Perforated duodenal diverticulum: report of two cases. *Hepatogastroenterology*. 1999;46(27):1755-1758.
37. Rao PM. Diagnosis please: case 11: perforated duodenal diverticulitis. *Radiology*. 1999;211(3):711-713.
38. Poostizadeh A, Gow KW, Al-Mahmeed T, Allardyce DB. Traumatic perforation of duodenal diverticulum. *J Trauma*. 1997;43(2):370-371.
39. Cavanagh JE Jr. Iatrogenic perforation of perivaterian duodenal diverticulum: report of a case. *Can J Surg*. 1996;39(4):336-338.
40. Berki C. Perforated duodenal diverticulum. *Acta Chir Hung*. 1995-1996;35(3-4): 265-270.
41. Mehdi A, Closset J, Houben JJ, Taton G, Mendes da Costa P, Lambilliotte JP. Duodenal diverticula: diagnosis and management of complicated forms: report of two clinical cases and review of the literature. *Acta Chir Belg*. 1994;94(6): 311-313.
42. Guglielmi A, Veraldi GF, Leopardi F, Frameglia M, Boni M. The perforation of a para-Vater's duodenal diverticulum (a report of 2 clinical cases) [in Italian]. *Ann Ital Chir*. 1993;64(3):309-313.
43. Elder J, Stevenson G. Delayed perforation of a duodenal diverticulum by a biliary endoprosthesis. *Can Assoc Radiol J*. 1993;44(1):45-48.
44. Umbricht-Sprüngli RE, Hollinger A, Meier L, Largiadèr F. Complications of diverticuli of the proximal small intestine: 3 case reports and review of the literature [in German]. *Chirurg*. 1992;63(7):568-571.
45. Pugash RA, O'Brien SE, Stevenson GW. Perforating duodenal diverticulitis. *Gastrointest Radiol*. 1990;15(2):156-158.
46. Steinman E, Utiyama EM, Bevilacqua RG, Birolini D. Perforated duodenal diverticulum: a report of 2 cases [in Portuguese]. *Rev Hosp Clin Fac Med Sao Paulo*. 1989;44(3):121-123.
47. Vassilakis JS, Tzovaras G, Chrysos E, Mouzas I, Manousos O, Xynos E. Roux-Y choledochojejunostomy and duodenojejunostomy for the complicated duodenal diverticulum. *Am J Surg*. 1997;174(1):45-48.
48. Coulier B, Maldague P, Bourgeois A, Broze B. Diverticulitis of the small bowel: CT diagnosis. *Abdom Imaging*. 2007;32(2):228-233.
49. Bassett V. Duodenal diverticula: with special reference to diverticula associated with pancreatic and biliary ducts. *Trans Chicago Path Soc*. 1907;7:83-93.
50. Macari M, Lazarus D, Israel G, Megibow A. Duodenal diverticula mimicking cystic neoplasms of the pancreas: CT and MR imaging findings in seven patients. *AJR Am J Roentgenol*. 2003;180(1):195-199.

©2012 American Medical Association. All rights reserved.

Downloaded From: http://jamanetwork.com/ on 05/22/2013

51. Pearl MS, Hill MC, Zeman RK. CT findings in duodenal diverticulitis. *AJR Am J Roentgenol*. 2006;187(4):W392-W395.
52. Tagaya N, Shimoda M, Hamada K, Ishikawa K, Kogure H. Laparoscopic duodenal diverticulectomy [case report]. *Surg Endosc*. 2000;14(6):592.
53. Graur F, Bala O, Bodea R, Geczi-Toth I, Vlad L, Iancu C. Laparoscopic resection of duodenal diverticulum: a case report. *Rom J Gastroenterol*. 2005;14(4):405-408.
54. Ettman IK, Kongtawng T. Massive gastrointestinal bleeding and perforation of a duodenal diverticulum with coexisting pancreatitis. *South Med J*. 1977;70(6):761-763.
55. Shackleton ME. Perforation of a duodenal diverticulum with massive retroperitoneal emphysema. *N Z Med J*. 1963;62:93-94.
56. Hansen TT, Taudorf E. Perforation of duodenal diverticulum with retroperitoneal emphysema [in Danish]. *Ugeskr Laeger*. 1977;139(11):653-655.
57. Yasui K, Tsukaguchi I, Ohara S, Sato K, Ono N, Sato T. Benign duodenocolic fistula due to duodenal diverticulum: report of two cases. *Radiology*. 1979;130(1):67-70.
58. Gore RM, Ghahremani GG, Kirsch MD, Nemcek AA Jr, Karoll MP. Diverticulitis of the duodenum: clinical and radiological manifestations of seven cases. *Am J Gastroenterol*. 1991;86(8):981-985.

INVITED CRITIQUE

Experience Be a Jewel

Experience be a jewel.

William Shakespeare, *The Merry Wives of Windsor*[1]

Thorson et al[2] describe 4 cases of perforated duodenal diverticula that they successfully managed nonoperatively and also present an update of the world literature on the subject. Their report is quite helpful as an encouragement to surgeons who encounter this uncommon entity to try the nonoperative approach. Although the authors were wise not to extrapolate too much from the series of case reports, one wonders what factors contribute to successful nonoperative management. Their review found no significant difference in clinical presentations of the operative compared with the nonoperative groups. This finding is not surprising because duodenal diverticular perforations are difficult to distinguish from other more common upper abdominal conditions. Once again, the multisection helical computed tomography scan makes the diagnosis. Perhaps the finding of peritonitis on examination should prompt operative intervention; however, the authors also found that the observed rate of peritonitis was not statistically different between the operative and nonoperative groups. Can we really believe statistics performed on case reports? I don't think the authors believe it either because they still advise that patients with peritoneal signs and sepsis should be taken "promptly for operative intervention." That is good surgical common sense speaking. With their track record of successful nonoperative experience, I'm listening.

I congratulate the authors on an interesting and thoughtful review of perforated duodenal diverticula. I feel a little more comfortable considering a nonoperative strategy next time I encounter this problem.

Patricia Eubanks May, MD

Author Affiliation: Department of Surgery, Veterans Affairs Sierra Nevada Health Care System, Reno.
Correspondence: Dr May, Department of Surgery, Veterans Affairs Sierra Nevada Health Care System, 975 Kirman Ave (112), Reno, NV 89502-2597 (patricia.may@va.gov).
Financial Disclosure: None reported.

1. Shakespeare W. *The Merry Wives of Windsor*. Act 2, scene 2, line 72.
2. Thorson CM, Paz Ruiz PS, Roeder RA, Sleeman D, Casillas VJ. The perforated duodenal diverticulum. *Arch Surg*. 2012;147(1):81-88.

©2012 American Medical Association. All rights reserved.
Downloaded From: http://jamanetwork.com/ on 05/22/2013