OBSERVATION

Novel *FUS* Deletion in a Patient With Juvenile Amyotrophic Lateral Sclerosis

Veronique V. Belzil, MSc; Jean-Sébastien Langlais, MD, MSc; Hussein Daoud, PhD; Patrick A. Dion, PhD; Bernard Brais, MD; Guy A. Rouleau, MD, PhD

Background: Juvenile amyotrophic lateral sclerosis (JALS) refers to a form of amyotrophic lateral sclerosis (ALS) in which a progressive upper and lower motor neuron degeneration begins before 25 years of age. It is generally associated with slow disease progression. During the past decade, a number of genes have been reported to cause JALS. Mutations in the *ALSIN* gene cause JALS type 2 (ALS2) as well as juvenile primary lateral sclerosis and infantile-onset ascending spastic paralysis. Mutations in the *SETX* gene can also sometimes lead to JALS. Conversely, mutations in *SOD1*, *TARDBP*, and *FUS* typically cause pure ALS, with adult onset between 46 and 56 years of age and usually rapid progression over 3 to 5 years. Recently, a few mutations in *FUS* have been associated with juvenile-onset of ALS characterized by a very rapid progression.

Objective: To investigate the genetics of a patient with juvenile-onset ALS.

Design and Patient: We sequenced all the coding exons of *SOD1*, *TARDBP*, and *FUS* in a 19-year-old patient experiencing rapid degeneration of upper and lower motor neurons.

Results: A novel 1–base pair deletion was detected in exon 14 of the *FUS* gene, leading to a frameshift and the integration of 33 new amino acids. The variant p.R495QfsX527 is located in the highly conserved, extreme C terminal of the FUS protein, where most of the mutations in *FUS* have been identified. The variant was also identified in the unaffected 47-year-old mother of the patient, who remains asymptomatic.

Conclusions: Our finding, along with other research, further confirms that *FUS* mutations can lead to an early-onset malignant form of ALS. In addition, our data lend additional support to the notion that disruption of the conserved C terminal of FUS is critical for developing ALS.

Arch Neurol. 2012;69(5):653-656. Published online January 16, 2012. doi:10.1001/archneurol.2011.2499

Author Affiliations: Centre of Excellence in Neurosciences of Université de Montréal (Ms Belzil and Drs Daoud, Dion, Brais, and Rouleau), and Notre-Dame Hospital (Dr Langlais), Centre hospitalier de l'Université de Montréal Research Center, and Departments of Pathology and Cellular Biology (Dr Dion) and Medicine (Dr Rouleau), Research Center, Centre hospitalier universitaire Sainte-Justine (Dr Rouleau), Montreal, Quebec, Canada.

Amyotrophic lateral sclerosis (ALS) is a severe neurodegenerative disease affecting the upper and lower motor neurons. The mean age at symptom onset is 45 years for cases with a family history and 55 years for sporadic cases.[1] Affected individuals generally have a pure ALS phenotype, with degeneration affecting mainly neurons of the motor cortex, brainstem, and spinal cord. Patients usually die of respiratory failure after 3 to 5 years of disease progression; no effective treatment currently exists. Approximately 10% of patients with ALS have family members affected with the disease.[2] Mutations in the *SOD1* gene explain approximately 2% of all ALS cases,[3] while variants in *TARDBP* and *FUS* each explain about 1% to 3% of overall cases.[4] On rare occasions, the first symptoms of motor neuron degeneration start before 25 years of age, usually with slower disease progression compared with later-onset typical ALS.[5] This juvenile type of ALS has previously been associated with mutations in the *SETX* gene[6] or the *ALSIN* gene for ALS2.[7] Mutations in *ALSIN* are also known to cause juvenile primary lateral sclerosis and infantile-onset ascending spastic paralysis.[8] After 2 reports in 2009 identified *FUS* mutations in familial ALS cases,[9,10] a few research groups further identified *FUS* mutations in patients with juvenile ALS who experienced unusual and unexpected rapid progression.[11-14] We report the case of a 19-year-old man with a deletion in exon 14 of the *FUS* gene, experiencing very rapidly progressing disease.

REPORT OF A CASE

A 19-year-old man, with a history of mild learning difficulties who had been working in commercial toxic waste recycling for

©2012 American Medical Association. All rights reserved.
Downloaded From: http://jamanetwork.com/ on 06/19/2013

less than 1 year, first developed painful right shoulder and arm weakness at the end of August 2009, which progressed rapidly, and in less than 1 month included neck weakness. At the beginning of December, right arm muscle atrophy in the patient was noticed by members of his family, which prompted him to seek medical attention. A complete neurologic examination and workup was done including brain and spine magnetic resonance imaging, repeated electromyographic examination, toxicology screening, lumbar puncture, and biochemical blood tests. The general medical examination was normal. On neurologic examination, he had a normal mental status. Examination of the cranial nerves showed tongue atrophy and fasciculations; bilateral facial weakness, with the right side worse than the left; severe weakness and atrophy; and fasciculations of the sternocleidomastoids and trapezius, with the right side much worse than left. The remainder of the cranial nerves was normal. Motor examination showed atrophy and severe weakness of the right shoulder and upper arm including supraspinatus, infraspinatus, subscapularis, deltoid, pectoralis, and biceps. He had moderate weakness and atrophy of his right triceps and wrist and finger extensors and flexors, as well as interossei of the hands. There was normal bulk, tone, and strength of his left side and right leg. He was areflexic in the right arm, with mild hypereflexia in the left arm, knees, and ankles, with equivocal plantar responses. The cerebellar examination was normal, with the exception of the right arm, which was not testable. The sensory examination was normal as well as of his gait. The brain and spine magnetic resonance images were normal. Results from the lumbar puncture as well as the detailed biochemical tests and toxicology screen were normal. An electromyographic examination showed normal conduction velocities and normal needle examination of the left arm, left shoulder, and left leg. There was some denervation in muscles of the right leg and severe denervation in muscles of the right shoulder and arm. In March 2010, the patient was suspected of having juvenile-onset ALS and was prescribed treatment with riluzole. In May, he developed dysphagia and dysarthria, leading to anorexia and severe weight loss. In August, a control neurologic examination showed a 36-kg young man with diffuse severe muscle atrophy. Muscle weakness was asymmetric, with profound right upper limb weakness and, to a lesser degree, bilateral leg involvement. The patient rapidly progressed to respiratory failure requiring mechanical ventilation. Repeated neurologic examinations showed no cognitive or sensory symptoms or signs. Although follow-up visits were scheduled, the patient was lost to follow-up. In summary, the patient mostly displayed a lower motor neuron phenotype, with the upper limbs and bulbar regions principally affected. Upper motor neurons seemed to be mildly affected.

The patient's clinical history revealed that he was generally in good health for his first 17 years of life. He was seen for dysphasia at 6 years of age, was prescribed methylphenidate hydrochloride from 6 to 16 years of age, but he did not show any previous signs of paralysis, progressive weakness, or neurologic symptoms. However, he attended welding school when he was 16 years of age, and he worked with hazardous recycling material at 17 years of age.

While the patient had no apparent family history of motor neuron diseases, his mother was diagnosed with an Arnold-Chiari malformation at 13 years of age; she experienced equilibrium problems and 1 cerebellar ataxia episode at that time. The mother's parents were not reported to have developed any neurodegenerative symptoms. Other family members including the patient's father and brother are in good health.

METHODS

DNA from the patient and his parents were extracted from peripheral blood using standard protocols. Primers for *SOD1*, *TARDBP*, and *FUS* were designed using the ExonPrimer software from the UCSC Human Genome Browser Web site (http://genome.ucsc.edu/cgi-bin/hgGateway). All 26 exons of the 3 genes were amplified for the patient for a total of 23 fragments, and the 1 fragment containing the mutation was amplified in his parents. Amplification was performed by polymerase chain reactions (PCRs) using the AmpliTaq Gold DNA Polymerase (Applied Biosystems) as per the manufacturer's instructions. The PCR product contained a minimum of 50 base pairs (bp) from each of the flanking introns. Products were directly sequenced in forward and reverse at the Genome Quebec Innovation Centre (Montreal, Quebec, Canada) using the 3730XL DNA analyzer (Applied Biosystems). Mutation surveyor software version 3.10 was used for mutation detection analyses (SoftGenetics). All exons of *FUS* were also amplified in 96 French-Canadian and 380 French control participants and have already been published.[11]

RESULTS

A novel 1-bp deletion of a guanine in exon 14 of the *FUS* gene (c.1484delG) (**Figure**, A) was identified and is predicted to cause a shift in the reading frame, resulting in the inclusion of 33 new amino acids (p.R495QfsX527), which modifies the highly conserved C terminal of the protein (Figure, B) that is believed to play a crucial role in RNA processing.[4] The final mutated protein is predicted to have 1 more amino acid than the wild type, resulting in a probable change in the C terminal function or interaction abilities. The variant was also identified in the patient's 47-year-old mother, who did not show any signs of motor neuron degeneration.

Interestingly, Elden et al[15] found that intermediate-length polyglutamine tracts (range, 24-33 repeats) in *ATXN2* confer an increased risk for developing ALS. We decided to test the length of the repeat in *ATXN2* in the 19-year-old patient and his parents, the hypothesis being that the patient affected by juvenile ALS developed the symptoms earlier than his mother because he inherited an intermediate-length polyglutamine tract from his father, who does not carry the *FUS* mutation. We amplified the *ATXN2* CAG repeats using PCR. We determined the CAG repeat sizes by capillary electrophoresis by incorporating a VIC-labeled M13 universal primer into the PCR reaction. Polymerase chain reaction products were then diluted (1:20),mixed with LIZ-500 size standard (Applied Biosystems), and processed for size de-

©2012 American Medical Association. All rights reserved.
Downloaded From: http://jamanetwork.com/ on 06/19/2013

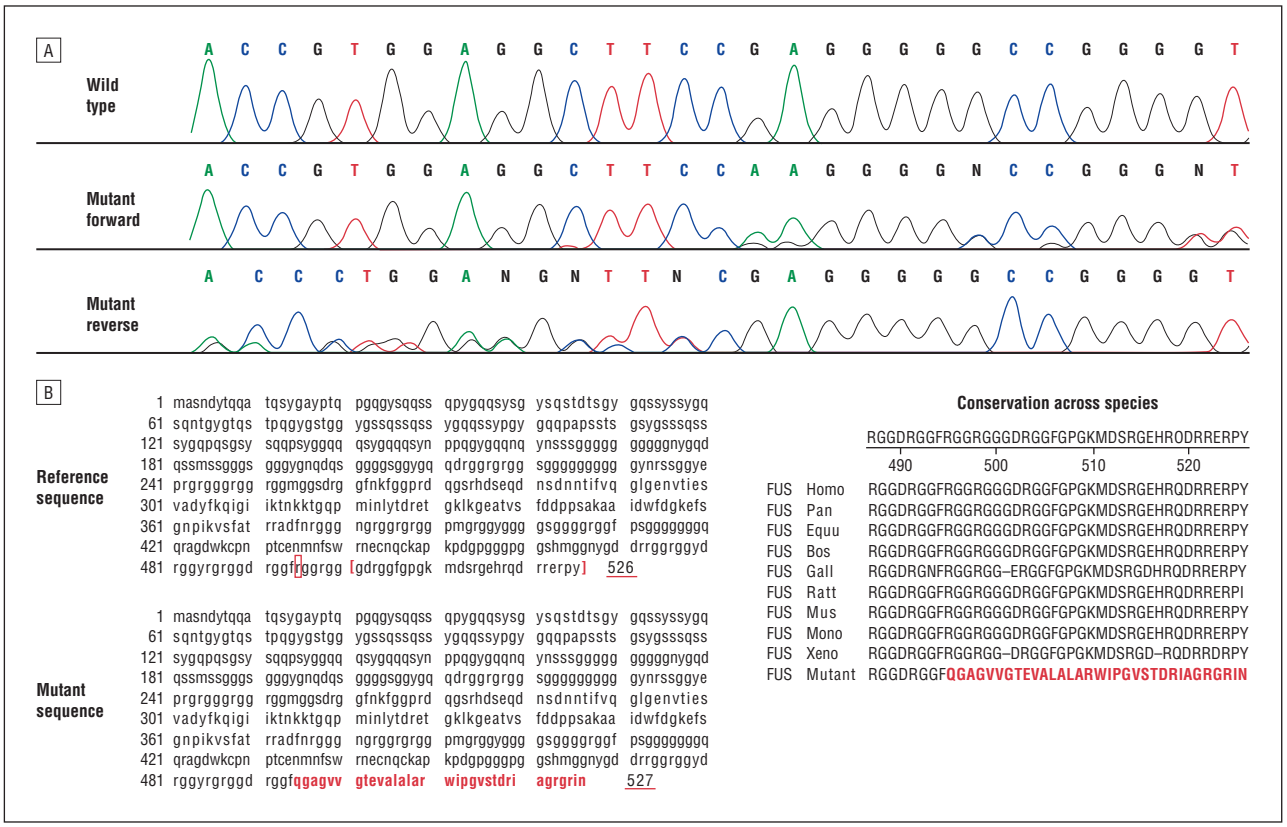

Figure. Chromatograms, protein sequence, and amino acid conservation. A, Chromatograms for the c.1484delG variant. B, Complete protein sequence of the wild-type 526 amino acids of FUS is on top, followed by the 527 amino acids mutant sequence on the bottom. The first amino acid affected by the nucleotide deletion is marked by a red rectangle on the reference sequence, and the highly conserved, extreme C terminal is between red brackets on the same sequence. The 33 new amino acids of the mutant sequence are in red in the protein sequence box and in the conservation across species box. The cluster analysis was performed using the Clustal W method and shows that the last 32 amino acids of the FUS protein are highly conserved across 9 species. The closest homologues were retrieved using the National Center for Biotechnology Information Basic Local Alignment Search Tool program.

termination on the ABI 3730 DNA analyzer (Applied Biosystems). Repeat sizes were determined using the GeneMapper Software version 4.0 (Applied Biosystems). All 3 individuals had both the (CAG)21 and (CAG)22 alleles, which are the most common in the general population. The experiment was repeated twice, yielding the same results.

COMMENT

A novel 1-bp deletion was detected in exon 14 of the *FUS* gene, leading to a frameshift and the integration of 33 new amino acids. The variant c.1484delG (p.R495QfsX527) is located in the highly conserved, extreme C terminal of the FUS protein, where most of the mutations in *FUS* have been identified. The variant was also identified in the patient's unaffected 47-year-old mother, who remains healthy. Separate deletions were already reported in familial ALS cases 1-bp upstream (c.1483delC) and 1-bp downstream (c.1485delA), producing p.R495EfsX527 and p.G497Afs527, respectively.[12] This confirms the importance of a conserved C terminal for the normal functioning of the FUS protein. Additionally, the same group published a nonsense substitution at position c.1483C>T that was shown to produce a truncated protein (p.R495X),[12] further reinforcing the importance of this region. What is particularly interesting is the age at onset and disease duration associated with the p.R495EfsX527-, p.G497Afs527-, and p.R495X-reported mutations. In fact, the 2 affected members of the family with the p.R495EfsX527 mutation displayed a significant difference in terms of age at onset and duration because 1 developed the first symptoms at 23 years of age and the disease progressed over a 48-month period, while the other developed ALS at 72 years of age and died 12 months after symptom onset. On the other hand, the 7 members of the family in whom the nonsense p.R495X mutation segregated had an early age at onset but varied in terms of disease duration. Five members of the family developed ALS at 14, 24, 27, 39, and 44 years of age, while 2 other members with the variant were still unaffected at 57 and 61 years of age. Moreover, the p.G497Afs527 mutation segregated in 3 members of another family, who experienced the first symptoms at 13, 29, and 29 years of age. The disease progressed very rapidly over 12-, 13-, and 18-month periods in those patients.

In addition, another group described a woman with sporadic ALS with a *FUS* p.G466VfsX14 splice mutation who experienced the first symptoms at 20 years of age; the disease progressed for a 22-month period.[14] Interestingly, our group also previously published 1 French-Canadian sporadic ALS case with a *FUS* p.Q519X mutation. This patient started to develop motor neuron

©2012 American Medical Association. All rights reserved.
Downloaded From: http://jamanetwork.com/ on 06/19/2013

symptoms at 20 years of age, and the disease progressed rapidly during a 12-month period,[11] underlying the fact that a mutation in that specific region gave rise to an early ALS onset often characterized by rapid progression.

The research cases just described along with our reported juvenile case underscore the importance of the last 32 amino acids of the FUS protein and demonstrate that despite an existing variability in terms of age at onset, it seems that patients carrying such mutations frequently develop ALS at an earlier age while the disease progresses more rapidly. However, other genetic modifiers might influence the age at which the first ALS symptoms will appear. An intermediate length of the polyglutamine tracts in *ATXN2* was not a modifier of the age at onset in our juvenile patient. On the other hand, the patient was highly exposed 2 years before developing the first symptoms to welding material as well as heavy metals, solvents, pesticides, and agricultural chemicals, all of which have been reported to be associated with ALS.[16-18] While detailed biochemical tests and toxicology screen results were normal, unknown genetic variants already present in the patient could have led to a certain vulnerability to toxic exposition, or mutations caused by such environmental exposition could explain why the patient developed the first signs of ALS while his mother remains healthy. However, it cannot be ruled out that other susceptibility variants in other genes explain the early onset. It could also be hypothesized that the mother carries a protective variant, preventing the early onset of the disease.

Accepted for Publication: October 11, 2011.
Published Online: January 16, 2012. doi:10.1001/archneurol.2011.2499
Correspondence: Guy A. Rouleau, MD, PhD, Centre hospitalier de l'Université de Montréal Research Centre, Notre-Dame Hospital, 1560 Sherbrooke E, Y-3633, Montreal, QC H2L 4M1, Canada (guy.rouleau@umontreal.ca).
Author Contributions: *Study concept and design:* Belzil. *Acquisition of data:* Langlais and Brais. *Analysis and interpretation of data:* Belzil, Daoud, Dion, and Rouleau. *Drafting of the manuscript:* Belzil and Brais. *Critical revision of the manuscript for important intellectual content:* Langlais, Daoud, Dion, Brais, and Rouleau. *Statistical analysis:* Belzil. *Obtained funding:* Rouleau. *Administrative, technical, and material support:* Belzil, Langlais, Daoud, and Dion. *Study supervision:* Brais and Rouleau.
Financial Disclosure: None reported.
Funding/Support: Ms Belzil and Dr Daoud are supported by the Canadian Institutes of Health Research. Dr Rouleau holds the Canada Research Chair and Jeanne-et-J-Louis-Levesque Chair for the Genetics of Brain Diseases.
Additional Contributions: We thank the patient and his parents who were involved in this study, Catherine André-Guimont and Annie Levert for technical support, and Anne Desjarlais, BSc, and Catherine Boyer for sample collection and organization.

REFERENCES

1. Camu W, Khoris J, Moulard B, et al; French ALS Research Group. Genetics of familial ALS and consequences for diagnosis. *J Neurol Sci*. 1999;165(suppl 1):s21-s26.
2. Shaw CE, Enayat ZE, Powell JF, et al. Familial amyotrophic lateral sclerosis: molecular pathology of a patient with a SOD1 mutation. *Neurology*. 1997;49(6):1612-1616.
3. Rosen DR, Siddique T, Patterson D, et al. Mutations in Cu/Zn superoxide dismutase gene are associated with familial amyotrophic lateral sclerosis. *Nature*. 1993;362(6415):59-62.
4. Lagier-Tourenne C, Polymenidou M, Cleveland DW. TDP-43 and FUS/TLS: emerging roles in RNA processing and neurodegeneration. *Hum Mol Genet*. 2010;19(r1):R46-R64.
5. Alonso A, Logroscino G, Jick SS, Hernan MA. Incidence and lifetime risk of motor neuron disease in the United Kingdom: a population-based study. *Eur J Neurol*. 2009;16(6):745-751.
6. Chen YZ, Bennett CL, Huynh HM, et al. DNA/RNA helicase gene mutations in a form of juvenile amyotrophic lateral sclerosis (ALS4). *Am J Hum Genet*. 2004;74(6):1128-1135.
7. Hadano S, Hand CK, Osuga H, et al. A gene encoding a putative GTPase regulator is mutated in familial amyotrophic lateral sclerosis 2. *Nat Genet*. 2001;29(2):166-173.
8. Eymard-Pierre E, Lesca G, Dollet S, et al. Infantile-onset ascending hereditary spastic paralysis is associated with mutations in the alsin gene. *Am J Hum Genet*. 2002;71(3):518-527.
9. Vance C, Rogelj B, Hortobágyi T, et al. Mutations in FUS, an RNA processing protein, cause familial amyotrophic lateral sclerosis type 6. *Science*. 2009;323(5918):1208-1211.
10. Kwiatkowski TJ Jr, Bosco DA, Leclerc AL, et al. Mutations in the FUS/TLS gene on chromosome 16 cause familial amyotrophic lateral sclerosis. *Science*. 2009;323(5918):1205-1208.
11. Belzil VV, Daoud H, St-Onge J, et al. Identification of novel FUS mutations in sporadic cases of amyotrophic lateral sclerosis. *Amyotroph Lateral Scler*. 2011;12(2):113-117.
12. Yan J, Deng HX, Siddique N, et al. Frameshift and novel mutations in FUS in familial amyotrophic lateral sclerosis and ALS/dementia. *Neurology*. 2010;75(9):807-814.
13. Bäumer D, Hilton D, Paine SM, et al. Juvenile ALS with basophilic inclusions is a FUS proteinopathy with FUS mutations. *Neurology*. 2010;75(7):611-618.
14. DeJesus-Hernandez M, Kocerha J, Finch N, et al. De novo truncating FUS gene mutation as a cause of sporadic amyotrophic lateral sclerosis. *Hum Mutat*. 2010;31(5):E1377-E1389.
15. Elden AC, Kim HJ, Hart MP, et al. Ataxin-2 intermediate-length polyglutamine expansions are associated with increased risk for ALS. *Nature*. 2010;466(7310):1069-1075.
16. Strickland D, Smith SA, Dolliff G, Goldman L, Roelofs RI. Amyotrophic lateral sclerosis and occupational history: a pilot case-control study. *Arch Neurol*. 1996;53(8):730-733.
17. Bonvicini F, Marcello N, Mandrioli J, Pietrini V, Vinceti M. Exposure to pesticides and risk of amyotrophic lateral sclerosis: a population-based case-control study. *Ann Ist Super Sanita*. 2010;46(3):284-287.
18. Kamel F, Umbach DM, Hu H, et al. Lead exposure as a risk factor for amyotrophic lateral sclerosis. *Neurodegener Dis*. 2005;2(3-4):195-201.

©2012 American Medical Association. All rights reserved.
Downloaded From: http://jamanetwork.com/ on 06/19/2013