ONLINE FIRST

Larger Osteotomies Result in Larger Ostia in External Dacryocystorhinostomies

Guy J. Ben Simon, MD; Chris Brown, MD; Alan A. McNab, MD

Objective: To evaluate whether final ostium size is determined by the osteotomy created during dacryocystorhinostomy (DCR).

Design: Prospective nonrandomized study. Intraoperative measurements of bony osteotomy were taken during external DCR. Endonasal endoscopy with functional endoscopic dye testing and internal ostium photography were performed 3 months after surgery.

Results: Fifty patients (mean age, 63 years) underwent 55 DCRs. Postoperative nasal endoscopy with functional endoscopic dye testing was performed in 27 cases (49%), and measurements of intranasal ostia were feasible in 24 of them (86%). The mean follow-up time was 7 months (range, 3-12 months). Surgical success was achieved in 25 of 27 patients (93%) who underwent postoperative nasal endoscopy. There was no difference in either the intraoperative osteotomy size or the postoperative ostium size between failed and successful cases. The mean (SD) intraoperative osteotomy size was 256.3 (89.0) mm^2, and the mean (SD) postoperative ostium size was 9.6 (6.7) mm^2. The intraoperative osteotomy size correlated positively with the postoperative intranasal ostium size ($r=0.45$; $P=.03$, Pearson bivariate correlation).

Conclusions: Larger osteotomies created during external DCR are correlated with larger postoperative ostia as measured by endonasal endoscopy and image analysis software. There is a trend toward greater success with larger osteotomies; however, failed cases in this series were not associated with smaller-sized intraoperative osteotomies.

Arch Facial Plast Surg. 2012;14(2):127-131.
Published online October 17, 2011.
doi:10.1001/archfacial.2011.73

Author Affiliations:
Department of Ophthalmology, Goldschleger Eye Institute, Sheba Medical Center, Tel Hashomer, Israel (Dr Ben Simon); and Ear, Nose, and Throat Department (Dr Brown) and Ophthalmic Plastic and Lacrimal Clinic (Dr McNab), Royal Victorian Eye and Ear Hospital, Melbourne, Australia.

THE KEY TO SUCCESS IN DACryocystorhinostomy (DCR) is in creating a large enough passage between the nasolacrimal sac and the nasal mucosa that will remain patent after surgery. A meticulous dissection, including careful opening of the nasolacrimal sac and incising the mucosa of the nasolacrimal duct, is a requirement for surgical success. Removal of the lacrimal bone and lacrimal process of the maxillary bone is also required in most cases. Intraoperative osteotomy is only 1 factor that contributes to success, and scar formation may be an equally important factor in determining surgical outcome.[1] Additional elements that influence outcome include small size and inappropriate position of the osteotomy as well as extension of the ethmoid air cells medial to the lacrimal sac.[1]

Although the extent of bone removal in DCR is controversial, "the more the better" is a common belief. The first study that examined postoperative ostia was conducted in 1982 by Linberg et al,[2] who used a rigid endoscope. The authors found no correlation between the sizes of the osteotomy created during DCR and the final ostium size. The purpose of the current study was to measure final ostium size by means of nasal endoscopy and the functional endoscopic dye test (FEDT)[3] with the use of image analysis software in patients undergoing external DCR surgery in order to examine whether there is any correlation between the primary osteotomy created during surgery and the final ostium size and to evaluate whether surgical outcome is influenced by these 2 factors.

METHODS

PATIENTS

This prospective nonrandomized study included all consenting consecutive patients with acquired nasolacrimal duct obstruction who underwent external DCR at the Royal Victorian

©2012 American Medical Association. All rights reserved.
Downloaded From: http://jamanetwork.com/ on 05/25/2013

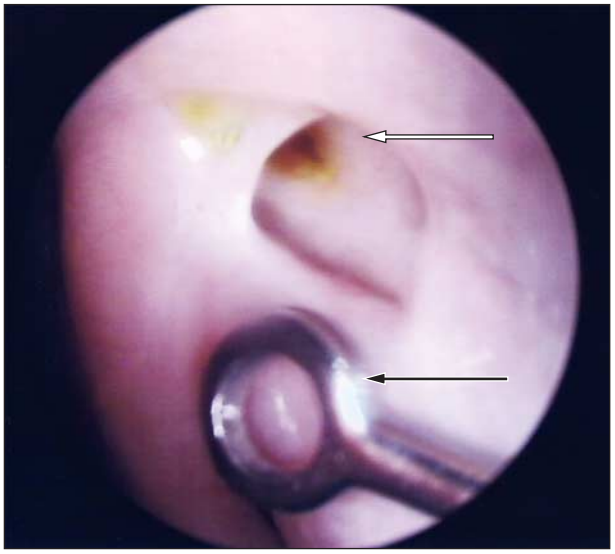

Figure 1. Postoperative endonasal photograph of a patient who underwent an external dacryocystorhinostomy. The white arrow indicates the intranasal ostium with fluorescein dye at the common canaliculus opening (positive functional endoscopic dye test result). A metal curette with a known diameter (3 mm) was used to measure the ostium size after surgery (black arrow).

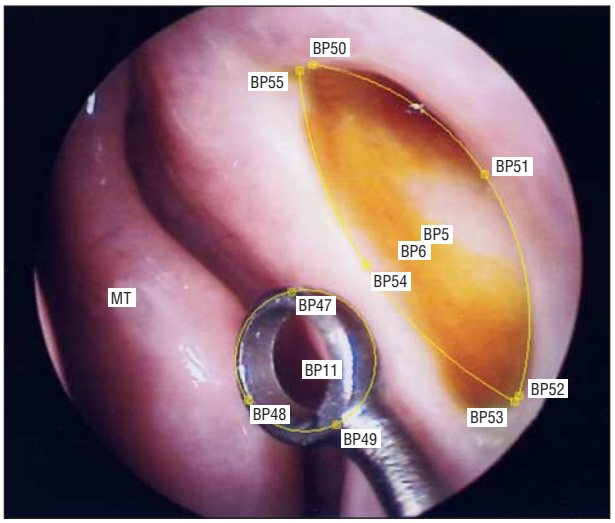

Figure 2. Postoperative endonasal photograph of a patient who underwent external dacryocystorhinostomy showing the intranasal ostium and a metal curette with a known diameter (3 mm). Image analysis software (Image-Pro Plus Version 4.5; Media Cybernetics, Bethesda, Maryland) and the best-fit circle method were used to measure the size of the curette in pixels: 2 arcs were used to measure the fistula size because most fistulas were ellipsoid. The program output included the area of the circle and the radius, length, and angle of the arc. BA indicates best-fit arc; BC, best-fit circle; BP, best-fit point; and MT, middle turbinate.

Eye and Ear Hospital, Melbourne, Australia. Institutional review board approval was obtained to conduct the study. All participants signed an informed consent.

SURGICAL TECHNIQUE

External DCR was performed in a standard fashion in all patients. A bony window, which included the anterior lacrimal crest, the lacrimal fossa, and the superior aspect of the nasolacrimal duct, was created using a rongeur. During surgery, the bone opening was measured in the anterior posterior and superior inferior axes with a millimeter ruler. The intraoperative osteotomy surface area was calculated by multiplying osteotomy height and width in millimeters. Anterior and posterior mucosal flaps were fashioned in the lacrimal sac and the nasal mucosa and sutured over a silicone tube using a 6-0 polyglactin suture. Success was defined as a resolution of symptoms and a lack of tearing, with a positive FEDT result.

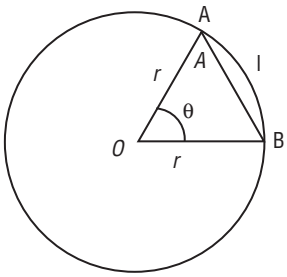

$$S_l = \frac{\theta}{360}\pi r^2$$

$$S_{ABO} = \frac{1}{2} r^2 \sin\left(\theta \frac{\pi}{180}\right)$$

$$S_{arc-l} = (S_l) - (S_{ABO})$$

Figure 3. Three equations were used to calculate the surface area of an arc *l* (S_l) (between points A and B) with radius (*r*) and angle (θ) (degrees), where S_{ABO} is the surface area of triangle ABO and S_{arc-l} is the surface area of arc *l* (sector minus triangle).

POSTOPERATIVE NASAL ENDOSCOPY FOR MEASURING THE INTRANASAL OSTIUM

All patients underwent endonasal endoscopy to evaluate the ostium size and surgical outcome 3 months after surgery. The intranasal ostium was photographed together with a 3-mm-diameter curette. The FEDT was performed by instilling fluorescein eyedrops and demonstrating the dye in the nose at the ostium (**Figure 1**). Normally, the dye would appear within seconds from instillation after several blinking cycles. Cases of late appearance (several minutes) were noted. Failure to demonstrate fluorescein in the nose was defined as a failed FEDT result.

Photographed images were scanned to digital images and analyzed using Image Pro Plus version 4.5 (Media Cybernetics, Bethesda, Maryland). The best-fit circle method was used to measure the curette size in pixels (**Figure 2**). Because postoperative ostia were generally ellipsoid, the surface area in pixels was determined by summing the areas of 2 arcs (Figure 2). If feasible, the best-fit circle method was applied to ostia as well. The ratio between ostium area to curette area was calculated and multiplied by the true known curette area in square millimeters.

The arc surface area was calculated by subtracting the triangle limited by the circle radius and angle (using Image Pro Plus computer software) from the sector area (with known radius and angle dimensions) (**Figure 3**). The total ostium area was calculated by summing the 2 arc surface areas. The arc method was applied for calculating curette surface in cases in which the best-fit circle method was not feasible. The area of a circle was calculated as the radius of the circle squared (multiplied by itself) times π.

STATISTICAL ANALYSIS

The Pearson bivariate correlation was used to analyze the intraoperative osteotomy size and the final postoperative ostium size. The independent samples *t* or Wilcoxon Mann-Whitney test was used to compare the intraoperative osteotomy size and the post-

©2012 American Medical Association. All rights reserved.
Downloaded From: http://jamanetwork.com/ on 05/25/2013

operative ostium size between successful and failed cases. Statistical analysis was performed using Microsoft Excel 2003 (Microsoft Corp, Redmond, Washington) and SPSS version 13.0 (SPSS Inc, Chicago, Illinois) computer software.

RESULTS

Fifty patients (mean [SD] age, 63 [15] years), 40 of whom were women, underwent 55 external DCRs (5 patients underwent bilateral surgery). The surgery was distributed evenly between the right and the left sides. The mean follow-up time was 7.1 months (range, 3-12 months). Success was achieved in 49 of 55 cases (89%). The mean (SD) intraoperative osteotomy size was 262.5 (87.5) mm^2 (range, 104-494 mm^2) in all cases, and there was no difference between failed and successful outcomes (250 mm^2 vs 264 mm^2; $P=.64$, independent samples t test).

Postoperative nasal endoscopy and FEDT were performed in 27 cases (49% of all cases). Other patients either did not return for follow-up or refused to undergo endonasal endoscopy after surgery. It was possible to measure the intranasal ostia in only 24 cases (86%) because 2 patients had a nasal septum deviation that did not allow visualization of their ostia (positive FEDT results in both), 1 patient had a pyogenic granuloma (positive FEDT result), and 1 patient had a scar at the fistula site (negative FEDT result).

Success was achieved in 25 of the 27 patients (93%) who underwent postoperative nasal endoscopy. One patient had a scarred ostium (negative FEDT result) and was scheduled for reoperation. The other patient had a pyogenic granuloma at the ostium site and late dye appearance (>5 minutes) on his FEDT; therefore, his case, too, was considered a failure. There was no difference in the preoperative osteotomy size and the final ostium size between failed and successful cases (232 mm^2 vs 251 mm^2 and 8.8 mm^2 vs 9.7 mm^2, respectively; $P_1=0.6$ and $P_2=0.8$, respectively, Wilcoxon Mann-Whitney test).

The intraoperative osteotomy size was 256.3 (89.0) mm^2 (range, 104-441 mm^2) among patients who underwent postoperative nasal endoscopy (**Figure 4**). The ostium size was 9.6 (6.7) mm^2 (range, 1.26-30.5 mm^2). The intraoperative osteotomy size was positively correlated with the postoperative intranasal ostium size ($r=0.45$; $P=.03$, Pearson bivariate correlation) (**Figure 5**). The quadratic fit method showed better correlation than the linear fit method (R^2 quadratic, 0.46; R^2 linear, 0.20).

Postoperative complications included pyogenic granuloma at the ostium size, with a positive delayed FEDT result (>5 minutes) in 1 patient (**Figure 6**). Two other patients had scars at the ostia and are scheduled for reoperation. No intraoperative complications were encountered in this group of patients.

COMMENT

Measurements performed by endonasal endoscopy 3 months after surgery demonstrated that creating a larger osteotomy during an external DCR procedure results in a larger final intranasal ostium. The overall success rate of the DCRs in this series was high (93%), and neither intraoperative osteotomy nor final ostium size influenced the success or the failure of those procedures. There is a trend toward greater success with larger osteotomies; however, failed cases in this series were not associated with smaller-sized intraoperative osteotomies.

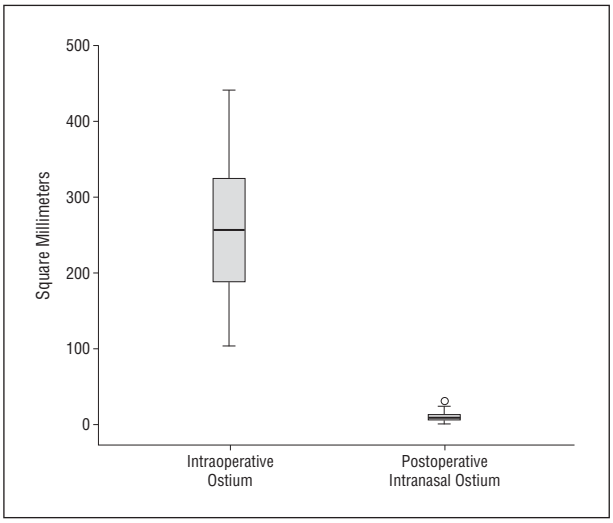

Figure 4. Box plot describing the mean intraoperative osteotomy size and the mean postoperative intranasal fistula size among the 24 study patients who underwent external dacryocystorhinostomy at the Royal Victorian Eye and Ear Hospital, Melbourne, Australia. The error bars represent the standard deviation of the size measured in square millimeters.

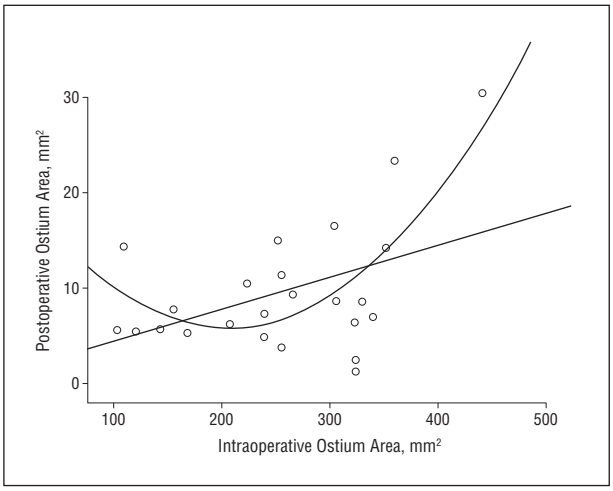

Figure 5. Scatterplot describing the postoperative intranasal ostium size in relation to the intraoperative osteotomy size among the 24 study patients who underwent external dacryocystorhinostomy at the Royal Victorian Eye and Ear Hospital, Melbourne, Australia. The osteotomy size correlated positively with the final ostium size ($r=0.45$; $P=.03$, Pearson bivariate correlation). The quadratic fit method shows better correlation than the linear fit method (R^2 quadratic, 0.46; R^2 linear, 0.20).

The findings of our study are not in agreement with the first report by Linberg et al,[2] who found that the average diameter of the bony opening created at surgery was 11.84 mm (ours was 18.2 mm), while the average diameter of the healed intranasal ostium was only 1.80 mm (ours was 3.5 mm). Interestingly, they found no correlation between the size of the bony opening and the final size of the intranasal ostium and therefore concluded that larger intraoperative osteotomies do not necessarily result in larger ostia after surgery. They also noted

©2012 American Medical Association. All rights reserved.
Downloaded From: http://jamanetwork.com/ on 05/25/2013

Figure 6. Postoperative endonasal photograph of a patient who underwent right external dacryocystorhinostomy and who experienced tearing 5 months after surgery. Endoscopic examination revealed a pyogenic granuloma at the fistula site, with delayed (>5 minutes) dye appearance after fluorescein instillation in the right eye.

that a good surgical outcome was obtained even with a small ostium. It is possible that they measured the common canalicular opening rather than the true postoperative intranasal ostium or fistula.[4] Assuming that a round osteotomy was created during surgery, the calculated area of the circle would be 100 mm^2, with a final ostium size of 2.5 mm^2. Although these sizes are somewhat smaller compared with our data, Linberg et al[2] also noted a more than 95% shrinkage of the intranasal ostia.

Other studies have evaluated postoperative nasal ostium size using endonasal endoscopy.[5-7] Deka et al[5] found that the intraoperative use of mitomycin C may enhance ostium size by preventing postoperative scarring at the surgery site. Patients treated with higher concentrations of mitomycin C (0.4 mg/mL) had substantially larger ostia (17 mm^2) than patients treated without mitomycin C (3.5-4.5 mm^2). You and Fang[7] showed that the intraoperative use of mitomycin C (0.2 or 0.5 mg/mL) was effective in creating larger ostia (20-22 mm^2) compared with standard DCR without mitomycin C (13 mm^2) and that it was also associated with a higher success rate. Although intraoperative osteotomy measurements were not taken in both studies,[5,7] they indirectly support the claim that most of the opening created during surgery is significantly narrowed by scar tissue over time. The data acquired in our study show that more than 90% of the opening is narrowed either by scar tissue or by fistula (ostium) formation but that even a narrow patent opening suffices for tear drainage and successful surgical outcome. A study by Gonzalvo Ibanez et al[6] found that the ostium shrank to a lesser (7%) extent when mitomycin C was used compared with standard surgery without mitomycin C (35%) and that the intraoperative use of mitomycin C resulted in a better outcome.

The critical osteotomy size that ensures surgical success has yet to be determined; however, it is largely accepted among oculoplastic surgeons that larger openings result in better outcomes. A recent article by Argin et al[8] reported that creating a 2×2-cm bony opening during surgery might result in ostia that are 1.21 to 4 cm^2 in surface area as measured by computed tomography 2 years after surgery. Although their final ostium size is similar to ours, comparison of these findings is difficult owing to different measuring techniques used in the 2 studies. Their conclusions that a 2×2-cm^2 bone defect might prevent restenosis and that it ensures success is supported only in part, since no control groups were used to evaluate different-sized openings after surgery.

Mann and Wormald[9] evaluated postoperative ostia at different time intervals after endoscopic endonasal DCR. They found that the DCR ostium shrinks by a small but significant amount 4 weeks after surgery and then remains relatively stable thereafter. The average ostium measured 11.8×7.2 mm (=84 mm^2) at the time of surgery, 10.1×6.4 mm (=64 mm^2) at 4 weeks, 9.8×6.5 mm (=63.7 mm^2) at 6 months, and 10.1×6.6 mm (=66 mm^2) at 12 months. We had a much greater discrepancy between the average intraoperative osteotomy (256 mm^2) and the final ostium size (9.6 mm^2); however, Mann and Wormald[9] performed DCR endonasally, and their preoperative measurements were limited to the size of the ostium and did not include the bony osteotomy. They used a 4-mm olive-tipped suction, rather than computer software, to measure the vertical diameter and the horizontal diameter of the ostium; this difference could account for the variations in the measurements between their study and ours. It may be reasonable to assume that the narrowing of an intranasal opening would occur to a lesser extent in endoscopic endonasal DCRs compared with external DCRs.

Additional factors that may contribute to a larger ostium include creation of posterior and anterior flaps rather than a single anterior flap,[5] appropriate location of the ostium relative to the nasolacrimal sac, extension of ethmoid air cells medial to the sac, and coexistence of intranasal disease.[1] Understanding the endonasal anatomy in relation to the lacrimal fossa is of utmost importance in DCR procedures, and even more so when the endoscopic approach is used.[10]

We acknowledge the fact that it would have been more accurate to measure intraoperative ostia, rather than osteotomies, using nasal endoscopy at the end of surgery; however, measurement of the fistula size was not performed. Measurement of the true ostia would demonstrate whether true shrinkage occurs during the healing period.

In conclusion, our findings support the hypothesis that creating larger bony osteotomies during external DCR results in substantially larger ostia as measured by postoperative endonasal endoscopy. It would be reasonable to expect that larger osteotomies would be associated with a higher success rate, but this was not borne out by our results, maybe because of the relatively small sample size. Surgical outcome is apparently influenced by additional yet undetermined factors.

Accepted for Publication: August 23, 2011.
Published Online: October 17, 2011. doi:10.1001/archfacial.2011.73
Correspondence: Guy J. Ben Simon, MD, Department of Ophthalmology, Goldschleger Eye Institute, Sheba Medical Center, Tel Hashomer, Israel (guybensimon@gmail.com).

©2012 American Medical Association. All rights reserved.
Downloaded From: http://jamanetwork.com/ on 05/25/2013

Author Contributions: *Study concept and design:* Ben Simon, Brown, and McNab. *Acquisition of data:* Ben Simon and Brown. *Analysis and interpretation of data:* Ben Simon. *Drafting of the manuscript:* Ben Simon. *Critical revision of the manuscript for important intellectual content:* Ben Simon, Brown, and McNab. *Statistical analysis:* Ben Simon. *Obtained funding:* Ben Simon and McNab. *Administrative, technical, and material support:* Ben Simon, Brown, and McNab. *Study supervision:* McNab.
Financial Disclosure: None reported.
Funding/Support: The study was supported in part by the Talpiot Medical Leadership Program, Sheba Medical Center.

REFERENCES

1. Gökçek A, Argin MA, Altintas AK. Comparison of failed and successful dacryocystorhinostomy by using computed tomographic dacryocystography findings. *Eur J Ophthalmol*. 2005;15(5):523-529.
2. Linberg JV, Anderson RL, Bumsted RM, Barreras R. Study of intranasal ostium external dacryocystorhinostomy. *Arch Ophthalmol*. 1982;100(11):1758-1762.
3. Minasian M, Olver JM. The value of nasal endoscopy after dacryocystorhinostomy. *Orbit*. 1999;18(3):167-176.
4. Baldeschi L, Nolst Trenité GJ, Hintschich C, Koornneef L. The intranasal ostium after external dacryocystorhinostomy and the internal opening of the lacrimal canaliculi. *Orbit*. 2000;19(2):81-86.
5. Deka A, Bhattacharjee K, Bhuyan SK, Barua CK, Bhattacharjee H, Khaund G. Effect of mitomycin C on ostium in dacryocystorhinostomy. *Clin Experiment Ophthalmol*. 2006;34(6):557-561.
6. Gonzalvo Ibanez FJ, Fuertes Fernandez I, Fernandez Tirado FJ, et al. External dacryocystorhinostomy with mitomycin C: clinical and anatomical evaluation with helical computed tomography. *Arch Soc Esp Oftalmol*. 2000;75(9):611-617.
7. You YA, Fang CT. Intraoperative mitomycin C in dacryocystorhinostomy. *Ophthal Plast Reconstr Surg*. 2001;17(2):115-119.
8. Argin A, Görür K, Ozcan C, Arslan E, Ozmen C, Vayisoglu Y. The role of larger osteotomy in long term success in external dacryocystorhinostomy. *J Plast Reconstr Aesthet Surg*. 2008;61(6):615-619.
9. Mann BS, Wormald PJ. Endoscopic assessment of the dacryocystorhinostomy ostium after endoscopic surgery. *Laryngoscope*. 2006;116(7):1172-1174.
10. Fayet B, Racy E, Assouline M, Zerbib M. Surgical anatomy of the lacrimal fossa a prospective computed tomodensitometry scan analysis. *Ophthalmology*. 2005;112(6):1119-1128.

©2012 American Medical Association. All rights reserved.
Downloaded From: http://jamanetwork.com/ on 05/25/2013