Picture of the Month

Jesleen Rana, BASc; Ahmed Alterkait, MBBCh; Michael Weinstein, FRCPC

A 12-YEAR-OLD BOY WITH NONVERBAL AUtism developed a 2-month history of petechiae and bruising followed by worsening musculoskeletal pain and refusal to walk. There was no preceding history of trauma, fever, or visible joint swelling. On physical examination he was pale and agitated. His lower limb range of motion was limited, and he maintained 90° flexion of both knees and external rotation of his left hip with refusal to ambulate. Petechiae and bruising were noted on his lower extremities (**Figure 1**), and gingival bleeding (**Figure 2**) and alopecia were noted. Investigations revealed microcytic anemia (hemoglobin level, 9.0 g/dL; reference range, 12.0-16.0 g/dL; to convert to grams per liter, multiply by 10.0), a low serum iron level, and normal white blood cell and platelet counts. The peripheral blood smear was normal apart from features suggestive of iron deficiency, and the erythrocyte sedimentation rate was elevated (46 mm/h; reference range, 1-10 mm/h). Radiographs of the legs demonstrated only soft-tissue swelling and osteopenia. Dietary history revealed longstanding restricted food preferences limited to yogurt, pasta, oatmeal, and water.

Author Affiliations: Queen's University, Kingston (Ms Rana) and Department of Pediatrics, The Hospital for Sick Children, Toronto (Drs Alterkait and Weinstein), Ontario, Canada.

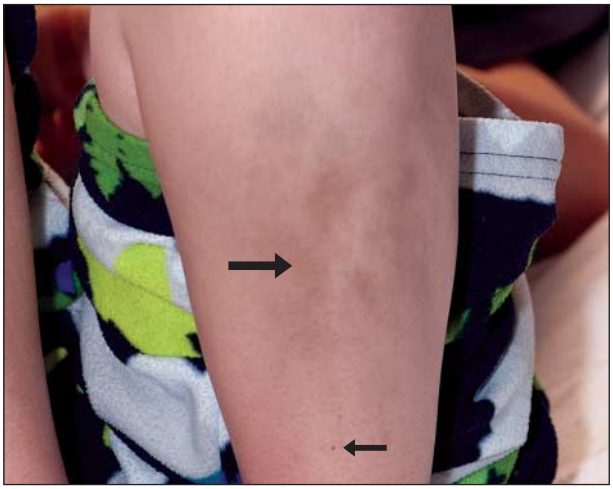

Figure 1. Bruising (large arrow) and perifollicular petechiae (small arrow) on the lower leg.

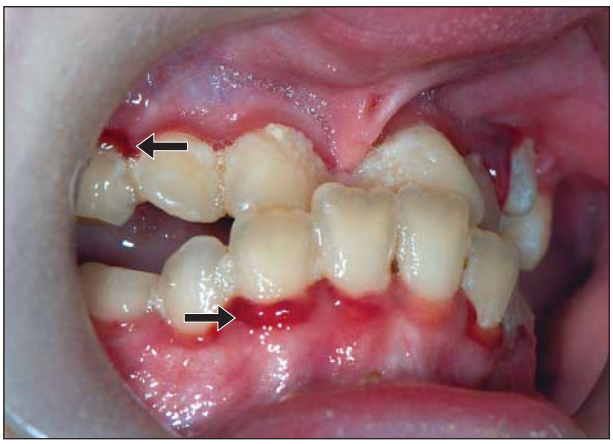

Figure 2. Diffuse gingival inflammation and bleeding (arrows).

©2012 American Medical Association. All rights reserved.

Downloaded From: http://jamanetwork.com/ on 05/24/2013