Image of the Month

Megan Steigelman, MD; Matthew Chauviere, MD

A 30-YEAR-OLD WOMAN PRESENTED TO OUR clinic with a painless, left-sided neck mass, which had slowly grown during 3 years. The patient denied any antecedent trauma, infection, or previous swelling in the area. She also denied any dyspnea, dysphagia, or left upper extremity weakness or paresthesia. Her medical history was significant for sickle cell trait, and she was a nonsmoker. On physical examination, she had a left supraclavicular mass that was soft, smooth, and fluctuant. A complete blood count showed she was anemic (hematocrit of 29), but had no symptoms of fatigue. An ultrasound of the neck showed a lobulated, multiseptated, thin-walled cystic mass in the left supraclavicular fossa measuring 8.2 cm in diameter. No wall thickening or mural nodules were seen. A computed tomographic scan of the neck with intravenous contrast was performed to further characterize the lesion (**Figure 1**). The cyst was fully excised in the operating room (**Figure 2**), and pathology confirmed the diagnosis.

Author Affiliations: Department of Surgery, David Grant Medical Center, Travis Air Force Base, California.

What Is the Diagnosis?

A. Lymphangioma
B. Branchial cleft cyst
C. Lymphoma
D. Dermoid cyst

Figure 2. Excised lesion.

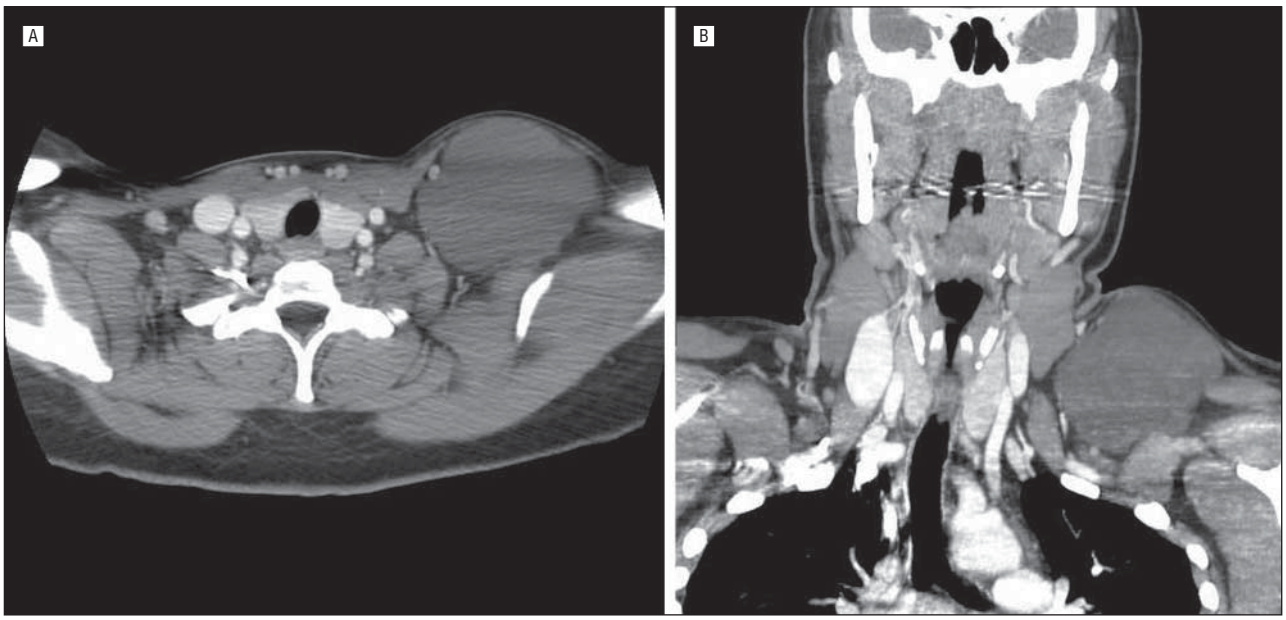

Figure 1. Computed tomographic imaging axial (A) and coronal (B) views of the cervical lesion.

©2012 American Medical Association. All rights reserved.
Downloaded From: http://jamanetwork.com/ on 05/21/2013