Picture of the Month

Ng Su Yuen, MRCPch; Sabeera Begum Kader Ibrahim, MS

An Indian girl carried to term and born weighing 2.87 kg was delivered spontaneously to a 29-year-old woman with no medical illness. She had meconium aspiration at delivery and was ventilated for 2 days. Her stay in the ward was complicated by the development of pneumothorax and recurrent hypoglycemia. On day 4 she developed thrombocytopenia (platelet count, $88\,000 \times 10^3/\mu L$ [to convert to $\times 10^9/L$, multiply by 1.0]) and 3 days later, she was noted to have an erythematous patch at her back that was treated as cellulitis with intravenous antibiotics. However, the lesion persisted and dermatologic review on day 9 of her life revealed an indurated, well-defined purplish plaque measuring 10.5×8 cm over her back (**Figure 1**) that was tender and warm but nonpulsatile. The remaining findings of her physical examination were normal, she was extubated successfully with no persistent respiratory symptoms, and there was no hepatosplenomegaly or lymphadenopathy. The correct diagnosis was made based on the characteristic skin changes and typical history and was confirmed by histologic examination of the skin biopsy. She was treated conservatively and monitored for complications of the condition. She was discharged well on day 14 of life. Her hypoglycemia and thrombocytopenia resolved before discharge. Her serum calcium level remained within the reference range on follow-up.

Author Affiliations: Paediatric Dermatology Unit, Institute Pediatrik, Hospital Kuala Lumpur, Kuala Lumpur, Wilayah Persekutuan, Malaysia.

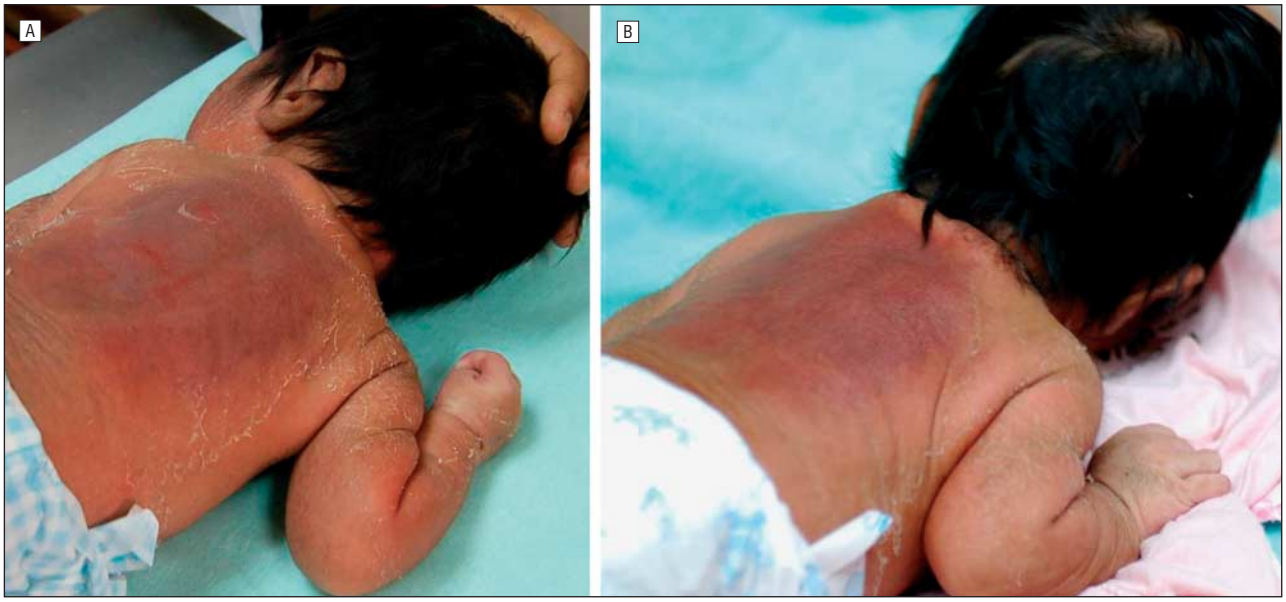

Figure 1. An indurated, well-defined purplish plaque measuring 10.5×8 cm was observed on the patient's back.

©2011 American Medical Association. All rights reserved.
Downloaded From: http://jamanetwork.com/ on 05/22/2013