ORIGINAL ARTICLE

Are Additional Localization Studies and Referral Indicated for Patients With Primary Hyperparathyroidism Who Have Negative Sestamibi Scan Results?

Dina M. Elaraj, MD; Rebecca S. Sippel, MD; Sheila Lindsay, RN; Ileana Sansano, MPH; Quan-Yang Duh, MD; Orlo H. Clark, MD; Electron Kebebew, MD

Hypothesis: Additional imaging studies are useful to select patients who are candidates for minimally invasive parathyroidectomy, and referral is not indicated when results from a preoperative sestamibi scan are negative.

Design, Setting, and Patients: Prospective analysis of 492 operations for primary hyperparathyroidism from May 2005 to May 2007 at a tertiary care center.

Main Outcome Measures: Accuracy of imaging studies, pathologic findings, and biochemical cure.

Results: Among the patients, 96% were cured. Of the sestamibi scan results, 91% were positive and 82% were true-positive. Ultrasonography results were positive in 51% of patients with negative sestamibi scan results, and 43% were true-positive. Patients with positive sestamibi scan results compared with those with negative sestamibi scan results had a higher rate of single-gland disease (87% vs 63%, respectively) and lower rates of double adenoma (6% vs 22%, respectively) and asymmetric hyperplasia (7% vs 15%, respectively) ($P<.001$). In patients with positive sestamibi scan results compared with those with negative sestamibi scan results, there was no significant difference in the rate of ectopic parathyroid glands (18% vs 12%, respectively) but there was a significant difference in cure rate (97% vs 89%, respectively) ($P=.008$).

Conclusions: Additional imaging with neck ultrasonography is helpful for selecting minimally invasive parathyroidectomy in most patients with primary hyperparathyroidism who have negative sestamibi scan results. Referral for parathyroidectomy may be considered in patients with negative sestamibi scan results because these results are associated with multigland disease and lower cure rates.

Arch Surg. 2010;145(6):578-581

Approximately 100 000 new cases of primary hyperparathyroidism (PHPT) are diagnosed annually.[1] Primary hyperparathyroidism is commonly due to a single parathyroid adenoma (80%-87%) followed by multigland disease (10%-15% asymmetric 4-gland hyperplasia, 2%-5% multiple adenomas) and, rarely, carcinoma (<1%).[1] It is one of the most common endocrine disorders for which parathyroidectomy is the only effective therapy. There has been a shift to a focused approach for parathyroidectomy because of improved accuracy of preoperative localizing studies and the use of intraoperative parathyroid hormone (PTH) testing to confirm biochemical cure. In most medical centers, the most accurate and first-line localizing study used in patients with PHPT is a sestamibi scan.[2] Positive sestamibi scan results that show single-gland disease allow a focused approach to be used with high biochemical cure rates, similar to those obtained with bilateral neck exploration.[3]

Although the accuracy of sestamibi scanning for localizing a parathyroid tumor is high, especially in patients with single-gland disease, a significant number of patients will have nonlocalizing studies.[2] In such cases, several investigators have demonstrated that the risk of multigland disease is high.[4-7] However, some investigators have suggested that a significant number of patients with PHPT who have negative sestamibi scan results could still undergo a focused-approach parathyroidectomy by having additional localizing studies that detect probable single-gland disease.[8,9] The most commonly used additional localizing studies are high-resolution neck ultrasonography and, more recently, 4-dimensional computed tomography.

Anecdotally, we have observed an increasing number of patients with PHPT who are referred for parathyroidectomy because their sestamibi scan results were nega-

Author Affiliations: Department of Surgery, Feinberg School of Medicine, Northwestern University, Chicago, Illinois (Dr Elaraj); and Department of Surgery, University of California, San Francisco (Drs Sippel, Duh, Clark, and Kebebew and Mss Lindsay and Sansano).

©2010 American Medical Association. All rights reserved.
Downloaded From: http://jamanetwork.com/ on 06/18/2013

tive. Some investigators have also suggested that patients with PHPT who have negative sestamibi scan results are more likely to have ectopic parathyroid glands and warrant referral to a tertiary care center with experienced endocrine surgeons.[10]

There are limited studies, however, that comprehensively address the impact of additional imaging studies on influencing the parathyroidectomy approach used and that determine the frequency of ectopic parathyroid tumors and the outcome of patients with negative sestamibi scan results. We therefore set out to determine whether obtaining additional imaging studies could increase the number of patients who could be identified preoperatively as having single-gland disease, improve the outcome of parathyroidectomy, and localize the site of disease in a prospective cohort of 487 unselected patients.

METHODS

Review of a prospective database identified 487 patients who underwent 492 neck explorations for PHPT at the University of California, San Francisco Medical Centers between May 2005 and May 2007. We reviewed demographic, clinical (including the presence of family history of PHPT and history of exposure to head and neck radiation), preoperative biochemical (serum calcium and intact PTH levels), and radiographic (high-resolution neck ultrasonography performed by board-certified radiologists and technetium Tc 99m sestamibi scans) data as well as operative notes, pathology reports, and clinic follow-up notes 2 to 3 weeks postoperatively. The committee on human research approved this study at our institution.

Patients underwent a focused-approach parathyroidectomy (operation limited to resection of 1 abnormal parathyroid gland without further neck exploration), unilateral neck exploration (identification of 2 parathyroid glands on the same side), or bilateral neck exploration (identification of all 4 parathyroid glands). The intraoperative PTH assay was used as an adjunct in most cases. Biochemical cure was confirmed by having both postoperative serum calcium and intact PTH values within the normal range. In cases where either the postoperative calcium or PTH level was elevated, biochemical cure was defined by the serum calcium level being within the normal range at least 6 months postoperatively.

The results of the preoperative imaging were compared with the operative results. A true-positive study was defined as one in which 1 abnormal parathyroid gland was identified and 1 abnormal parathyroid gland was resected, resulting in biochemical cure. A study that identified all abnormal parathyroid glands in the case of multigland disease was also defined as a true-positive study. A false-positive study was defined as one in which no abnormal parathyroid gland was found on the side identified by the preoperative imaging study. A study that identified more than 1 abnormal parathyroid gland with the intraoperative finding of a single abnormal gland and subsequent biochemical cure was also defined as a false-positive study. Given that all patients had a biochemical diagnosis of PHPT, there were no true-negative studies. A false-negative study was defined as one that failed to show all of the abnormal parathyroid glands. Imaging studies of patients with persistent disease after neck exploration (n=20) or of those who were lost to follow-up (n=6) were designated as unknown and were excluded from accuracy calculations.

Data are presented as mean (SD) or as number (percentage). Categorical data were compared using the Fisher exact test with 2-tailed *P* values. A difference was defined as statistically significant when $P<.05$.

Table. Demographic and Clinical Characteristics of Patients With Primary Hyperparathyroidism

Characteristic	Value
Female, No. (%)	382 (78)
Race/ethnicity, No. (%)	
White	412 (85)
Other/not specified	75 (15)
Age, mean (SD), y	59.2 (13.4)
History of head and neck radiation, No. (%)	40 (8)
Personal or family history of PHPT, No. (%)	38 (8)
Familial PHPT	28
MEN-1	8
MEN-2A	2
Unknown family history	10
Type of PHPT, No. (%)	
Initial presentation	431 (88)
Persistent disease[a]	48 (10)
Recurrent disease[a]	13 (2)
Preoperative calcium level, mean (SD), mg/dL	11.1 (0.8)
Preoperative intact PTH level, mean (SD), pg/mL	128.4 (89.1)

Abbreviations: MEN, multiple endocrine neoplasia; PHPT, primary hyperparathyroidism; PTH, parathyroid hormone.

SI conversion factors: To convert calcium to millimoles per liter, multiply by 0.25; to convert PTH to nanograms per liter, multiply by 1.

[a] Persistent disease is defined by an elevated serum calcium level with an inappropriately elevated PTH level 6 months following the initial operation for PHPT. Recurrent disease is defined by a period of normocalcemia for at least 6 months following the initial operation for PHPT with subsequent elevation in the serum calcium level and an inappropriately elevated PTH level.

RESULTS

Four hundred eighty-seven patients had 492 neck operations for PHPT (88% initial and 12% reoperation). The demographic and clinical characteristics of the study cohort are summarized in the **Table**. The overall biochemical cure rate was 96% and was significantly higher in initial operations (97%) than in reoperations (87%) ($P<.001$).

Results from 447 sestamibi scans were positive (91%) and 82% were true-positive (**Figure**). Sestamibi scan results were positive for a single abnormal gland in 391 cases (87%) and positive for multiple glands in 56 cases (13%). In patients who had negative sestamibi scan results, ultrasonography results were positive in 51%, and 43% of cases were true-positive (Figure).

Three hundred thirty-nine patients (69%) underwent parathyroidectomy via a focused or unilateral approach, while 153 (31%) underwent bilateral neck exploration. Of the 480 patients who had 1 or more abnormal parathyroid gland resected, 407 patients (85%) had a single adenoma and 73 (15%) had a double adenoma (n=35 [7%]) or multigland hyperplasia (n=38 [8%]). Twelve patients had negative results on neck exploration. Patients with positive sestamibi scan results were significantly more likely to have a focused or unilateral neck exploration for parathyroidectomy ($P<.001$) (Figure).

Patients who had positive sestamibi scan results compared with those who had negative sestamibi scan results were significantly more likely to have single-gland disease (87% vs 63%, respectively) than multigland disease (double adenoma, 6% vs 22%, respectively; asymmetric hyperplasia, 7% vs 15%, respectively) ($P<.001$).

©2010 American Medical Association. All rights reserved.
Downloaded From: http://jamanetwork.com/ on 06/18/2013

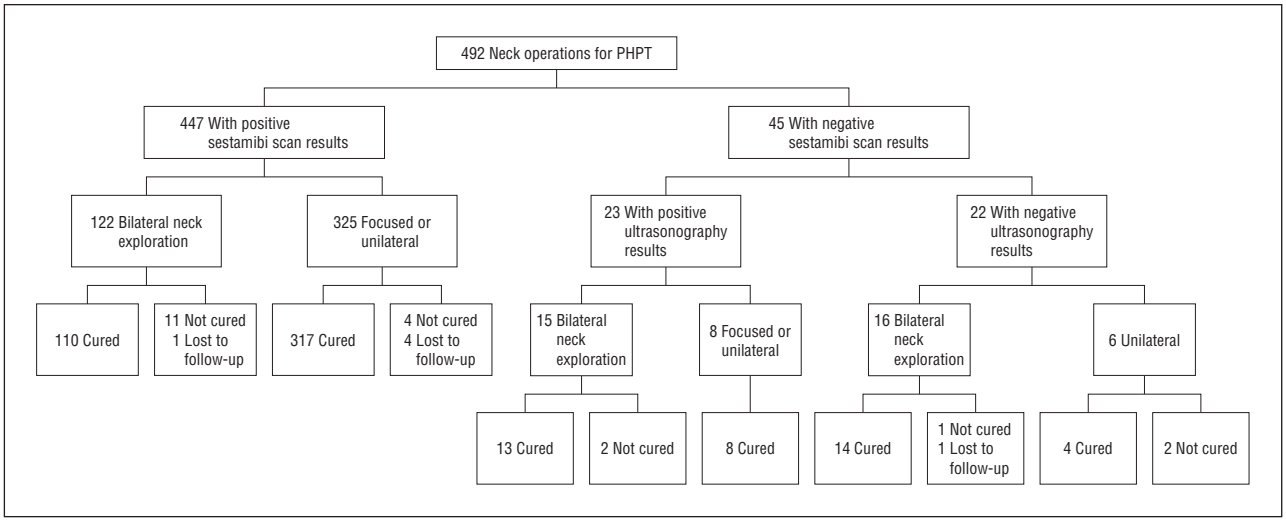

Figure. Results of imaging studies and neck exploration of 492 neck operations for primary hyperparathyroidism (PHPT).

Eighteen percent of patients with positive sestamibi scan results had ectopic parathyroid glands vs 12% of patients with negative sestamibi scan results. There was no significant difference by the site of parathyroid tumor (ie, ectopic vs normal anatomic sites). We found no significant difference by age, sex, race/ethnicity, and preoperative serum total calcium and intact PTH levels in patients with PHPT who had positive vs negative sestamibi scan results.

Patients with PHPT who had positive sestamibi scan results had a higher biochemical cure rate than patients who had negative sestamibi scan results (97% vs 89%, respectively; $P=.008$). We performed a subset analysis of only patients who were cured, comparing groups with positive vs negative sestamibi scan results, and also found a significant difference in the type of parathyroid disease ($P<.001$) and surgical approach used ($P<.001$). We further performed a subset analysis of patients who underwent only initial neck exploration, because patients with persistent or recurrent disease often require multiple localizing studies to ensure that the hyperfunctioning and enlarged parathyroid tumor is identified. The differences in the type of parathyroid disease and cure rate persisted in this subgroup of patients.

COMMENT

Most patients with PHPT have single-gland disease, and the use of sestamibi scanning has proven to be useful for selecting patients who would be ideal candidates for a focused or minimally invasive approach. However, when sestamibi scan results are negative, the need and utility of additional imaging studies, their predictive value of single-gland vs multigland disease, and the implications on outcome are just beginning to be defined but have not been comprehensively addressed in a single cohort study. We found that neck ultrasonography in patients with negative sestamibi scan results correctly indicated single-gland disease in 54% of patients. Also, negative sestamibi scan results were associated with a higher risk of multigland disease and lower biochemical cure rates.

The routine use of additional imaging studies to determine whether patients with PHPT have single-gland vs multigland disease has been advocated by some investigators because when these studies are concordant for 1 enlarged parathyroid gland, the likelihood of a successful focused parathyroidectomy approach with or without the use of intraoperative PTH measurement is high (>95%).[11,12] Ultrasonography has been most commonly used in addition to sestamibi scanning at most centers, but 4-dimensional computed tomography has also been used more recently. When the sestamibi scan results are negative and when an additional imaging study is used, up to 80% of the cases have been reported to be positive for single-gland disease. We observed a similar rate in our cohort, and 46% of these patients were able to undergo a focused approach or unilateral parathyroidectomy with biochemical cure. Our findings suggest that the use of a focused approach is possible in such cases, but intraoperative PTH measurement should probably be used to confirm biochemical cure. The cost-effectiveness of using localizing studies in addition to sestamibi scanning is unknown, especially if sestamibi scan results are already positive for single-gland disease in patients with initial PHPT.[13]

Negative sestamibi scan results are informative about which surgical approach may be best to use because they indicate a higher risk of multigland disease and, in some studies, a higher risk of an ectopic parathyroid tumor requiring more extensive dissection.[4-7,10] We found that 37% of patients with negative sestamibi scan results had multigland disease, similar to the rates observed by other investigators.[4-7] When the sestamibi scan and neck ultrasonography results were negative, 40% of patients had multigland disease. All of these patients underwent bilateral neck exploration, and the biochemical cure rate was 100%. Although some investigators have reported higher rates of ectopic parathyroid tumors in patients with negative sestamibi scan results, we found no significant difference in our study cohort. This is not surprising as sestamibi scanning is better for localizing ectopic parathyroid tumors in the mediastinum, which cannot be imaged with neck ultrasonography.[14] We also found that

©2010 American Medical Association. All rights reserved.
Downloaded From: http://jamanetwork.com/ on 06/18/2013

the biochemical cure rate in patients with negative sestamibi scan results was lower, even when considering only patients who underwent initial operation for PHPT.

Limitations of our data include the short follow-up for most of our patients, which may affect the long-term biochemical cure rates. Other studies, however, have used normal postoperative calcium levels with or without the addition of normal postoperative PTH values to define biochemical cure.[15,16]

There are no established criteria for referral of patients with PHPT to tertiary care medical centers. Several investigators have suggested that complication rates are lower in high-volume centers or when the operations are performed by high-volume surgeons.[17,18] Most parathyroidectomies are, however, performed by low-volume surgeons. Although anecdotal, the number of patients being referred for negative sestamibi scan results has increased in our practice. Our data suggest that there is a higher risk of failed neck exploration because of multigland disease in patients with PHPT who have negative sestamibi scan results. Of course, it is unclear whether these patients' outcomes would be any different if they received their care at a nontertiary care center, but given that most patients with persistent or recurrent PHPT are referred to experienced endocrine surgeons, it may be reasonable to suggest that patients with negative sestamibi scan results be referred to such centers. There are several reasons for this: (1) parathyroidectomy complication rates are lower when performed by a high-volume endocrine surgeon; (2) localizing studies performed at tertiary care centers may be more accurate; and (3) nontertiary care centers do not usually have the availability of parathyroid gland cryopreservation in cases of multigland disease requiring subtotal parathyroidectomy.

In summary, we have found that patients with PHPT who have negative sestamibi scan results benefit from having additional imaging studies to determine whether they have single-gland vs multigland disease. Negative sestamibi scan results are associated with a higher risk of multigland disease and lower biochemical cure rates. Therefore, referral for parathyroidectomy to a tertiary care center may be considered in patients with negative sestamibi scan results.

Accepted for Publication: June 3, 2009.
Correspondence: Dina M. Elaraj, MD, Department of Surgery, Feinberg School of Medicine, Northwestern University, 676 N St Clair St, Ste 650, Chicago, IL 60611 (delaraj@nmh.org).
Author Contributions: *Study concept and design:* Duh, Clark, and Kebebew. *Acquisition of data:* Elaraj, Lindsay, and Sansano. *Analysis and interpretation of data:* Elaraj, Sippel, Duh, and Kebebew. *Drafting of the manuscript:* Elaraj and Kebebew. *Critical revision of the manuscript for important intellectual content:* Elaraj, Sippel, Lindsay, Sansano, Duh, Clark, and Kebebew. *Statistical analysis:* Elaraj and Kebebew. *Obtained funding:* Duh, Clark, and Kebebew. *Administrative, technical, and material support:* Lindsay, Sansano, Clark, and Kebebew. *Study supervision:* Duh, Clark, and Kebebew.
Financial Disclosure: None reported.
Funding/Support: This study was supported in part by the Mount Zion Health Fund and the Friends of Endocrine Surgery.
Role of the Sponsors: The sponsors had no role in the design and conduct of the study; collection, management, analysis, and interpretation of the data; and preparation, review, or approval of the manuscript.
Previous Presentation: This paper was presented at the 80th Annual Meeting of the Pacific Coast Surgical Association; February 14, 2009; San Francisco, California.

REFERENCES

1. Kebebew E, Clark OH. Parathyroid adenoma, hyperplasia, and carcinoma: localization, technical details of primary neck exploration, and treatment of hypercalcemic crisis. *Surg Oncol Clin N Am.* 1998;7(4):721-748.
2. Uruno T, Kebebew E. How to localize parathyroid tumors in primary hyperparathyroidism? *J Endocrinol Invest.* 2006;29(9):840-847.
3. Palazzo FF, Delbridge LW. Minimal-access/minimally invasive parathyroidectomy for primary hyperparathyroidism. *Surg Clin North Am.* 2004;84(3):717-734.
4. Civelek AC, Ozalp E, Donovan P, Udelsman R. Prospective evaluation of delayed technetium-99m sestamibi SPECT scintigraphy for preoperative localization of primary hyperparathyroidism. *Surgery.* 2002;131(2):149-157.
5. Sebag F, Hubbard JG, Maweja S, Misso C, Tardivet L, Henry JF. Negative preoperative localization studies are highly predictive of multiglandular disease in sporadic primary hyperparathyroidism. *Surgery.* 2003;134(6):1038-1042.
6. Mihai R, Gleeson F, Buley ID, Roskell DE, Sadler GP. Negative imaging studies for primary hyperparathyroidism are unavoidable: correlation of sestamibi and high-resolution ultrasound scanning with histological analysis in 150 patients. *World J Surg.* 2006;30(5):697-704.
7. Yip L, Pryma DA, Yim JH, Carty SE, Ogilvie JB. Sestamibi SPECT intensity scoring system in sporadic primary hyperparathyroidism. *World J Surg.* 2009;33(3):426-433.
8. Harari A, Zarnegar R, Lee J, Kazam E, Inabnet WB III, Fahey TJ III. Computed tomography can guide focused exploration in select patients with primary hyperparathyroidism and negative sestamibi scanning. *Surgery.* 2008;144(6):970-979.
9. Davis ML, Quayle FJ, Middleton WD, et al. Ultrasound facilitates minimally invasive parathyroidectomy in patients lacking definitive localization from preoperative sestamibi scan. *Am J Surg.* 2007;194(6):785-791.
10. Chan RK, Ruan DT, Gawande AA, Moore FD Jr. Surgery for hyperparathyroidism in image-negative patients. *Arch Surg.* 2008;143(4):335-337.
11. Gawande AA, Monchik JM, Abbruzzese TA, Iannuccilli JD, Ibrahim SI, Moore FD Jr. Reassessment of parathyroid hormone monitoring during parathyroidectomy for primary hyperparathyroidism after 2 preoperative localization studies. *Arch Surg.* 2006;141(4):381-384.
12. Arici C, Cheah WK, Ituarte PH, et al. Can localization studies be used to direct focused parathyroid operations? *Surgery.* 2001;129(6):720-729.
13. Ruda JM, Stack BC Jr, Hollenbeak CS. The cost-effectiveness of additional preoperative ultrasonography or sestamibi-SPECT in patients with primary hyperparathyroidism and negative findings on sestamibi scans. *Arch Otolaryngol Head Neck Surg.* 2006;132(1):46-53.
14. Phitayakorn R, McHenry CR. Incidence and location of ectopic abnormal parathyroid glands. *Am J Surg.* 2006;191(3):418-423.
15. Mozzon M, Mortier PE, Jacob PM, Soudan B, Boersma AA, Proye CA. Surgical management of primary hyperparathyroidism: the case for giving up quick intraoperative PTH assay in favor of routine PTH measurement the morning after. *Ann Surg.* 2004;240(6):949-954.
16. Kebebew E, Hwang J, Reiff E, Duh QY, Clark OH. Predictors of single-gland vs multigland parathyroid disease in primary hyperparathyroidism: a simple and accurate scoring model. *Arch Surg.* 2006;141(8):777-782.
17. Sosa JA, Tuggle CT, Wang TS, et al. Clinical and economic outcomes of thyroid and parathyroid surgery in children. *J Clin Endocrinol Metab.* 2008;93(8):3058-3065.
18. Sosa JA, Powe NR, Levine MA, Udelsman R, Zeiger MA. Profile of a clinical practice: thresholds for surgery and surgical outcomes for patients with primary hyperparathyroidism: a national survey of endocrine surgeons. *J Clin Endocrinol Metab.* 1998;83(8):2658-2665.

©2010 American Medical Association. All rights reserved.
Downloaded From: http://jamanetwork.com/ on 06/18/2013