Image of the Month

Faith Dorsey, MD; Melissa W. Taggart, MD; William E. Fisher, MD

A 54-YEAR-OLD WOMAN PRESENTED WITH chronic intermittent sharp midepigastric abdominal pain. She denied having jaundice or a change in her bowel function but admitted to a 5.4-kg weight loss over 3 months. Medical, surgical, family, and social histories were unremarkable. There was no history of neurofibromatosis 1. The results of physical examination and routine laboratory tests, including liver function tests, were normal. A right upper quadrant ultrasonographic and computed tomographic (CT) scan with contrast revealed a 1.4-cm enhancing lesion in the head of the pancreas without duct dilation (**Figure 1**).

Author Affiliations: The Elkins Pancreas Center, Michael E. DeBakey Department of Surgery, Baylor College of Medicine (Drs Dorsey and Fisher), and Department of Pathology, Saint Luke's Episcopal Hospital (Dr Taggart), Houston, Texas.

What Is the Diagnosis?

A. Pancreatic adenocarcinoma
B. Neuroendocrine carcinoma
C. Pancreatic schwannoma
D. Renal cell carcinoma metastatic to the pancreas

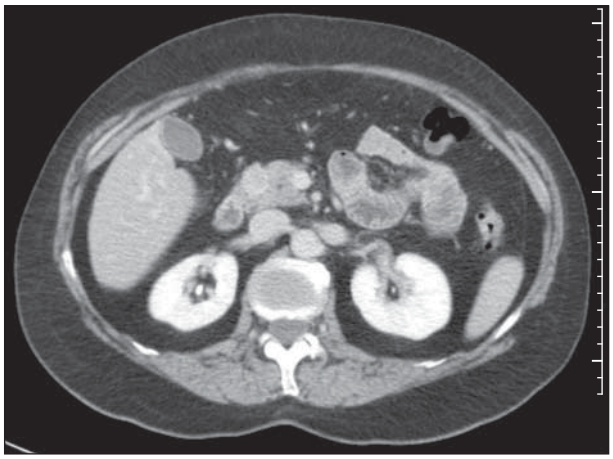

Figure 1. Preoperative computed tomographic scan showing a 1.4-cm enhancing lesion in the head of the pancreas.

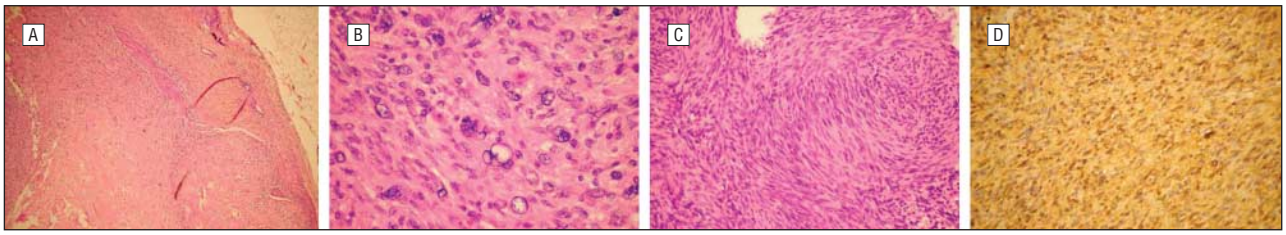

Figure 2. Histology of the resected specimen showing an encapsulated neoplasm within the pancreas composed of spindle cells. A, Nerve fibers are adjacent to and within the fibrous capsule (hematoxylin-eosin staining, original magnification ×40). B, The nuclei demonstrated significant atypia focally (hematoxylin-eosin, original magnification ×400). C, Verocay bodies (rows of nuclei with intervening cell processes) were present (hematoxylin-eosin, original magnification ×200). D, An immunohistochemical stain for S-100 shows diffuse nuclear and cytoplasmic staining (polyclonal S-100, original magnification ×100). These findings are consistent with the diagnosis of ancient schwannoma.

©2010 American Medical Association. All rights reserved.
Downloaded From: http://jamanetwork.com/ on 05/21/2013