Answer

Splenic Artery Pseudoaneurysm

During celiac arteriography, a splenic artery pseudoaneurysm (PSA) with a tight jet of contrast medium extravasation from the midsplenic artery was identified (**Figure 2**). Coil embolization was performed, with coils deployed at the site of contrast agent leak, eliminating the extravasation. The remaining hospital course was uneventful, with continued hemodynamic stability, improving abdominal tenderness, normalization of the serum lipase level, and a stable hemoglobin level. The patient tolerated a regular diet without difficulty and was discharged.

Chronic pancreatitis is traditionally associated with upper gastrointestinal bleeding originating from peptic ulcers, esophageal or gastric varices, and erosive gastritis. Alternatively, pseudocysts can erode into the splenic artery and cause gastrointestinal bleeding. Arterial PSAs in this patient population are rare but may present with potentially lethal hemorrhage. The mechanism for PSA formation in chronic pancreatitis is enzymatic erosion of the arterial walls triggered by an overall inflammatory reaction in the pancreas. Mortality rates due to peripancreatic vessel PSA have been reported to be as high as 40%, making early diagnosis and adequate treatment clinically important.[1]

The clinical presentation of the PSA depends on the behavior of the vessel involved: local compression can cause early satiety, abdominal fullness, or vague pain. The PSA may rupture into the peritoneal cavity, the retroperitoneum, the biliary pancreatic ducts, the portal vein, or an adjacent pseudocyst. The varied bleeding site may manifest as melena, or, in cases of frank rupture, patients may present with severe abdominal pain and extensive bleeding leading to hemoperitoneum and hemodynamic instability. In order of incidence, the splenic artery (31%) appears to be the artery most affected, followed by the gastroduodenal, pancreaticoduodenal, and hepatic arteries.[2] Early imaging studies are critical for adequate diagnosis. Contrast-enhanced CT is a well-established noninvasive method for peripancreatic vessel imaging. Arteriography is useful in localizing the source of the bleeding in smaller PSAs, which can be missed by CT. However, intermittent arterial bleeding and venous bleeding can be missed by angiography.[3]

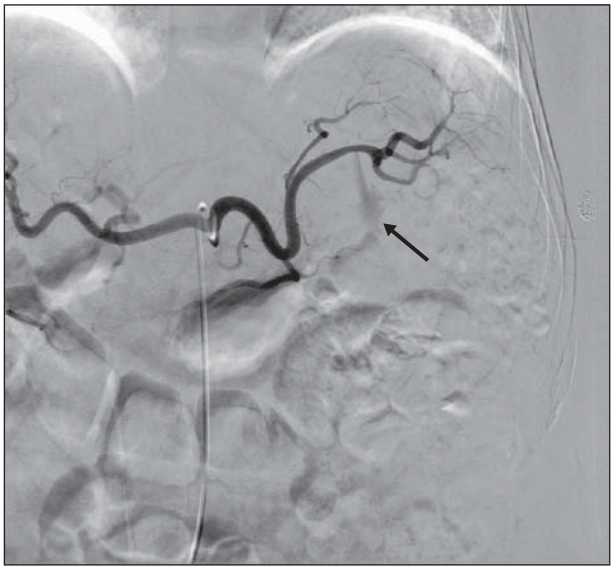

Figure 2. Selective splenic arteriography findings show a jet of contrast medium extending into a pseudoaneurysm (arrow).

Once the PSA has been identified, effective treatment can be achieved with endovascular therapy or by open surgical approaches. Although uncontrolled bleeding with hemodynamic instability and acute abdomen is generally a surgical indication, growing experience with coil embolization has resulted in its increased use to avoid difficult operations in an already inflamed field. Successful embolization has been reported in 79% to 100% of cases, with a mortality rate as high as 30%.[4,5] Some surgeons still favor surgical repair given the risk and mortality associated with embolization in some of the published case series.[3] Surgical options include proximal and distal ligation of the bleeding vessel, as well as drainage of the cyst and pancreatic resection. Distal pancreatectomy and splenectomy are preferred in cases of bleeding near the tail of the pancreas, since these procedures have low morbidity and mortality. Survival outcomes are better when lesions are in the body and tail of the pancreas compared with those in the head of the pancreas.[6]

In conclusion, although rare, splenic artery PSAs secondary to chronic pancreatitis do occur and present a unique clinical challenge. Prompt recognition through the judicious use of imaging can lead to less-invasive therapeutic strategies, such as endovascular coil embolization, and avoid difficult abdominal operations and considerable morbidity.

Accepted for Publication: October 1, 2010.
Correspondence: Julie A. Freischlag, MD, Department of Surgery, The Johns Hopkins University, 720 Rutland Ave, Ross 759, Baltimore, MD 21205 (jfreisc1@jhmi.edu).
Author Contributions: *Study concept and design:* Loyo, Guzzo, Lum, and Freischlag. *Acquisition of data:* Loyo. *Analysis and interpretation of data:* Lum and Freischlag. *Drafting of the manuscript:* Loyo, Guzzo, and Lum. *Critical revision of the manuscript for important intellectual content:* Guzzo, Lum, and Freischlag. *Study supervision:* Guzzo, Lum, and Freischlag.
Financial Disclosure: None reported.
Disclaimer: Dr Freischlag is the editor of the *Archives of Surgery*. She was not involved in the editorial evaluation or decision to accept this article for publication.

©2011 American Medical Association. All rights reserved.
Downloaded From: http://jamanetwork.com/ on 05/21/2013

REFERENCES

1. Hsu JT, Yeh CN, Hung CF, et al. Management and outcome of bleeding pseudoaneurysm associated with chronic pancreatitis [published online January 11, 2006]. *BMC Gastroenterol*. 2006;6:3. doi:10.1186/1471-230X-6-3.
2. Balachandra S, Siriwardena AK. Systematic appraisal of the management of the major vascular complications of pancreatitis. *Am J Surg*. 2005;190(3):489-495.
3. Moore E, Matthews MR, Minion DJ, et al. Surgical management of peripancreatic arterial aneurysms. *J Vasc Surg*. 2004;40(2):247-253.
4. Vujic I, Andersen BL, Stanley JH, Gobien RP. Pancreatic and peripancreatic vessels: embolization for control of bleeding in pancreatitis. *Radiology*. 1984;150(1):51-55.
5. Savastano S, Feltrin GP, Antonio T, Miotto D, Chiesura-Corona M, Castellan L. Arterial complications of pancreatitis: diagnostic and therapeutic role of radiology. *Pancreas*. 1993;8(6):687-692.
6. Stabile BE, Wilson SE, Debas HT. Reduced mortality from bleeding pseudocysts and pseudoaneurysms caused by pancreatitis. *Arch Surg*. 1983;118(1):45-51.

Submissions

The Editor welcomes contributions to the Image of the Month. Manuscripts should be submitted via our online manuscript submission and review system (http://manuscripts.archsurg.com). Articles and photographs accepted will bear the contributor's name. Manuscript criteria and information are per the Instructions for Authors for Archives of Surgery (http://archsurg.ama-assn.org/misc/ifora.dtl). No abstract is needed, and the manuscript should be no more than 3 typewritten pages. There should be a brief introduction, 1 multiple-choice question with 4 possible answers, and the main text. No more than 2 photographs should be submitted. There is no charge for reproduction and printing of color illustrations.

©2011 American Medical Association. All rights reserved.

Downloaded From: http://jamanetwork.com/ on 05/21/2013