Image of the Month

Miral Amin, MD; Egbert Liquete, MD; Amy Braddock, MD; Robert B. Robinson, MD

A 66-YEAR-OLD, OTHERWISE HEALTHY MAN presented to the surgeon's office concerning a palpable lump in his right flank. He denied any fever, chills, or constitutional symptoms, and he had no history of trauma. His medical history included polycystic kidney disease; his surgical history, laparoscopic cholecystectomy 3 years earlier for acute gangrenous cholecystitis with cholelithiasis and excision of a lipoma from the right side of the abdominal wall 1 year earlier. On examination, the mass was approximately 10 × 5 cm and mobile. There was no overlying erythema, tenderness, ecchymosis, or induration. The other physical examination results were unremarkable. The patient was taken to the operating room for excision of the mass with a 12th rib operative approach in a left lateral decubitus position. During exploration, the mass was noted to be an abscess. The cavity was copiously irrigated and the incision was closed over a closed suction drain. Ultrasonography (US) and computed tomography (CT) were performed to evaluate the etiology of the abscess. The US image and CT scan (**Figure 1**) showed a complex retroperitoneal mass just behind the right kidney. The soft-tissue inflammation extended to the skin.

Author Affiliations: General Surgery Residency Program, Division of General Surgery, Department of Surgery, St. Joseph Mercy Oakland, Pontiac, Michigan.

What Is the Diagnosis?

A. Mass in the right adrenal gland
B. Retroperitoneal liposarcoma
C. Retroperitoneal retained gallstone
D. Mass in the right kidney

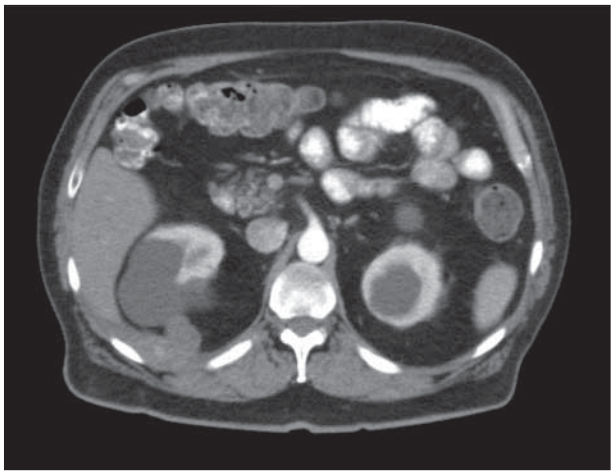

Figure 1. The computed tomographic scan shows a complex retroperitoneal mass just behind the right kidney.

©2011 American Medical Association. All rights reserved.
Downloaded From: http://jamanetwork.com/ on 05/19/2013