Image of the Month

Ahmed Fouad Bouras Jr, MD; Stéphanie Truant, MD, PhD; Carlos Zerrweck, MD; Emmanuel Boleslawski, MD; François-René Pruvot, MD; Philippe Zerbib, MD, PhD

A 71-YEAR-OLD MAN WAS ADMITTED TO OUR hospital for a routine checkup, during which an incidental cystic mass in the liver was discovered. His past medical history included obesity (body mass index [calculated as weight in kilograms divided by height in meters squared], 34.7), 1.4 oz of daily alcohol consumption since adolescence, atrial fibrillation, and type 2 diabetes mellitus; past exposure to an endemic zone of hydatid disease was also documented. Blood analysis showed an elevated serum level of γ-glutamyltransferase (90 U/L [to convert to microkatals per liter, multiply by 0.0167]), but the test results were within normal ranges; these included liver function tests, complete blood cell count, level of tumor markers, and serologic tests for amoebae and hydatid disease. Computed tomography revealed a dysmorphic liver and a 5-cm septated cystic mass of segment 8 with peripheral heterogeneous enhancement in portal and delayed phases, without enhancement in the arterial phase. There were internal septations but no calcifications in the wall (**Figure 1**). There was no portal hypertension on computed tomographic imaging, and a hepatic venous pressure gradient of 8 mmHg was reported. Also, magnetic resonance imaging was performed, not being contributory. Owing to an uncertain diagnosis, an exploratory laparotomy with complete cystic mass excision was conducted. The operative findings were as follows: a cirrhotic liver and a cystic mass with a macroscopic benign aspect and a thick, black-colored fluid inside. Postoperative courses were uneventful.

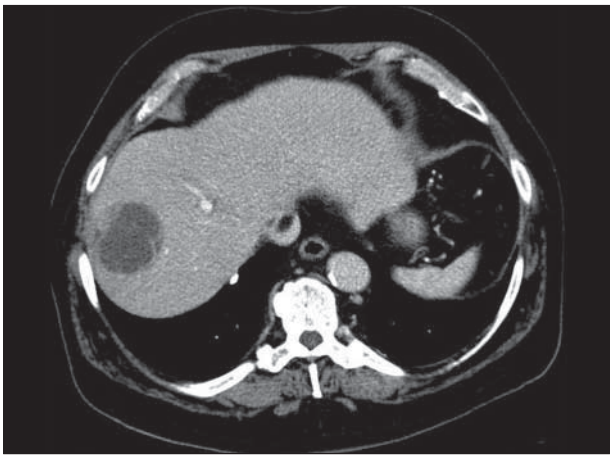

Figure 1. Cystic mass of segment 8 with peripheral enhancement in portal phase.

Author Affiliation: Department of Digestive Surgery and Transplantations, Aile Ouest, Hopital Huriez, Lille, France.

What Is the Diagnosis?

A. Hydatic cyst
B. Serous cystadenoma or cystadenocarcinoma
C. Cystic hepatocellular carcinoma
D. Liver abscess

©2011 American Medical Association. All rights reserved.

Downloaded From: http://jamanetwork.com/ on 05/25/2013