SECTION EDITOR: GEORGE J. HRUZA, MD; ASSISTANT SECTION EDITORS: MICHAEL P. HEFFERNAN, MD; CHRISTIE AMMIRATI, MD

Fractional Photothermolysis for the Treatment of Adult Colloid Milium

Diego E. Marra, MD; Shahram Pourrabbani, MD; Edgar F. Fincher, MD; Ronald L. Moy, MD; David Geffen School of Medicine, University of California, Los Angeles (Drs Marra, Pourrabbani, Fincher, and Moy), and Department of Internal Medicine, West Los Angeles Veterans Affairs Medical Center (Dr Pourrabbani)

The Cutting Edge: Challenges in Medical and Surgical Therapeutics

REPORT OF A CASE

An otherwise healthy 54-year-old white man presented for evaluation of a long-standing, progressive eruption on his cheeks. On physical examination, the affected areas showed large yellowish plaques composed of minute pseudovesicular lesions (**Figure 1**). The patient admitted to a long history of unprotected sun exposure. His medical history was negative for photosensitizing medications and disorders, and there was no family history of similar skin findings. A biopsy specimen, which was obtained from a representative area on the left cheek, revealed deposition of eosinophilic hyalinized material within the papillary dermis. These large collections distended the dermal papillae, and the hyalinized material showed fracturing artifact. The results of Congo red staining were positive. These findings supported the diagnosis of adult colloid milium (CM). The patient underwent a workup, including a complete blood cell count, metabolic profile, erythrocyte sedimentation rate, and serum protein electrophoresis, and the results were all within normal limits. The patient had previously undergone treatment with topical retinoids, without benefit. He had been offered carbon dioxide laser resurfacing but had declined because of the associated risks and prolonged recovery period.

THERAPEUTIC CHALLENGE

Colloid milium is a potentially disfiguring condition with limited treatment options. It does not respond to topical therapies, and although it may improve after dermabrasion or laser resurfacing, such ablative modalities can result in significant morbidity, risks, and often-unacceptable limitations on patients with active lifestyles.

SOLUTION

After a full discussion of treatment options, the patient agreed to a trial of fractional resurfacing to a limited area with a commercially available laser system (Fraxel; Reliant Technologies, Palo Alto, Calif). After application of a tracking dye, 30% lidocaine gel was applied to the left cheek and was left in place for 1 hour before treatment. The patient received a total of 5 treatments to the left cheek that were spaced 2 to 3 weeks apart. The treatments were performed at settings of 20 mJ, 125 microthermal zones per square centimeter, and 10 to 12 passes. The total energy delivered per treatment ranged from 1.6 to 2.1 kJ. The patient tolerated the procedure extremely well; he reported that, after his treatment on Fridays, he would return to work the following Monday, without sequelae. Although little benefit could be seen after the first and second treatments, the patient showed clear improvement after the third treatment. After 5 treatments, a remarkable degree of improvement was evident, especially in comparison to the untreated side (**Figure 2**). The patient has since undergone treatment to the right cheek, with comparable clearing of lesions.

COMMENT

Colloid milium is a rare cutaneous deposition disease that is characterized by the presence of multiple, dome-shaped, amber or flesh-colored papules ranging from 0.5 to 5.0 mm in diameter that develop on sun-exposed areas of the skin. These lesions clinically resemble vesicles and occur on areas such as the face, neck, ears, hands, and forearms of individuals with prolonged sun exposure and actinically damaged skin.[1] A mucoid or gelatinous substance can sometimes be expressed from these papules by applying pressure or puncture.[2] The lesions are often easily hemorrhagic with minor trauma.[3] Involved skin may be thickened, furrowed, and hyperpigmented.[2] The male-female ratio is 4:1.[4]

Colloid milium, which was first described in 1866, was thought to be a result of the degeneration of sebaceous glands.[2] Although multiple theories have been proposed regarding the pathogenesis of CM, the exact etiology of colloid deposition in the skin remains unclear. In 1925, Gans[5] postulated that CM was caused by the breakdown of collagen material. In 1943, Arnold[6] postulated that breakdown of elastin might also be involved. Prolonged, unprotected sun exposure is clearly involved in the pathogenesis of CM, but the mechanism through which this occurs is not understood. Sun expo-

©2007 American Medical Association. All rights reserved.
Downloaded From: http://jamanetwork.com/ on 06/20/2013

Figure 1. Appearance of the patient right (A) and left (B) sides of the patient's face before initiation of treatment.

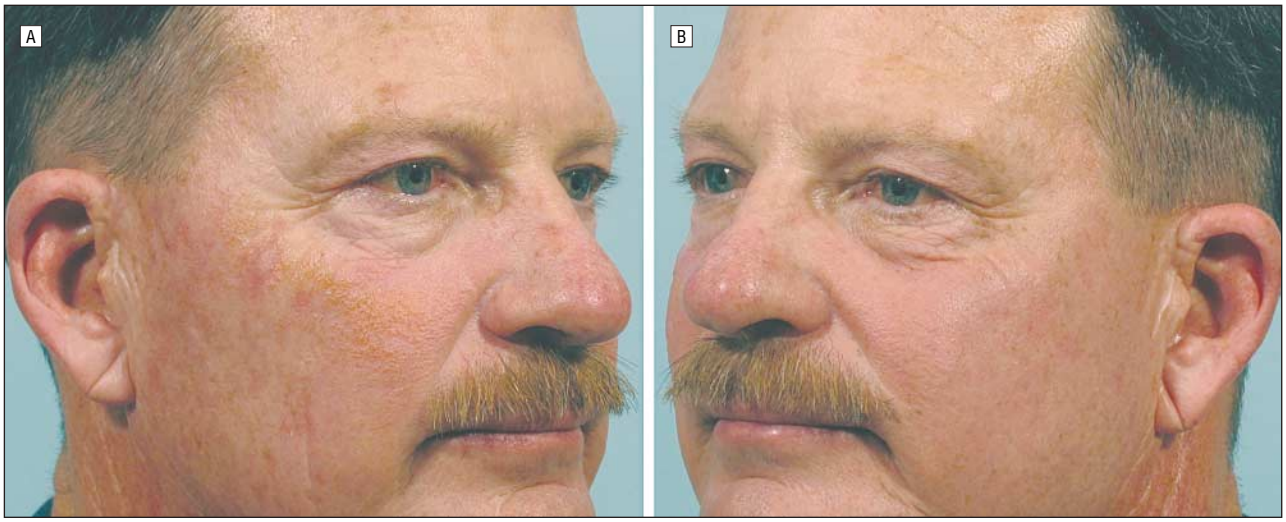

Figure 2. Appearance of the patient after 5 fractional resurfacing treatment sessions to the left cheek. A, The right hemiface received no treatment during this period. B, Note complete clearance of lesions on the patient's left side.

sure may damage the structure of elastin directly, affect the synthetic process of elastin in fibroblasts, or trigger the liberation of elastinolytic enzymes such as elastase and other proteases, leading to the destruction of these fibers.[7]

The effective treatment of CM is almost as elusive as its pathogenesis. Cryotherapy and chemical peels have been tried, with limited success. In 1978, Apfelberg et al[4] demonstrated the successful treatment of CM on the dorsum of the hands with dermabrasion. There was no clinical recurrence at the 12-month follow-up visit. Netscher et al[3] attempted to treat a 46-year-old man with CM of the hands and face with dermabrasion. The patient had previously undergone a 35% trichloroacetic acid peel, without success. The authors postulated that the specific histologic characteristics of CM accounted for the failure of chemical peels and explained the success with dermabrasion; ie, since the lesions of CM are mostly in the papillary dermis, they believed these to be too deep to be affected by chemical peeling agents.[3] Recently, Ammirati et al[8] reported the use of the erbium:YAG laser (9.8 J/cm2, 5-mm spot, and 10-msec pulse duration) in the treatment of CM. The patient experienced excellent improvement, but treatment required deep intravenous sedation, an involved postoperative care regimen, and a 2-week recovery period.

Fractional resurfacing is a new technology that relies on a 1550-nm diode-pumped erbium fiber laser delivered through an optically tracked microprocessor-controlled handpiece to produce an array of microscopic thermal zones. Each of these zones is extremely thin (approximately 100 µm in diameter) and 400 to 700 µm deep, producing a column of thermal damage that results in collagen denaturation. The technology relies on the premise that untreated areas surrounding each column of thermal damage provide a reservoir from which regeneration may take place.[9,10]

The pattern of microscopic thermal zones is independent of handpiece velocity and can be adjusted to deliver a density of 125 or 250 microscopic thermal zones per square centimeter. At these densities, and with the recommended number of individual passes, each treat-

©2007 American Medical Association. All rights reserved.
Downloaded From: http://jamanetwork.com/ on 06/20/2013

ment session covers approximately 20% of the targeted skin. A complete course of treatment therefore consists of 5 treatment sessions, spaced 2 to 4 weeks apart. The laser emission is absorbed primarily by water; because it contains little water, the stratum corneum of the epidermis is spared. Treatment can be performed with a topical anesthetic. Because of these properties, the recovery period is limited to 1 to 2 days of erythema likened to a mild sunburn and occasional edema; postoperative care requires only bland emollients and sun protection during that time; and, to our knowledge, serious adverse events, such as scarring, pigmentary changes, and infection, have not been reported.[9-11] This is in contrast to ablative modalities such as carbon dioxide and erbium-YAG laser resurfacing, which require recovery periods of 1 to 2 weeks as well as elaborate postoperative care regimens and can be accompanied by infection, scarring, prolonged erythema, and significant pigmentary changes. The technology can also be used in other anatomical sites that are not amenable to ablative resurfacing modalities, such as the hands and neck; therefore, it may provide a viable alternative for patients with CM at these sites, for whom treatment has previously not been available. The effectiveness of fractional photothermolysis in the treatment of CM may be a result of its depth of penetration, as histologic examination of treated skin has demonstrated treatment-associated effects into the reticular dermis.[10]

Despite the dramatic results seen in this case, final conclusions regarding the effectiveness of fractional resurfacing in the treatment of CM cannot be made, and additional studies are warranted. It would be valuable to investigate the use of the technology in patients with CM in other anatomical sites, such as the dorsal aspect of the hands, and to assess its responsiveness to treatment vis-à-vis facial CM. Longer follow-up and additional treatment courses should also be investigated.

Accepted for Publication: July 10, 2006.
Correspondence: Ronald L. Moy, MD, David Geffen School of Medicine, University of California, Los Angeles, 100 UCLA Medical Plaza, Suite 590, Los Angeles, CA 90024 (rmoy@ucla.edu).
Author Contributions: Dr Moy had full access to all the data in the study and takes responsibility for the integrity of the data and the accuracy of the data analysis. *Study concept and design:* Marra, Pourrabbani, and Moy. *Acquisition of data:* Marra and Moy. *Analysis and interpretation of data:* Marra, Fincher, and Moy. *Drafting of the manuscript:* Marra and Pourrabbani. *Critical revision of the manuscript for important intellectual content*: Marra, Fincher, and Moy. *Statistical analysis:* Marra. *Study supervision:* Fincher and Moy.
Financial Disclosure: None reported.

REFERENCES

1. Innocenzi D, Barduagni F, Cerio R, Wolter M. UV-induced colloid milium. *Clin Exp Dermatol*. 1993;18:347-350.
2. Graham JH, Marques AS. Colloid milium: a histochemical study. *J Invest Dermatol*. 1967;49:497-507.
3. Netscher DT, Sharma S, Kinner BM, Lyos A, Griego RD. Adult-type colloid milium of hands and face successfully treated with dermabrasion. *South Med J*. 1996; 89:1004-1007.
4. Apfelberg DB, Druker D, Spence B, Maser MR, Lash H. Treatment of colloid milium of the hand by dermabrasion. *J Hand Surg [Am]*. 1978;3:98-100.
5. Gans O. *Histologie der Hautkrankheiten*. Berlin, Germany: Julius Springer; 1925.
6. Arnold HL. Colloid pseudomilium. *Arch Dermatol*. 1943;48:262-269.
7. Kobayashi H, Hashimoto K. Colloid and elastic fibre: ultrastructural study on the histogenesis of colloid milium. *J Cutan Pathol*. 1983;10:111-122.
8. Ammirati CT, Giancola JM, Hruza GJ. Adult-onset facial colloid milium successfully treated with the long-pulsed Er:YAG laser. *Dermatol Surg*. 2002;28:215-219.
9. Geronemus RG. Fractional photothermolysis: current and future applications. *Lasers Surg Med*. 2006;38:169-176.
10. Manstein D, Herron GS, Sink RK, Tanner H, Anderson RR. Fractional photothermolysis: a new concept for cutaneous remodeling using microscopic patterns of thermal injury. *Lasers Surg Med*. 2004;34:426-438.
11. Fisher GH, Geronemus RG. Short-term side effects of fractional photothermolysis. *Dermatol Surg*. 2005;31:1245-1249.

Submissions

Clinicians, residents, and fellows are invited to submit cases of challenges in management and therapeutics to this section. Cases should follow the established pattern. Manuscripts should be prepared double-spaced with right margins nonjustified. Pages should be numbered consecutively with the title page separated from the text (see Instructions for Authors [http://archderm.ama-assn.org/misc/ifora.dtl] for information about preparation of the title page). Clinical photographs, photomicrographs, and illustrations must be sharply focused and submitted as separate JPG files with each file numbered with the figure number. Material must be accompanied by the required copyright transfer statement (see authorship form [http://archderm.ama-assn.org/misc/auinst_crit.pdf]). Preliminary inquiries regarding submissions for this feature may be submitted to George J. Hruza, MD (ghruza@aol.com). Manuscripts should be submitted via our online manuscript submission and review system (http://manuscripts.archdermatol.com).

©2007 American Medical Association. All rights reserved.
Downloaded From: http://jamanetwork.com/ on 06/20/2013