OBSERVATION

Failure of Extensive Extramammary Paget Disease of the Inguinal Area to Clear With Imiquimod Cream, 5%

Possible Progression to Invasive Disease During Therapy

Julie S. Green, MD, PhD; Nicole M. Burkemper, MD; Scott W. Fosko, MD

Background: Surgical approaches are the standard treatment for extramammary Paget disease (EMPD), but nonsurgical modalities may be preferred and more appropriate for some patients. Topical administration of imiquimod cream, 5%, has improved or resolved in situ EMPD (n=21), but treatment failures (n=6) have also been reported.

Observations: We treated an elderly patient with initial biopsy-proved in situ genital EMPD with daily topical imiquimod, 5%, for 14 weeks. Midtreatment mapping biopsy specimens demonstrated invasive disease, with minimal clinical improvement. The patient subsequently underwent surgical excision.

Conclusions: Of the 27 published cases that describe imiquimod treatment of EMPD, 6 report treatment failure (22%), but factors that may contribute to treatment failure are not well understood. In the present patient, treatment with imiquimod may have been complicated by variable lesion thickness, which inhibited uniform penetration of imiquimod, or the presence of invasive disease not detected on initial biopsy. The efficacy of imiquimod to treat extensive invasive EMPD has not been demonstrated, and surgical approaches remain the most appropriate treatment for invasive disease. Variable responses to topical imiquimod use among patients suggest that other factors may be important in determining response to therapy.

Arch Dermatol. 2011;147(6):704-708

Author Affiliations:
Departments of Dermatology (Dr Green), Dermatopathology (Dr Burkemper), Mohs Surgery and Cutaneous Oncology (Dr Fosko), Pathology (Dr Burkemper), Ophthalmology (Dr Fosko), Otolaryngology–Head and Neck Surgery (Dr Fosko), and Internal Medicine (Dr Fosko), Saint Louis University School of Medicine, and Saint Louis University Cancer Center (Dr Fosko), St Louis, Missouri.

SURGICAL MANAGEMENT OF EXtramammary Paget disease (EMPD) remains a therapeutic mainstay, but alternative treatments for primary limited cutaneous EMPD in the anogenital area that avoid cosmetic and functional defects after extensive tissue removal are under investigation. Local recurrence of EMPD can be significant,[1] highlighting the insidious nature of EMPD and the need to identify more effective treatments. The topical immunomodulator imiquimod, 5%, has been reported to induce clinical and histologic resolution of superficial EMPD,[2-12] but several cases of imiquimod failure have also been described.[13-17] Herein, we present a case of genital EMPD considered to be limited to in situ disease at the beginning of treatment with topical imiquimod that proved refractory, with demonstration of invasive disease during treatment. We also review the current literature (articles published in English and obtained through PubMed, Ovid, and GoogleScholar searches conducted between July 1, 2009, and August 31, 2010) regarding successes (n=21) and failures (n=6) of imiquimod therapy for EMPD and present characteristics that could portend treatment failure.

REPORT OF A CASE

An 82-year-old man presented with a 1-year history of a pruritic lesion in the left inguinal area. Physical examination revealed a 9×5-cm velvety pink patch with a central, slightly elevated, verrucous plaque involving the suprapubic area, scrotum, and base of the penis (**Figure 1**A). Invasive disease was clinically suspected given the central plaque. Six 3-mm mapping punch biopsy specimens were collected peripherally and centrally and demonstrated only in situ EMPD (Figure 1B and C). Findings from lymph node and full-body skin examination, colonoscopy, and cystoscopy were unremarkable. After a urology consultation and discussion of treatment options, the patient chose a nonsurgical approach and applied imiquimod cream, 5%, to the lesion once daily for 14 weeks for a total of 98 applications. During treatment, tolerable mild lesional tenderness and erythema developed. Eleven weeks after the start of treatment, clinical improvement was limited to

©2011 American Medical Association. All rights reserved.
Downloaded From: http://jamanetwork.com/ on 05/23/2013

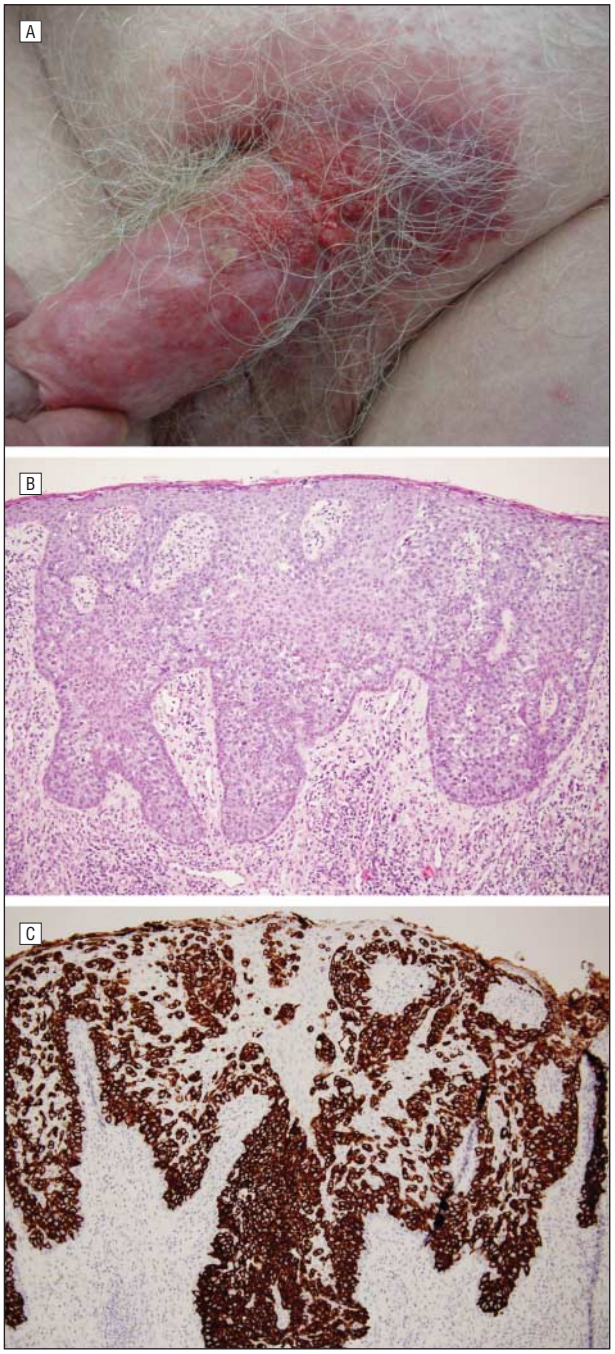

Figure 1. A, Clinical appearance of the lesion before imiquimod cream, 5%, treatment. B, Histopathologic appearance of the lesion before treatment demonstrating in situ extramammary Paget disease (EMPD) (hematoxylin-eosin, original magnification ×10). C, Histopathologic appearance of the lesion before treatment demonstrating in situ EMPD (cytokeratin 7, original magnification ×10).

the periphery of the lesion (**Figure 2**A). Four 3-mm mapping punch biopsy specimens detected residual in situ EMPD peripherally but an invasive component at the center of the lesion. The patient then underwent excision of the lesion. Histopathologic analysis revealed invasive EMPD to a depth of 7.5 mm (Figure 2B). Peripheral margins were free of tumor; however, 1 tumor nest was identified 0.2 mm from the deep margin. The patient elected close observation.

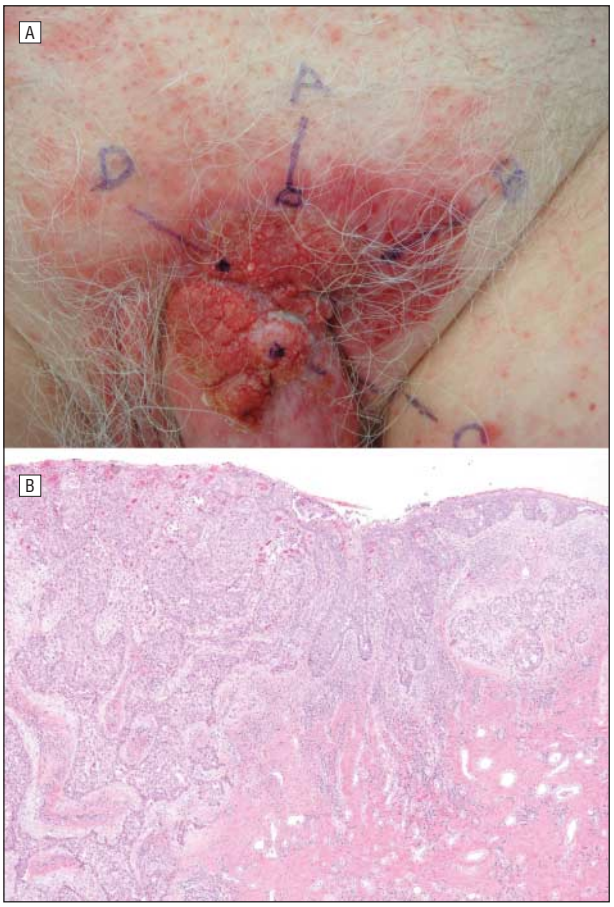

Figure 2. A, Clinical appearance of the lesion after 11 weeks of daily imiquimod cream, 5%, application. B, Histopathologic appearance of the surgical excision demonstrating dermal invasion (hematoxylin-eosin, original magnification ×20).

COMMENT

Extramammary Paget disease is a relatively rare neoplasm classically involving skin-bearing apocrine glands in locations other than the nipple or areola of the breast.[18,19] For unclear reasons, EMPD can be associated with underlying adnexal adenocarcinoma or other internal malignant neoplasms.[18] Most commonly, EMPD involves vulvar skin in women, but it may present in the inguinal, scrotal, and penile areas in men and in the perineal and perianal regions in both sexes.[18,19] Clinically, EMPD has an insidious onset, with patients reporting symptoms of itching, burning, and pain in affected areas even before visible lesions appear.[19] Lesions of EMPD are described as erythematous or white, well-demarcated plaques with variable amounts of crust, ulceration, and scale.[19] Histopathologic analysis reveals large round cells with abundant pale cytoplasm at all levels of the epithelium.[18-20] Generally, patients with in situ EMPD have a good prognosis,[20] but the presence of dermal invasion or metastasis seems to significantly increase morbidity and mortality.[21] Similarly, EMPD associated with an underlying visceral malignancy carries a worse prognosis.[19,22]

Historically, EMPD has been treated with wide surgical excision despite high recurrence rates (31%-61%).[1] More recently, EMPD has been treated with Mohs micro-

©2011 American Medical Association. All rights reserved.
Downloaded From: http://jamanetwork.com/ on 05/23/2013

Table 1. Summary of Articles in the Literature Documenting Successful Treatment of EMPD With Imiquimod

Source	Type of Article	Location	Primary vs Recurrent EMPD	Previous Treatment	Pretreatment Histologic Findings	Treatment Regimen (Imiquimod Concentration, Application Frequency, Length of Treatment)	Histologic Assessment After Imiquimod Treatment	Follow-up (Clinically Negative), mo
Zampogna et al,[5] 2002	Case series (n=2)	1: Scrotum 2: Perineum	1: Recurrent 2: Primary	1: ED&C 2: None	1: In situ 2: In situ	1: 5% Daily for 6 d; qod for 16 wk 2: 5% qod for 7.5 wk	1: "Posttreatment bx" negative 2: Negative at 4 mo	12
Qian et al,[41] 2003	Case report (n=1)	Scrotum	Recurrent	MMS and photodynamic therapy	In situ	5% 3 Times/wk for 6 wk	Negative immediately after tx	14
Wang et al,[8] 2003	Case report (n=1)	Vulva	Recurrent	Excision	In situ	5% Daily for 6 d; qod for 5 wk	Negative at 12 mo	12
Berman et al,[10] 2003	Case report (n=1)	Groin/ scrotum	Recurrent	MMS	Dermal microinvasion	5% Daily for 6 wk	Negative at 4 and 6 mo	6
Hieken and Lasser,[9] 2005	Abstract (n=1)	Groin/ perineum	Primary	None	In situ	5% Daily for 10 wk; 10-d break mid-tx	"Multiple negative repeat bx"	[a]
Badgwell and Rosen,[43] 2006	Case report (n=1)	Thigh	Primary	None	In situ	5% 3 Times/wk for 16 wk	Negative at 6 mo	15
Cohen et al,[3] 2006	Case report (n=1)	Groin	Primary	None	In situ	5% qod for 16 wk	Negative immediately after tx	9
Mirer et al,[2] 2006	Case series (n=1)	Intergluteal cleft	Primary	None	In situ	5% 5 d/wk for 4 wk; qod for 4 wk; 2 applications/wk for 8 wk	Negative at 6 and 12 mo	6 and 12
Vereecken et al,[42] 2007	Case report (n=1)	Perianal	Residual	Excision	In situ	5% Daily for 12 wk	Negative immediately after tx cessation	12
Geisler and Manahan,[7] 2008	Case report (n=1)	Vulva	Recurrent	Excision	? In situ	5% 2 Times/wk for 16 wk	Negative at 1 mo	12
Hatch and Davis,[6] 2008	Case series (n=2)	1: Vulva/ perineum 2: Vulva	1: Recurrent 2: Recurrent	1: Excision 2: Radical vulvectomy	1: In situ 2: In situ	1: qod for 8.5 wk; 2-wk break; daily for 10 d; qod for 11 wk[a] 2: "2 Packets" daily for 2 wk; "1 packet" daily for 5 wk; qod for 7 wk[a]	1: Negative at 4 mo 2: Negative at 4 mo	1: 4 2: 4
Challenor et al,[12] 2009	Case series (n=2)	1: Vulva 2: Vulva	1: Primary 2: Primary	None	1: In situ 2: In situ	1: Partial vulvectomy, then 5% 3 times/wk for 12 wk 2: Partial vulvectomy, then 5% 3 times/wk for 12 wk	1: Not performed 2: Not performed	1: 4 2: 3
Sendagorta et al,[4] 2010	Case series (n=3)	1: Vulva 2: Vulva 3: Vulva	1: Primary 2: Primary 3: Primary	None	1: In situ 2: In situ 3: In situ	1: 5% Daily for 3 wk; qod for 3 wk 2: 5% Daily for 3 wk; qod for 2 wk 3: 5% Daily for 3 wk; qod for 2 wk	1: Negative at 6 and 12 mo 2: Negative at 2, 6, and 12 mo 3: Negative at 2 and 6 mo	1: 12 2: 22 3: 20
Cecchi et al,[11] 2010	Case report (n=1)	Perineum	Primary	None	In situ	5% 3 Times/wk for 16 wk	Negative at 4 mo	12
Ho and Aw,[40] 2010	Case series (n=2)	1: Genital 2: Vulva	1: Primary 2: Primary	None	"EMPD"; no comment about depth of invasion	1: 5% 3 Times/wk for 4 wk; daily for 12 wk 2: 5% 3 Times/wk for 18 wk	1: Negative immediately after tx cessation 2: Not performed	1: 12 2: None

Abbreviations: bx, biopsy; ED&C, electrodessication and curettage; EMPD, extramammary Paget disease; MMS, Mohs micrographic surgery; qod, every other day; tx, treatment.

[a] Additional data about treatment were not included in original reports.

graphic surgery, the often preferred modality given its lower recurrence rate (23%) compared with standard excision.[1] Nonsurgical modalities used alone or in conjunction with surgical excision may be more appropriate for some patients. In the past, such treatment modalities have included irradiation,[23-25] topical chemotherapy with fluorouracil[26,27] or bleomycin,[28] various systemic chemotherapeutic regimens,[29-32] laser ablation,[33-36] and photodynamic therapy,[37-39] with varying efficacy. Recently, topical imiquimod, 5%, has emerged as a potential treatment for superficial EMPD. Treatment of EMPD of the vulva,[4,6-8,12,40] groin and scrotum,[3,5,9,10,40,41] perineum,[2,5,11,42] thigh,[43] and bilateral chest[17] with topical imiquimod, 5%, has been reported in 27 patients, with treatment success documented in 21 patients (78%).

Of the 21 patients with treatment success, 13 had primary EMPD,[2-5,9,11,12,40,43] 7 had recurrent EMPD,[5-8,10,41] and 1 had residual EMPD (**Table 1**).[42] Imiquimod cream, 5%, was applied with a frequency ranging from twice weekly for 16 weeks[7] to daily for 12 weeks.[42] Recurrent and residual cases of EMPD had been treated previously with surgical excision and vulvectomy,[6-8,42] Mohs micrographic surgery,[10,41] electrodessication and curettage,[5] or photodynamic therapy.[41] Of the 21

©2011 American Medical Association. All rights reserved.
Downloaded From: http://jamanetwork.com/ on 05/23/2013

Table 2. Summary of Articles in the Literature Documenting Failure of Imiquimod Treatment in EMPD

Source	Type of Article	Location	Primary vs Recurrent EMPD	Previous Treatment	Pretreatment Histologic Findings	Treatment Regimen (Imiquimod Concentration, Application Frequency, Length of Treatment)	Histologic Assessment After Imiquimod Treatment	Follow-up (Clinically Negative)
Bamford and Seidelmann,[15] 2001	Abstract (n=1)	Groin/ scrotum	Primary	None	In situ	1% for 12 wk[a]	Residual EMPD	[a]
Urosevic and Dummer,[16] 2004	Unpublished observation in review article	Genital	[a]	None	[a]	4 wk[a]	"Partial response"	[a]
Ye et al,[13] 2006	Case report (n=1)	Scrotum	Recurrent	Excision	In situ	5% Daily for 6 wk; qod for 4 wk	Residual in situ EMPD	[a]
Yeh and Hu,[17] 2007	Case report (n=1)	Bilateral chest	Primary	None	In situ	5% qod for 24 wk; every 3 d for 12 wk	Not performed	Clinical recurrence 11 wk after tx
Gass et al,[14] 2008	Abstract (n=2)	Vulva	[b]	None	[a]	3 Times/wk for 16 wk[a]	Residual EMPD	[a]

Abbreviations: EMPD, extramammary Paget disease; qod, every other day; tx, treatment.
[a] Additional data about treatment were not included in the original articles.
[b] The report did not indicate whether the lesion was primary or recurrent.

reported cases of treatment success, 18 were characterized as in situ EMPD on pretreatment biopsy, 1 contained dermal microinvasion, and 2 were not clarified.[10,40] Posttreatment biopsy specimens were negative for EMPD in 18 patients and were not obtained in 3 patients.[12,40] Follow-up was a relatively brief 10.8 months for the 18 patients for whom such details were provided (Table 1). In 5 of these patients, follow-up was 6 months or less, and in 4 patients, follow-up was recorded for 4 months or less.

To date, there are 6 cases (6 of 27 [22% of cases reported]) of topical imiquimod failure in the treatment of EMPD in the literature (**Table 2**).[13-17] Among these, 3 cases of in situ EMPD were noted on pretreatment biopsy,[13,15,17] but pretreatment biopsy findings were not reported for the remaining 3 cases (Table 2). One case was documented to be recurrent in situ EMPD,[13] for which the patient had previously undergone surgical excision. The treatment regimen in these patients ranged from application of imiquimod cream, 1%, daily for 12 weeks[15] to application of 5% cream every other day for 24 weeks and then every 3 days for 12 additional weeks.[17] Posttreatment biopsy specimens revealed residual EMPD in all 5 patients for which such information was provided (Table 2). Length of follow-up was noted only for 1 case, in which recurrence was noted clinically 11 weeks after the cessation of treatment, with no posttreatment biopsies performed.[17]

Herein, we report apparent resistance to imiquimod therapy in an elderly patient with genital EMPD with either missed invasive disease at initial presentation or progression from in situ to invasive disease during treatment. In this case, only in situ EMPD was initially detected on mapping biopsies, including biopsies of the thicker and more hyperkeratotic portion of the lesion. Given these pathology results, our impression was that the biopsy specimens of the thick central portion of the lesion represented pronounced in situ disease. Therefore, we proceeded with imiquimod therapy. Several important points should be considered. Mapping biopsy specimens are typically collected from multiple representative areas of a lesion in an attempt to predict the general histopathologic condition of the lesion as a whole, but they do not allow the pathologist to examine the entire lesion. They are merely a "sampling" of a lesion's histopathologic appearance. Therefore, in the present patient, invasive disease may have been missed from the outset by the initial mapping biopsy specimens. The efficacy of topical imiquimod use in extensive invasive EMPD has not been documented,[5] and surgical excision in these cases may be more appropriate. Another point to consider is that therapeutic responses may be related to the depth of penetration of imiquimod such that thicker portions of an in situ lesion or tumor with extensive adnexal involvement or invasive disease may exhibit incomplete responses. In addition, variable responses to imiquimod in patients with presumed in situ EMPD suggests that additional, as yet unknown, factors may be important in predicting response to treatment. Furthermore, although topical imiquimod application may be effective in cases of in situ EMPD, refractory cases of presumed in situ EMPD may require further evaluation for an invasive component or other contributing factors.

Accepted for Publication: November 24, 2010.
Correspondence: Julie S. Green, MD, PhD, Department of Dermatology, Saint Louis University School of Medicine, 1402 S Grand Blvd, St Louis, MO 63104 (schwarj2@gmail.com).
Author Contributions: Drs Green and Fosko had full access to all the data in the study and take responsibility for the integrity of the data and the accuracy of the data analysis. *Study concept and design:* Green and Fosko. *Acquisition of data:* Green, Burkemper, and Fosko. *Analysis and interpretation of data:* Green, Burkemper, and Fosko. *Drafting of the manuscript:* Green and Fosko. *Critical revision of the manuscript for important intellectual content:* Burkemper and Fosko. *Administrative, technical, and*

©2011 American Medical Association. All rights reserved.
Downloaded From: http://jamanetwork.com/ on 05/23/2013

material support: Burkemper and Fosko. *Study supervision:* Burkemper and Fosko.
Financial Disclosure: None reported.
Additional Contributions: Christine Nelsen, MD, Department of Dermatopathology, Saint Louis University School of Medicine, collected the photomicrographs; Mark Doig, PA-C, Department of Mohs Surgery and Cutaneous Oncology, Saint Louis University School of Medicine, and James Cummings, MD, formerly of the Department of Surgery, Urology Division, Saint Louis University and currently with the Department of Surgery, Urologic Surgery Division, University of Missouri–Columbia, assisted with patient care; and Steven Palmer, MD, private practice, St Louis, referred the patient.

REFERENCES

1. Coldiron BM, Goldsmith BA, Robinson JK. Surgical treatment of extramammary Paget's disease: a report of six cases and a reexamination of Mohs micrographic surgery compared with conventional surgical excision. *Cancer*. 1991; 67(4):933-938.
2. Mirer E, El Sayed F, Ammoury A, Lamant L, Messer L, Bazex J. Treatment of mammary and extramammary Paget's skin disease with topical imiquimod. *J Dermatolog Treat*. 2006;17(3):167-171.
3. Cohen PR, Schulze KE, Tschen JA, Hetherington GW, Nelson BR. Treatment of extramammary Paget disease with topical imiquimod cream: case report and literature review. *South Med J*. 2006;99(4):396-402.
4. Sendagorta E, Herranz P, Feito M, et al. Successful treatment of three cases of primary extramammary Paget's disease of the vulva with Imiquimod: proposal of a therapeutic schedule. *J Eur Acad Dermatol Venereol*. 2010;24(4):490-492.
5. Zampogna JC, Flowers FP, Roth WI, Hassenein AM. Treatment of primary limited cutaneous extramammary Paget's disease with topical imiquimod monotherapy: two case reports. *J Am Acad Dermatol*. 2002;47(4)(suppl):S229-S235.
6. Hatch KD, Davis JR. Complete resolution of Paget disease of the vulva with imiquimod cream. *J Low Genit Tract Dis*. 2008;12(2):90-94.
7. Geisler JP, Manahan KJ. Imiquimod in vulvar Paget's disease: a case report. *J Reprod Med*. 2008;53(10):811-812.
8. Wang LC, Blanchard A, Judge DE, Lorincz AA, Medenica MM, Busbey S. Successful treatment of recurrent extramammary Paget's disease of the vulva with topical imiquimod 5% cream. *J Am Acad Dermatol*. 2003;49(4):769-772.
9. Hieken T, Lasser A. Successful nonoperative treatment of extensive extramammary Paget's disease. *J Clin Oncol*. 2005;23(16S):2584.
10. Berman B, Spencer J, Villa A, Poochareon V, Elgart G. Successful treatment of extramammary Paget's disease of the scrotum with imiquimod 5% cream. *Clin Exp Dermatol*. 2003;28(suppl 1):36-38.
11. Cecchi R, Pavesi M, Bartoli L, Brunetti L, Rapicano V. Perineal extramammary Paget disease responsive to topical imiquimod. *J Dtsch Dermatol Ges*. 2010; 8(1):38-40.
12. Challenor R, Hughes G, Fitton AR. Multidisciplinary treatment of vulval extramammary Paget's disease to maintain sexual function: an imiquimod success story. *J Obstet Gynaecol*. 2009;29(3):252-254.
13. Ye JN, Rhew DC, Yip F, Edelstein L. Extramammary Paget's disease resistant to surgery and imiquimod monotherapy but responsive to imiquimod combination topical chemotherapy with 5-fluorouracil and retinoic acid: a case report. *Cutis*. 2006;77(4):245-250.
14. Gass J, Rytina E, Sterling J, Todd P. Unsuccessful treatment of extramammary Paget's disease with topical imiquimod [abstract]. *Br J Dermatol*. 2008;159 (suppl 1):64. doi:10.1111/j.1365-2133.2008.08538.x.
15. Bamford J, Seidelmann S. Clinical and immunologic response of extramammary Paget's disease to imiquimod [abstract]. *J Invest Dermatol*. 2001;117 (2):537. doi:10.1046/j.1523-1747.2001.14325.x.
16. Urosevic M, Dummer R. Role of imiquimod in skin cancer treatment. *Am J Clin Dermatol*. 2004;5(6):453-458.
17. Yeh MH, Hu SL. Treatment of double ectopic extramammary Paget's disease of bilateral chest with imiquimod 5% cream. *J Eur Acad Dermatol Venereol*. 2007; 21(7):997-999.
18. Shepherd V, Davidson EJ, Davies-Humphreys J. Extramammary Paget's disease. *BJOG*. 2005;112(3):273-279.
19. Kanitakis J. Mammary and extramammary Paget's disease. *J Eur Acad Dermatol Venereol*. 2007;21(5):581-590.
20. Shaco-Levy R, Bean SM, Vollmer RT, et al. Paget disease of the vulva: a histologic study of 56 cases correlating pathologic features and disease course. *Int J Gynecol Pathol*. 2010;29(1):69-78.
21. Hatta N, Yamada M, Hirano T, Fujimoto A, Morita R. Extramammary Paget's disease: treatment, prognostic factors and outcome in 76 patients. *Br J Dermatol*. 2008;158(2):313-318.
22. Chanda JJ. Extramammary Paget's disease: prognosis and relationship to internal malignancy. *J Am Acad Dermatol*. 1985;13(6):1009-1014.
23. Moreno-Arias GA, Conill C, Sola-Casas MA, Mascaro-Galy JM, Grimalt R. Radiotherapy for in situ extramammary Paget disease of the vulva. *J Dermatolog Treat*. 2003;14(2):119-123.
24. Moreno-Arias GA, Conill C, Castells-Mas A, Arenas M, Grimalt R. Radiotherapy for genital extramammary Paget's disease in situ. *Dermatol Surg*. 2001;27 (6):587-590.
25. Besa P, Rich TA, Delclos L, Edwards CL, Ota DM, Wharton JT. Extramammary Paget's disease of the perineal skin: role of radiotherapy. *Int J Radiat Oncol Biol Phys*. 1992;24(1):73-78.
26. Bewley AP, Bracka A, Staughton RC, Bunker CB. Extramammary Paget's disease of the scrotum: treatment with topical 5-fluorouracil and plastic surgery. *Br J Dermatol*. 1994;131(3):445-446.
27. Del Castillo LF, Garcia C, Schoendorff C, Garcia JF, Torres LM, Garcia Almagro D. Spontaneous apparent clinical resolution with histologic persistence of a case of extramammary Paget's disease: response to topical 5-fluorouracil. *Cutis*. 2000; 65(5):331-333.
28. Watring WG, Roberts JA, Lagasse LD, et al. Treatment of recurrent Paget's disease of the vulva with topical bleomycin. *Cancer*. 1978;41(1):10-11.
29. Thirlby RC, Hammer CJ Jr, Galagan KA, Travaglini JJ, Picozzi VJ Jr. Perianal Paget's disease: successful treatment with combined chemoradiotherapy: report of a case. *Dis Colon Rectum*. 1990;33(2):150-152.
30. Kariya K, Tsuji T, Schwartz RA. Trial of low-dose 5-fluorouracil/cisplatin therapy for advanced extramammary Paget's disease. *Dermatol Surg*. 2004;30(2, pt 2): 341-344.
31. Watanabe Y, Hoshiai H, Ueda H, Nakai H, Obata K, Noda K. Low-dose mitomycin C, etoposide, and cisplatin for invasive vulvar Paget's disease. *Int J Gynecol Cancer*. 2002;12(3):304-307.
32. Yamazaki N, Yamamoto A, Wada T, Ishikawa M, Moriya Y, Nakanishi Y. A case of metastatic extramammary Paget's disease that responded to combination chemotherapy. *J Dermatol*. 1999;26(5):311-316.
33. Becker-Wegerich PM, Fritsch C, Schulte KW, et al. Carbon dioxide laser treatment of extramammary Paget's disease guided by photodynamic diagnosis. *Br J Dermatol*. 1998;138(1):169-172.
34. Lai YL, Yang WG, Tsay PK, Swei H, Chuang SS, Wen CJ. Penoscrotal extramammary Paget's disease: a review of 33 cases in a 20-year experience. *Plast Reconstr Surg*. 2003;112(4):1017-1023.
35. Louis-Sylvestre C, Haddad B, Paniel BJ. Paget's disease of the vulva: results of different conservative treatments. *Eur J Obstet Gynecol Reprod Biol*. 2001; 99(2):253-255.
36. Valentine BH, Arena B, Green E. Laser ablation of recurrent Paget's disease of vulva and perineum. *J Gynecol Surg*. 1992;8(1):21-24.
37. Zollo JD, Zeitouni NC. The Roswell Park Cancer Institute experience with extramammary Paget's disease. *Br J Dermatol*. 2000;142(1):59-65.
38. Raspagliesi F, Fontanelli R, Rossi G, et al. Photodynamic therapy using a methyl ester of 5-aminolevulinic acid in recurrent Paget's disease of the vulva: a pilot study. *Gynecol Oncol*. 2006;103(2):581-586.
39. Shieh S, Dee AS, Cheney RT, Frawley NP, Zeitouni NC, Oseroff AR. Photodynamic therapy for the treatment of extramammary Paget's disease. *Br J Dermatol*. 2002;146(6):1000-1005.
40. Ho S-AJE, Aw DC. Extramammary Paget's disease treated with topical imiquimod 5% cream. *Dermatol Ther*. 2010;23(4):423-427.
41. Qian Z, Zeitoun NC, Shieh S, Helm T, Oseroff AR. Successful treatment of extramammary Paget's disease with imiquimod. *J Drugs Dermatol*. 2003;2(1): 73-76.
42. Vereecken P, Awada A, Ghanem G, et al. A therapeutic approach to perianal extramammary Paget's disease: topical imiquimod can be useful to prevent or defer surgery. *Med Sci Monit*. 2007;13(6):CS75-CS77.
43. Badgwell C, Rosen T. Treatment of limited extent extramammary Paget's disease with 5 percent imiquimod cream. *Dermatol Online J*. 2006;12(1):22.

©2011 American Medical Association. All rights reserved.
Downloaded From: http://jamanetwork.com/ on 05/23/2013