

SECTION EDITOR: BEVERLY P. WOOD, MD

## Radiological Case of the Month

Michael Yuri Torchinsky, MD; Hannah Shulman, MD; Daniel Landau, MD

**A** 9-WEEK-OLD girl was seen for a 12-day history of fever (38.5°C), vomiting, and refusal to move the left arm for 24 hours prior to admission. There was no history of trauma. She was born at 36 weeks' gestation by cesarean delivery because of fetal distress. On physi-

From the Department of Pediatrics B and Department of Radiology, Soroka Medical Center, Ben Gurion University of the Negev, Beer Sheva, Israel.

cal examination she was irritable, pale, and did not move her left arm in response to painful stimuli; she cried when it was manipulated at the shoulder. Movement of the right arm and both legs were normal. Laboratory findings included white blood cell count,  $14.8 \times 10^9/L$ , with differential showing myelocytes,  $0.15 \times 10^9/L$ ; bands,  $0.59 \times 10^9/L$ ; segmented neutrophils,  $4.88 \times 10^9/L$ ; and lymphocytes,  $8.14 \times 10^9/L$ . Hematocrit was 0.23; reticulocyte count, 0.15; platelet count,  $293 \times 10^9/L$ ; and erythrocyte sedimentation rate, 110 mm/h. Findings from serum chemistry, glucose-6-phosphate dehydrogenase activity, Coomb test, and blood cultures were normal. Radiographs of the shoulders and humeri were unremarkable. A 3-phase technetium 99m methylene diphosphonate bone scan was performed on the first and fifth hospital days with normal results. Axial computed tomography of the humeri (Figure 1) and additional long bone radiographs (Figure 2 and Figure 3) were obtained.

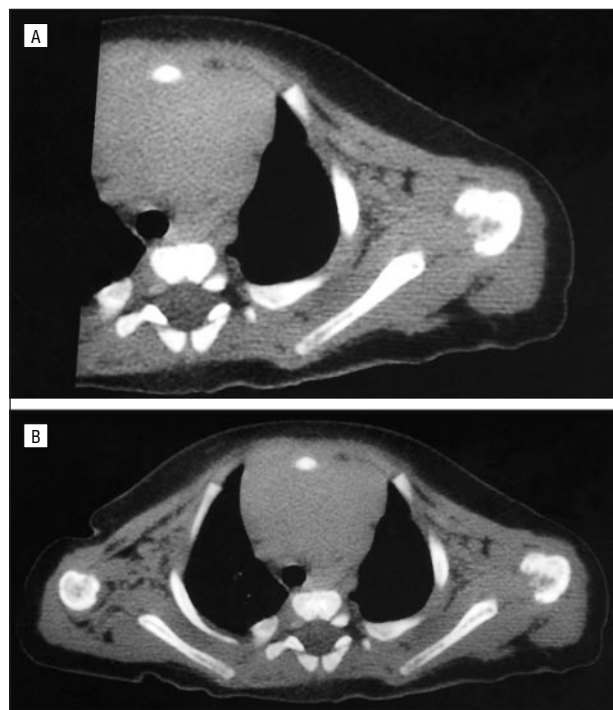


Figure 1.

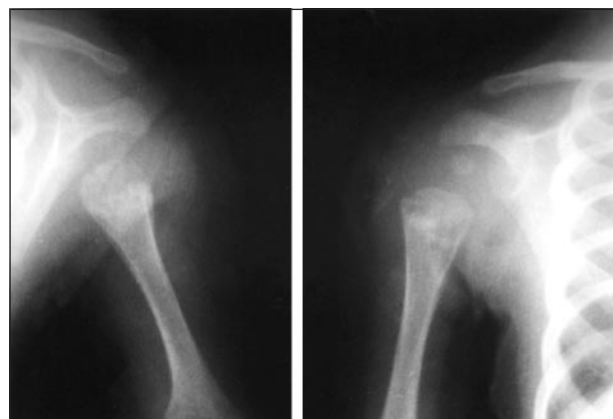


Figure 2.

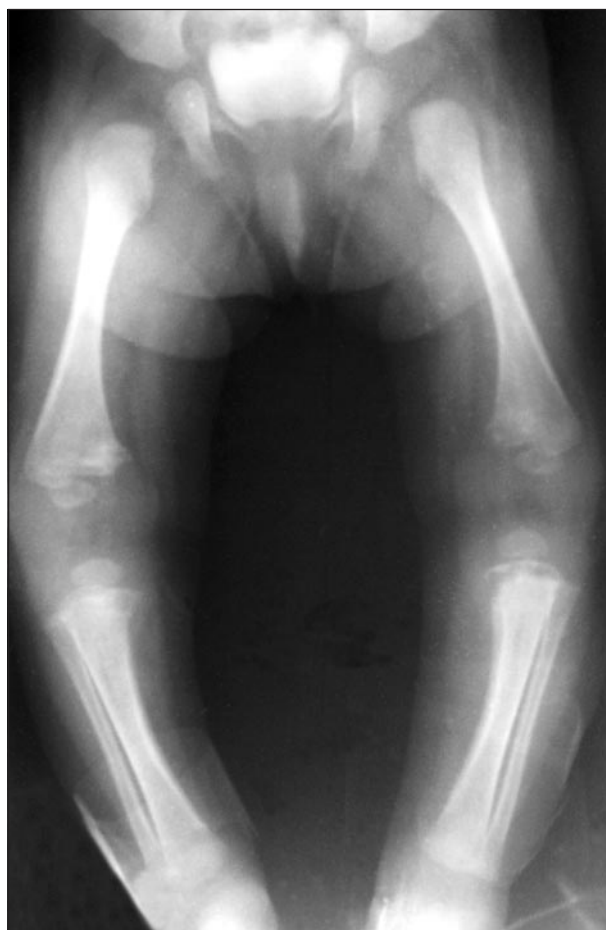


Figure 3.

# Denouement and Discussion

## Congenital Syphilis Presenting as Osteomyelitis With Normal Radioisotope Bone Scan

**Figure 1.** Axial computed tomogram of the left humerus, performed on the 10th hospital day, shows extensive areas of osteolysis and cortical destruction of the proximal metaphysis. There is soft tissue swelling.

**Figure 2.** Frontal radiographs of the shoulders on the 10th hospital day show osteolytic metaphyseal lesions of both proximal humeri.

**Figure 3.** Radiographs of the long bones of the lower extremities (10th hospital day) show bilaterally symmetrical diaphyseal periostitis and metaphysitis of both distal femora and proximal tibiae, a pathognomonic sign of congenital syphilis.

On the second hospital day, the infant's serum VDRL test was 1:16. It rose 16-fold and reached a dilution level of 1:256 by the 10th hospital day. This result was 4 times higher than her mother's serum VDRL test result (1:64). Findings from a serum microagglutination test for cerebrospinal fluid were normal, as were results of a cerebrospinal fluid VDRL test. The diagnosis of congenital syphilis was established. The infant was treated with intravenous cefuroxime sodium, 150 mg/kg daily, because hematogenous osteomyelitis was initially suspected. After the positive serum VDRL test result was reported, cefuroxime was replaced by intravenous aqueous crystalline penicillin G, 300 000  $\mu\text{m}/\text{kg}$  daily, which was given for 14 days. The infant recovered completely.

The incidence of early congenital syphilis remains relatively high.<sup>1,2</sup> Early diagnosis and timely treatment are important to prevent serious complications. Congenital syphilis usually manifests during the first 3 months after birth with signs of fever, prolonged rhinitis, erythematous maculopapular rash of the palms and soles, hepatosplenomegaly, pseudoparalysis, Coombs-negative hemolytic anemia, leukocytosis, and monocytosis.<sup>3-5</sup> The definitive diagnosis is based on the results of a serum quantitative nontreponemal test (VDRL or rapid plasma reagin) considered conclusive when the infant's titer is at least 4 times higher than that of the mother. The infant's antitreponemal immunoglobulin antibody test is also used for diagnosis.<sup>1</sup> Bone involvement with bilaterally symmetrical periostitis and metaphysitis occurs in 95% of symptomatic infants.<sup>6,7</sup> Asymmetric focal osteolytic metaphyseal lesions with sequestra or pathological fractures are also reported.<sup>8</sup>

To our knowledge, this is the first reported demonstration of diagnostic computed tomography of the skeletal lesions of early congenital syphilis. Computed tomography shows osteolysis and cortical destruction of the proximal left humerus and soft tissue swelling. These changes account for acute pain, which leads to pseudoparalysis in congenital syphilis.

Despite the clinical, laboratory, and later imaging signs, the 3-phase technetium 99m methylene diphos-

phonate bone scan in this patient repeatedly had negative findings. Increased accumulation radioactive tracer at the site of inflammation is characteristic of osteomyelitis.<sup>9</sup> Lim et al<sup>10</sup> reported a false-negative result from bone scan in a case of pseudoparalysis from congenital syphilis. The occurrence reflects the specific character of metaphyseal pathology. Histopathological analysis of the metaphysis in syphilis reveals an obliterative endarteritis secondary to binding of spirochetes to endothelial cells with inflammatory plasma cell-rich perivascular infiltration.<sup>11-13</sup> Spirochetes are identified in bone tissue by specific Dieterle stains.<sup>1,14</sup> Obliterative vasculitis leads to decreased blood flow, atrophy, focal necrosis, and diffuse interstitial fibrosis.<sup>12,13,15</sup> These changes may explain why the radioactive tracer does not accumulate at the site of syphilitic osseous lesions.

Accepted for publication June 27, 1999.

Reprints: Daniel Landau, MD, Department of Pediatrics B, Soroka Medical Center, PO Box 151, Beer Sheva 84101, Israel.

### REFERENCES

1. American Academy of Pediatrics. Syphilis. In: Peter G, Hall CB, Halsey NA, Marcy SM, Pickering LK, eds. *1997 Red Book: Report of the Committee on Infectious Diseases*. 24th ed. Elk Grove Village, Ill: American Academy of Pediatrics; 1997: 504-514.
2. Koshier MS, Caniza M. Parrot pseudoparalysis of the upper extremities. *J Bone Joint Surg Am*. 1996;78:284-287.
3. Rasool MN, Govender S. The skeletal manifestations of congenital syphilis: a review of 197 cases. *J Bone Joint Surg Br*. 1989;71:752-755.
4. Sachdev M, Bery K, Chawla S. Osseous manifestations in congenital syphilis: a study of 55 cases. *Clin Radiol*. 1982;33:319-323.
5. Dorfman DH, Glaser JH. Congenital syphilis presenting in infants after the newborn period. *N Engl J Med*. 1990;323:1299-1302.
6. Giacola GP, Wood BP. Congenital syphilis. *AJDC*. 1991;145:1045-1046.
7. Brion LP, Manuli MD, Rai B, Kresh MJ, Pavlov H, Glaser J. Long-bone radiographic abnormalities as a sign of active congenital syphilis in asymptomatic newborns. *Pediatrics*. 1991;88:1037-1040.
8. Solomon A, Rosen E. Focal osseous lesions in congenital lues. *Pediatr Radiol*. 1978;7:36-39.
9. Mandell GA. Imaging in the diagnosis of musculoskeletal infections in children. *Curr Prob Pediatr*. 1996;26:218-237.
10. Lim HK, Smith WL, Sato Y, Choi J. Congenital syphilis mimicking child abuse. *Pediatr Radiol*. 1995;25:560-561.
11. Samuelson J, Van Lichtenberg F. Syphilis. In: Cotran RS, Kumar V, Robbins SL, Schoen FJ, eds. *Robbins Pathologic Basis of Disease*. 5th ed. WB Saunders Co; 1994:343-346.
12. O'Shea. Congenital syphilis in a twin gestation. *Pediatr Pathol*. 1992;12:865-870.
13. Froberg MK, Fitzgerald TJ, Hamilton TR, Hamilton B, Zarabi M. Pathology of congenital syphilis in rabbits. *Infect Immun*. 1993;61:4743-4749.
14. Dzebolu NN. Congenital syphilis: an unusual presentation. *Radiology*. 1980;136: 372.
15. Levine Z, Sherer DM, Jacobs A, Rotenberg O. Nonimmune hydrops fetalis due to congenital syphilis associated with negative intrapartum maternal serology screening. *Am J Perinatol*. 1998;15:233-236.