

# Endoscopic Ultrasound Added to Mediastinoscopy for Preoperative Staging of Patients With Lung Cancer

Jouke T. Annema, MD, PhD

Michel I. Versteegh, MD

Maud Veselić, MD

Lutz Welker, MD

Thais Mauad, MD, PhD

Jacob K. Sont, PhD

Luuk N. A. Willems, MD, PhD

Klaus F. Rabe, MD, PhD

UP TO 40% OF THORACOTOMIES performed for non-small cell lung cancer (NSCLC) are reported to be unnecessary due to imperfect preoperative staging.<sup>1,2</sup> Accurate preoperative staging is important in identifying those patients who will benefit from surgical resection.<sup>3,4</sup> Patients with lymph node metastases (N2/N3) are not considered eligible for surgical resection, except for minimal N2 disease. All currently available staging techniques, such as computed tomography (CT) of the thorax, positron emission tomography (PET), transbronchial needle aspiration, and mediastinoscopy, have limited accuracy in selecting those lung cancer patients without regional lymph node metastases.<sup>5,6</sup>

Transesophageal ultrasound-guided fine-needle aspiration (EUS-FNA) is a minimally invasive and safe technique to sample mediastinal lymph nodes under real-time conditions and is complementary to mediastinoscopy in its diagnostic reach.<sup>5,7,8</sup> The EUS-FNA ex-

**Context** Up to 40% of thoracotomies performed for non-small cell lung cancer are unnecessary, predominantly due to inaccurate preoperative detection of lymph node metastases and mediastinal tumor invasion (T4). Mediastinoscopy and the novel, minimally invasive technique of transesophageal ultrasound-guided fine-needle aspiration (EUS-FNA) target different mediastinal lymph node stations. In addition, EUS can identify tumor invasion in neighboring organs if tumors are located adjacent to the esophagus.

**Objective** To investigate the additional value of EUS-FNA to mediastinoscopy in the preoperative staging of patients with non-small cell lung cancer.

**Design, Setting, and Patients** Prospective, nonrandomized multicenter trial performed in 1 referral and 5 general hospitals in the Netherlands. During a 3-year period (2000-2003), 107 consecutive patients with potential resectable non-small cell lung cancer underwent preoperative staging by both EUS-FNA and mediastinoscopy. Patients underwent thoracotomy with tumor resection if mediastinoscopy was negative. Surgical-pathological staging was compared with preoperative findings and the added benefit of the combined strategy was assessed.

**Intervention** The EUS-FNA examination was performed as an additional staging test to mediastinoscopy in all patients.

**Main Outcome Measure** Detection of mediastinal tumor invasion (T4) and lymph node metastases (N2/N3) comparing the combined staging by both EUS-FNA and mediastinoscopy with staging by mediastinoscopy alone.

**Results** The combination of EUS-FNA and mediastinoscopy identified more patients with tumor invasion or lymph node metastases (36%; 95% confidence interval [CI], 27%-46%) compared with either mediastinoscopy alone (20%; 95% CI, 13%-29%) or EUS-FNA (28%; 95% CI, 19%-38%) alone. This indicated that 16% of thoracotomies could have been avoided by using EUS-FNA in addition to mediastinoscopy. However, 2% of the EUS-FNA findings were false-positive.

**Conclusion** These preliminary findings suggest that EUS-FNA, when added to mediastinoscopy, improves the preoperative staging of lung cancer due to the complementary reach of EUS-FNA in detecting mediastinal lymph node metastases and the ability to assess mediastinal tumor invasion.

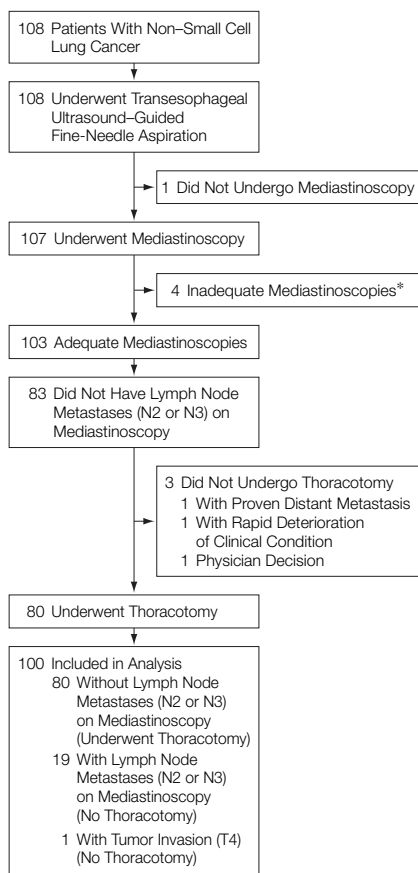
JAMA. 2005;294:931-936

www.jama.com

amination has a sensitivity of 88% and a specificity of 91% in analyzing mediastinal lymph nodes.<sup>5,7,8</sup> To date it is not known how EUS-FNA compares with mediastinoscopy, nor to what extent the combination of EUS-FNA and mediastinoscopy improves preoperative staging.

**Author Affiliations:** Divisions of Pulmonary Medicine (Drs Annema, Mauad, Willems, and Rabe), Cardiothoracic Surgery (Dr Versteegh), Pathology (Dr Veselić), and Medical Decision Making (Dr Sont), Leiden University Medical Center, Leiden, the Netherlands; and Division of Pulmonary Medicine, Krankenhaus Grosshansdorf, Grosshansdorf, Germany (Dr Welker).  
**Corresponding Author:** Jouke T. Annema, MD, PhD, Department of Pulmonology C3 P, Albinusdreef 2, 2300 RC Leiden University Medical Center, PO Box 9600, Leiden, the Netherlands (j.t.annema@lumc.nl).

See also Patient Page.

**Figure.** Flowchart of Staging for Patients With Non-Small Cell Lung Cancer

Asterisk indicates no biopsies of at least lymph node station 4L and 4R and 7.

Patients with tumors invading the mediastinum, heart, or central vessels are generally not candidates for surgery. Currently, mediastinal tumor invasion (T4) is frequently assessed intraoperatively because CT has limited sensitivity and specificity (<75%) for mediastinal invasion<sup>9</sup> and PET has no value in detecting T4 tumors due to its limited anatomical resolution. However, in a recent study,<sup>10</sup> EUS has demonstrated a high sensitivity (88%) and specificity (98%) in diagnosing T4 tumors.

In the present prospective study, patients with proven NSCLC who were candidates for surgical resection were staged by both EUS-FNA and mediastinoscopy. The EUS-FNA results were used for study purposes only. The primary aim was to assess whether stag-

ing by EUS-FNA in addition to mediastinoscopy improved preoperative staging compared with staging by mediastinoscopy alone.

## METHODS

Patients with proven NSCLC without signs of distant metastases after conventional staging and who were scheduled for mediastinoscopy were eligible for the present study. According to local guidelines, all NSCLC patients who are surgical candidates are staged by mediastinoscopy regardless of mediastinal lymph node size on CT scans. Patients were approached by a study physician and asked to undergo an EUS-FNA examination on a voluntary basis for study purposes. Candidates for the study were explicitly told that EUS-FNA results were going to be used for study purposes only and that further treatment decisions would be based on the results of mediastinoscopy. A single exception was created in the protocol for patients with an N3 lymph node metastasis confirmed by EUS-FNA that was not assessed by mediastinoscopy. However, this situation did not occur once the trial was under way. If the absence of regional lymph node metastases was confirmed at mediastinoscopy, patients underwent resection of the lung tumor with complete lymph node dissection. The EUS-FNA examination was performed separately from mediastinoscopy to assess possible complications and acquire information about patients' preference for either staging technique. The ethical committee of the Leiden University Medical Center (Leiden, the Netherlands) approved this study. Oral and written informed consent for study participants was obtained at study entry.

### EUS-FNA Examinations and Surgery

All EUS-FNA examinations were scheduled prior to mediastinoscopy. We deliberately decided not to randomize the sequence of EUS-FNA and mediastinoscopy because we wanted to prevent a situation in which all lymph node tissue was removed by mediastinoscopy, which would prevent EUS-FNA from sampling it. The EUS-FNA examinations

were performed at the Department of Pulmonary Medicine, Leiden University Medical Center, using a Pentax FG 34 UX echoendoscope (Pentax GmbH, Hamburg, Germany) with a longitudinal convex ultrasound transducer and an adjustable ultrasonic frequency of 5, 7.5, or 10 MHz in combination with a Hitachi EUB 6500 ultrasound scanner (Hitachi Medical Systems Ltd, Reeuwijk, the Netherlands). The EUS-FNA examination was performed on an outpatient basis under conscious sedation using 1 to 5 mg of midazolam (intravenously). Lymph nodes were described, videotaped, and numbered according to the regional lymph node classification for lung cancer staging.<sup>11</sup> Aspiration of mediastinal lymph nodes was performed under ultrasound guidance from the esophagus with a 22-gauge needle and vacuum (Hancke/Vilmann type, GIP/Medi-Globe Inc, Tempe, Ariz). The aspirated material was stained and examined on-site for adequacy before assessment by an experienced cytopathologist. If the primary tumor was visible with EUS, the presence or absence of mediastinal tumor invasion was recorded. Patients were observed for 2 hours after the procedure and were instructed to contact the hospital if chest or other discomfort occurred.

The EUS-FNA findings were not available to cardiothoracic surgeons. Cervical mediastinoscopy was considered adequate if it minimally included biopsies of the left and right lower paratracheal (4L, 4R) and the subcarinal lymph nodes.<sup>7</sup> Pathological examination of resected mediastinal lymph nodes was performed according to standard procedures (in lymph nodes <1 cm, sliced once in the midline; in lymph nodes >1 cm, lamination of the lymph node and staining with hematoxylin-eosin). An experienced pathologist judged all lymph node biopsies. Surgeons dissected the regional lymph node stations during thoracotomy.

### Assessment of Lymph Node Metastases and Tumor Invasion

For both EUS-FNA and mediastinoscopy, microscopic proof of malig-

nancy was compulsory to stage a lymph node as malignant. For CT, mediastinal lymph nodes with a short axis (>1 cm) were classified as enlarged. An experienced radiologist reviewed the CT scans of the chest according to the regional lymph node classification.<sup>11</sup>

For CT, the presence or absence of mediastinal tumor invasion was recorded. Endoscopic ultrasound findings demonstrating tumor invasion to the heart, large central vessels, or mediastinum equaled tumor stage T4. After both an EUS-FNA examination and mediastinoscopy, patients' preference for either EUS-FNA or mediastinoscopy was assessed by a short questionnaire.

### Statistical Analysis

The primary end point of this study was the detection of mediastinal tumor invasion (T4) or lymph node metastases (N2/N3). The outcomes were reported as point estimates with 95% confidence intervals (CIs). The reference standard for the presence or absence of lymph node metastases or tumor invasion was histological evaluation as performed by both mediastinoscopy and thoracotomy with lymph node dissection (for those patients in whom no lymph node metastases were detected by mediastinoscopy) or mediastinoscopy alone (for those patients with lymph node metastases assessed by mediastinoscopy). In the latter group, it was judged unethical to verify tumor-positive mediastinoscopic results by open thoracotomy. We hypothesized that the prevalence of patients with either mediastinal tumor invasion (T4) or lymph node metastases (N2/N3) was 40% and that mediastinoscopy alone would detect half of these patients (20%). Due to the complementary reach of EUS-FNA and mediastinoscopy and the fact that EUS-FNA might assess tumor invasion, we hypothesized that combined staging by both EUS-FNA and mediastinoscopy would detect 30% of these patients.

For EUS-FNA and mediastinoscopy, separately and in combination, the sensitivity, specificity, positive predictive value (PPV), negative predictive value (NPV), and diagnostic accu-

racy were assessed for the lymph node stations, which can be reached by either technique as opposed to all existing lymph node stations. For mediastinoscopy these were stations 2L, 2R, 4L, 4R, and 7 and for EUS-FNA these were stations 3, 4L, 5, 7, 8, and 9. For both CT and EUS-FNA, the accuracy of mediastinal tumor invasion was assessed. At the end of the study, to assess interobserver variability quantified by the  $\kappa$  statistic, CT scans of the chest, lymph node aspirates obtained by EUS-FNA, and lymph node biopsies obtained by mediastinoscopy were reevaluated by an independent thoracic radiologist, a cytopathologist, and a pathologist not involved in the study. All statistical analyses were performed using SPSS version 12.0 (SPSS Inc, Chicago, Ill).

### RESULTS

A total of 108 consecutive patients with proven NSCLC were enrolled in the study. Eight patients were not evaluable for the primary outcome measure due to inadequate (n=4) or cancelled (n=1) mediastinoscopies, lack of surgical verification after negative mediastinoscopies due to a proven distant metastasis (n=1), a rapidly deteriorating clinical condition (n=1), and a treating physician changing his therapeutic strategy (n=1) (FIGURE). Characteristics of the 100 evaluable patients appear in TABLE 1.

#### Direct Benefit of Additional Staging by EUS-FNA

The combination of EUS-FNA and mediastinoscopy identified more patients (36%; 95% CI, 27%-46%) with mediastinal tumor invasion (T4) or lymph node metastases (N2/N3) compared with either mediastinoscopy alone (20%; 95% CI, 13%-29%) or EUS-FNA alone (28%; 95% CI, 19%-38%). The EUS-FNA examination detected advanced disease in 16% of patients with a negative mediastinoscopy by assessing lymph node metastases (N2) in 9%, mediastinal tumor invasion (T4) in 4%, and both mediastinal tumor invasion (T4) and lymph node metastases (N2) in 3% of patients (TABLE 2). This indicated that 16% of

**Table 1.** Characteristics of Evaluable Patients With Proven Non-Small Cell Lung Cancer Considered for Surgery (N = 100)

	No. of Patients
Sex	
Male	69
Female	31
Age, median (range), y	60 (34-82)
Histology of carcinoma	
Squamous cell	48
Adenocarcinoma	32
Large cell undifferentiated	14
Adenosquamous	4
Adenocystic	1
Bronchioalveolar cell	1
Lobe	
Left upper	21
Left lower	25
Lingula	4
Right upper	32
Right lower	14
Middle	4
Stage assessed by computed tomography	
I	28
II	7
IIIA	37
IIIB	27
IV	1
Pathological stage	
I	32
II	18
IIIA	30
IIIB	13
IV	7

thoracotomies could have been avoided by using EUS-FNA in addition to mediastinoscopy. However, 2% of the EUS-FNA results were false-positive.

#### Node Staging

The prevalence of lymph node metastases (N2/N3), as assessed after surgery, in our cohort was 36%. A CT scan of the chest was available with slices of at least 10 mm and intravenous contrast was used in 87% of patients. Half of the patients had normal-sized mediastinal lymph nodes. For CT, the sensitivity of assessing mediastinal lymph node metastases was 69%; specificity, 49%; PPV, 43%; NPV, 73%; and diagnostic accuracy, 56% (TABLE 3).

The EUS-FNA examination detected N2 (21%) or N3 (1%) lymph node metastases in 22 of the 100 patients (Table 2). In 26 patients, no EUS-guided aspirates of mediastinal lymph node were taken due to the very small size (<5 mm) or absence of detectable lymph nodes. Of the 74 patients

in whom EUS-guided aspirates of mediastinal lymph nodes were taken (median number of needle passes: 3; range, 1-7), representative material was obtained in 66 patients (89%). Patients without detectable nodes or those with small, sonographic nonsuspicious nodes in which aspirates were not evaluable also were staged as N0. Of the 36 patients with proven lymph node metastases (N2/N3), they were located within reach of EUS-FNA in 29 patients and were confirmed in 22 of these patients. Lymph node metastases that were missed were located at the stations 4L in 1 patient, 5 in 1 patient, 7 in 4 patients, and 8 in 1 patient. Two subcarinal lymph node metastases assessed by EUS-FNA were not confirmed by mediastinoscopy and thoracotomy. For EUS-FNA, the sensitivity of assessing mediastinal lymph nodes was 76%; specificity, 97%; PPV, 92%; NPV, 91%; and diagnostic accuracy, 91% (Table 3). No complications, such

as fever, chest pain, or mediastinitis, occurred during or after EUS-FNA.

Mediastinoscopy detected N2 (17%) or N3 (2%) lymph node metastases in 19 of the 100 patients (Table 2). Of the 36 patients with lymph node metastases (N2/N3), they were located within reach of mediastinoscopy in 29 patients and were confirmed in 19 of these patients. Lymph node metastases that were missed were located at station 4L in 2 patients and station 7 in 8 patients. In the 10 patients in which mediastinoscopy was false-negative, biopsy material was obtained from the affected lymph node station. For mediastinoscopy, the sensitivity of assessing mediastinal lymph nodes was 66%; specificity, 100%; PPV, 100%; NPV, 88%; and diagnostic accuracy, 90% (Table 3). Six patients reported hoarseness that occurred immediately after mediastinoscopy.

Lymph node metastases were confirmed in 31 (86%) of 36 patients by either EUS-FNA or mediastinoscopy

(Table 2). The 5 lymph node metastases that were missed by both techniques were located at station 4L in 1 patient, 5 in 1 patient, 7 in 2 patients, and 8 in 1 patient. The combination of EUS-FNA and mediastinoscopy detected more patients with lymph node metastases (31%; 95% CI, 22%-41%) compared with either mediastinoscopy alone (19%; 95% CI, 11%-28%) or EUS-FNA alone (22%; 95% CI, 14%-31%). For the combination of mediastinoscopy and EUS-FNA, the sensitivity of assessing all regional mediastinal lymph node stations was 86%; specificity, 97%; PPV, 94%; NPV, 93%; and diagnostic accuracy, 93% (Table 3).

### Tumor Staging

The prevalence of mediastinal tumor invasion was 17%. Mediastinal tumor invasion (T4) was assessed by EUS-FNA in 7 (44%) of the 17 patients based on invasion in the mediastinum (n=4), large central vessels (n=2), or both (n=1) (Table 2). Of the 7 patients with mediastinal tumor invasion (T4) staged by EUS-FNA, 4 were staged T4 by CT as well. The sensitivity of EUS-FNA was 44%; specificity, 100%; PPV, 100%; NPV, 88%; and accuracy, 89%. The sensitivity of CT was 38%; specificity, 88%; PPV, 38%; NPV, 88%; and accuracy, 79%. One patient was staged T4 by mediastinoscopy based on tracheal growth of an upper lobe tumor. Previously, a second bronchoscopy with deep mucosal biopsies did not reveal a tumor.

### Surgical-Pathological Staging and Interobserver Variability

Because mediastinoscopy yielded positive results in 20% of the patients, a thoracotomy was performed in 80% of the patients. Of the 80 patients who underwent thoracotomy (Figure), the following pathological data were obtained: N2 lymph node metastases in 12 patients (15%); mediastinal tumor invasion (T4) in 8 patients (10%); both mediastinal tumor invasion (T4) and lymph node metastases (N2) in 3 patients (3%); both mediastinal tumor invasion (T4) and either small pleural metastases or satellite nodules in another lobe (M1) in 5 patients

**Table 2.** Preoperative Staging of Patients With Non-Small Cell Lung Cancer

Stage	No. of Patients (N = 100)		
	Mediastinoscopy	EUS-FNA	Mediastinoscopy + EUS-FNA
N0	80	70*	62
N2 (false-positive)	0	2	2
N2 or N3	19	22	31
T4 (+N2)	1	6 (1†)	5 (3‡)
T4 and/or N2 or N3	20	28	36

Abbreviations: EUS, endoscopic ultrasound; FNA, fine-needle aspiration.

\*Patients without detectable nodes or those with small, sonographic nonsuspicious nodes in which aspirates were not evaluable also were staged as N0.

†One patient was staged both T4 and N2 by EUS.

‡One patient was staged T4N2 by EUS and 2 were staged T4 by EUS and N2 by mediastinoscopy.

**Table 3.** Diagnostic Values in the Analysis of N2/N3 Lymph Node Stations in Non-Small Cell Lung Cancer

	No. (%) of Patients			
	Computed Tomography (n = 100)	Mediastinoscopy* (n = 93)	EUS-FNA* (n = 93)	Mediastinoscopy + EUS-FNA (n = 100)
Sensitivity	69 (69)	61 (66)	71 (76)	86 (86)
Specificity	49 (49)	93 (100)	90 (97)	97 (97)
Predictive value				
Positive	43 (43)	93 (100)	86 (92)	94 (94)
Negative	73 (73)	82 (88)	85 (91)	93 (93)
Accuracy	56 (56)	84 (90)	85 (91)	93 (93)

Abbreviations: EUS, endoscopic ultrasound; FNA, fine-needle aspiration.

\*Assessed according to diagnostic range.

(6%); and lymph node metastases (N2) and either small pleural metastases or satellite nodules in another lobe (M1) in 2 patients (3%). In 2 patients, the EUS-FNA findings of lymph node metastases (N2) were not confirmed by surgical-pathological staging. The pathological staging of the cohort appears in Table 1. Four patients undergoing thoracotomy experienced severe complications: hypoxia due to cardiac arrest (n=1), bleeding necessitating pneumectomy instead of lobectomy (n=1), bronchopleural fistula (n=1), and an irreversible spinal cord paralysis (n=1).

The interobserver variability in assessing lymph node metastases by CT yielded a  $\kappa$  of 0.65; for cytology obtained by EUS-FNA,  $\kappa$  = 0.88; and for histology obtained by mediastinoscopy,  $\kappa$  = 1.0. In this study, 80% of patients preferred EUS-FNA, 10% preferred mediastinoscopy, and 10% had no preference for either technique.

## COMMENT

This study demonstrates that preoperative staging by EUS-FNA in addition to mediastinoscopy identifies more patients with either mediastinal tumor invasion (T4) or lymph node metastases (N2/N3) compared with staging by mediastinoscopy alone. The results can be explained by the fact that EUS-FNA and mediastinoscopy have a complementary reach in assessing regional lymph node stations and in the ability of EUS-FNA to detect mediastinal tumor invasion. If the EUS-FNA results had been taken into account in the present study, a thoracotomy could have been prevented in 1 of 6 patients. Our findings are directly applicable to clinical practice.

This is the first study, to our knowledge, that prospectively compared EUS-FNA with mediastinoscopy in the preoperative staging of NSCLC. Additionally, this is the first study in which positive findings from EUS-FNA were verified by surgical-pathological findings. New diagnostic tests, such as EUS-FNA, need to be evaluated against the reference standard to assess their value.

Two patients in this study were overstaged by EUS-FNA because investiga-

tors judged a round, well-defined hypoechoic structure located adjacent to a left lower lobe tumor as a subcarinal lymph node. Endoscopic ultrasound-guided biopsies of this structure revealed malignant cells; however, neither mediastinoscopy nor thoracotomy revealed subcarinal lymph node metastases. In retrospect, biopsies had been taken from the tumor itself, and the false-positive results were due to misinterpretation of the EUS-FNA images. We now believe that a mediastinoscopy should always be performed in patients with lymph nodes located immediately adjacent to the primary tumor.

Only half of the patients in the present study had enlarged mediastinal lymph node stations on CT scans. Therefore, it is not surprising that our sensitivity of 76% in assessing mediastinal lymph nodes by EUS-FNA is a bit lower than other studies (median, 88%; range, 82%-97%).<sup>5,7,8,12,13</sup> This difference could be explained by the fact that in other studies EUS-FNA was performed in selected patients with enlarged mediastinal lymph nodes on CT scans. The prevalence of regional lymph node metastases was around 70% in a recent review<sup>5</sup> compared with the prevalence of 36% found in this study. We did not select patients on the basis of enlarged mediastinal lymph nodes, which is a scenario that is in our opinion closer to clinical reality.

In addition to regional lymph node staging, EUS-FNA identified 7 (44%) of the 17 patients with T4 tumors invading the mediastinum (n=4), large central vessels (n=2), or both (n=1). The prevalence of T4 tumors in the present study was relatively high. With a sensitivity of 44% and a specificity of 100%, EUS-FNA was more accurate than CT, which had a sensitivity of only 38% and a specificity of only 88%. The only other study<sup>10</sup> providing data about tumor staging assessed by EUS reported a sensitivity of 88%; specificity, 98%; PPV, 70%; and NPV, 99%. However, not all cases of mediastinal tumor invasion (T4) in that study were verified by surgical-pathological staging.

Surgical-pathological staging is the reference standard for preoperative lymph

node staging. We carefully assessed all mediastinoscopies and excluded those not performed adequately. The specificity, PPV, NPV, and accuracy of assessing mediastinal lymph nodes by mediastinoscopy in our study correspond well with those found in the literature.<sup>5,7</sup> However, the sensitivity of mediastinoscopy in our study (66%) was lower compared with the pooled sensitivity (81%) of cervical mediastinoscopy reported in a recent review.<sup>5</sup> Although some of these studies reported sensitivities around 70%, a few large retrospective studies found sensitivities up to 93%. These data should be judged critically because nothing was mentioned about the rigidity of lymph node sampling at thoracotomy in the largest study with 1369 patients and a reported sensitivity of 85%.<sup>14</sup> The key issue is validation of negative mediastinoscopy results. In the other large study<sup>15</sup> of 1259 patients, the reported sensitivity of 93% for mediastinoscopy was calculated for the superior lymph nodes only. If we apply that definition to our data, the sensitivity of mediastinoscopy in our study cohort would increase to 90% because 8 of the 10 missed metastases were located subcarinally. The dorsal part of lymph node station 7, the most frequently involved mediastinal station, cannot be reached by mediastinoscopy.<sup>14,16</sup> However, due to its position adjacent to the esophagus, it can be reached by EUS-FNA.

The reported hoarseness, which occurred immediately after mediastinoscopy in 6% of patients, was possibly due to recurrent nerve paralysis. The morbidity of mediastinoscopy reported in the literature is 2%.<sup>14</sup> The majority of patients (80%) in our study preferred EUS-FNA compared with mediastinoscopy because of the absence of general anesthesia and clinical admission.

Some limitations apply to this study. The EUS-FNA examinations were performed at only 1 academic center with highly experienced clinicians, while mediastinoscopy and CT were performed at several study sites. The end point of this study was the assessment of a specific staging end point, the presence of either mediastinal tumor inva-

sion (T4) or lymph node metastases (N2/N3). This end point is important because patients with N2/N3 lymph node metastases (stage IIIA/IIIB) or mediastinal tumor invasion (stage IIIB) are not considered candidates for surgical resection. The data demonstrate that staging by EUS-FNA in addition to mediastinoscopy improves preoperative staging significantly. Although not proven in a randomized design, these data strongly suggest that additional staging by EUS-FNA reduces unnecessary thoracotomies. The obvious question that remains is whether the staging of NSCLC by EUS-FNA is another add-on or a breakthrough in selecting patients for surgical resection.

Staging by EUS-FNA in addition to mediastinoscopy in this study demonstrated that this combination could have led to the prevention of a thoracotomy in 1 of 6 patients, with an expected impact on patient management comparable with the addition of PET to mediastinoscopy.<sup>2</sup> The improvement in the preoperative staging due to PET<sup>17</sup> and PET-CT<sup>18</sup> has resulted in the recommendation to use PET in the preoperative workup of NSCLC.<sup>3,19</sup> In the only large comparison study between PET and EUS-FNA, with the identification of inoperable patients as primary outcome, PET and EUS-FNA had similar sensitivities (68% and 63%, respectively) and NPVs (64% and 68%, respectively). However, superior specificity of EUS compared with PET (100% and 72%, respectively) and a considerably lower expense led researchers in one study<sup>20</sup> to the conclusion that EUS was preferred above PET in preoperative staging to identify inoperable patients. A new algorithm is needed for mediastinal lymph node staging in which the place of the following techniques should be defined: bronchoscopy with transbronchial needle aspiration, endobronchial ultrasound-guided transbronchial needle aspiration, EUS-FNA, PET, and mediastinoscopy. We advocate the use of EUS-FNA early in the preoperative staging of NSCLC because EUS-FNA alone in the present study pro-

vided proof of lymph node metastases or mediastinal tumor invasion in 28% of patients with NSCLC.

Overall, mediastinoscopy and EUS-FNA have inherent limitations and they should be viewed as complementary in the regional staging of NSCLC. These preliminary findings suggest that EUS-FNA, a novel, minimally invasive staging procedure for lung cancer, may improve the preoperative staging due to the complementary reach of EUS-FNA in detecting mediastinal lymph node metastases and the ability to assess mediastinal tumor invasion. However, the occurrence of false-positive EUS-FNA findings in selected cases needs to be further investigated.

**Author Contributions:** Dr Annema had full access to all of the data in the study and takes responsibility for the integrity of the data and the accuracy of the data analysis.

**Study concept and design:** Annema, Versteegh, Sont, Willems, Rabe.

**Acquisition of data:** Annema, Versteegh, Veselić, Welker, Rabe.

**Analysis and interpretation of data:** Annema, Versteegh, Veselić, Mauad, Sont, Rabe.

**Drafting of the manuscript:** Annema, Versteegh, Mauad, Rabe.

**Critical revision of the manuscript for important intellectual content:** Annema, Versteegh, Veselić, Welker, Sont, Willems, Rabe.

**Statistical analysis:** Annema, Sont.

**Obtained funding:** Annema, Rabe.

**Administrative, technical, or material support:** Annema, Versteegh, Veselić, Welker, Mauad, Willems, Rabe.

**Study supervision:** Rabe.

**Financial Disclosures:** None reported.

**Funding/Support:** The research for this article was supported by a grant from the Leiden University Medical Center. Hitachi Ultrasound (Reeuwijk, the Netherlands) provided the ultrasound scanner and echocardiography on a loan basis.

**Role of the Sponsor:** The Leiden University Medical Center had no influence on the design, conduct of the study, or the data analysis.

**IKW Oncology Study Group:** E. H. Bel, MD, PhD; J. J. Brahim, MD; H. Codrington, MD; H. Dik, MD; J. Kersbergen, MD; H. C. J. van Klink, MD; K. W. Kralingen, MD, PhD; P. Marton, MD; B. Roldaan, MD, PhD; H. Schreur, MD, PhD; B. Slotema, MD; J. Stolk, MD, PhD; A. Ten Brinke, MD, PhD; H. P. A. van Veen, MD; and T. Wever, MD.

**Previous Presentations:** Presented in part at the 97th International Conference of the American Thoracic Society, San Francisco, Calif, May 22, 2001; 10th World Conference on Lung Cancer, Vancouver, British Columbia, August 12, 2003; and 100th International Conference of the American Thoracic Society Conference, Orlando, Fla, May 24, 2004.

**Acknowledgment:** We thank E. Joekes, MD, and J. Tjon a Ling, MD (Division of Radiology, Leiden University Medical Center), for scoring computed tomographic scans; D. Grootendorst, PhD, and F. Rosendaal, PhD (Division of Clinical Epidemiology, Leiden University Medical Center), for advice on statistical analyses; and A. van der Mey and W. J. Oud-

shoorn (Division of Pulmonary Medicine, Leiden University Medical Center) for computing and logistical assistance. Drs Joekes and Tjon a Ling received a fee of €900 for their contributions. No compensation was given to Drs Grootendorst and Rosendaal or to van der Mey and W. J. Oudshoorn.

## REFERENCES

- Herder GJ, Verboom P, Smit EF, et al. Practice, efficacy and cost of staging suspected non-small cell lung cancer. *Thorax*. 2002;57:11-14.
- van Tinteren H, Hoekstra OS, Smit EF, et al. Effectiveness of positron emission tomography in the preoperative assessment of patients with suspected non-small-cell lung cancer. *Lancet*. 2002;359:1388-1393.
- Spira A, Ettinger DS. Multidisciplinary management of lung cancer. *N Engl J Med*. 2004;350:379-392.
- Spiro SG, Porter JC. Lung cancer: where are we today? current advances in staging and nonsurgical treatment. *Am J Respir Crit Care Med*. 2002;166:1166-1196.
- Tolozza EM, Harpole L, Detterbeck F, McCrory DC. Invasive staging of non-small cell lung cancer. *Chest*. 2003;123(1 suppl):157S-166S.
- Tolozza EM, Harpole L, McCrory DC. Noninvasive staging of non-small cell lung cancer. *Chest*. 2003;123(1 suppl):137S-146S.
- Kramer H, Groen HJ. Current concepts in the mediastinal lymph node staging of nonsmall cell lung cancer. *Ann Surg*. 2003;238:180-188.
- Larsen SS, Krasnik M, Vilmann P, et al. Endoscopic ultrasound guided biopsy of mediastinal lesions has a major impact on patient management. *Thorax*. 2002;57:98-103.
- Venuta F, Rendina EA, Ciriaco P, et al. Computed tomography for preoperative assessment of T3 and T4 bronchogenic carcinoma. *Eur J Cardiothorac Surg*. 1992;6:238-241.
- Varadarajulu S, Schmulewitz N, Wildi SF, et al. Accuracy of EUS in staging of T4 lung cancer. *Gastrointest Endosc*. 2004;59:345-348.
- Mountain CF, Dresler CM. Regional lymph node classification for lung cancer staging. *Chest*. 1997;111:1718-1723.
- Annema JT, Hoekstra OS, Smit EF, et al. Towards a minimally invasive staging strategy in NSCLC. *Lung Cancer*. 2004;44:53-60.
- Wallace MB, Kennedy T, Durkalski V, et al. Randomized controlled trial of EUS-guided fine needle aspiration techniques for the detection of malignant lymphadenopathy. *Gastrointest Endosc*. 2001;54:441-447.
- Hammoud ZT, Anderson RC, Meyers BF, et al. The current role of mediastinoscopy in the evaluation of thoracic disease. *J Thorac Cardiovasc Surg*. 1999;118:894-899.
- Coughlin M, Deslauriers J, Beaulieu M, et al. Role of mediastinoscopy in pretreatment staging of patients with primary lung cancer. *Ann Thorac Surg*. 1985;40:556-560.
- Detterbeck FC, DeCamp MM Jr, Kohman LJ, Silvestri GA. Lung cancer: invasive staging: the guidelines. *Chest*. 2003;123(1 suppl):167S-175S.
- Pieterman RM, van Putten JW, Meuzelaar JJ, et al. Preoperative staging of non-small-cell lung cancer with positron-emission tomography. *N Engl J Med*. 2000;343:254-261.
- Lardinois D, Weder W, Hany TF, et al. Staging of non-small-cell lung cancer with integrated positron-emission tomography and computed tomography. *N Engl J Med*. 2003;348:2500-2507.
- Pfister DG, Johnson DH, Azzoli CG, et al. ASCO treatment of unresectable NSCLC guideline: update 2003. *J Clin Oncol*. 2004;22:330-353.
- Fritscher-Ravens A, Davidson BL, Hauber HP, et al. Endoscopic ultrasound, positron emission tomography, and computerized tomography for lung cancer. *Am J Respir Crit Care Med*. 2003;168:1293-1297.