

# Bevacizumab in Patients With Hereditary Hemorrhagic Telangiectasia and Severe Hepatic Vascular Malformations and High Cardiac Output

Sophie Dupuis-Girod, MD, PhD

Isabelle Ginon, MD

Jean-Christophe Saurin, MD, PhD

Denis Marion, MD

Elsa Guillot, MD

Evelyne Decullier, PhD

Adeline Roux, MSc

Marie-France Carette, MD, PhD

Brigitte Gilbert-Dussardier, MD, PhD

Pierre-Yves Hatron, MD, PhD

Pascal Lacombe, MD, PhD

Bernard Lorcerie, MD, PhD

Sophie Rivière, MD

Romain Corre, MD

Sophie Giraud, MD, PhD

Sabine Bailly, PhD

Gilles Paintaud, MD, PhD

David Ternant, MD

Pierre-Jean Valette, MD, PhD

Henri Plauchu, MD, PhD

Frédéric Faure, MD, PhD

**H**EREDITARY HEMORRHAGIC telangiectasia (HHT) (Online Mendelian Inheritance in Man [OMIM] #187300) is a dominantly inherited genetic vascular disorder characterized by recurrent epistaxis; cutaneous telangiectasia; and visceral arteriovenous malformations (AVMs) that affect many organs, including the lungs, gastrointestinal tract, liver, and brain. Diagnosis is based on the Curaçao criteria and

**Context** The only treatment available to restore normal cardiac output in patients with hereditary hemorrhagic telangiectasia (HHT) and cardiac failure is liver transplant. Anti-vascular endothelial growth factor treatments such as bevacizumab may be an effective treatment.

**Objectives** To test the efficacy of bevacizumab in reducing high cardiac output in severe hepatic forms of HHT and to assess improvement in epistaxis duration and quality of life.

**Design, Setting, and Patients** Single-center, phase 2 trial with national recruitment from the French HHT Network. Patients were 18 to 70 years old and had confirmed HHT, severe liver involvement, and a high cardiac index related to HHT.

**Intervention** Bevacizumab, 5 mg per kg, every 14 days for a total of 6 injections. The total duration of the treatment was 2.5 months; patients were followed up for 6 months after the beginning of the treatment.

**Main Outcome Measure** Decrease in cardiac output at 3 months after the first injection, evaluated by echocardiography.

**Results** A total of 25 patients were included between March 2009 and November 2010. Of the 24 patients who had echocardiograms available for reread, there was a response in 20 of 24 patients with normalization of cardiac index (complete response [CR] in 3 of 24, partial response [PR] in 17 of 24, and no response in 4 cases. Median cardiac index at beginning of the treatment was 5.05 L/min/m<sup>2</sup> (range, 4.1-6.2) and significantly decreased at 3 months after the beginning of the treatment with a median cardiac index of 4.2 L/min/m<sup>2</sup> (range, 2.9-5.2;  $P < .001$ ). Median cardiac index at 6 months was significantly lower than before treatment (4.1 L/min/m<sup>2</sup>; range, 3.0-5.1). Among 23 patients with available data at 6 months, we observed CR in 5 cases, PR in 15 cases, and no response in 3 cases. Mean duration of epistaxis, which was 221 minutes per month (range, 0-947) at inclusion, had significantly decreased at 3 months (134 minutes; range, 0-656) and 6 months (43 minutes; range, 0-310) ( $P = .008$ ). Quality of life had significantly improved. The most severe adverse events were 2 cases of grade 3 systemic hypertension, which were successfully treated.

**Conclusion** In this preliminary study of patients with HHT associated with severe hepatic vascular malformations and high cardiac output, administration of bevacizumab was associated with a decrease in cardiac output and reduced duration and number of episodes of epistaxis.

**Trial Registration** clinicaltrials.gov Identifier: NCT00843440

JAMA. 2012;307(9):948-955

www.jama.com

is considered definite if at least 3 of 4 criteria are fulfilled.<sup>1</sup> The criteria are spontaneous and recurrent epistaxis,

**Author Affiliations** are listed at the end of this article. **Corresponding Author:** Sophie Dupuis-Girod, MD, PhD, Hôpital Louis Pradel, Genetic Department and National Reference Center for Rendu-Osler Disease, Bron F-69677, France (sophie.dupuis-girod@chu-lyon.fr).

telangiectasia, family history, and visceral lesions.

Hepatic involvement is observed in up to 74% of patients,<sup>2,3</sup> but no more than 8% of those patients, mainly women, have symptomatic liver shunting.<sup>4,5</sup> The liver vascular malformations result in 3 complications: high output cardiac failure, in most cases and more rarely portal hypertension, and biliary necrosis. Hepatic shunting, like other extracardiac systemic shunts, is thought to be associated with increased cardiac preload and decreased peripheral vascular resistances, leading to an adaptive increase of cardiac output. High-output cardiac failure usually starts with a progressive increase in cardiac output, in turn leading to elevated left ventricle filling pressures, dyspnea, heart failure, and pulmonary hypertension.<sup>6</sup>

Two genes are associated with HHT: *ENG* (OMIM 131195) coding for endoglin<sup>7</sup> and *ACRLV1* (OMIM 601284) coding for the activin receptor-like kinase 1, ALK-1.<sup>8</sup> Mutations in either 1 of these 2 genes account for most clinical cases. In addition, mutations in *MADH4* (encoding SMAD4 [OMIM 600993]), which are responsible for juvenile polyposis/HHT overlap syndrome, have been described.<sup>9</sup> *ENG* and *ACVRL1* encode endothelial cell transmembrane proteins that appear to be components of the receptor complexes for growth factors of the transforming growth factor  $\beta$  superfamily (TGF- $\beta$ ). It has thus been hypothesized that HHT is related to an imbalanced state between antiangiogenic factors (such as bone morphogenetic protein 9) and proangiogenic factors (such as vascular endothelial growth factor [VEGF]).<sup>10</sup>

Because of the molecular mechanisms involved in both angiogenesis and HHT, a VEGF inhibitor such as bevacizumab could be an effective treatment for HHT. Because HHT is a multivisceral disease, systemic therapy seems to be preferable to local therapy. Prior case reports support this notion because bevacizumab resulted in clinical improvement in patients with

HHT.<sup>11,12</sup> Furthermore, the only treatment available at the present time in severe hepatic forms of HHT to restore normal cardiac output is an orthotopic liver transplant,<sup>13</sup> the disadvantages of which are multiple and include surgical morbidity, mortality, and an immunosuppressive treatment for life. Treatment with bevacizumab could prove beneficial because its use does not contraindicate subsequent liver transplant should the drug not control the complications of HHT.

We studied the efficacy of bevacizumab in severe hepatic forms of HHT associated with high cardiac output and report the results of this treatment with a 6-month follow-up period.

## METHODS

The study was prospective, open-label, and noncomparative and conducted in single institution after nationwide recruitment. Constructed according to the principles of the Gehan 2-stage design,<sup>14</sup> the study used a double sampling schedule to eliminate any ineffective treatment before enrolling the entire cohort. In the first stage of this design, if no objective response (defined by any decrease in cardiac index compared with the initial value) is seen in any of the patients, the drug would be rejected and the study stopped. A drug producing 1 or more responses in this first series of patients would enter the second stage, in which additional patients are treated. The purpose of the second stage is to estimate the response rate with a desired level of statistical precision.

The sample size was based on the requirements for stopping the study if the response rate was less than 30% with a 90% power and for estimating the response rate with a standard error of 10%. It was necessary to include 7 patients in the preliminary stage. If no success was observed in this stage, the trial would have been stopped. When at least 1 success was observed, the trial was continued after evaluation by an independent committee by including an additional 16 to 18 patients, depending on the success rate observed.

## Patient Selection

Enrollment began in March 2009. This study enrolled patients aged 18 to 70 years with clinically confirmed HHT (the presence of at least 3 of the Curaçao criteria), severe liver involvement connected with the HHT disease, and dyspnea ( $\geq$  class II according to the New York Heart Association) with high cardiac output on echocardiography, defined by a cardiac index of greater than 3.9 L/min/m<sup>2</sup> in men or greater than 3.6 L/min/m<sup>2</sup> in women.

To avoid the risk of thrombosis or hemorrhage, patients were excluded if they had thrombosis in the 6 months prior to enrollment, atrial fibrillation, cerebral AVMs on magnetic resonance angiography, thrombopenia, or anticoagulant treatment. This study was approved by the local research ethics committee and by the French Medical Products Agency (AFSSAPS). Oral and written informed consent were obtained from all patients in accordance with national regulations.

## Treatment

Patients received bevacizumab intravenously at a dose of 5 mg per kg per injection every 14 days for a total of 6 injections. All doses were administered during a 1-day hospitalization period in a unit specializing in clinical research. One or 2 patients were included every week. After 7 patients completed 3 months of follow-up, an evaluation was performed by an independent committee before other patients were included. The second Gehan stage was initiated 3 months after completion of the first stage. Cardiac output measurements were performed before the first injection and then at 3 and 6 months after the first injection.

## Efficacy Criteria

The primary efficacy criterion was any decrease in cardiac index at 3 months evaluated by echocardiography, as compared with that measured at the beginning of the trial (before the first injection). All patients also underwent an echocardiogram at 6 months. Optimal efficacy (complete response [CR]) was

**Table 1.** Baseline Patient Characteristics (N = 25)

	No. (%)	Mean (SD)	Median (Range)
Age, y	25 (100)	57.44 (8.6)	59 (35-68)
Sex			
Female	24 (96)		
Male	1 (4)		
Presence of PAVMs	8 (32)		
Gene mutation			
ACVRL1	22 (88)		
ENG	2 (8)		
SMAD4	1 (4)		
Cardiac index, L/min/m <sup>2</sup>	24	5.01 (0.67)	5.05 (4.1-6.2)
Dyspnea <sup>a</sup>			
Class II	17 (68)		
Class III	8 (32)		
Left-ventricular filling pressures			
Low	10 (40)		
Limit	8 (32)		
High	7 (28)		
sPAP, mm Hg	25 (100)	37.36 (11.5)	33 (23-79)
Duration of epistaxis, min/mo	25 (100)	221 (239.7)	179 (0-947)
Hemoglobin, g/L	25 (100)	118.7 (22.5)	120 (51-168)
Liver enzymes, U/L			
AST	25 (100)	33 (12.1)	31 (16-57)
ALT		30 (16.1)	25 (7-71)
Alkaline phosphatase		127 (60.2)	104 (47-259)
GGT		160 (151.4)	138 (16-702)

Abbreviations: ALT, alanine aminotransferase; AST, aspartate aminotransferase; GGT,  $\gamma$ -glutamyltransferase; PAVMs, pulmonary arteriovenous malformations; sPAP, systolic pulmonary artery pressure.

SI conversion factors: To convert AST, ALT, alkaline phosphatase, and GGT to  $\mu$ kat/L, multiply by 0.0167.

<sup>a</sup>According to the New York Heart Association.

defined as normalization of cardiac output (cardiac index between 2.5 and 3.9 L/min/m<sup>2</sup> for men and between 2.5 and 3.6 L/min/m<sup>2</sup> for women) at 3 months. Partial response (PR) was defined by any decrease in the cardiac index compared with the initial value but without normalization.

Echocardiography was performed using a Vivid 7 echocardiograph (General Electric) and by the same cardiologist (I.G.), under the same conditions (patient at rest in a quiet atmosphere with unchanged treatment), to minimize induced variations in cardiac output. Left ventricle (LV) size and function, left atrial (LA) size, Doppler evaluation of LV-filling pressures (using mitral and pulmonary venous flow and E/Ea ratio), and pulmonary pressure were assessed using standard measurements. Cardiac output (CO) was evaluated by measuring left ventricular outflow

tract (LVOT) and LVOT velocity-time integral (VTI), obtained on pulse Doppler imaging. The LVOT region of interest was outlined with a cursor as identified on pulse Doppler imaging. From this point, the computer obtained subsequent measurements automatically. Using these measurements, CO was calculated using this formula:  $(\pi \times [LVOT/2]^2 \times LVOT VTI \times \text{heart rate})$  divided by 1000. The CO value was indexed to height and weight to obtain the cardiac index. At least 5 blood flow velocity measurements were averaged, and at least 3 measurements of LV outflow tract diameter were also taken at the aortic orifice. All data were recorded on CD-ROM, and a blinded reread was performed at the end of the study (I.G.).

Secondary criteria at 3 months included: dyspnea according to New York Heart Association classification and

echocardiographic data and skin, mouth, and nose examination (face and hand telangiectasia were numbered and recorded on a diagram before treatment and at 3 and 6 months). We used a daily time report and a grid to record daily duration and number of episodes of epistaxis. Hemoglobin levels and number of blood transfusions were systematically recorded at each visit. Quality of life was evaluated using the Short Form-36 Health Survey (SF-36) questionnaire<sup>15</sup> before treatment and 3 and 6 months after treatment.

Liver evaluation included a clinical examination as well as biological and radiological assessments. Biological liver measurements included transaminases, alkaline phosphatases,  $\gamma$ -glutamyltransferase, and total bilirubin. Liver radiological response was monitored using Doppler ultrasound and multiphase multidetector hepatic computed tomographic (CT) examinations before treatment and at 3 and 6 months. Liver volumes were obtained using CT scan and Vitrea version 5.1 (Vital Images). Liver Doppler ultrasound determined diameter, course, and abnormalities of the hepatic artery, portal vein, and hepatic veins. Contrast-enhanced ultrasound was recorded and analyzed offline to assess functional modifications of liver hepatic perfusion, enhancement times, and kinetics before treatment and at 15 days, 29 days, 57 days, and 3 months after the beginning of treatment for patients who did not have pulmonary AVMs. Vascular spots, arterial contrast enhancement, transit time between the hepatic artery and hepatic veins, and parenchyma enhancement curve (ascending curve and area under the curve) were measured to register early functional changes. Images were not blinded.

Patients with pulmonary AVM before treatment on CT scan underwent a control CT scan at 6 months.

#### Bevacizumab Pharmacokinetics

Blood samples were collected before and 2 hours after the end of each injection

and additional samples taken 5 hours and 24 hours after the first one. Bevacizumab serum concentrations were measured using a validated enzyme-linked immunosorbent assay<sup>16</sup> and described using a population pharmacokinetic approach with Monolix software (Inria). A 2-compartment model with first-order transfer constants gave the best results and was used to estimate the bevacizumab area under the concentration vs time curve (AUC) until evaluation times.

### Safety

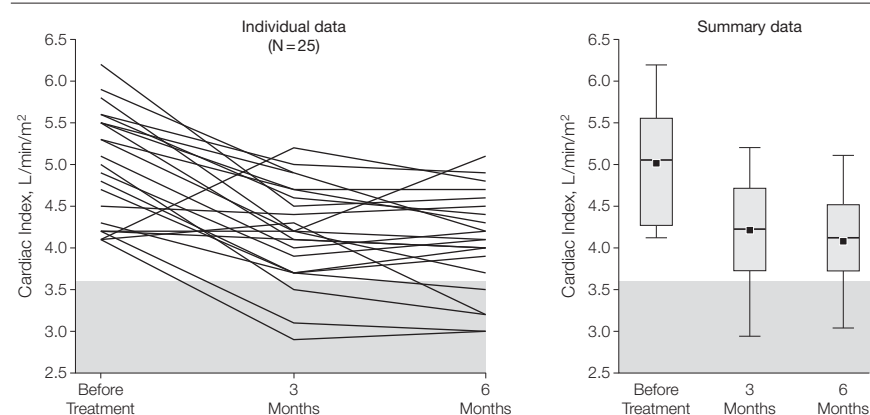
Adverse events were graded by investigators according to the National Cancer Institute common toxicity criteria scale (version 3.0). Any grade 3 and 4 toxicity events on the scale were considered to be toxic events with the exception of rest dyspnea, epistaxis, anemia associated with epistaxis, or the chronic digestive hemorrhages associated with HHT before treatment. Safety was evaluated at each visit by physical examination, laboratory testing, and assessment for adverse events. Adverse events were classified as unrelated, doubtful, possibly related, probably related, or certainly related to the treatment.

### Statistics

The analysis was descriptive with frequency for qualitative variables and mean, median, and range for quantitative variables. The efficacy population was defined by all patients with the evaluation criterion available at 3 months. Patients withdrawing from the study after at least 1 injection were considered as nonresponse. Comparisons between values at inclusion and values at 3 or 6 months were made using the Wilcoxon signed-rank test for paired data. Trend over time was assessed using a repeated measures model. Comparison between qualitative values at inclusion and at 3 and 6 months were made using Cochran-Armitage test for trend. A *P* value of 5% (2-tailed) was used to identify statistical significance. All analyses were performed using SAS version 9.1 (SAS Institute).

©2012 American Medical Association. All rights reserved.

**Figure 1.** Blinded Cardiac Index Before Treatment and 3 and 6 Months After the Beginning of Treatment With Bevacizumab



Cardiac index significantly declined in response to bevacizumab treatment. Squares indicate mean values; error bars, 95% CIs; boxes, median and interquartile range; shaded area, reference value range.

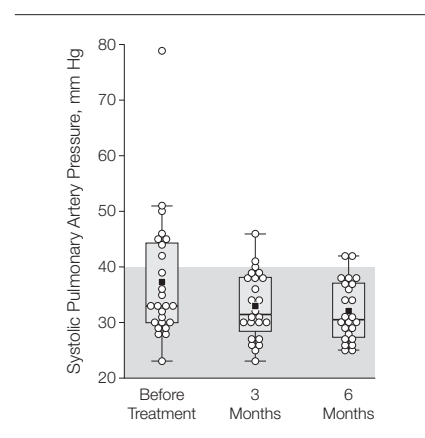
### RESULTS

Twenty-eight patients were included in this study between March 2009 and November 2010. Of them, 3 patients did not receive the treatment: 1 because of technical difficulties associated with vein access for the perfusion followed by a withdrawal of consent and 2 because of hypertension before treatment. Twenty-five patients were treated and 24 analyzed because the echocardiogram was not available for reread. Twenty-four received the entire bevacizumab injection schedule, and 1 stopped the treatment after 2 injections for personal convenience and was considered as having nonresponse (data were not available for this patient at 3 and 6 months).

#### Patient Characteristics Before Treatment

All 25 patients had hepatic AVMs with hepatic murmur in 22 cases (TABLE 1). Hepatic artery diameter was increased on CT scan in all patients (mean, 11.5 mm; range 7-14) with double hepatic arteries in 8 cases. All patients had a high cardiac index before treatment (mean, 5.01 L/min/m<sup>2</sup>) associated with dyspnea (class II n=17 and class III n=8). Fourteen patients had also elevated LV filling pressures and 8 had elevated pulmonary artery pressure.

**Figure 2.** Systolic Pulmonary Artery Pressures Before Treatment and 3 and 6 Months After the Beginning of Treatment With Bevacizumab



Five of 8 patients had normalization of pulmonary hypertension. Circles indicate individual values; squares, mean values; error bars, 95% CIs; boxes, median and interquartile range; shaded area, reference value range.

#### Response to Treatment

Intermediate analysis rejected inefficacy as 5 of 7 patients had a response (1 CR and 4 PR) at 3 months after the beginning of the treatment. The first stage in the Gehan design was therefore conclusive, and 18 patients were included in the second stage.

Final analysis of the main criterion included 25 patients; the blinded analysis was performed on 24 patients due to an unreadable CD. Blinded analysis

JAMA, March 7, 2012—Vol 307, No. 9 951

showed a response in 20 of 24 patients with normalization of cardiac index (CR) in 3 of 24, PR in 17 of 24, and no response in 4 cases. Mean and median cardiac index at beginning of the treatment were 5.01 L/min/m<sup>2</sup> (95% CI, 4.72-5.29) and 5.05 L/min/m<sup>2</sup> (range, 4.1-6.2), respectively, and significantly decreased at 3 months after the beginning of the treatment with a mean and a median cardiac index of 4.20

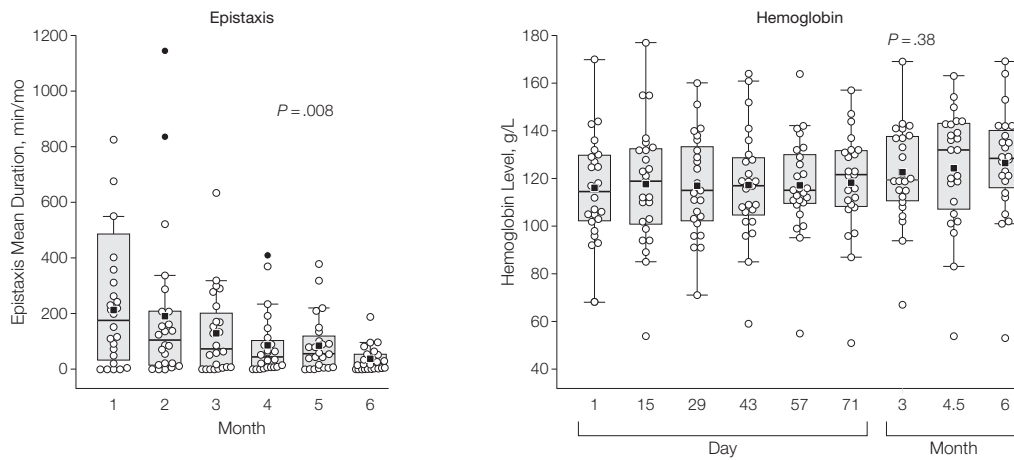
L/min/m<sup>2</sup> (95% CI, 3.94-4.45) and 4.2 L/min/m<sup>2</sup> (range, 2.9-5.2), respectively ( $P < .001$ ) (FIGURE 1).

Blinded cardiac index at 6 months was significantly lower than cardiac index before treatment (mean, 4.06 L/min/m<sup>2</sup>; 95% CI, 3.80-4.33, and median, 4.1 L/min/m<sup>2</sup>; range, 3.0-5.1). Among 23 patients with available data at 6 months, we observed CR in 5 cases, PR in 15 cases, and no response in 3

cases. Other cardiac parameters improved after treatment: systolic pulmonary hypertension (n=8) was normalized in 5 patients (FIGURE 2) and elevated LV filling pressure (n=14) was normalized in 6 patients at 3 months. Furthermore, 6 of the NYHA class III dyspnea changed to class II 6 months after the beginning of the treatment.

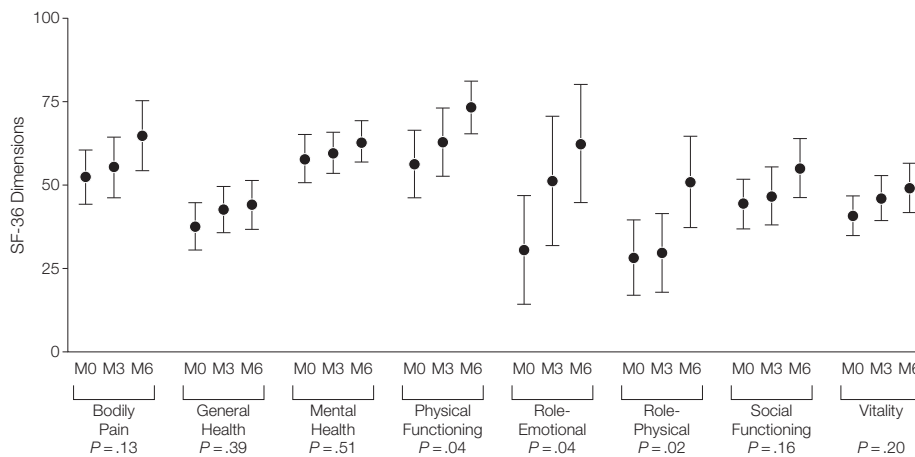
Mean duration of epistaxis, which was 221 minutes per month (range,

**Figure 3.** Epistaxis and Hemoglobin Levels After Treatment With Bevacizumab



The mean duration of epistaxis episodes (measured as minutes per month) significantly declined; the mean number of epistaxis episodes was 26 episodes per month before treatment and 20 per month after treatment. Hemoglobin levels remained stable throughout the course of the study. Squares indicate mean values; open circles, individual values; error bars, 95% CI; and filled circles, outliers (either an outside value, defined as a value smaller than the lower quartile minus 1.5 times the interquartile range, or larger than the upper quartile plus 1.5 times the interquartile range, or a far-out value, defined as a value that is smaller than the lower quartile minus 3 times the interquartile range, or larger than the upper quartile plus 3 times the interquartile range).  $P$  values are for mixed model.

**Figure 4.** SF-36 Scores Before Treatment and 3 and 6 Months After the Beginning of Treatment With Bevacizumab



All quality-of-life measures were improved. Higher scores indicate better outcome. SF-36 indicates Short Form-36 Health Survey; circles, mean values; error bars, 95% CI; M0, before treatment began; M3 and M6, 3 months and 6 months after treatment began. The comparison test to get the  $P$  values was from a repeated measures model.

0-947) at inclusion, had significantly decreased at 3 months (134 minutes; range, 0-656) and 6 months (43 minutes; range, 0-310) ( $P = .008$ ) (FIGURE 3). Mean number of epistaxis episodes was 26 episodes per month (range, 0-79) at inclusion, 20 episodes per month (range, 0-101) at 3 months, and 11 (range, 0-74) at 6 months. Eighty-seven percent of patients had a decrease in the mean duration of epistaxis of more than 30%.

The mean hemoglobin level was 119 g/L (range, 51-168) and 127 g/L (range, 53-169) before and 6 months after the beginning of the treatment ( $P = .38$ ) (Figure 3). Four patients required 12 blood transfusions in the first 3 months after treatment, and 5 transfusions during the 3 to 6 months after treatment. Number of telangiectasia on the face (skin, mouth, and nose) and hands did not significantly decrease 3 or 6 months after the beginning of the treatment. The SF-36 questionnaire revealed an improvement in all dimensions of quality of life after treatment (FIGURE 4).

None of the biological liver tests results significantly differed before and 3 and 6 months after treatment, including levels of aspartate aminotransferase (mean, 33, 43, and 40 U/L, respectively), alanine aminotransferase (mean, 30, 39, and 38 U/L, respectively), alkaline phosphatase (mean, 127, 152,

and 139 U/L, respectively),  $\gamma$ -glutamyltransferase (mean, 160, 170, and 178 U/L, respectively), and total bilirubin (mean, 11, 11, and 13  $\mu\text{mol/L}$ , respectively). However, an increase of both alanine and aspartate aminotransferase levels (1.5 times the initial value) was observed in 5 patients.

Hepatic CT scan and Doppler ultrasound parameters before and after treatment were not significantly different (TABLE 2). Contrast-enhanced ultrasound examination was performed in 16 patients. The presence of vascular spots was not significantly different before and after treatment; however, hepatic dynamic parameters improved significantly after treatment (Table 2).

#### Bevacizumab Pharmacokinetics

The distribution and elimination half-lives of bevacizumab (mean and inter-individual clearance volume) were 1.60 days (14%) and 21.5 days (27%), respectively. These values are similar to those previously reported in cancer patients.<sup>16,17</sup> The decrease in cardiac index and improvement of epistaxis at 3 and 6 months were not related to bevacizumab exposure as estimated by its cumulated AUC.

#### Adverse Effects

No patients experienced thromboembolic events, hemorrhage, gastrointes-

tinal perforation, or reversible posterior leukoencephalopathy. A total of 89 adverse events were declared as possibly or certainly related in 21 patients. One patient had a grade 3 systemic blood hypertension noticed 30 days after the first bevacizumab injection; this event was certainly related to bevacizumab and successfully treated with amlodipine. Twenty patients had at least 1 adverse event possibly related to bevacizumab (1-2 events in 8 patients, 3-4 events in 5 patients, 5 events in 4 patients, and >10 events in 3 patients). All events were observed during the 90 days following the first injection of bevacizumab. Among them, headache (52 events), nausea and vomiting (12 events), asthenia (9 events), abdominal pain (4 events), muscular pain (4 events), diarrhea (6 events), and rash (1 event) were reported.

#### COMMENT

In this trial of patients with HHT, bevacizumab was effective 3 months after the beginning of the treatment in 80% of patients in decreasing cardiac output related to hepatic shunting, with normalization of cardiac output in 12% of patients. There was clinical improvement of dyspnea and normalization of pulmonary pressure in patients with pulmonary hypertension before treatment, consistent with these results. Un-

**Table 2.** Computed Tomography (n = 25), Doppler (n = 25), and Contrast-Enhanced Liver Ultrasound (n = 16) Findings Before and After Bevacizumab Treatment

	Before Treatment		Month 3 <sup>a</sup>		Month 6 <sup>a</sup>		P Value <sup>b</sup>
	Mean (95% CI)	Median (Range)	Mean (95% CI)	Median (Range)	Mean (95% CI)	Median (Range)	
CT scan							
Liver volume, mL	1410 (1288-1532)	1413 (914-2118)	1242 (1147-1337)	1239 (882-1680)	1289 (1181-1398)	1240 (863-1800)	.08
HA diameter, mm	10.9 (10.0-11.9)	11 (7-15)	10.5 (9.4-11.6)	10 (5.5-15.8)	10.7 (9.8-11.7)	11 (7-15)	.80
Doppler ultrasound PFV, cm/s	200 (170-230)	200 (100-400)	219 (178-266)	200 (80-414)	201 (173-230)	200 (90-407)	.70
Contrast-enhanced ultrasound							
Vascular spots, No.	16		16		ND		>.99
TAH, sec	8.9 (8.4-9.5)	9 (7-11)	9.4 (8.2-10.5)	9 (5-15)	ND		.38
TTAVSH, sec	2.75 (2.2-3.3)	3 (0-4)	3.75 (3.0-4.5)	3 (2-8)	ND		.03
ABa, dB	10.19 (8.7-11.7)	9.5 (7-16)	8.05 (6.5-9.6)	8.2 (4-14)	ND		.11
Sn, dB	6.35 (1.4-11.3)	3.8 (2.1-40.0)	5.38 (3.7-7.1)	4.3 (2.7-15.8)	ND		.32

Abbreviations: ABa, ascending curve of the parenchyma enhancement curve; CT, computed tomographic; HA, hepatic artery; ND, not done; PFV, peak flow velocity; Sn, area under the curve; TAH, arterial contrast enhancement time; TTAVSH, transit time between the hepatic artery and hepatic veins.

<sup>a</sup>Time is measured from the beginning of the treatment.

<sup>b</sup>Mixed models  $P$  value (Mann-Whitney  $P$  value for contrast-enhanced ultrasound parameters).

til now, only case reports suggested a potential effect in HHT patients with severe hepatic shunting complicated by cardiac heart failure.<sup>11,12</sup> In HHT, regression of high cardiac output has been described after liver transplantation, supporting the idea that normalization of liver vascularization makes it possible to normalize cardiac function.<sup>18</sup> Similarly, we can hypothesize that the efficacy of bevacizumab, a VEGF antagonist, is based on its action on liver capillaries, contributing to reduced shunting and its cardiac consequences. As number of nosebleeds decreased with treatment, reduction of cardiac index could have at least partly attributed to better levels of hemoglobin. However, the absence of difference in hemoglobin levels at the time of evaluation before and after treatment supports the link between hepatic shunting reduction and decreased cardiac index. Patients were carefully tracked and medical treatment for cardiac failure was not modified during the study.

Nosebleeds are a major life-threatening complication in HHT. We showed that the total duration of epistaxis significantly improved 6 months after the beginning of the treatment in 87% of patients, as reported in a few case reports.<sup>11,19</sup> No surgery was needed or performed for nosebleeds during the study. Patients were carefully followed up for epistaxis because mild nosebleeds as well as nasal cartilage septum perforation have been described as an adverse effect of bevacizumab in patients with cancer.<sup>20-23</sup> Although longer follow-up is necessary, no worsening of epistaxis was observed in this study, and we hypothesized that in patients with cancer, infectious factors due to immunosuppression combined with nasal angiogenesis changes probably have a major role in the nosebleeds.

The SF-36 questionnaire, a validated health status survey, revealed low scores before treatment and improvement in all scores, particularly for vitality and physical dimensions after treatment. This observa-

tion probably reflects improvements in both dyspnea and epistaxis, although being observed in a study setting cannot be excluded as an explanation. However, in a previously published study on the quality of life of patients with HHT, it was effectively shown that the levels of health-related quality of life measured with the SF-36 were lower than those of normal controls in all domains except for bodily pain,<sup>24</sup> and that the duration of epistaxis and liver involvement had a major influence on health-related quality of life in HHT.<sup>25,26</sup>

Toxic effects were low and easily manageable in this study. Grade 3 bevacizumab-related toxicity was limited to systemic hypertension and was uncomplicated and successfully treated. In the literature, bevacizumab is generally well tolerated, although its use is associated with significant rates of systemic hypertension, with up to 16% rates of grade 3 hypertension.<sup>20,27-29</sup> This point must be carefully checked during treatment. Other adverse effects were limited to grade 1 adverse effects, mainly headaches, asthenia, and arthralgia during treatment with a spontaneous favorable evolution. No adverse effects regarding bleeding or clotting were observed. However, because of the small number of patients and the short follow-up time, toxicity and adverse effects should continue to be observed closely.

This study had several limitations. First, we chose to carry out a nonrandomized controlled trial for pragmatic reasons. Indeed, a small number of patients have severe liver involvement in this rare disease. In the European study on liver transplant in HHT, only 40 patients received transplantations because of HHT during the period 1985 to 2003<sup>30</sup> and around 70 patients in the European liver transplant register. For this reason, we chose the Gehan method to rapidly eliminate any treatment that was not effective or that had high toxicity. All patients were treated in the same center for security reasons, but recruitment was national. Second, because of the

small number of participants, these preliminary findings are encouraging, but we cannot draw any conclusions as to the efficacy and safety of bevacizumab in patients with HHT. These biases can influence findings in a nonrandomized study.

In conclusion, this preliminary study suggests that bevacizumab may be a therapeutic option in the treatment of HHT. Our results demonstrated improved cardiac output and reduced epistaxis. Toxicity was moderate. We do not know if this treatment could be definitive or a bridging therapy while patients are waiting for a liver transplant. Longer follow-up studies are necessary to determine the duration of HHT efficacy and whether maintenance therapy is required.

**Author Affiliations:** Hospices Civils de Lyon, Hôpital Louis Pradel, Genetic Department and National Reference Center for Rendu-Osler Disease, Bron, France (Drs Dupuis-Girod and Plauchu); Université de Lyon, Medical School, Université Lyon 1 (Drs Dupuis-Girod, Decullier, and Plauchu); Cardiology Department (Dr Ginon) and Radiology Department (Drs Marion, Guillot, and Valette), Hospices Civils de Lyon, Centre Hospitalier Lyon Sud, Pierre-Bénite, France; Hepatogastroenterology Department (Dr Saurin) and Head and Neck Surgery Department (Dr Faure), Hospices Civils de Lyon, Hôpital E. Herriot, Lyon, France; Hospices Civils de Lyon, pôle IMER, Lyon (Dr Decullier and Ms Roux); Radiology Department, Hôpital Tenon, Assistance Publique-Hôpitaux de Paris, Université Pierre et Marie Curie (Paris VI) Paris, France (Dr Carette); Genetic Department, CHU La Milétrie, Poitiers, France (Dr Gilbert-Dussardier); Internal Medicine Department, Université Lille 2, CHRU de Lille, Lille, France (Dr Hatron); Radiology Department, Hôpital Ambroise Paré, Assistance Publique-Hôpitaux de Paris, Paris Ile-de-France Ouest, Université Boulogne, France (Dr Lacombe); Internal Medicine Department, Hôpital de Dijon, Dijon, France (Dr Lorcerie); Internal Medicine Department, Centre Hospitalier Universitaire, Montpellier, France (Dr Rivière); Hôpital Pontchaillou, Rennes, France (Dr Corre); Molecular Biology Laboratory, Hospices Civils de Lyon, Hôpital E. Herriot, Lyon (Dr Giraud); Biology of Cancer and Infection, INSERM, Unité 1036, Grenoble, France (Dr Bailly); and CNRS, UMR 6239, Université François Rabelais de Tours, Tours, France (Drs Paintaud and Ternant).

**Author Contributions:** Dr Dupuis-Girod had full access to all of the data in the study and takes responsibility for the integrity of the data and the accuracy of the data analysis.

**Study concept and design:** Dupuis-Girod, Ginon, Saurin, Decullier, Ternant, Faure.

**Acquisition of data:** Dupuis-Girod, Ginon, Saurin, Marion, Guillot, Carette, Gilbert-Dussardier, Hatron, Lacombe, Lorcerie, Rivière, Corre, Giraud, Ternant, Valette, Plauchu, Faure.

**Analysis and interpretation of data:** Dupuis-Girod, Ginon, Decullier, Roux, Bailly, Paintaud, Ternant, Faure.

**Drafting of the manuscript:** Dupuis-Girod, Ginon, Corre, Ternant.

**Critical revision of the manuscript for important intellectual content:** Dupuis-Girod, Ginon, Saurin, Marion, Guillot, Decullier, Roux, Carette,

Gilbert-Dussardier, Hatron, Lacombe, Lorcerie, Rivière, Giraud, Bailly, Paintaud, Ternant, Valette, Plauchu, Faure.

**Statistical analysis:** Dupuis-Girod, Decullier, Roux, Paintaud, Ternant.

**Obtained funding:** Dupuis-Girod, Hatron, Plauchu. **Administrative, technical, or material support:** Dupuis-Girod, Giraud, Paintaud, Ternant, Valette, Plauchu, Faure.

**Study supervision:** Dupuis-Girod, Ginon, Saurin, Decullier, Plauchu.

**Conflict of Interest Disclosures:** All authors have completed and submitted the ICMJE Form for Disclosure of Potential Conflicts of Interest. Dr Paintaud reported being a consultant for Laboratoires Français du Fractionnement et des Biotechnologies (LFB), Roche Pharma, Wyeth, Janssen, and Pierre-Fabre Laboratories. No other disclosures were reported.

**Funding/Support:** This work was financed by the institution (Hospices Civils de Lyon) with a grant supported by the National Research Program (PHRC 2009 and 2010) and by Roche Laboratories, which also provided the drug. Measurement of bevacizumab serum concentrations were carried out within the CePiBAC platform. CePiBAC is cofinanced by the European Union. Europe is committed to the region Centre with the European Regional Development Fund.

**Role of the Sponsor:** The funding organization (National Research Program) and Roche Laboratories had no role in the design and conduct of the study; in the collection, analysis, and interpretation of the data; or in the preparation, review, or approval of the manuscript.

**Additional Contributions:** We thank all the patients who participated in this study, the association of patients, and all the members of the French HHT Network, as well as Anne-Emmanuelle Fargeton, for their technical help. No one received compensation for the contributions.

## REFERENCES

- Shovlin CL, Guttmacher AE, Buscarini E, et al. Diagnostic criteria for hereditary hemorrhagic telangiectasia (Rendu-Osler-Weber syndrome). *Am J Med Genet.* 2000;91(1):66-67.
- Buscarini E, Danesino C, Olivieri C, et al. Doppler ultrasonographic grading of hepatic vascular malformations in hereditary hemorrhagic telangiectasia: results of extensive screening. *Ultraschall Med.* 2004;25(5):348-355.
- Buonamico P, Suppressa P, Lenato GM, et al. Liver involvement in a large cohort of patients with hereditary hemorrhagic telangiectasia: echo-color-Doppler vs multislice computed tomography study. *J Hepatol.* 2008;48(5):811-820.
- Buscarini E, Plauchu H, Garcia Tsao G, et al. Liver involvement in hereditary hemorrhagic telangiectasia: consensus recommendations. *Liver Int.* 2006;26(9):1040-1046.
- Garcia-Tsao G. Liver involvement in hereditary hemorrhagic telangiectasia (HHT). *J Hepatol.* 2007;46(3):499-507.
- Faughnan ME, Granton JT, Young LH. The pulmonary vascular complications of hereditary haemorrhagic telangiectasia. *Eur Respir J.* 2009;33(5):1186-1194.
- McAllister KA, Grogg KM, Johnson DW, et al. Endoglin, a TGF-beta binding protein of endothelial cells, is the gene for hereditary haemorrhagic telangiectasia type 1. *Nat Genet.* 1994;8(4):345-351.
- Johnson DW, Berg JN, Baldwin MA, et al. Mutations in the activin receptor-like kinase 1 gene in hereditary haemorrhagic telangiectasia type 2. *Nat Genet.* 1996;13(2):189-195.
- Gallione CJ, Repetto GM, Legius E, et al. A combined syndrome of juvenile polyposis and hereditary haemorrhagic telangiectasia associated with mutations in MADH4 (SMAD4). *Lancet.* 2004;363(9412):852-859.
- David L, Mallet C, Mazerbourg S, Feige JJ, Bailly S. Identification of BMP9 and BMP10 as functional activators of the orphan activin receptor-like kinase 1 (ALK1) in endothelial cells. *Blood.* 2007;109(5):1953-1961.
- Flieler D, Hainke S, Fischbach W. Dramatic improvement in hereditary hemorrhagic telangiectasia after treatment with the vascular endothelial growth factor (VEGF) antagonist bevacizumab. *Ann Hematol.* 2006;85(9):631-632.
- Mitchell A, Adams LA, MacQuillan G, Tibballs J, vanden Driesen R, Delriviere L. Bevacizumab reverses need for liver transplantation in hereditary hemorrhagic telangiectasia. *Liver Transpl.* 2008;14(2):210-213.
- Faughnan ME, Palda VA, Garcia-Tsao G, et al. International guidelines for the diagnosis and management of hereditary hemorrhagic telangiectasia. *J Med Genet.* 2011;48(2):73-87.
- Gehan EA. The determination of the number of patients required in a preliminary and a follow-up trial of a new chemotherapeutic agent. *J Chronic Dis.* 1961;13:346-353.
- Ware JE Jr, Sherbourne CD. The MOS 36-item short-form health survey (SF-36): I, Conceptual framework and item selection. *Med Care.* 1992;30(6):473-483.
- Ternant D, Cézé N, Lecomte T, et al. An enzyme-linked immunosorbent assay to study bevacizumab pharmacokinetics. *Ther Drug Monit.* 2010;32(5):647-652.
- Lu JF, Bruno R, Eppler S, Novotny W, Lum B, Gaudreault J. Clinical pharmacokinetics of bevacizumab in patients with solid tumors. *Cancer Chemother Pharmacol.* 2008;62(5):779-786.
- Dupuis-Girod S, Chesnais AL, Ginon I, et al. Long-term outcome of patients with hereditary hemorrhagic telangiectasia and severe hepatic involvement after orthotopic liver transplantation: a single-center study. *Liver Transpl.* 2010;16(3):340-347.
- Simonds J, Miller F, Mandel J, Davidson TM. The effect of bevacizumab (Avastin) treatment on epistaxis in hereditary hemorrhagic telangiectasia. *Laryngoscope.* 2009;119(5):988-992.
- Saif MW, Mehra R. Incidence and management of bevacizumab-related toxicities in colorectal cancer. *Expert Opin Drug Saf.* 2006;5(4):553-566.
- Traina TA, Norton L, Drucker K, Singh B. Nasal septum perforation in a bevacizumab-treated patient with metastatic breast cancer. *Oncologist.* 2006;11(10):1070-1071.
- Fakih MG, Lombardo JC. Bevacizumab-induced nasal septum perforation. *Oncologist.* 2006;11(1):85-86.
- Ruiz N, Fernandez-Martos C, Romero I, et al. Invasive fungal infection and nasal septum perforation with bevacizumab-based therapy in advanced colon cancer. *J Clin Oncol.* 2007;25(22):3376-3377.
- Pasculli G, Resta F, Guastamacchia E, Di Gennaro L, Suppressa P, Sabbà C. Health-related quality of life in a rare disease: hereditary hemorrhagic telangiectasia (HHT) or Rendu-Osler-Weber disease. *Qual Life Res.* 2004;13(10):1715-1723.
- Geisthoff UW, Heckmann K, D'Amelio R, et al. Health-related quality of life in hereditary hemorrhagic telangiectasia. *Otolaryngol Head Neck Surg.* 2007;136(5):726-733.
- Khalid SK, Pershbacher J, Makan M, Barzilai B, Goodenberger D. Worsening of nose bleeding heralds high cardiac output state in hereditary hemorrhagic telangiectasia. *Am J Med.* 2009;122(8):779.
- Hurwitz H, Fehrenbacher L, Novotny W, et al. Bevacizumab plus irinotecan, fluorouracil, and leucovorin for metastatic colorectal cancer. *N Engl J Med.* 2004;350(23):2335-2342.
- Kabbinnar FF, Hambleton J, Mass RD, Hurwitz HI, Bergsland E, Sarkar S. Combined analysis of efficacy: the addition of bevacizumab to fluorouracil/leucovorin improves survival for patients with metastatic colorectal cancer. *J Clin Oncol.* 2005;23(16):3706-3712.
- Kabbinnar FF, Schulz J, McCleod M, et al. Addition of bevacizumab to bolus fluorouracil and leucovorin in first-line metastatic colorectal cancer: results of a randomized phase II trial. *J Clin Oncol.* 2005;23(16):3697-3705.
- Lerut J, Orlando G, Adam R, et al; European Liver Transplant Association. Liver transplantation for hereditary hemorrhagic telangiectasia: report of the European liver transplant registry. *Ann Surg.* 2006;244(6):854-862.