

Supplementary Online Content

Hawass Z, Gad YZ, Ismail S, et al. Ancestry and pathology in King Tutankhamun's family. *JAMA*. 2010;303(7):638-647.

eAppendix. Details of Methods, Results, and Comment

eFigure 1. Comparison of El Amarna Art (circa 1353-1323 BC) With the Remains of Akhenaten (KV55)

eFigure 2. Variant *STEVOR* Gene Sequences Obtained From DNA Extracts of Tutankhamun

eFigure 3. Grave Goods Found in Tutankhamun's Tomb KV62

This supplemental material has been provided by the authors to give readers additional information about their work.

eAppendix. Details of Methods, Results, and Comment

METHODS

Radiology. The scanning parameters used were KV=130 effective MAS ranged from 23 to 63. Pitch ranged from 0.83 to 1.8. FOV from 350 to 500. Slice thickness 0.6 to 1.25 mm. Reconstruction 0.4 to 0.8 mm. The scan took a few minutes and produced thousands of images. The refinement process was undertaken using 3D reconstruction, real-time extraction with sagittal, coronal, and axial planes as well as oblique planes. The use of soft tissue kernel and high-resolution kernel supplemented with different ranges of window width and level followed by maximum intensity projection, multiplanner reconstruction (MIP, MPR) were carried out. In a second step, surface shaded display (SSD) with different threshold values was performed. Colored mapping of different volumes using the volume rendering technique (VRT) was also applied (**online interactive feature**).

Molecular Genetics: Good Working Practice, Data Authentication. A dedicated ancient DNA laboratory was established in the basement of the Egyptian Museum in Cairo. A second laboratory also exclusively dedicated to work with ancient DNA was established at the Faculty of Medicine, Cairo University. A subset of the data generated in the Egyptian Museum laboratory 1 was independently replicated in laboratory 2 by another research team (these data sets are indicated in the manuscript). DNA typing of all lab team members was performed (Y.Z.G., S.I., R.K., D.F., N.H., A.A., S.W., M.F.), and records were used for comparison with the data generated in our ancient DNA studies. Identical “modern-ancient” data sets were considered as nonauthentic and were omitted from our study. No contemporary unknown DNA sample was allowed in the laboratories. For each mummy, PCR experiments were repeated up to 30 times using various bone samples from different body areas (**online interactive feature**). Microsatellites were monitored for slippage, and genotypes were determined by majority rule.

Molecular Genetics: PCR, Cloning, and Sequencing. Mummies were tested for pandemic plague (Black Death, bubonic plague), tuberculosis, leprosy, leishmaniasis, and malaria. Conditions for the various test assays and primer sequences can be obtained on request from the authors. For malaria testing we applied a modification of the *STEVOR* polymerase chain reaction (PCR) protocol described by Cheng and colleagues.¹ All plasmodial gene fragments (*STEVOR*, *AMA1*, *MSPI*) were amplified in a 50- μ L PCR reaction containing 1x AmpliTaq Gold® PCR Master Mix (Applied Biosystems), 20 pmol of each primer, and aliquots of the extracted DNA. The cycling conditions using a GeneAmp® PCR System 9700 Thermocycler (Applied Biosystems) were: 94°C for 5 minutes, then 30 cycles of 94°C for 30 seconds, 66°C for 30 seconds, and 72°C for 30 seconds, followed by a final extension of 72°C for 10 minutes. If necessary, an aliquot of this PCR was transferred into a new tube and re-cycled under the following conditions: the touch-down protocol for the second round of PCR was 95°C for 5 minutes, then 5 cycles of 95°C, 62°C, 72°C at 30 seconds each, followed by 5 cycles of 95°C, 57°C, 72°C at 30 seconds each, then 25 cycles of 95°C for 30 seconds, 52°C for 15 seconds, 72°C for 30 seconds, and a final extension for 7 minutes. Alternatively, the same protocol for thermal cycling but with different reagents including 100 mM dNTPs, 0.125-0.5 μ L of Herculase® II Fusion DNA polymerase solution, and 1x PCR Buffer (Stratagene) was applied. The oligonucleotide sequences were as follows: Stevor1 5-GGGAATTCTTTATTTGATGAAGATG-3, Stevor2 5-GCATTATCATAATGATCCAGAACT-3, Stevor3 5-GTTTCCAATAATTCTTTTCTAGC-3, AMA-f 5-CCCACACCACAAGAACAAAAT-3, AMA-r1 5-CTCTTATACCTGAACCATGAAC-3, AMA-r2 5-ACTGGACATTTCCCTGATGG-3, AMA-r3 5-ATTTCCCGTAGCTACCGGTG-3, MspIMAD20-f 5-AAATGAAGGAACAAGTGGAACAGCTGTTAC-3, MspIMAD20-r 5-ATCTGAAGGATTTGTACGCTTGAATTACC-3, MspIRO33-f 5-TAAAGGATGGAGCAAATACTCAAGTTGTTG-3, MspIRO33-r 5-CATCTGAAGGATTTGCAGCACCTGGAGATC-3, MspIK1-f 5-AAATGAAGAAGAAATTACTACAAAAGGTGC-3, MspIK1-r 5-GCTTGCATCAGCTGGAGGGCTTGACCCAGA-3.

Cloning of PCR products was performed with the TOPO TA Cloning® Kit and One Shot MAX Efficiency DH5 α -T1 chemically competent *E.coli* cells according to standard protocols (Invitrogen). For colony PCR purposes we used universal primers M13 forward 5-GTAAAACGACGGCCAG-3 and reverse 5-CAGGAAACAGCTATGAC-3 (Eurofins MWG Operon).

ExoSAP-IT (USB) cleaned DNA was used for the Sanger cycle-sequencing reactions with BigDye Terminator v3.1 chemistry. Samples were run on a 3130 Genetic Analyzer (Applied Biosystems).

Molecular Genetics: Software and Databases. Database analyses were performed at the NCBI platform offering various program packages and also the plasmDB that is particularly useful for the evaluation of plasmodial sequences. The BlastN v.2.2.21+ algorithm was applied, with access to approximately 9.6 million sequences deposited in the databases GenBank, EMBL, DDBJ, and PDB. The GenoProof® software (Qualitytype AG, Dresden) was applied for determining short tandem repeat-based paternity or kinship. The software calculates the likelihood *W* based on the frequency of the zero hypothesis *x* (alleged father/mother is the child’s biological father/mother) and counter hypothesis

© 2010 American Medical Association. All rights reserved.

y (alleged father/mother is not the child's biological father/mother). GenoProof® calculates the paternity index for individual markers as well as the combined paternity index² for all examined loci as well as the paternity/maternity likelihood W. A probability of more than 99.73% is regarded as "paternity is practically proven."³

RESULTS

Kinship Analyses. The obtained short tandem repeat (STR) profiles (**Figure 1**) revealed a high degree of half-allele sharing and segregation through family generations, suggesting a close relation of all investigated mummies. To set up a multigeneration pedigree, the probabilities of each single parent to child relation and family trios (mother, father and child) were calculated by using the GenoProof® software. The statistical analysis revealed that the mummy KV55 is most probably the father of Tutankhamun (probability of 99.9999981%), and KV35 Younger Lady could be identified as his mother (99.9999997%). The testing of Amenhotep III as father of Tutankhamun and KV35 Elder Lady as putative mother were both negative owing to mismatching alleles. Amenhotep III could be clearly identified as father of KV55, showing a paternal probability of 99.9999999%. The results demonstrate that the mummy in KV55 is the son of Amenhotep III and father of Tutankhamun, leading to the assumption (also supported by the radiological findings) that the mummy can be identified as Akhenaten. It could be further shown that Tutankhamun is the most likely father of the 2 fetuses found in KV62 (Fetus 1: 99.97992885%, Fetus 2: 99.99999299%). The degree of shared alleles between the female mummy KV21A and Fetus 1 and Fetus 2 points toward a possible identification of the mummy as Ankhensnamun, the mother of both fetuses and wife of Tutankhamun. Further data are needed because the incomplete data set does not allow a clear statistical evaluation. The family pedigree was completed by the identification of KV35 Elder Lady as a daughter of Yuya and Thuya (99.99999929%), indicating that she could be Queen Tiye. This was confirmed by the calculation of the kinship of Amenhotep III and KV35 Elder Lady as father and mother of KV55, which revealed a probability of 99.99999964%. Any other hypothetical family relations such as Younger Lady as mother of KV55 were statistically withdrawn. Based on the partial Y-chromosomal information, on the amount of autosomal half-allele sharing (**Figure 1**) and family trio likelihood calculation, we reconstructed the most plausible royal pedigree. The full relationships between all mummies are shown in a 5-generation pedigree (**Figure 2**).

Gynecomastia, Feminity, and Syndromes. The right iliac bone is well preserved, the sacrum bone lacks the fifth segment, and the coccyx bone is missing as well as the ischium bones and the inferior pubic ramus at the left hip. The only feminine feature is the somewhat strong appearance of both iliac bones and the greater sciatic notch, which appears slightly pronounced. However, the ischio-pubic region, with its well preserved obturator foramen on the right side, unambiguously speaks for a male pelvis (**Figure 1D-G**). We thus cannot support a diagnosis pointing to any form of gynecomastia or feminity in the KV55 mummy.

Pathology in the Royal Mummies. All available computed tomography (CT) data of our mummies were thoroughly reexamined to collect as much data as possible on pathologies and possible indications of their individual causes of death.

A slight deformity of the spine in many of the mummies is of no clinical importance. We identified several normal anatomical variants, such as an incomplete cleft palate, a few small extra bones along the lambdoid suture (Wormian bones), and an Os tibiale externum in Tutankhamun. The brachycephalic skull in Tutankhamun appears to be a family trait and is not connected to disease such as craniosynostoses, since the study demonstrated no premature closure of cranial sutures. Furthermore, it was also not caused by an intentional, ritual deformation of the skull bones. A deformed upper left wisdom tooth lacked secondary changes. With respect to the latter findings we can see similar content of features in KV55, which underlines the very close relationship between this mummy and Tutankhamun as father and son.

Among various bony malformations (e.g., cleft palate, kyphoscoliosis, club feet, flat feet) we also found indications for bone degeneration, neoplastic changes and trauma in our collection of mummies. The various findings are listed in **Table 3**. It is evident that there is an accumulation of malformations within a few generations of the Tutankhamun lineage. Further research will show if this is suggestive of a disadvantageous genetic background resulting from interfamilial marriage in the royals. As can be seen in the genetically distant mummy control group (ie, TT320-CCG61065, TT320-CCG61066, KV60A, KV60B), there is also an obvious high frequency of disorders of the spine and feet. This makes it highly unlikely that the discussed conditions are indeed inherited.

Possible scenarios for the cause of death can be proposed for 3 of the mummies under investigation, as well as for Tutankhamun (discussed below). The head injuries of the Younger Lady in KV35 were lethal. Queen Hatshepsut (KV60A) had a metastasising malignant tumor locating to the iliac bone of the pelvis as well as a dental abscess in a terminal stage, possibly causing septicemia. The third mummy is the anonymous royal CCG61065 in TT320, which was originally thought to be Thutmose I. This 30-year-old man died as a result of an arrow wound to the chest.

Infectious Diseases: *STEVR* Data. Ten exemplary clones out of the Tutankhamun *STEVR* PCR assay were tested, and 3 different sequence variants were identified. One variant that was not found in the DNA databases contained a deletion of an adenine base within a length-polymorphic A-homopolymer-run (position 58,318 in AE014185) and a C to G transversion (position 58,380 in AE014185) (eFigure 2). The 3 best matches were obtained with AE014185, AF065200.1, and M63817.1, displaying a 98% maximum identity in a 100% query coverage (E value $2e-67$), thereby showing the 2 mismatches. Two further entries, XM_001347643.1 and AF065209.1 also reach a 100% query coverage, but only a poor maximum identity of bases of 88% (E value $9e-41$), which is reflected by a total of 18 mismatches.

Infectious Diseases: *AMA1* Data. Sequencing of the 28 cloned *AMA1* gene fragments from Tutankhamun (14 originating from the first biopsy that was already used in the *STEVR* PCRs and another 14 using a new biopsy) showed overall identity to the plasmodial reference sequence EU586508. Three single-nucleotide alterations (A>G and T>C transitions) in the clonal sequences can be attributed to the degraded condition of the old DNA. Furthermore, we also attempted amplifications of larger plasmodial PCR products (264 base pairs [bp] and larger) but found that only the smaller *AMA1* amplicons with sizes of 131 bp and 196 bp were feasible. Since the DNA was without any signs of PCR inhibition, the amplification of the failed assays may be due to the fragmented status of the ancient DNA (data not shown). The *AMA1* DNA sequences of Yuya, Thuya, and the anonymous TT320 royal deviated in each one base position compared with the plasmodial reference sequence. We found that Yuya and Thuya show ambiguous bases at positions 366 and 365, respectively. Moreover, the royal CCG61065 from TT320 showed a transversion mutation (A>C) at nucleotide position 379 of the *AMA1* gene (or position 12,941,232 in AE014186.2). This results in a triplet exchange ATA>CTA and predicts a change of the amino acid isoleucine into a leucine. Since p.I127L represents a conservative change, it is probably without gross effect in the peptide's structural integrity.

Infectious Diseases: *MSP1* Information. It is feasible to genotype the genus *Plasmodium* by exploring the different alleles of the *MSP1* gene to roughly estimate the number of individual plasmodial infections and to examine the extent of parasite genetic diversity. Based on analysis of the *MSP1* sequence diversity, this gene is divided into 17 blocks: 7 highly variable blocks are interspersed with 5 conserved and 5 semiconserved regions.⁴ The *MSP1* allelic variants fall under the 3 major types of allele families termed K1, RO33, and MAD20.^{4,5}

Infectious Diseases: *MSP1* Cloning and Database Analyses. The observed sequence diversity in the *MSP1* clones reflects the polymorphic status of the targeted *MSP1* gene fragment. Thus, we believe that differences in sequence length (up to 36 nucleotides) are not the result of hampered amplification reactions but rather are real allelic variants, since all indels can be divided by the number 3 (coding triplets); ie, the reading frame is retained.

BlastN testing of the *MSP1* MAD20 sequences in both the NCBI and the plasmODB databases revealed better matches with sequence entries derived from *P. falciparum* field isolates, and only poor E values (ie, $9e-07$, 0.006, 0.88) with the ubiquitous plasmodial 3D7 laboratory strain (NC_004326.1, AL844504.1) commonly used as experimental DNA template in laboratories that are dedicated to malaria research. Of the 4 different clonal sequence types obtained from Tutankhamun, 2 matched well ($3e-79$, $1e-98$), whereas the other 2 did not achieve a 100% identity. The best database hits using the latter 2 MAD20 sequences as the subject were with X05624.2 (E value of $1e-77$, 1 mismatch) and M32116.1 (E value of $1e-79$, 3 mismatches). Deviating base positions were 380T>C (X05624.2), and 133G>A, 144C>T, 168C>T (M32116.1). The transition changes in Tutankhamun are currently unknown in modern plasmodial DNA and are thus not represented in the actual databases.

The *MSP1* allele data of Tutankhamun were successfully replicated in the second, independently working ancient DNA laboratory. Database analysis confirmed all the established sequences of PCR products and individual clones as plasmodial sequences.

COMMENT

Kinship Determination. In 1922, Howard Carter uncovered the almost undisturbed tomb of King Tutankhamun, who ruled Egypt in the late 18th dynasty.⁶ Tutankhamun's burial trove contained more than 5000 objects, along with the mummy of the young king. However, despite this wealth of artifacts, some of which were inscribed with the names of key figures from this period, there was not enough information available to definitively confirm the identities of the pharaoh's parents.

Prime contenders for the role of Tutankhamun's father are the pharaohs Amenhotep III and Akhenaten, with a little-known king named Smenkhkare also mentioned in the literature as a possibility.^{7,8} Inscriptional evidence points most strongly to Amenhotep III as his father.^{9,10-13} However, given the length of Akhenaten's reign (17 years) and Tutankhamun's age at his coronation (about 9 years), this is only possible if Amenhotep III shared the throne with Akhenaten for at least 12 years.^{14,15} Thus, Egyptologically the most likely candidate is Akhenaten, although Smenkhkare remains a possibility.⁷

On Tutankhamun's paternal side, most Egyptologists turn to the skeletonized mummy found in tomb KV55. The hypothesis of kinship between this mummy and Tutankhamun was established in the 1960s when Harrison¹⁶ demonstrated that both share several interesting and unique anthropological features.¹⁷ This was further supported through the application of a serological micromethod, showing that the blood group of both individuals was identical.¹⁸ The identity of the KV55 mummy has been a matter of significant debate. Royal epithets inscribed on the coffin in which it was found are otherwise attested only in association with Akhenaten.⁷ However, previous radiological studies have concluded that the body is that of a man who died in his early 20s.¹⁶ This is generally thought to be too young for Akhenaten, who came to the throne as an adult and ruled for 17 years,¹⁶ so the enigmatic Smekhkare, about whom almost nothing is known,¹⁹ has been suggested as a possible alternative.^{7,12,20}

The historical identification of Tutankhamun's mother is dependent on his father. If Tutankhamun was the son of Amenhotep III, Queen Tiye is one candidate for his mother;^{10,13,21} he may also have been the child of another queen (possibilities include several of Amenhotep III's daughters).^{8,22,23} If his father were Smenkhkare, his mother was most likely Merytaten.^{8,9} An identification of Akhenaten as his father suggests as possible mothers Nefertiti,¹³ Kiya, or another royal wife.^{9,11,13,21,24-28} Other royal women mentioned in the literature as possibilities for Tutankhamun's mother are Akhenaten's sisters Nebetiah and Beketaten, and 2 of his daughters with Nefertiti, Meketaten and Meritaten.⁸

Tutankhamun was married to Ankhnesenamun, a daughter of Akhenaten and Nefertiti and possibly later the wife of Tutankhamun's successor, Ay.⁸ Prior to this study, none of the mummies discovered to date had been identified as possible candidates for the body of this queen.

In our study, a total of more than 55 bone biopsies were used to elucidate the individual relationships of the 18th-dynasty individuals. The preliminary Y-chromosome data showed identical short tandem repeat constellations in Amenhotep III, KV55, and Tutankhamun. These paleogenetic findings do not in themselves prove any relationship between the 3 individuals but do increase the probabilities that they indeed share the same paternal lineage. Control mummies examined along with those of King Tutankhamun's putative family members yielded different Y-specific alleles or no data at all in case of the negative controls (ie, female mummies). Thus, we consider our results as authentic.

Fine-analysis of the genetic relationships between the mummies was achieved by genetic fingerprint typing, thereby exploring autosomal alleles. We obtained complete fingerprint profiles of all individuals except for the KV62 fetuses and both mummies A and B from KV21, who yielded partial data sets. By evaluating the segregation of alleles through the familial generations we reconstructed the most plausible royal pedigree, a 5-generation kindred (**Figure 2**). After statistical evaluation, we conclude that Yuya and Thuya (generation I) are the parents of the KV35 Elder Lady, indicating that she is most likely Queen Tiye, the royal wife of Amenhotep III. Both Amenhotep III and the now-identified Queen Tiye are the parents (generation II) of the mummy found in KV55 and also the Younger Lady found in KV35 (generation III). Our recent anthropological analysis of the KV55 mummy showed that he was much older than previously assumed, which provided further evidence that this mummy could be the pharaoh Akhenaten. The proof that Amenhotep III and Queen Tiye are the parents of KV55, combined with this anthropological and archeological evidence, indicates that the mummy in KV55 is almost certainly Akhenaten.

The allele constellations in all short tandem repeat markers tested indicate that the KV35 Younger Lady is a full-sister of the KV55 mummy, and is unlikely to be Nefertiti or Kiya, neither of whom is attested as a daughter of Amenhotep III. This leaves Nebetiah and Beketaten, daughters of Amenhotep III not known to have married their father and who therefore might have married their brother, as the most likely candidates for the KV35 Younger Lady.

Subsequently, Akhenaten and KV35 Younger Lady are the parents of Tutankhamun. Additionally, Tutankhamun (generation IV) might be the father of the fetuses found in KV62 (generation V). However, to finalize this relationship, we would need to analyze the putative mother, Ankhnesenamun, the wife of Tutankhamun, who preliminary results suggest might be mummy KV21A (**Figure 1, Figure 2**). However, more data on KV21A (and also KV21B) are needed to confirm this proposal. Consequently, part of an ongoing project is the examination of the hypervariable region of the maternally inherited mitochondrial DNA of all mummies. This will be of particular interest to shed more light on the putative interfamilial marriages within the generations III and IV.

Disease or Amarna Artistic Style ? It has been suggested by some authors that Akhenaten and other family members may have had Marfan syndrome, a complex disorder.²⁹⁻³¹ Marfan syndrome may affect various systems, including the cardiovascular, musculoskeletal, central nervous, pulmonary, ocular, and integumentary systems. Potential cardiovascular manifestations include annuloaortic ectasia with or without aortic valve insufficiency, aortic aneurysm, aortic dissection, mitral valve prolapse, and pulmonary artery dilation. In addition, there may be a wide range of musculoskeletal manifestations, including scoliosis, chest wall deformity, arachnodactyly, dolichocephaly, and acetabular protrusion.³²⁻³⁴ Macroscopic as well as radiological inspection of all mummies revealed that they were short in stature and generally more gracile than populations today. The gracile appearance is further pronounced by the shrinking of the bodies as a result of the mummification process. Thus, it might be reasonable to add 2-3 cm to our estimated values for the individual body heights (**Table 2**). Despite the gracile appearance we could not determine arachnodactyly, an important feature in determining Marfan syndrome, in any of the mummies under investigation. We

must stress that the appearance of Madonna fingers in some of the mummies appears to be a natural variant condition in the ancient Egyptian population (**Table 2**). It is thus not considered pathological; however, it is slightly pronounced owing to shrinkage resulting from mummification.

The complex diagnosis of Marfan syndrome is based on certain combinations of major and minor clinical features described in the 1986 Berlin classification system, which was revised by expert consensus to create the 1996 Ghent classification system.³³ We note that there is a fair amount of missing morphological information due to the destruction in some mummies after removal of the linen wrappings (**Table 2**). To diagnose Marfan syndrome in an individual, the Ghent nosology for example implies that 1 main criterion must be identified in 2 different organ systems. A third system must contribute with at least a minor criterion. However, we can only evaluate 1 or 2 systems in mummies, which hampers the secure Marfan diagnosis. It is not possible to evaluate the cardiovascular, central nervous, pulmonary, ocular, and integumentary systems. Considering the features of the musculoskeletal system available in our mummies, one must define the presence of at least 4 of the following skeletal manifestations to fulfill 1 main criterion: (1) severe form of pectus carinatum, (2) severe form of pectus excavatum, (3) disproportionately long limbs (arm span > height; value larger 1.05) and digits or reduced upper-to-lower segment ratio (value <0.85), (4) scoliosis with a Cobb angle larger than 20°, (5) medial displacement of the malleolus resulting in flat feet, (6) presence of protrusio acetabuli. None of our mummies fulfills the criteria for a single main criterion. The few features observed in the mummies relating to the King Tutankhamun lineage as well as in the control cohort are somewhat evenly distributed. We also identified a typical congenital contractural arachnodactyly (CCA) sign in 2 of the mummies, namely KV35 Elder Lady (“Tutankhamun clan”) and Thutmose II (“Hatshepsut clan”), but this does not mean that they had this disorder. This feature, the crumpled helix of the ear, could have also been introduced during the mummification process post-mortem (**Table 2**).

Based on our examinations we also exclude “marfanoid” disorders such as MASS phenotype (OMIM#604308), Ehlers-Danlos syndrome (OMIM#130050), homocystinuria (OMIM+236200), CCA or Beals-Hecht syndrome (OMIM#121050), Stickler syndrome (OMIM#108300), Shprintzen-Goldberg syndrome (OMIM#182212), multiple endocrine neoplasia type 2B (OMIM#162300), and the Loeys-Dietz syndrome (OMIM#609192).

Malaria Tropica. Malaria is a disease caused by parasites of the genus *Plasmodium*. The infection is transmitted to humans through the bites of female *Anopheles* mosquitoes. Five species of *Plasmodium* protozoa are pathogenic to humans, and each leads to different clinical features: *P falciparum* causes the severe form of malaria (malaria tropica), whereas *P malariae*, *P vivax*, and *P ovale* cause less severe clinical courses of disease with the manifestations of malaria quartana (*P malariae*) and malaria tertiana (*P vivax* and *P ovale*). *Plasmodium knowlesi*—genetically close to *P vivax*—is originally a parasite of macaques; however, it can cause severe malaria in humans. Because we applied primers that are highly specific for the *P falciparum* genome, we can safely conclude that our 4 positively typed mummies (Tutankhamun, Thuya, Yuya, and the royal CCG61065 in TT320) had malaria tropica, the most severe form of malaria.

The nonspecific clinical symptoms of malaria are a consequence of the asexual reproduction of the pathogenic *Plasmodium* in its erythrocytic stage. The incipient disease manifests frequently in discomfort, loss of appetite, headache, and fever.³⁵ The disease is largely determined by the plasmodial strain and the status of the immune system of the affected individual. In case of a defective or impaired immune system, the condition of the patient worsens progressively, with symptoms such as severe chills, sweats, joint pain, headaches, spleen aches, severe fatigue, nausea, and vomiting. Particularly, malaria tropica can result in hyperlactatemia^{36,37}; hypoglycemia; acute renal damage caused by tubular necrosis³⁸; or damage of the retina, bone marrow, or heart muscle,³⁹ which often ends up being lethal. In the case of an explosive titer increase of *P falciparum*, this leads to a generalized, episodic destruction of red blood cells, with subsequent release of the cellular components in the serum. These, in conjunction with antigens of the parasite, can trigger a strong immune response in the body or may even cause a circulatory shock. The particular pathogenicity of *P falciparum* is owing to the properties of the parasite surface, which allows for the sequestration, ie, the attachment to the endothelium, of capillaries and venules.³⁸ This subsequently leads in the affected organs to a disseminated disorder of the microcirculation.⁴⁰

The most dangerous form of a *P falciparum* infection, however, is cerebral malaria.⁴¹ This leads to sequestration of parasites in the capillaries of the central nervous system and thus disorders the blood perfusion and clotting and defects the vascular permeability of the blood-brain barrier. This leads to edema in the affected areas of the brain, to infarction and hemorrhage, which can manifest clinically with fever, decreased consciousness, convulsions, coma, and finally, death.⁴²

A parasitemia of more than 500 000 parasites/μL quickly results in an extensive hemolysis. In turn, this high frequency (average parasitemia of >5 000 parasites/μL of blood)⁴³ makes the identification of pathogenic plasmodium DNA in ancient mummified tissue feasible. Moreover, the high number of genes and pseudogenes comprising the *STEVOR* multicopy gene family (similar to the mitochondrial PCR approach in paleogenetics) is another argument in

favor of this powerful PCR system for initial screening purposes. The great sensitivity and specificity of the *STEVOR* assay¹ makes it also applicable to ancient DNA.

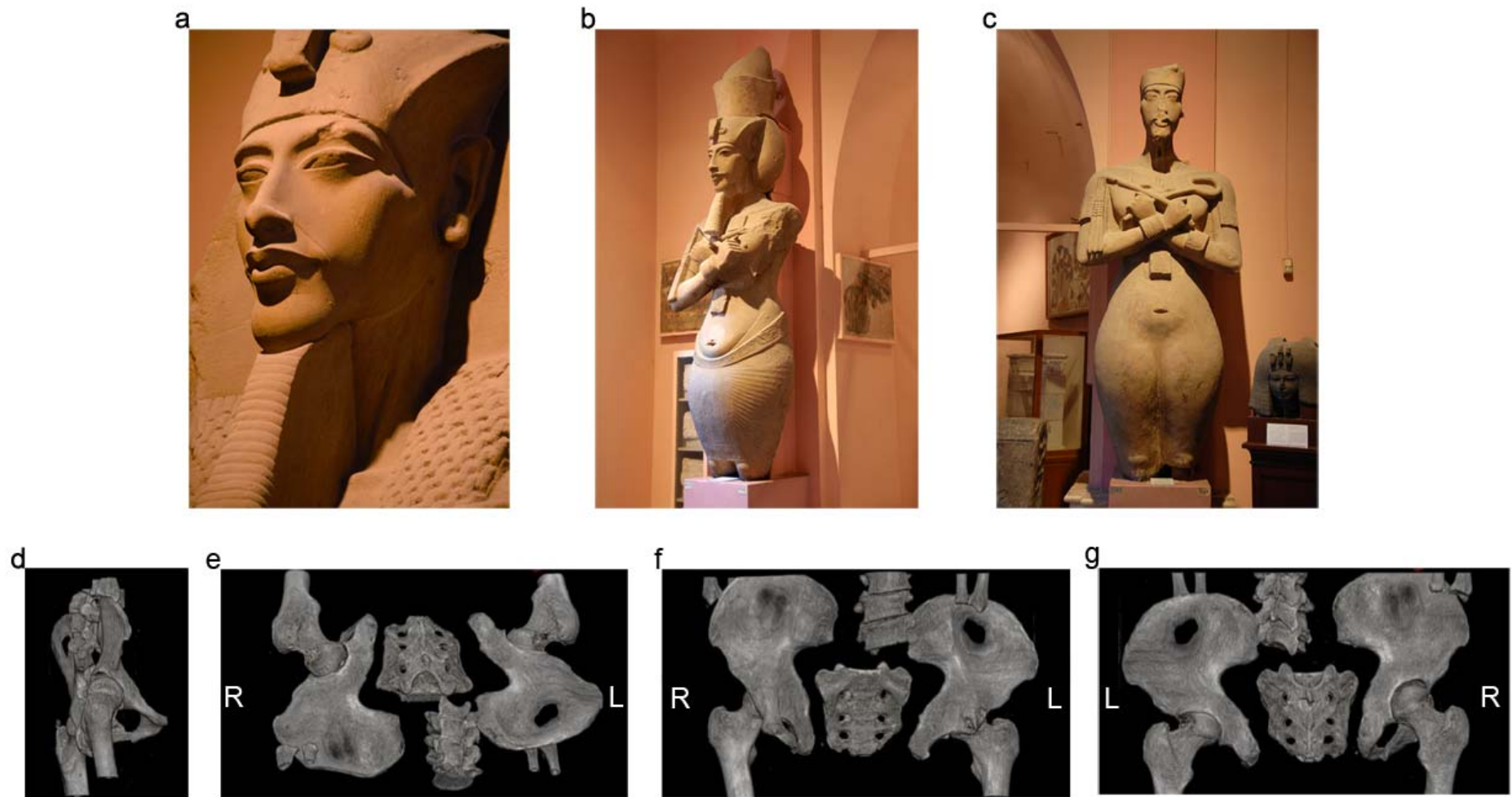
Walking Impairment and Canes. Additional evidence for Tutankhamun's diseased foot is found in a scene from an ornamented chest found in the tomb, on which the king is depicted standing with his right hand resting on a staff while Queen Ankhesenamun stands in front of him offering bouquets (**eFigure 3C**).⁴⁴ Other scenes on the same chest show the king sitting on a cushioned stool with his queen at his feet while he shoots arrows from his bow,⁴⁵ and additional scenes of this sort, with the king seated to perform sporting activities such as shooting a bow or throwing a boomerang, appear on the small golden shrine from the tomb.⁴⁵ A similar scene has recently been found on a block from the area of Memphis. Interestingly, other kings are shown standing to perform these activities; the fact that Tutankhamun is shown seated is significant and supports our conclusion of a walking impairment.

Afterlife Pharmacy. The ancient Egyptians had a rich pharmaceutical treasure that contained more than 700 drugs (see also Papyrus Ebers).⁴⁶ The ancient Egyptian doctors thought that the human body is crossed by a number of vessels in which blood, urine, semen, mucus, feces, as well as air flowed. According to their interpretation of human anatomy, the doctors believed that all diseases, even worms (eg, *Dracunculus medinensis*) in the body are caused by a blockage of these vessels.⁴⁷ Consequently, to break the blockage and cure the diseases, all kind of laxatives were frequently prescribed. In addition to the burial and cultic equipment and the furniture found in the tomb of Tutankhamun, there was also a significant quantity of comestibles. Howard Carter estimated the content of the oil store in the KV62 antechamber alone at approximately 350 L.⁴⁸ Because both malaria and the bone necrosis cause fever and pain, we now discuss medication that might have been used to fight the typical symptoms (eg, fever, ague, spleen aches, headaches, exhaustion, pain). Two kinds of natural medication were particularly frequent in the tomb: first, fruits from the nabq tree, also known as *Zizyphus spina-christi* L. Willd., were deposited in 36 baskets in the tomb (**eFigure 3D**). Primarily used as food, the fruit or its infusion were also prescribed to treat stomach complaints, fever, and pain (Bln 153 [12,12-13,3]).^{47,49} Second, 8 primary baskets containing coriander mericarps (*Coriandrum sativum* L.) were also found in KV62 (**eFigure 3E**).⁴⁸ These were applied internally against gastrointestinal complaints but also externally for treatment of suppurative wounds.⁴⁷ Interestingly, coriander was also used in recipes for the treatment of diseases that are in the head, ie, so-called demonic diseases.⁵⁰ It is subject to debate whether ague/chill appeared demonic to the ancient Egyptians. Furthermore, 4 baskets of *Cocculus* fruits (*Cocculus hirsutus* Diels) were found.⁴⁸ Since the use of the *Cocculus* bush in the African and Arabian folk medicine is still prevalent, one can imagine that this had already been used by the ancient Egyptian doctors as a treatment for fever.^{47,51,52} Furthermore, *Juniperus oxycedrus* L. (2 pure big baskets with berries)⁴⁸ has a strong diuretic effect and was also used against headaches, pain, and softening of joints (Eb 101 [24,20-25,3]).^{47,50} In addition, there were 4 baskets of raisins (dried grapes of *Vitisvinifera spec.*) and 6 baskets with dates, with stones removed, from *Phoenix dactylifera* L.. According to the Ebers papyrus, both were applied to fight pain, as exemplified in Eb 99 (24,14-24,18) and Eb 98 (24,12-24,13), Eb 101 (24,20-25,3), respectively. The latter 3 berries/fruits are also used together in a recipe that "shall remove heat [fever?] and pain in the thoracic region" (Eb 186 [35,21-36,2], see also Bln 155 [13,8-10]).

REFERENCES

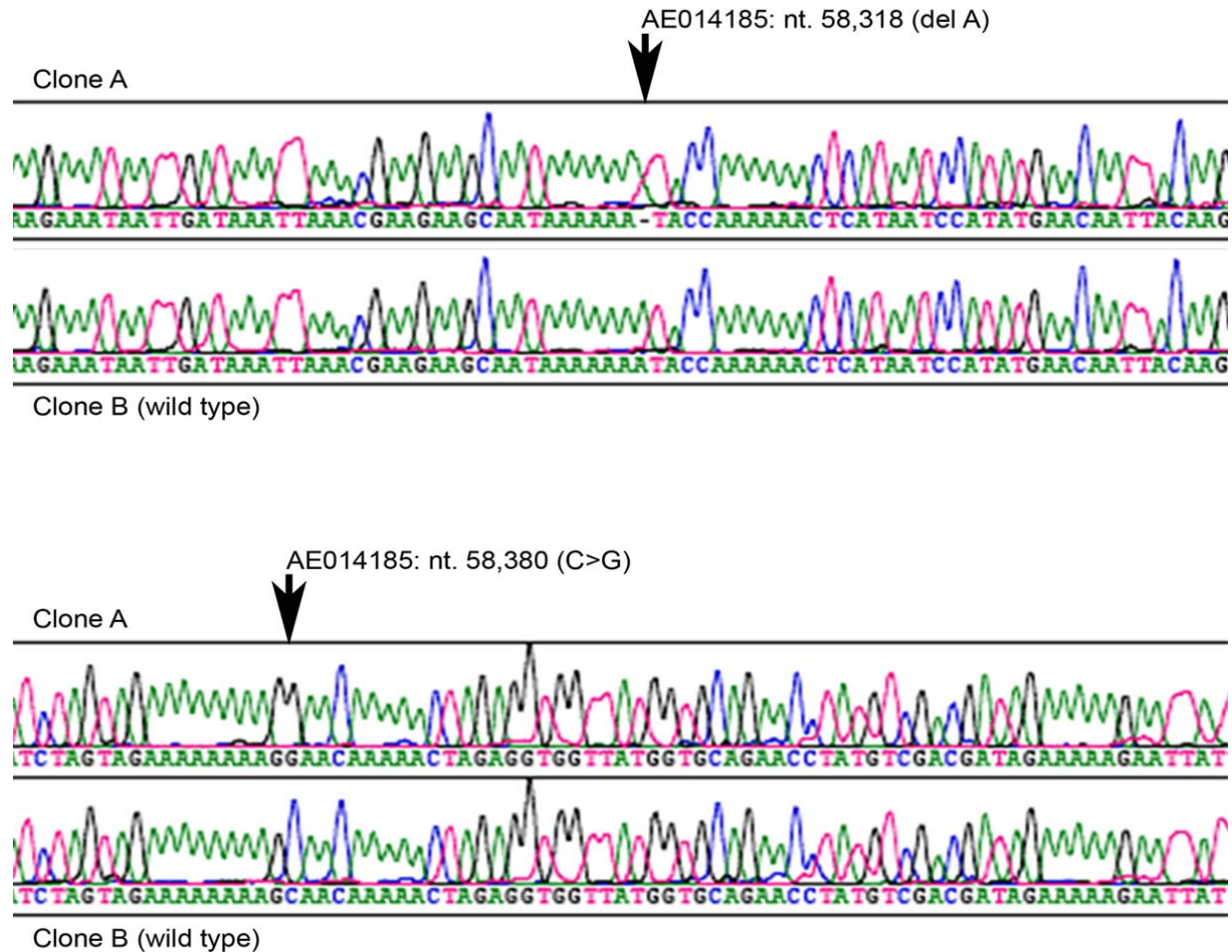
1. Cheng Q, Lawrence G, Reed C, et al. Measurement of plasmodium growth rates in vivo: a test of malaria vaccines. *Am J Trop Med Hyg.* 1997;57(4):495-500.
2. Butler JM. *Forensic DNA typing, Biology, Technology and Genetics of STR Markers*, 2nd ed. London: Elsevier Academic Press; 2005.
3. Hummel K. *Erblich-polymorphe Eigenschaften des Blutes zur Klärung strittiger Blutverwandtschaften und fraglicher Identitäten.* Verlag Dr. Kovac; 1997.
4. Kiwanuka GN. Genetic diversity in Plasmodium falciparum merozoite surface protein 1 and 2 coding genes and its implications in malaria epidemiology: a review of published studies from 1997-2007. *J Vector Borne Dis.* 2009;46(1):1-12.
5. Mlambo G, Sullivan D, Mutambu SL et al. Analysis of genetic polymorphism in select vaccine candidate antigens and microsatellite loci in Plasmodium falciparum from endemic areas at varying altitudes. *Acta Trop.* 2007;102(3):201-205.
6. Carter H, Mace AC. *The tomb of Tut-Ankh-amun.* Vol. II London: Cassell and Co.; 1927.
7. Baker D. *Encyclopedia of the Pharaohs, Volume I: Predynastic to the Twentieth Dynasty.* Cairo, American University in Cairo Press; 2008.
8. Dodson A, Hilton D. *The Complete Royal Families of Ancient Egypt.* London: Thames and Hudson; 2004.
9. Harris JE, Wente, EF. *An X-Ray Atlas of the Royal Mummies.* Chicago: University of Chicago Press; 1980.
10. Connolly RC. Kinship of Smenkhkare and Tutankhamen affirmed by serological micromethod. Microdetermination of blood group substances in ancient human tissue. *Nature.* 1969;224(5217):325.
11. Helck W. Kijê. *Mitteilungen des Deutschen Archäologischen Instituts.* 1984;40:159-167.
12. Freed RE, Markowitz YJ, D'Auria SH. *Pharaohs of the Sun: Akhenaten; Nefertiti; Tutankhamun.* London: Thames and Hudson; 1999.
13. Silverman DP, Wegner JW, Houser-Wegner J. *Akhenaten and Tutankhamun: Revolution and Restoration.* Philadelphia: University of Pennsylvania Museum Publication; 2006.
14. Dorman P. *The Temple of Soleb: A Final Word on the Coregency.* The 59th Annual Meeting of the American Research Center in Egypt, Grand Hyatt Seattle: Seattle, WA, Apr 25; 2008.
15. Murnane WJ. *Ancient Egyptian Coregencies.* Chicago: University of Chicago Press; 1977.
16. Harrison RG. An anatomical examination of the Pharaonic remains purported to be Akhenaten. *J Egypt Arch.* 1966;52:95-119.
17. Desroches-Noblecourt C. *Tutankhamen.* London: Michael Joseph Ltd.; 1963.
18. Harrison RG, Connolly RC, Abdalla A. Kinship of Smenkhkare and Tutankhamun demonstrated serologically. *Nature.* 1969;224(5217):325-326.
19. Dodson A. Were Nefertiti and Tutankhamen Coregents? *KMT.* 2009;20(3):41-49.
20. Redford DB. *Oxford Encyclopedia of Ancient Egypt.* Vol. I Cairo: American University in Cairo Press; 2001.
21. Kozloff A, Bryan, BM. *Egypt's Dazzling Sun: Amenhotep III and his World.* Cleveland, Cleveland Museum of Art and Indiana University Press; 1992.
22. Redford DB. Once again the filiation of Tutankhamun. *Journal of the Society of the Study of Egyptian Antiquities.* 1978/1979;9:107-115.
23. Redford DB. *Akhenaten: The Heretic King.* Princeton: Princeton University Press; 1984.
24. Martin GT. *The Royal Tomb at El-'Amarna.* Vol. 2 London: Egypt Exploration Society; 1989.
25. Reeves N. *The Complete Tutankhamun: The King, the Tomb, the Royal Treasure.* London and New York: Thames and Hudson; 1990.
26. Arnold D. *The Royal Women of Amarna: Images of Beauty from Ancient Egypt.* New York: The Metropolitan Museum of Art; 1996.
27. Reeves N, Wilkinson R. *The Complete Valley of the Kings.* Cairo, American University in Cairo Press; 1996.
28. Thomas AP. The other women at Akhetaten, Royal Wife Kiya. *Amarna Letters.* 1994;3: 72-81.
29. Paulshock BZ. Tutankhamun and his brothers. Familial gynecomastia in the Eighteenth Dynasty. *JAMA.* 1980;244(2):160-164.
30. Braverman IM, Redford DB, Mackowiak PA. Akhenaten and the strange physiques of Egypt's 18th dynasty. *Ann Intern Med.* 2009;150(8):556-560.
31. Farag TI, Iskandar A. Tutankhamun's paternity. *J R Soc Med.* 1998;91(5):291-292.
32. Pyeritz RE, McKusick VA. The Marfan syndrome: diagnosis and management. *N Engl J Med.* 1979;300(14):772-777.
33. De Paepe A, Devereux RB, Dietz HC, Hennekam RC, Pyeritz RE. Revised diagnostic criteria for the Marfan syndrome. *Am J Med Genet.* 1996;62(4):417-426.
34. Wilner HI, Finby N. Skeletal manifestations in the Marfan syndrome. *JAMA.* 1964;187:490-495.

35. Sherman IW. *Malaria: Parasite Biology, Pathogenesis, and Protection*. Washington DC: ASM Press; 1998.
36. Agbenyega T, Angus BJ, Bedu-Addo G, Baffoe-Bonnie B, Guyton T, Stacpoole PW, Krishna S. Glucose and lactate kinetics in children with severe malaria. *J Clin Endocrinol Metab*. 2000;85(4):1569-1576.
37. Day NP, Phu NH, Mai NT, et al. The pathophysiologic and prognostic significance of acidosis in severe adult malaria. *Crit Care Med*. 2000;28(2):1833-1840.
38. Mehta KS, Halankar AR, Makawana PD, Torane PP, Satija PS, Shav VB. Severe acute renal failure in malaria. *J Postgrad Med*. 2001;47(1):24-26.
39. Kumar A, Haery C, Parrillo JE. Myocardial dysfunction in septic shock: part I clinical manifestation of cardiovascular dysfunction. *J Cardiothorac Vasc Anesth*. 2001;15(4):485-511.
40. Dondorp AM, Kager PA, Vreeken J, White NJ. Abnormal blood flow and red blood cell deformability in severe malaria. *Parasitol Today*. 2000;16(6):228-232.
41. Aikawa M, Iseki M, Barnwell JW, Taylor D, Oo MM, Howard RJ. The pathology of human cerebral malaria. *Am J Trop Med Hyg*. 1990;43(2):30-37.
42. WHO: Warrell DA, Molyneux ME, Beales PF. Severe and complicated malaria. *Trans R Soc Trop Med Hyg*. 1990;84(2):1-65.
43. Ntoumi F, Ngoundou-Landji J, Lekoulou F, Luty A, Deloron P, Ringwald P. Site-based study on polymorphism of Plasmodium falciparum MSP-1 and MSP-2 genes in isolates from two villages in Central Africa. *Parassitologia*. 2000;42(3-4):197-203.
44. Saleh M, Sourouzi H. *Official Catalogue of the Egyptian Museum, Cairo*. Mainz: Verlag Philipp von Zabern. Carter 540, Carter 551, cat. no. 188; 1987.
45. Saleh M, Sourouzi H. *Official Catalogue of the Egyptian Museum, Cairo*. Mainz: Verlag Philipp von Zabern. Carter 108, cat. no. 178; 1987.
46. Diener H. *Fachlexikon ABC Arzneipflanzen und Drogen*. Frankfurt am Main: 1st ed. Verlag Harri Deutsch Thun; 1986.
47. Germer R. *Die Heilpflanzen der Ägypter*. Düsseldorf; Zürich: Artemis und Winkler, 2002.
48. Germer R. *Die Pflanzenmaterialien aus dem Grab des Tutanchamun*. Hildesheim: Hildesheimer ägyptologische Beiträge; 1989.
49. Germer R. *Handbuch der altägyptischen Pflanzen. Philippika, Marburger altertumskundliche Abhandlungen 21*. Wiesbaden: Harrassowitz Verlag; 2008.
50. Westendorf W. *Erwachen der Heilkunst: die Medizin im alten Ägypten*. Zürich: Artemis Verlag AG; 1992.
51. Neuwinger HD. *African traditional Medicine: a Dictionary of Plant Use and Applications*. Stuttgart: Medpharm Scientific; 2000.
52. Ghazanfar SA. *Handbook of Arabian medicinal Plants*. Boca Raton: CRC Press; 1994.




eFigure 1. Comparison of El Amarna Art (circa 1353-1323 BC) With the Remains of Akhenaten (KV55)

a) JE49528, colossal statue that once lined a colonnade in the Precinct of the Aten at Karnak temple, 18th dynasty, reign of Akhenaten. b) JE49529, colossus of Akhenaten, Karnak, Precinct of the Aten, 18th dynasty, reign of Akhenaten. The king wears a pleated kilt that hangs low on a swollen belly and wears a double crown that symbolizes dominion over Upper and Lower Egypt. c) JE55938, colossus from Karnak, precinct of the Aten, 18th dynasty, reign of Akhenaten. The body appears not clearly male and has thus raised controversy; it has also been suggested that it represents Nefertiti. d-g) Four projections of the KV55 pelvis, profile view, tilted pelvis with view from above, anterior-posterior, posterior-anterior.



eFigure 1. Variant *STEVOR* Gene Sequences Obtained From DNA Extracts of Tutankhamun
 Sequence electropherograms of 2 clones are shown; one with “delA” and “C>G” alterations and one representing the wild-type sequence.



eFigure 3. Grave Goods Found in Tutankhamun's Tomb KV62

a) Vitrine displaying some of the pharaoh's walking sticks in the Egyptian Museum in Cairo. b) Exemplary cane made of ebony and gold with a size of 155.8 cm, showing explicit signs of wear at the bottom part. Stick imitating reed with gilt ends. (JE 61729) Section/serial number: SR 1/789. c) Relief in KV62. Private illustration showing the king essentially resting on a cane while he is accompanied by his wife Ankhesenamun. d) Mericarps of *Coriandrum sativum* (repository ID 2793) possibly applied to cure the body. e) Fruits of *Zizyphus spina-christi* (repository ID 2790) possibly used as drug components to fight pain and fever.