

Leg Ulcers and Hydroxyurea

Forty-one Cases

Marie-Emmanuelle Sirieix, MD; C. Debure, MD; N. Baudot, MD; L. Dubertret, MD; M.-E. Roux, MD; P. Morel, MD; C. Frances, MD; S. Loubeyres, MD; C. Beylot, MD; D. Lambert, MD; P. Humbert, MD; O. Gauthier, MD; M. Dandurand, MD; B. Guillot, MD; L. Vaillant, MD; G. Lorette, MD; J.-M. Bonnetblanc, MD; C. Lok, MD; J.-P. Denoeux, MD

Background: Hydroxyurea is an antitumor agent used to treat chronic myeloproliferative disorders. Leg ulcerations have been reported in patients undergoing long-term hydroxyurea therapy for myeloproliferative diseases. To better define this dermatological adverse effect of hydroxyurea therapy and to try to understand the pathophysiological process of this disease, we collected medical information for such patients in a multicenter retrospective study.

Observations: Forty-one patients (mean age, 67 years) developed leg ulcerations while undergoing hydroxyurea therapy (mean therapy duration, 5 years). The sex ratio was 1, and there was no underlying vascular disease. Hematologic abnormalities were identified. Com-

plete recovery from the ulcerations occurred quickly after withdrawal of treatment in 33 (80%) of the cases.

Conclusions: This longest-reported series of patients confirms the role of hydroxyurea therapy in the onset of leg ulcerations. Healing or improvement requires cessation of treatment. Cutaneous atrophy and impaired wound healing may explain the relationship between hydroxyurea and leg ulcers. In addition, the megaloblastic erythrocytes resulting from the presence of hydroxyurea may circulate poorly through the capillary network. A prospective study in hematologic centers would be valuable.

Arch Dermatol. 1999;135:818-820

From *Rééducation Vasculaire, Hôpital Broussais (Drs Sirieix and Debure), Dermatologie, Hôpital Saint-Louis (Drs Baudot, Dubertret, Roux, and Morel), and Médecine Interne, Hôpital Pitié-Salpêtrière (Dr Frances) Paris; Dermatologie, Hôpital du Haut-Lévêque, Pessac (Drs Loubeyres and Beylot); Dermatologie, Hôpital du Bocage, Dijon (Dr Lambert); Dermatologie, Hôpital Saint-Jacques, Besançon (Dr Humbert); Dermatologie, Hôpital Robert Boulin, Libourne (Dr Gauthier); Dermatologie, Hôpital Caremeau, Nîmes (Drs Dandurand and Guillot); Dermatologie, Hôpital Trousseau, Tours (Drs Vaillant and Lorette); Dermatologie, Hôpital Dupuytren, Limoges (Dr Bonnetblanc); and Dermatologie, Hôpital Sud, Amiens (Drs Lok and Denoeux), France.*

HYDROXYUREA is a cytostatic agent that acts during cellular replication (S phase)¹ and inhibits DNA synthesis but does not affect RNA synthesis. It has been used for almost 40 years and is considered the drug of choice for treatment of chronic myeloproliferative diseases. The most common hematologic adverse effects are changes in megaloblastic erythrocytes, which are, however, benign and do not require that medication be discontinued.¹

The dermatological adverse effects have been well documented. These include xerosis, diffuse hyperpigmentation, brown-nail discoloration, stomatitis, erythema, and scaling of the face, hands, and feet (dermatomyositis-like eruptions).²⁻⁶ In the last 20 years, only a small number of patients with cutaneous ulcerations have been reported.⁷⁻¹⁰ In this study we describe a series of 41 patients who developed leg ulcers during hydroxyurea therapy.

during hydroxyurea therapy between 1986 and 1996. The mean age of the patients at diagnosis was 67 years (age range, 38-90 years). The sex ratio was 1 (21 men). Hydroxyurea was administered to treat essential thrombocythemia (16 patients), chronic myelogenous leukemia (16 patients), polycythemia vera (7 patients), chronic lymphocytic leukemia (1 patient), and myeloid splenomegaly (1 patient). The mean duration of hydroxyurea therapy was 5 years (range, 6 months to 13 years). The mean duration of leg ulcers before withdrawal of hydroxyurea therapy was 10 months (range, 1-48 months). One patient had diabetes mellitus and 13 (31%) had vascular hypertension. Vascular studies showed associated arteriopathy in 3 patients (7%): 1, asymptomatic distal arteriopathy and 2, intermittent claudication. Venous insufficiency was also recorded: 7 patients (17%) had varicose veins and 4 patients (10%) had a history of thrombotic disease.

In 29 patients (70%) it was the first episode of cutaneous ulceration of the lower limbs. The leg ulcer was located close to the malleoli in half of the patients, or on the calf and foot (dorsal part and toes).

RESULTS

Twelve centers sent medical records for 41 patients who suffered from leg ulceration

PATIENTS AND METHODS

We performed a multicenter retrospective study to investigate the incidence of leg ulcers among patients treated with hydroxyurea for myeloproliferative disorders. The aim was to better define this adverse effect of hydroxyurea therapy and to understand the pathophysiological process of this disease. A medical questionnaire was sent to French dermatological centers. The inclusion criteria screened for patients taking hydroxyurea who concomitantly developed leg ulcers that were not responsive to standard wound care (topical wound dressings, manual debridement, compression bandaging, bed rest, and systemic antibiotic therapy), which led to discontinuation of therapy. The history of leg ulcers, hematologic disease, vascular risk factors, and vascular status (results of physical examination and, if abnormal, ultrasound data) were recorded.

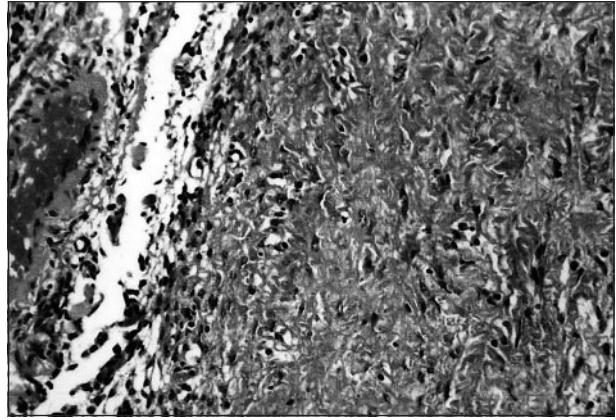
Multiple ulcers occurred in 25 (60%) of the patients. All cutaneous ulcerations were painful and fibrous, and in 10 cases (25%) were necrotic. The periulcerous skin was thin and atrophic with purpura in 2 cases.

Biopsy specimens were taken from 11 patients. Histopathologic findings showed epidermal atrophy, dermal fibrosis, and scar tissue without vascular lesion (**Figure**). In 1 case a few small capillaries were occluded, as in livedoid vasculitis, but direct immunofluorescence staining findings were negative. In another case there were fibrinoid deposits in the dermis with extravasation of red blood cells and leukocytoclastic vasculitis.

Twenty-four patients (58%) had other dermatological adverse effects: 11 experienced dermatomyositis-like eruptions; 5, brown-nail discoloration; 4, melanodermy; 3, cutaneous atrophy; and 1, livedoid lesions of the hands.

The leg ulcers quickly healed or improved after discontinuation of hydroxyurea therapy. Thirty-three patients (80%) completely recovered from their cutaneous ulcerations in a mean of 3 months (range, 1-24 months). In the 8 remaining patients there was an improvement and a reduction in the ulceration size. Four of these 8 patients were examined 1 month after discontinuation of hydroxyurea treatment. The other 4 had no underlying arterial disease. One had left popliteal venous thrombosis sequelae, but ulcerations were present on both legs. There was no relation between the size of the ulcerations and total exposure of the patients to hydroxyurea. Hydroxyurea therapy was never resumed.

Normal blood cell counts during hydroxyurea therapy were associated with good remission of the hematologic disease (no thrombocytosis or polycythemia). After discontinuation of hydroxyurea treatment and replacement with another type of chemotherapy, usually pipobroman, there was a change in blood dyscrasia with an increase in red blood cell count. Concurrently, however, there was a decrease in mean globular volume from $121 \mu\text{m}^3$ to $110 \mu\text{m}^3$ over 1 month. No recurrent



Skin biopsy specimen from a typical hydroxyurea-induced ulcer. Note the presence of fibrosclerosis of the dermis without an inflammatory reaction. Also note the lack of specific changes.

ulcers or other hematologic adverse effects were observed once treatment was adjusted.

COMMENT

The dermatological characteristics of hydroxyurea-related leg ulcers were similar to those previously described: painful, fibrous, persistent ulcers with atrophic periulcerous skin.⁷⁻¹⁰ Necrosis was seen in only 25% of cases, sometimes with a periulcerous purpura (2 cases). This incidence is much lower than in previous reports.^{3,5,6} Necrosis and periulcerous purpura are typical of livedoid vasculitis, but there is no difference in the evolution. The location of the ulcers was often near the malleoli or the tibial crest, suggesting a posttraumatic origin.

The clinical course was similar to that described in other reports: a long duration of hydroxyurea treatment (mean duration, 5 years), a first episode of multiple ulcers in 23 cases (70%), a long duration of ulcer disease despite meticulous wound care (mean duration, 10 months), a complete healing in 33 cases (80%) (mean time to healing, 3 months), and a marked improvement in the ulcers after discontinuation of hydroxyurea therapy.

In agreement with the findings of Montefusco et al⁷ and Nguyen and Margolis,⁸ there was no major vascular disease (diabetes mellitus or venous or arterial insufficiency) that could account for the presence of persistent ulcers in this elderly population. Leg ulcer biopsy specimens were taken in 11 cases. Histopathologic findings showed no specific change, which is similar to previous reports.^{7,8,10} There was no lichenoid tissue reaction but rather an epidermal atrophy. The dermal tissue was sclerotic without inflammatory reaction. At the time the skin lesions developed, the myeloproliferative disorder was well controlled with hydroxyurea therapy: platelet or red blood cell counts were in the normal range. Contrary to the findings of Wirth et al,¹¹ leg ulcerations disappeared after cessation of hydroxyurea therapy and, paradoxically, there was an underlying blood dyscrasia parallel with thrombocytosis or polycythemia. Leg ulcers healed when blood dyscrasia appeared. Thus, hyperviscosity resulting from the myeloproliferative disorder could be ruled out as a contributor to these ulcers.

The major pathogenic mechanism responsible for production of cutaneous ulcers is direct cytologic damage. Hydroxyurea selectively kills cells during the synthesis phase of the cell cycle, without affecting RNA production.¹ Basal keratinocytes and collagen synthesis could therefore be damaged.^{7,10} This could also explain the other dermatological adverse effects observed in 24 (58%) of the patients. Patients were exposed to hydroxyurea therapy for long periods (a mean of 5 years in our study), suggesting a cumulative toxic dose. Nguyen and Margolis⁸ proposed that cutaneous atrophy induced by hydroxyurea, followed by minor trauma and impaired wound healing, could lead to ulcer formation. Those authors limited hydroxyurea therapy and noticed an improvement in 4 cases. Unfortunately, limiting therapy adversely affects the control of the hematologic disease, and by increasing hyperviscosity it also increases the risk that ulceration will occur. Resuming hydroxyurea treatment led to a recurrence of ulceration.¹⁰

The main adverse effect of hydroxyurea therapy is hematologic toxic effects. Red blood cell, leukocyte, and platelet counts can be lowered. Inhibition of DNA synthesis without modification of RNA synthesis can cause red blood cells to become megaloblastic. Large erythrocytes are seen within 24 hours after the start of therapy and then return to normal shape a few weeks after chemotherapy is discontinued.¹² An increase in mean corpuscular volume during hydroxyurea treatment could affect the susceptibility to deformation and the adherence of red blood cells.

Gilbert et al¹³ measured a decrease in red blood cell susceptibility to deformation in patients with myeloproliferative disorders treated with hydroxyurea. Engström and Löfvenberg¹⁴ recently studied the effects of treatment of myeloproliferative disorders with hydroxyurea on red blood cell geometry and deformability. They confirmed a large increase in cell volume (39%). This change resulted in a 12% increase in the minimum cell diameter. These changes in size did not affect cell deformability in a static red blood cell-bending model and in a red blood cell-filterability model with a 5- μ m-pore membrane. However, there was a significantly increased filtration resistance with a 3- μ m-pore membrane. Most other filtration studies were performed with a 3- μ m nickel-mesh system.¹⁵ Reduced red blood cell susceptibility to deformation may impair blood flow in the microcirculation. Thus, hydroxyurea could induce a cutaneous anoxia leading to cutaneous ulceration after a minor trauma. The fact that wounds heal quickly following cessation of treatment with concurrent return to normal of the mean corpuscular volume supports this hypothesis. The very painful aspect of these ulcers also suggests an anoxic mechanism, as in arterial ulcers.

This extensive assessment of ulcers arising from hydroxyurea therapy (41 cases) confirms the findings of pre-

vious studies. We observed a typical clinical pattern that was not associated with vascular disease. In this elderly population, the loss of autonomy and the requirement for administration of analgesic drugs with secondary central nervous system effects make leg ulcerations a very disabling disease. Good recovery occurs after discontinuation of hydroxyurea treatment. Thus, a replacement therapy should be considered. These conclusions need to be confirmed by a prospective study in hematologic centers to determine the prevalence of this disease among patients treated with hydroxyurea.

Accepted for publication April 1, 1999.

This study was supported in part by the Centre de Recherches sur les Maladies Vasculaires Périphériques Association Claude Bernard, Paris, France.

Reprints: Marie-Emmanuelle Sirieix, MD, Service de Rééducation Vasculaire, Hôpital Broussais, 96 Rue Didot, 75674 Paris, Cedex 14, France (e-mail: marie-emmanuelle.sirieix-h@brs.ap-hop-paris.fr).

REFERENCES

1. Boyd AS, Neldner KH. Hydroxyurea therapy. *J Am Acad Dermatol.* 1991;25: 518-524.
2. Renfro L, Kamino H, Raphael B, Moy J, Sanchez M. Ulcerative lichen planus-like dermatitis associated with hydroxyurea. *J Am Acad Dermatol.* 1991;24:143-145.
3. Senet P, Aractingi S, Porneuf M, Perrin P, Duterque M. Hydroxyurea-induced dermatomyositis-like eruption. *Br J Dermatol.* 1995;133:455-459.
4. Daoud MS, Gibson LE, Pittelkow MR. Hydroxyurea dermatopathy: a unique lichenoid eruption complicating long-term therapy with hydroxyurea. *J Am Acad Dermatol.* 1997;36:178-182.
5. Michel JL, Perrot JL, Thomas L, et al. Complications cutanées de l'hydroxyurée: 17 cas. *Ann Dermatol Venerol.* 1996;123(suppl 1):127-128.
6. Sigal M, Crickx B, Blanchet P, Perron J, Simony J, Belaïch S. Lésions cutanées induites par l'utilisation au long cours de l'hydroxyurée. *Ann Dermatol Venerol.* 1984;111:895-900.
7. Montefusco E, Aiimena G, Gastaldi R, Carlesimo OA, Valesini G, Mandelli G. Unusual dermatologic toxicity of long term therapy with hydroxyurea in chronic myelogenous leukemia. *Tumori.* 1986;72:317-321.
8. Nguyen TV, Margolis DJ. Hydroxyurea and lower leg ulcers. *Cutis.* 1993;52:217-219.
9. Esteve E, Roger M, Nguyen P, Kallis B. Cas pour diagnostic. *Ann Dermatol Venerol.* 1996;123:271-272.
10. Best PJ, Daoud MS, Pittelkow MR, Petit RM. Hydroxyurea-induced leg ulceration in 14 patients. *Ann Intern Med.* 1998;128:29-32.
11. Wirth K, Schoepf E, Mertelsmann R, Lindemann A. Leg ulceration with associated thrombocytosis: healing of ulceration associated with treatment of the raised platelet count. *Br J Dermatol.* 1998;138:533-535.
12. Babior BM. Erythrocyte disorders: anemia related to disturbance of DNA synthesis (megaloblastic anemias). In: Williams WJ, Buetler E, Ersley AJ, Lichtman MA, eds. *Hematology.* 4th ed. New York, NY: McGraw-Hill Book Co; 1990:467.
13. Gilbert HS, Stump DD, Roth EF. Hydroxyurea-associated reduction of red cell deformability [abstract]. *Clin Res.* 1985;33:546A.
14. Engström KG, Löfvenberg E. Treatment of myeloproliferative disorders with hydroxyurea: effects on red blood cell geometry and deformability. *Blood.* 1998; 91:3986-3991.
15. Rodgers GP, Dover GJ, Uyesaka N, Noguchi CT, Schechter AN, Nienhuis AW. Augmentation by erythropoietin of the fetal-hemoglobin response to hydroxyurea in sickle cell disease. *N Engl J Med.* 1993;328:73-80.

Archives Web Forum

Want to discuss this article with the authors and your colleagues? Then take part in the Archives of Dermatology's new World Wide Web forum. For details, see the ARCHIVES' Web site at <http://www.ama-assn.org/derm>.