

Outbreak of *Pseudomonas aeruginosa* Infections Caused by Commercial Piercing of Upper Ear Cartilage

William E. Keene, PhD, MPH

Amy C. Markum, RN, BSN

Mansour Samadpour, PhD

ALTHOUGH POPULATION-based data are scant, ear and body piercing appears to be increasingly popular.^{1,2} Ear piercing in particular is often performed in an unregulated or loosely regulated environment¹ by people with uncertain infection control skills. Although the results are usually benign, ear piercing can lead to serious infections.³⁻⁹

In September 2000, an otolaryngologist in Klamath Falls, Oregon, was consulted about a teenager with a suppurating ear infection. The patient was admitted for surgery. The day before onset, the girl's ear had been pierced at a jewelry kiosk. The previous day, the same physician had seen an outpatient with a similar infection and a similar history of piercing at the same kiosk. Both patients were pierced in upper ear cartilage; both wound cultures yielded *Pseudomonas aeruginosa*.

The physician alerted the local health department, noting that in 20 years of practice he had never seen this kind of infection. His report prompted our investigation, which identified an ongoing common-source outbreak of disfiguring upper ear infections.

See also Patient Page.

Context Sporadic infections following ear piercing are well documented, but common-source outbreaks are rarely recognized.

Objective To investigate reports of auricular chondritis subsequent to commercial ear piercing.

Design, Setting, and Subjects Outbreak investigation by Oregon public health agencies, including cohort study of persons pierced at a jewelry kiosk in August-September 2000, environmental sampling, and molecular subtyping of isolates. Confirmed cases had *Pseudomonas aeruginosa* cultured from ear wounds. Suspected cases had signs and symptoms of external ear infection, including drainage of pus or blood for at least 14 days.

Main Outcome Measures Risk factors for infection and comparison of bacterial isolates by molecular subtyping.

Results From 186 piercings in 118 individuals, we identified 7 confirmed *P aeruginosa* infections and 18 suspected infections. Confirmed cases were 10 to 19 years old. Most were initially treated with antibiotics ineffective against *Pseudomonas*. Four were hospitalized, 4 underwent incision and drainage surgeries (1 as an outpatient), and several were cosmetically deformed. Upper ear cartilage piercing was more likely to result in either confirmed or suspected infection than was lobe piercing (confirmed: RR undefined, $P < .001$; suspected: RR, 3.6; 95% confidence interval, 1.5-8.5). All persons with confirmed infections had their ear cartilage pierced with an open, spring-loaded piercing gun. Patient isolates were indistinguishable by molecular subtyping, and matching isolates were recovered from a disinfectant bottle and nearby sink. At least 1 worker admitted sometimes spraying the disinfectant on the ear studs before piercing.

Conclusions Ear cartilage piercing is inherently more risky than lobe piercing. Clinicians should respond aggressively to potential auricular chondritis and consider *Pseudomonas* a possible cause pending culture results.

JAMA. 2004;291:981-985

www.jama.com

METHODS

Body and ear piercing businesses are regulated in Oregon, and state licensing agency representatives provided information about the industry and implicated kiosk. The kiosk was staffed by the owner or 1 of 3 employees. We reviewed previous inspection reports and, with a state inspector, conducted an

Author Affiliations: Acute & Communicable Disease Program, Oregon Department of Human Services, Portland (Dr Keene); Klamath County Department of Public Health, Klamath Falls, Ore (Ms Markum); and Department of Environmental Health, University of Washington School of Public Health, Seattle (Dr Samadpour). Dr Samadpour is now with the Institute for Environmental Health, Seattle.

Corresponding Author: William E. Keene, PhD, MPH, Acute & Communicable Disease Program, Oregon Department of Human Services, 800 NE Oregon St, Suite 772, Portland, OR 97232 (william.e.keene@state.or.us).

initial visit on September 15, 2000. The owner agreed to suspend ear piercing pending our investigation.

We conducted active surveillance at local medical facilities. Using the kiosk's records, we reconstructed an arbitrary cohort of customers whose ears were pierced from August 1 through September 15, 2000, and interviewed them using a standardized questionnaire. Persons with active infections were seen and referred for medical care as indicated. Pus or wound swabs were cultured for *Pseudomonas*. We issued a press release to encourage medical evaluation of active infections and to enhance case finding.

We defined confirmed infections among cohort members as any infection at the piercing site that developed within 2 weeks of piercing from which *P aeruginosa* was cultured. Suspected infections were marked by induration or erythema at the piercing site; local pain or tenderness; and drainage of blood or pus lasting at least 14 days. We excluded persons reporting minor problems not meeting either definition (eg, <14 days of drainage) or whose piercing location could not be definitely classified as lobe or cartilage.

We reviewed procedures and work schedules with the kiosk staff. We collected environmental samples in and around the kiosk. Solid surfaces, including countertops, plumbing fixtures, and ear-piercing guns, were wiped with saline-moistened swabs. Disinfectant solutions were collected into sterile containers. Tap water and sink aerators were collected into 1% sodium thiosulfate solutions to neutralize chlorine. Kiosk workers were screened for *Pseudomonas* by stool and hand cultures. For the latter, workers donned sterile gloves into which we poured approximately 50 mL of warmed sterile saline solution. After 5 minutes of finger agitation, the gloves were removed and the solution was decanted into sterile containers. Samples were enriched in brain-heart infusion broth, plated onto membrane-filtration *P aeruginosa* agar and cetrinide agar, and cultured for *Pseudomonas* by standard methods. For comparison pur-

poses, the local hospital laboratory saved all *P aeruginosa* isolates obtained from non-outbreak-associated patients during the next 3 months.

For microrestriction fingerprinting (MRF), DNA was extracted from *Pseudomonas* isolates grown overnight on tryptic soy agar as previously described.¹⁰ Ten to twenty microliters (approximately 1.5 µg/µL) of the DNA preparations was digested with *NcrI* (American Allied Biochemical, Aurora, Colorado). DNA fragments were electrophoretically separated on 15 × 20-cm agarose gels in Tris-borate EDTA (17 hours at 70 V). Antibio-

grams for patient isolates were abstracted from laboratory records. To gauge the frequency of auricular chondritis subsequent to ear piercing, in 2002 we mailed all otolaryngologists licensed in Oregon (outside Klamath County) a brief questionnaire, including case photographs, asking how many patients with piercing-related chondritis they had seen during the past year and cumulatively during earlier years in practice. Follow-up telephone calls were made to nonrespondents. No effort was made to identify specific patients or to exclude potentially duplicative patient reports.

Relative risks (RRs), 95% confidence intervals (CIs), and 2 × 2 table *P* values (by Fisher exact test) were calculated for selected exposure variables using EpiInfo software (version 6.04b; Centers for Disease Control and Prevention, Atlanta, Ga). Each piercing was treated as an independent event.

RESULTS

Cohort Study and Clinical Details

We identified receipts for 124 individuals during the 45-day period and interviewed 118; 6 could not be located. These 118 individuals underwent 186 ear piercings (defined as new holes) during this period, of which 7 (4%) resulted in confirmed *P aeruginosa* infection and 18 (10%) led to suspected infections. *Staphylococcus aureus* was cultured from one person with a suspected earlobe infection; no other pathogens were identified. Twenty-

six piercings (14%) resulted in minor symptoms not meeting either case definition; no problems were reported after 130 piercings (70%), and the outcome of 5 piercings (3%) could not be determined. FIGURE 1 shows the occurrence of ear piercings during this period and their outcomes.

At least 63 of 186 piercings (34%) were done in upper ear cartilage, including all 7 with confirmed *P aeruginosa* infection; 112 (60%) were lobe piercings and the locations of 11 (6%) were ambiguous. Relative to lobe piercing, cartilage piercing was associated with an increased risk of both confirmed (RR, undefined; *P* < .001) and suspected (RR, 3.6; 95% CI, 1.5-8.5) infections.

Worker A performed the plurality of piercings (82 [44%]), including 6 of 7 that resulted in confirmed infections and 4 of 18 that resulted in suspected infections (Figure 1). Restricting analysis to piercings by worker A, cartilage piercing remained associated with an increased risk of confirmed infection (RR, undefined; *P* < .001). The risk of developing confirmed or suspected infections was higher for cartilage piercing by other workers as well (RR, 3.2; 95% CI, 1.2-8.5).

At least 14 persons sought medical attention. The 7 patients with confirmed *P aeruginosa* infection were aged 10 to 19 years. Their symptoms began within a few hours to 3 days after piercing (median, 1 day); they presented for medical attention 2 to 8 days (median, 5) after symptom onset. All had abscess formation with associated swelling, pain, bleeding, and drainage. Two reported retroauricular lymphadenopathy. Reported systemic signs and symptoms were minor and nonspecific. On initial presentation, most patients were treated with cephalosporins or other drugs ineffective against *P aeruginosa* (TABLE).

Six patients with confirmed infection were referred to otolaryngologists—3 only after the health department intervened. Four patients were hospitalized: 3 for incision and drainage surgery and 1 to receive intravenous therapy. Another refused

admission and underwent incision and drainage as an outpatient. Four were treated with fluoroquinolones. The active infections resolved within 1 to 3 months and several resulted in significant disfigurement of the pinna (FIGURE 2). By 2002, all but 2 patients had been lost to follow-up.

Practice Review

The jewelry kiosk had been routinely inspected in January 2000, 8 months before the outbreak was recognized. At that time, the operator was cited for im-

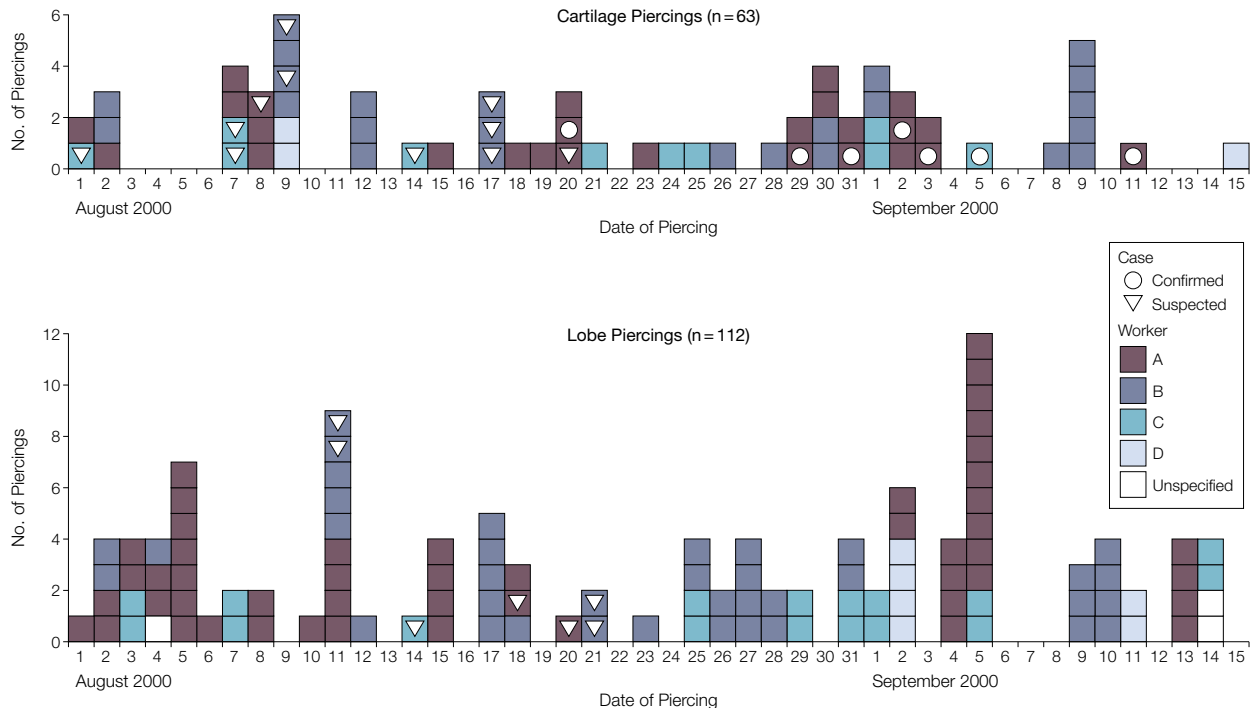
proper record keeping, hand washing, and equipment disinfection practices, as well as use of improper equipment (open, spring-loaded guns) to pierce cartilage. Although approved for lobes, these devices were not legal for cartilage piercing in Oregon.

Citations notwithstanding, kiosk workers had continued to use the guns on both lobes and cartilage. Each worker gave a somewhat different account of “standard” procedures, none of which could be verified. All stated that a customer’s ear was first wiped

with alcohol. A sterile ear stud was loaded into a gun, ideally without touching either the stud or the part of the gun that touched the ear. The piercing gun was then positioned and triggered, driving the stud through the ear.

Worker A stated that before using the piercing gun, she would mist the assemblage with disinfectant from an atomizer bottle—a practice other operators denied. Although originally containing another product and not intended to be reused, the disinfectant atomizer had been used for months and

Figure 1. Piercing Outcomes by Date, Piercing Site, and Worker

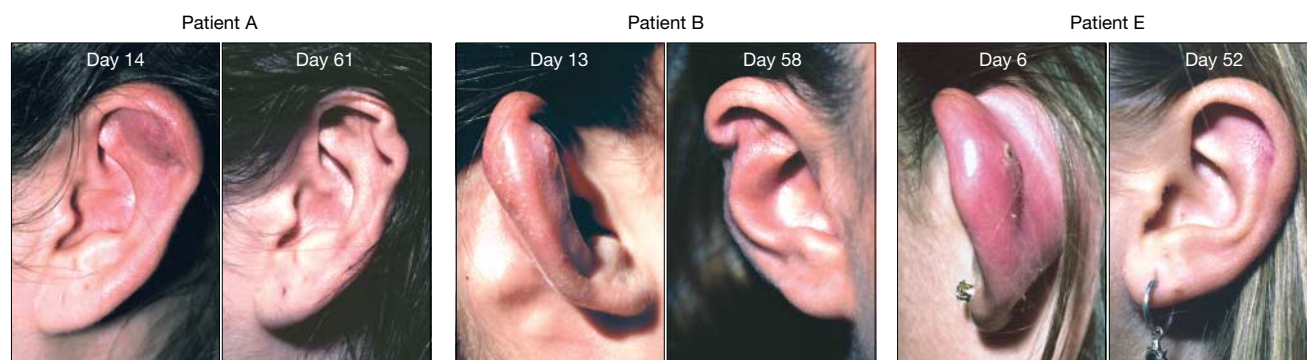


Boxes, each of which represent a single piercing, are stacked from bottom to top according to time of piercing.

Table. Treatment Schedules for Confirmed Cases

Patient	Piercing to Symptom Onset (Incubation), d	Onset to Initial Presentation, d	Initial Therapy	Onset to Initial Otolaryngologist Consult, d	Postconsult Therapy
A	3	5	Amoxicillin/clavulanate	5	Ciprofloxacin
B	2	2	Cephalexin, clarithromycin	11	Ceftazidime
C	0	5	Cephalexin, ceftriaxone	21	None
D	1	2	Cephalexin, cefazolin	5	Clindamycin, gentamicin
E	1	2	Cephalexin	3	Ceftazidime, ciprofloxacin
F	3	6	Cephalexin, ceftriaxone, amoxicillin/clavulanate	16	Ceftazidime, ciprofloxacin
G	1	8	Cefazolin, ampicillin/ sulbactam, levofloxacin	*	

*This individual was not referred to an otolaryngologist.

Figure 2. Acute and Convalescent Phase of *Pseudomonas aeruginosa* Infections Following Piercing of Upper Ear Cartilage

Depicted are 3 patients with confirmed *Pseudomonas aeruginosa* infections shown by days after piercing. Older, unrelated piercings of patients A and E are visible.

refilled many times. The contents could not be verified but were reported to be a blend in uncertain proportions of a “double” quaternary ammonium disinfectant, a phenolic disinfectant, and tap water from a nearby utility sink.

Culture and Subtyping Results

Pseudomonas aeruginosa was not recovered from any of the solid surfaces that were swabbed, from tap water at the 2 sinks used by shop employees, or from faucet aerators, but it was cultured from 2 of 4 workers (1 from stool, 1 from hands), from the atomizer solution, and from waste water in traps beneath both sinks.

All 7 patient isolates had indistinguishable antibiograms. Five isolates were available for further subtyping; all were indistinguishable by MRF subtyping and indistinguishable from the atomizer and the utility sink trap isolates. They differed from the bathroom sink and worker isolates, which were heterogeneous. The 13 community isolates collected by the hospital between October and December 2000 comprised 12 MRF patterns, none of which matched the outbreak strain.

Otolaryngologist Survey

Of 136 otolaryngologists licensed in Oregon, 13 (10%) were retired, dead, or unlocatable. Of the remaining 123, we received responses from 94 (76%). They reported seeing 53 patients with ear piercing-related auricular chondritis

within the previous year, and 8 (15%) of these patients had *P aeruginosa* infection. In their cumulative 1406 practice-years of experience, the otolaryngologists estimated having seen an additional 190 patients with piercing-related auricular chondritis, 27 (14%) of them with *P aeruginosa* infection. Twenty-seven (29%) of the responding clinicians reported never having seen piercing-related auricular chondritis.

COMMENT

Pseudomonas aeruginosa is known to cause sporadic cartilage infections following ear piercing or other trauma,^{9,11-14} but we found no descriptions of previous common-source outbreaks. This unfortunate natural experiment confirms the assertion that ear cartilage is more prone to serious infection than the lobe is.^{7,11,13-15} It also underscores the importance of infection control training wherever invasive procedures are performed—even in nonmedical settings.

A constellation of events aligned to cause this outbreak. First, open piercing guns were used to drive relatively blunt studs through cartilage, rather than recommended¹⁶ (and, in Oregon, legal) alternatives such as needle piercing. Second, a “single-use” disinfectant bottle was refilled repeatedly, becoming contaminated with *P aeruginosa*, presumably at the sink where organisms were recovered.

Finally, at least 1 worker sometimes sprayed the sterile studs and piercing gun with disinfectant, not appreciating that sterile implements would not benefit from a spray with any disinfectant, much less a contaminated one.

The size of this outbreak is difficult to assess. The specificity of our suspected case definition for *Pseudomonas* infections could not be determined, but the asymmetrical timing of confirmed vs suspected infections (Figure 1) suggests that more cases would have been confirmed had more persons—particularly those with cartilage infections—been cultured during their first weeks of symptoms. The outbreak may have begun well before August; following news media reports, we learned of several similar-sounding infections from individuals pierced before the study period.

The incidence of serious sequelae following ear piercing is not well known. Several surveys in selected populations have found high rates of minor complications.^{3,6,17} One outbreak subsequent to lobe piercing (staphylococcal infections at a children’s party⁴) and a case-control study implicating lobe piercing as a risk factor for hepatitis B transmission¹⁸ were reported in the 1970s. Noninfectious problems, notably metal hypersensitivity, may be more common than serious infection.² Case reports aside, there are essentially no data about the incidence of auricular

chondritis following piercing. The physician survey results suggest that specialist visits are uncommon.

Cartilage wounds can be slow to heal and may demand aggressive therapy, including surgical debridement and drainage.^{7,11,14,19} While cultures are recommended, empirical therapy of auricular chondritis should include coverage for *Pseudomonas*, which may be the most common cause.¹²⁻¹⁵ Given limited options for outpatient therapy, ciprofloxacin has been recommended as the drug of choice,^{13,14} notwithstanding concerns about pediatric use.

Culturing *Pseudomonas* from a bottle of disinfectant has ample precedent.^{20,21} Whatever it was, the atomizer solution was clearly not pseudomonocidal.

In commercial settings, better worker training is a worthwhile goal, but the most effective interventions may include both changes to ear-piercing equipment that reduce the potential for worker error and increased regulatory attention.⁹ This outbreak prompted re-

visions to Oregon regulations, adopted in 2001, that included a ban on the use of open, spring-loaded piercing guns as well as increased educational and training requirements for workers. Of course, given the ubiquity of *Pseudomonas* in plumbing fixtures and other aqueous environments, some risk of infection will remain until the wound heals.

Although *P aeruginosa* infections per se are not reportable in any state, suspected common-source outbreaks of any kind are reportable in every state.²² Reporting obligations may be overlooked by clinicians, especially when the offending organism is not specifically named on reporting lists. This outbreak smoldered for weeks—perhaps months—until 2 patients happened to be referred to the same otolaryngologist, who promptly notified the local health department. Had the outbreak occurred in a larger community, with more specialists and hospitals, or had the clinician not contacted the health department, it might have continued in-

definitely—unnoticed, uninvestigated, and uncontrolled.

Author Contributions: As principal investigator, Dr Keene had full access to all of the data in the study and takes responsibility for the integrity of the data and the accuracy of the data analysis.

Study concept and design, drafting of the manuscript, statistical expertise, study supervision: Keene. **Acquisition of data:** Keene, Markum, Samadpour. **Analysis and interpretation of data:** Keene, Samadpour.

Critical revision of the manuscript for important intellectual content: Keene, Markum, Samadpour.

Administrative, technical, or material support: Keene, Markum, Samadpour.

Funding/Support: This investigation was conducted by public health agencies of the State of Oregon and Klamath County. Much of the former's funding comes from Emerging Infections Program Cooperative Agreement U50/CCU011184, a federal grant. Dr Samadpour donated his laboratory's services without restriction.

Role of the Sponsor: The sponsoring agencies had no involvement in the design, conduct, analysis, or write-up of this investigation.

Previous Presentations: Presented in part as a poster at the annual meeting of the Infectious Diseases Society of America, October 24-27, 2002, Chicago, Ill.

Acknowledgment: This outbreak was first identified and reported by the late Glenn-Eric Hager, MD. We would also like to acknowledge the contributions of Douglas Todd, MD, and Scott Graham, DO; Anthony Igou; Marilyn Sutherland and other staff at the Klamath County Department of Public Health; Bob Gruchalla and Kevin Weeks; Jason Baker, MD, and Paul Cieslak, MD.

REFERENCES

- Braithwaite RL, Stephens T, Sterk C, Braithwaite K. Risks associated with tattooing and body piercing. *J Public Health Policy*. 1999;20:459-470.
- Koenig LM, Carnes M. Body piercing medical concerns with cutting-edge fashion. *J Gen Intern Med*. 1999;14:379-385.
- Cortese TA, Dickey RA. Complications of ear piercing. *Am Fam Physician*. 1971;4:66-72.
- Sanders DY. Complications of ear piercing. *Woman Physician*. 1971;26:459.
- Van Sciver AE. Hepatitis from ear piercing. *JAMA*. 1969;207:2285.
- Biggar RJ, Haughie GE. Medical problems of ear piercing. *N Y State J Med*. 1975;75:1460-1462.
- Staley R, Fitzgibbon JJ, Anderson C. Auricular infections caused by high ear piercing in adolescents. *Pediatrics*. 1997;99:610-611.
- Cumberworth VL, Hogarth TB. Hazards of ear-piercing procedures which traverse cartilage: a report of *Pseudomonas* perichondritis and review of other complications. *Br J Clin Pract*. 1990;44:512-513.
- Tweeten SSM, Rickman LS. Infectious complications of body piercing. *Clin Infect Dis*. 1998;26:735-740.
- Samadpour M, Grimm L, Desai B, Alfi D, Ongerth JE, Tarr PI. Molecular epidemiology of *Escherichia coli* O157:H7 strains by bacteriophage I restriction fragment length polymorphism analysis: application to a multistate foodborne outbreak and a day-care center cluster. *J Clin Microbiol*. 1993;31:3179-3183.
- Turkeltaub SH, Habal MB. Acute *Pseudomonas* chondritis as a sequel to ear piercing. *Ann Plast Surg*. 1990;24:279-282.
- Cicchetti S, Skillman J, Gault DT. Piercing the upper ear: a simple infection, a difficult reconstruction. *Br J Plast Surg*. 2002;55:194-197.
- Hanif J, Frosh A, Marnane C, Ghufoor K, Rivron R, Sandhu G. "High" ear piercing and the rising incidence of perichondritis of the pinna. *BMJ*. 2001;322:906-907.
- Kent SE, Rokade AV, Premraj K, Butcher C. "High" ear piercing and perichondritis of the pinna. *BMJ*. 2001;323:400.
- More DR, Seidel JS, Bryan PA. Ear-piercing techniques as a cause of auricular chondritis. *Pediatr Emerg Care*. 1999;15:189-192.
- Health Canada. Infection prevention and control practices for personal services: tattooing, ear/body piercing and electrolysis. *Can Commun Dis Rep*. 1999;25(suppl 3):1-73.
- Simplot TC, Hoffman HT. Comparison between cartilage and soft tissue ear piercing complications. *Am J Otolaryngol*. 1998;19:305-310.
- Johnson CJ, Anderson H, Spearman J, Madson J. Ear piercing and hepatitis. *JAMA*. 1974;227:1165.
- Orticochea M. Surgical treatment of acute chondritis of the external ear. *Br J Plast Surg*. 1980;33:38-40.
- Lee J, Fialkow P. Benzalkonium chloride: source of hospital infection with Gram-negative bacteria. *JAMA*. 1960;177:708-710.
- Frank MJ, Schaffner W. Contaminated aqueous benzalkonium chloride: an unnecessary hospital infection hazard. *JAMA*. 1976;236:2418-2419.
- Roush S, Birkhead G, Koo D, Cobb A, Fleming D. Mandatory reporting of diseases and conditions by health care professionals and laboratories. *JAMA*. 1999;282:164-170.