Case Report/Case Series

Posterior Cortical Atrophy as an Extreme Phenotype of *GRN* Mutations

Paola Caroppo, MD, PhD; Catherine Belin, MD, MA; David Grabli, MD, PhD; Didier Maillet, PhD; Anne De Septenville, PhD; Raffaella Migliaccio, MD, PhD; Fabienne Clot, PhD; Foudil Lamari, MD; Agnès Camuzat, BSc; Alexis Brice, MD; Bruno Dubois, MD, PhD; Isabelle Le Ber, MD, PhD

IMPORTANCE Posterior cortical atrophy (PCA) is characterized by progressive visuoperceptual and visuospatial deficits and commonly considered to be an atypical variant of Alzheimer disease. Mutations of the *GRN* gene are responsible for a large phenotypic spectrum, but, to our knowledge, the association of PCA with *GRN* mutations has never been described.

OBSERVATIONS We studied a patient presenting with insidious impairment of basic visuoperceptual skills and apperceptive visual agnosia with predominant posterior atrophy corresponding to a visual/ventral variant of PCA. A heterozygous p.Arg110* (c.328C>T) *GRN* mutation was identified in this patient.

CONCLUSIONS AND RELEVANCE This study extends the clinical spectrum of *GRN* mutations that may be responsible for a PCA phenotype. The *GRN* phenotypes overlap other degenerative dementias and highlight the limits of actual nosologic boundaries in dementias. The *GRN* gene should be analyzed in patients with PCA, particularly when the damage progresses to anterior cerebral regions and a family history of dementia is present.

JAMA Neurol. 2015;72(2):224-228. doi:10.1001/jamaneurol.2014.3308
Published online December 29, 2014.

Author Affiliations: Author affiliations are listed at the end of this article.

Corresponding Author: Paola Caroppo, MD, PhD, Institut du Cerveau et de la Moelle Épinière, Hôpital de la Salpêtrière, 47 Boulevard de l'hôpital, 75013 Paris, France (paolacaroppo@libero.it).

Posterior cortical atrophy (PCA)[1] is a rare neurodegenerative syndrome affecting the primary visual occipital, occipitotemporal, and biparietal cortices. Patients usually present with progressive high-order visual and visuomotor deficits.[2] A classification into dorsal and ventral subtypes has been proposed.[2,3] The dorsal stream (biparietal/occipitoparietal cortices) is implicated in object location, visually guided motor movements, and motor planning. The patients present with apraxia, visuospatial problems, agraphia, or Balint syndrome with preserved basic perceptual abilities, object recognition, and reading. The ventral visual stream (occipitotemporal cortices) is implicated in recognition of objects, faces, and written words. The patients with ventral/visual stream lesions have alexia, apperceptive visual agnosia, and prosopagnosia.[3] A rarer variant associated with severe occipital involvement (the visual variant) is characterized by primary visual failure and impairment of basic perceptual abilities.[3]

Posterior cortical atrophy is considered to be an atypical variant of Alzheimer disease (AD) because most cases have AD pathologic characteristics.[4,5] In rare cases, pathologic lesions of Lewy body dementia, corticobasal degeneration, prion disease, or subcortical gliosis are identified.[4]

In most instances, patients have no family history of dementia. Mutations of the *PSEN1*,[6] *PRNP*,[7] and *IT15*[8] genes have been identified in a few patients, but the genetic basis of PCA remains elusive.[2] We identified a mutation in the *GRN* gene (RefSeq NM_002087.2) in a patient presenting with visual deficits, apperceptive visual agnosia, and occipital cortical atrophy, which fit the criteria of PCA.[1-3] This study extends the phenotypic spectrum of *GRN* mutations and contributes to better delineation of the nosologic boundaries of genetic dementias.

Methods

This study was approved by the Ethics Committee of the Assistance Publique-Hôpitaux de Paris, Paris, France. All participants provided written informed consent.

Description of the Patient

The proband (individual 005) had a corticobasal syndrome and was referred for genetic counseling because of a family history of dementia (**Figure 1**A). His sibling (individual 004) had progressive blurred vision at 58 years of age. Individual 004 had difficulty recognizing the shape of objects but no problem with color perception. He had difficulties in face recognition but he could identify the person by recognizing the voice. Reading and watching television were difficult. At that time,

Copyright 2015 American Medical Association. All rights reserved.

Downloaded From: https://jamanetwork.com/ on 02/24/2022

Figure 1. Family Pedigree and *GRN* Mutation

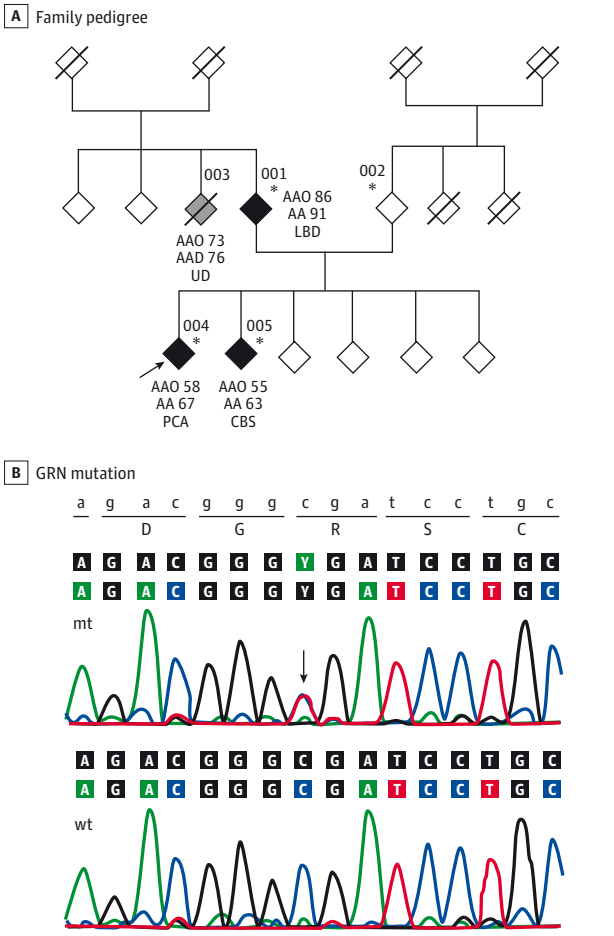

A, The proband is individual 005. Solid symbol indicates affected individual; white symbol, unaffected individual; gray symbol, affected by unspecified dementia but no DNA available; slash, deceased; and arrow, patient described in the report. Diamonds were used for confidentiality of sex. AA indicates actual age; AAD, age at death; AAO, age at onset; asterisk, DNA available; CBS, corticobasal syndrome; LBD, Lewy body dementia; PCA, posterior cortical atrophy; and UD, unspecified dementia. B, Chromatogram of the c.328C>T (p.Arg110*) mutation is in the upper half (arrow), with the normal sequence below. mt Indicates mutated; wt, wild-type.

he was living alone without other cognitive deficits. He was autonomous in his travels and activities of daily life and served as the caregiver for a parent with dementia. Results of oculomotricity and the ophthalmologic, visual field, and visual acuity examinations were normal.

The neuropsychological examination of individual 004 at 60 years of age (**Table**) revealed basic impairment of visuoperceptual skills and apperceptive visual agnosia. The identification of objects was possible by tactile, auditory, and olfactory modalities. The Balint and Gerstmann syndromes were absent. The perception of visually guided motor movements and spatial localization were normal without optic apraxia. Praxis and language were normal. The patient had alexia caused by the perceptive deficit. Word spelling was preserved. He had moderate conceptualization, strategy, and working memory deficits. Verbal and semantic memories

Table. Neuropsychological Profile of Individual 004[a]

Tests	Patient's Score/ Maximal Score
MMSE scores[9]	
Total score	16/30[b]
Orientation	9/10
Learning	3/3
Arithmetic	0/5
Memory	2/3
Language	4/8
Constructional praxis	0/1
Birmingham Object Recognition Battery scores	
Length match	0/30
Size match	0/30
Orientation match	0/30
Position of gap match	0/30
Visual Object and Space Perception Battery scores	
Shape decision	10/20[c]
Incomplete letters	0/20
Silhouettes	0/30
Dot counting	0/10
Position discrimination	0/20
Picture naming score	0/80
Identification of real objects	
Visual input	0/10
Tactile input	10/10
Auditory input	3/3
Olfactory input	3/3
Identification	
Living/nonliving objects	3/6[b]
Simples shapes	1/4[b]
Colors	16/20
Movement perception	
Objects localization in space	Normal
Target tracking	Normal
Line bisection task	0
Symbol cancellation task	0
Words reading	0
Sentences reading	0
Letters identification	0/6
Writing words on dictation	
Regular	10/10
Irregular	9/10
Logatoms	10/10
Oral spelling of words (on dictation)	
Regular	5/5
Irregular	5/5
Logatoms	4/5
Reconstitution of words on spelling	
Regular	3/5
Irregular	3/5
Logatoms	2/5

(continued)

Copyright 2015 American Medical Association. All rights reserved.

Downloaded From: https://jamanetwork.com/ on 02/24/2022

Table. Neuropsychological Profile of Individual 004[a] (continued)

Tests	Patient's Score/ Maximal Score
Faces identification	
Facial Recognition Test	0/54
Famous and unknown faces recognition	0
Facial expression recognition	2/10[b]
Praxies	
Symbolic gestures	5/5
Monomanual gestures	5/5
Bimanual gestures	4/5
Meaningless gestures	1/5[b]
Constructional praxies	
Geometrical figures copy	0
Memory drawing	1/4[b]
Short-term memory	
Digit span forward	6
Visual-spatial span	0
Long-term memory	
Logic memory I	9
Logic memory II	7
Retention, %	76
Semantic knowledge battery	74/78
Executive functions	
Digit span backward	3[b]
Isaacs Set Test	
15 s	21
60 s	49
Repetitions	4
Similarities	4/19[b]

Abbreviation: MMSE, Mini-Mental State Examination.

[a] The patient (right handed) underwent testing at 60 years of age, 2 years after disease onset.

[b] Scores are less than the cutoff.

were normal. Magnetic resonance imaging at 60 years of age revealed bilateral occipital atrophy mainly affecting the inferior occipital gyrus with extension to the superior lingual and the fusiform gyri (**Figure 2**A) and mild frontal and occipitoparietal junction atrophy. He had no parkinsonism or motor symptoms. He received a diagnosis of PCA. Four years later, the visuoperceptual deficit still predominated but memory problems had appeared (encoding and storage deficits). At 63 years of age, he developed apathy and perseverative behaviors. Magnetic resonance imaging showed marked diffuse atrophy (Figure 2B). The patient progressively became mute and bedridden.

Family History

The proband (individual 005) had corticobasal syndrome at 60 years of age (Figure 1A). The parent (individual 001) had a clinical diagnosis of Lewy body dementia at 87 years of age; the parent's sibling (individual 003) had unspecified dementia at 73 years of age.

Progranulin Plasma Level and *GRN* Sequencing

Initially, a *GRN* mutation was searched for in the proband because of the corticobasal syndrome and the family history. Individuals 001, 002 (the spouse of individual 001), and 004 underwent analyses secondarily.

We collected blood and plasma samples from these individuals. The progranulin plasma level was measured with a human enzyme-linked immunosorbent assay kit (ELISA kit Proepithelin; Adipogen). The 13 exons of *GRN* were sequenced using Sanger methods. The apolipoprotein E (APOE) genotype was determined using a commercially available assay (TaqMan; Applied Biosystems).

Results

The plasmatic progranulin level was reduced in the proband (39 μg/L) and individuals 001 (47 μg/L) and 004 (29 μg/L) (reference range, 100-300 μg/L). A heterozygous c.328C>T (p.Arg110*) *GRN* mutation was found in individuals 001 and 004 and the proband (Figure 1B) but not in individual 002. This mutation has been identified previously.[10] The APOE genotype of all the mutation carriers was ε3/ε3.

Discussion

We identified a *GRN* mutation in a patient with PCA characterized by prominent visual deficits, apperceptive visual agnosia, alexia, and prosopoagnosia with preservation of other cognitive functions. Greater impairment of basic visuoperceptual skills was compatible with a main involvement of visual cortices. Apperceptive visual agnosia, with the preservation of object recognition by other sensorial modalities, indicated the extension of damage along the ventral visual stream.[2,3] Predominant atrophy of the primary visual cortex—and to a lesser degree of the parieto-occipital region—was in agreement with the clinical criteria of a visual/ventral variant of PCA.[2,3]

Mutations of the *GRN* gene are associated with a large spectrum of phenotypes of frontotemporal lobar degeneration (FTLD).[10] Most mutation carriers present with a behavioral variant of FTLD, progressive nonfluent aphasia, corticobasal syndrome, or a phenotype mimicking Lewy body dementia. The presentation of individual 004 was very unusual because isolated visual agnosia at onset has not been reported in *GRN* carriers. The topography of the lesions was also different from that of *GRN* carriers, in whom atrophy predominantly involves the frontal, temporal, and parietal cortices but preserves the occipital regions at onset.[11] This study extends the clinical spectrum of *GRN* mutations and demonstrates that, in rare cases, the pathologic changes can be confined to the posterior cortex at onset. The phenotypic variability characterizing *GRN* carriers is not explained by the type of mutations, all leading to progranulin haploinsufficiency and thus supporting the strong influence of additional disease modifiers.

Mutations of *GRN* are associated with TDP-43 neuronal inclusions.[12] To our knowledge, no pathologic cases of PCA with

Copyright 2015 American Medical Association. All rights reserved.

Downloaded From: https://jamanetwork.com/ on 02/24/2022

Figure 2. Structural Magnetic Resonance Images (MRIs) for Individual 004

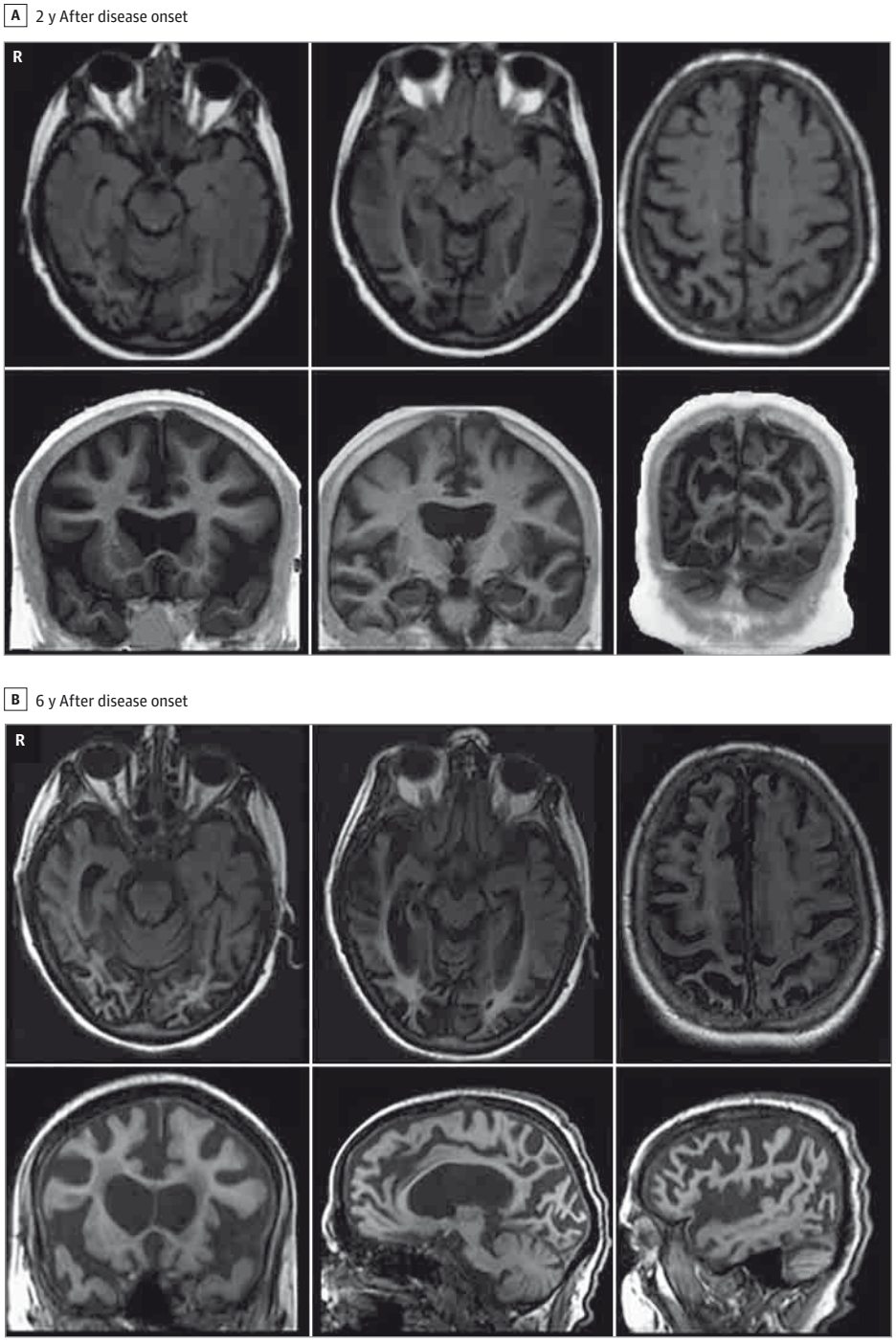

We used fluid-attenuated inversion recovery and T1-weighted sequences for MRI. A, Axial and coronal sections 2 years after disease onset (at 60 years of age). The MRIs reveal greater atrophy in the bilateral inferior occipital, superior lingual, and fusiform gyri and mild atrophy in the frontal areas and occipitoparietal junction. The hippocampus appears to be spared. B, Axial, coronal, and sagittal sections 6 years after disease onset (at 64 years of age). The MRIs show marked and diffuse brain atrophy, particularly involving the insular and medial frontal regions. R indicates right.

TDP-43 inclusions have been described. We cannot exclude coincidental association of AD pathologic features in individual 004 owing to the absence of brain pathologic examination, cerebrospinal fluid analyses, and amyloid positron emission tomographic study. The association of TDP-43 and AD pathologic features has been described previously in 2 *GRN* carriers presenting with the typical phenotypes of AD or logopenic progressive aphasia.[13] In that study, both patients were heterozygous for the APOE ε4 allele, suggesting that AD pathologic features could be explained, at least in part, by the APOE status. A highly significant association exists between the APOE ε4 allele and the risk for PCA and posterior AD.[14] The absence of the APOE ε4 allele in our patient suggests a distinct pathologic process and that PCA could be an extreme phenotype of the *GRN* disease spectrum. This conclusion is supported by the rapid progression of atrophy to the anterior cortical regions

Copyright 2015 American Medical Association. All rights reserved.

Downloaded From: https://jamanetwork.com/ on 02/24/2022

(Figure 2), which is rather different from PCA with AD pathologic features. In the latter process, the damage remains relatively centered on the posterior lobes, even in the late stage.[1,15]

Conclusions

This study enlarges the mutational spectrum of PCA to *GRN* mutations and provides evidence that *GRN* analyses could be indicated in PCA, particularly when the damage progresses to the anterior cerebral regions and a family history of dementia is present. The link between PCA and genetic forms of FTLD is supported by the recent identification of a *MAPT* mutation in 1 case of PCA.[16] Analyses of genes in FTLD in patient cohorts will be necessary to better evaluate their genetic contribution to PCA. Finally, this study underlines a possible continuum in degenerative dementias and highlights the limits of actual nosologic boundaries. Clarifying these boundaries by identifying factors driving phenotypic heterogeneity will have important implications for the definition of new diagnosis criteria of degenerative dementias and recruitment for clinical trials in the future.

ARTICLE INFORMATION

Accepted for Publication: September 5, 2014.

Published Online: December 29, 2014. doi:10.1001/jamaneurol.2014.3308.

Author Affiliations: Sorbonne Universités, Université Pierre et Marie Curie Université Paris 06, Unité Mixte de Recherche (UMR) S 1127, Institut du Cerveau et de la Moelle Épinière (ICM), Paris, France (Caroppo, Grabli, De Septenville, Migliaccio, Camuzat, Brice, Dubois, Le Ber); Institut National de la Santé et de la Recherche Médicale, U 1127, Paris, France (Caroppo, Grabli, De Septenville, Migliaccio, Camuzat, Brice, Dubois, Le Ber); Centre National de la Recherche Scientifique, UMR 7225, Paris, France (Caroppo, Grabli, De Septenville, Migliaccio, Camuzat, Brice, Dubois, Le Ber); ICM, Hôpital de la Pitié-Salpêtrière, Paris, France (Caroppo, Grabli, De Septenville, Migliaccio, Camuzat, Brice, Dubois, Le Ber); Mémoire et Maladie Neurodégénérative, Service de Neurologie, Unité d'Explorations Fonctionnelles, Assistance Publique–Hôpitaux de Paris (AP-HP), Centre Hospitalier Universitaire Avicenne, Bobigny, France (Belin, Maillet); Département des Maladies du Systéme Nerveux, AP-HP, Hôpital de la Pitié-Salpêtrière, Paris, France (Grabli, Migliaccio, Dubois, Le Ber); Centre de Référence des Démences Rares, AP-HP, Hôpital de la Pitié-Salpêtrière, Paris, France (Clot, Le Ber); Département de Génétique et Cytogénétique, Unité Fonctionnelle de Neurogénétique Moléculaire et Cellulaire, AP-HP, Hôpital de la Pitié-Salpêtrière, Paris, France (Clot); Laboratoire de Biochimie, AP-HP, Hôpital de la Pitié-Salpêtrière, Paris, France (Lamari); Département de Génétique et Cytogénétique, Unité Fonctionnelle de Génétique Clinique, AP-HP, Hôpital de la Pitié-Salpêtrière, Paris, France (Brice).

Author Contributions: Dr Le Ber had full access to all the data in the study and takes responsibility for the integrity of the data and the accuracy of the data analysis.
Study concept and design: Caroppo, Brice, Le Ber.
Acquisition, analysis, or interpretation of data: Caroppo, Belin, Grabli, Maillet, De Septenville, Migliaccio, Clot, Lamari, Camuzat, Dubois, Le Ber.
Drafting of the manuscript: Caroppo, Clot, Camuzat, Le Ber.
Critical revision of the manuscript for important intellectual content: Belin, Grabli, Maillet, De Septenville, Migliaccio, Lamari, Brice, Dubois.
Obtained funding: Caroppo, Brice, Le Ber.
Administrative, technical, or material support: De Septenville, Clot, Lamari, Camuzat.
Study supervision: Le Ber.

Conflict of Interest Disclosures: None reported.

Funding/Support: This study was supported by contract ANR-10-IAIHU-06 from Investissements d'avenir (Dr De Septenville); by a doctoral fellowship from Carlo Besta Institute (Dr Caroppo); and by contract R12091DD from the France Alzheimer Association (Dr Brice).

Role of the Funder/Sponsor: The funding sources had no role in the design and conduct of the study; collection, management, analysis, and interpretation of the data; preparation, review, or approval of the manuscript; and decision to submit the manuscript for publication.

Additional Contributions: Lydia Guennec, BS, Isabelle Lagroua, RN, Sylvie Forlani, PhD, and Christelle Dussert, BS, of the DNA and cell bank of Centre de Recherche de la ICM, Hôpital de la Salpêtrière, Paris, France, provided excellent technical assistance. None of these contributors received financial compensation for their roles.

REFERENCES

1. Crutch SJ, Lehmann M, Schott JM, Rabinovici GD, Rossor MN, Fox NC. Posterior cortical atrophy. *Lancet Neurol*. 2012;11(2):170-178.

2. McMonagle P, Deering F, Berliner Y, Kertesz A. The cognitive profile of posterior cortical atrophy. *Neurology*. 2006;66(3):331-338.

3. Alladi S, Xuereb J, Bak T, et al. Focal cortical presentations of Alzheimer's disease. *Brain*. 2007; 130(pt 10):2636-2645.

4. Renner JA, Burns JM, Hou CE, McKeel DW Jr, Storandt M, Morris JC. Progressive posterior cortical dysfunction: a clinicopathologic series. *Neurology*. 2004;63(7):1175-1180.

5. Migliaccio R, Agosta F, Rascovsky K, et al. Clinical syndromes associated with posterior atrophy: early age at onset AD spectrum. *Neurology*. 2009;73(19): 1571-1578.

6. Sitek EJ, Narożańska E, Pepłońska B, et al. A patient with posterior cortical atrophy possesses a novel mutation in the presenilin 1 gene. *PLoS One*. 2013;8(4):e61074. doi:10.1371/journal.pone.0061074.

7. Depaz R, Haik S, Peoc'h K, et al. Long-standing prion dementia manifesting as posterior cortical atrophy. *Alzheimer Dis Assoc Disord*. 2012;26(3): 289-292.

8. Caixeta L. Huntington's disease presenting as posterior cortical atrophy. *Arq Neuropsiquiatr*. 2011; 69(2B):407-408.

9. Folstein MF, Folstein SE, McHugh PR. Mini-Mental State: a practical method for grading the cognitive state of patients for the clinician. *J Psychiatr Res*. 1975;12:189-198.

10. Le Ber I, Camuzat A, Hannequin D, et al; French Research Network on FTD/FTD-MND. Phenotype variability in progranulin mutation carriers: a clinical, neuropsychological, imaging and genetic study. *Brain*. 2008;131(pt 3):732-746.

11. Whitwell JL, Weigand SD, Boeve BF, et al. Neuroimaging signatures of frontotemporal dementia genetics: C9ORF72, tau, progranulin and sporadics. *Brain*. 2012;135(pt 3):794-806.

12. Neumann M, Sampathu DM, Kwong LK, et al. Ubiquitinated TDP-43 in frontotemporal lobar degeneration and amyotrophic lateral sclerosis. *Science*. 2006;314(5796):130-133.

13. Perry DC, Lehmann M, Yokoyama JS, et al. Progranulin mutations as risk factors for Alzheimer disease. *JAMA Neurol*. 2013;70(6):774-778.

14. Carrasquillo MM, Khan Qu, Murray ME, et al. Late-onset Alzheimer disease genetic variants in posterior cortical atrophy and posterior AD. *Neurology*. 2014;82(16):1455-1462.

15. Kas A, de Souza LC, Samri D, et al. Neural correlates of cognitive impairment in posterior cortical atrophy. *Brain*. 2011;134(pt 5):1464-1478.

16. Rossi G, Bastone A, Piccoli E, et al. Different mutations at V363 MAPT codon are associated with atypical clinical phenotypes and show unusual structural and functional features. *Neurobiol Aging*. 2014;35(2):408-417.

Copyright 2015 American Medical Association. All rights reserved.

Downloaded From: https://jamanetwork.com/ on 02/24/2022