

# Anatomical Wiring and Functional Networking Changes in the Visual System Following Optic Neuritis

Yael Backner, MS; Joseph Kuchling, MD; Said Massarwa; Timm Oberwahrenbrock, PhD; Carsten Finke, MD; Judith Bellmann-Strobl, MD; Klemens Ruprecht, MD; Alexander U. Brandt, MD; Hanna Zimmermann, MEng; Noa Raz, PhD; Friedemann Paul, MD; Netta Levin, MD, PhD

**IMPORTANCE** Clinical outcome in multiple sclerosis was suggested to be driven by not only remyelination but also adaptive reorganization. This mechanism needs to be further understood.

**OBJECTIVE** To explore anatomical and functional visual networks in patients with optic neuritis (ON) to assess the relative weight of each connectivity modality to expedite visual recovery.

**DESIGN, SETTING, AND PARTICIPANTS** Between March 11, 2011, and May 26, 2014, 39 patients with either clinically isolated syndrome (CIS) ON (n = 18) or other CIS (non-ON) (n = 21) were recruited 1 to 28 months following an initial clinical event. These patients enrolled in an ongoing prospective cohort study (107 participants at the time of this present study) about the disease course of CIS and multiple sclerosis. Inclusion criteria were an age of 18 to 65 years, the suggestive clinical and paraclinical diagnosis of CIS or multiple sclerosis after relevant differential diagnoses have been ruled out, the existence of complete imaging data, and no ocular comorbidities. Anatomical connectivity was evaluated by diffusion tensor imaging, and functional connectivity was evaluated by resting-state functional magnetic resonance imaging. The visual pathways, including optic tracts, optic radiations, and splenial fibers, were delineated, and the resting-state visual networks were detected. Data analysis took place from September 1, 2015, to December 1, 2015.

**MAIN OUTCOMES AND MEASURES** Connectivity changes were quantified and compared to determine the association of ON with the visual network.

**RESULTS** This study included 18 patients with CIS ON, 11 (61%) of whom were women with a mean (SD) age of 32.83 (8.53) years, and 21 patients with CIS non-ON (11 [52%] of whom were women with a mean [SD] age of 30.86 [7.54] years). With the use of diffusion tensor imaging, reduced diffusivity (mean [SD] fractional anisotropy, 0.35 [0.03] vs 0.38 [0.03];  $P < .01$ ) was evident along the optic tracts of patients with ON, suggesting the extension of axonal injury from the damaged optic nerve. Neither the optic radiations nor the splenial fibers showed evidence of loss of integrity. Yet, in the presence of an intact postgeniculate anatomical network, the functional connectivity within the visual network was higher in the ON cohort. Functional connectivity observed in cortical motion-related areas was inversely correlated with the visual evoked potential-measured conduction velocity ( $r = -0.59$ ;  $P < .05$ ).

**CONCLUSIONS AND RELEVANCE** In this cohort, local optic nerve demyelinating damage does not affect distant wiring, but even in the presence of an intact anatomical network, functional modification may occur. These functional network changes may be part of the recovery process, but further research is needed to elucidate this process.

JAMA Neurol. 2018;75(3):287-295. doi:10.1001/jamaneurol.2017.3880  
Published online January 2, 2018.

◀ Editorial page 274

◀ Related article page 296

+ Supplemental content

+ CME Quiz at  
[jamanetwork.com/learning](http://jamanetwork.com/learning)

**Author Affiliations:** Functional Imaging Unit, Department of Neurology, Hadassah-Hebrew University Medical Center, Jerusalem, Israel (Backner, Massarwa, Raz, Levin); Department of Neurology, Charité-Universitätsmedizin Berlin, Berlin, Germany (Kuchling, Finke, Ruprecht, Paul); NeuroCure Clinical Research Center, Charité-Universitätsmedizin Berlin, Berlin, Germany (Oberwahrenbrock, Bellmann-Strobl, Brandt, Zimmermann, Paul); Experimental and Clinical Research Center, Max Delbrück Center for Molecular Medicine and Charité-Universitätsmedizin Berlin, Berlin, Germany (Bellmann-Strobl, Paul).

**Corresponding Author:** Netta Levin, MD, PhD, Functional Imaging Unit, Department of Neurology, Hadassah-Hebrew University Medical Center, POB 12,000, Jerusalem 91120, Israel ([netta@hadassah.org.il](mailto:netta@hadassah.org.il)).

The term *multiple sclerosis* (MS) stems from the neuropathological observation of numerous focal “plaques” in the white matter<sup>1</sup>; thus, MS imaging research had initially concentrated on lesion localization and load. However, the discrepancy between lesion load and clinical disability suggested that damage by far exceeds areas of focal inflammation and that the brain should be evaluated as a whole.<sup>2-6</sup>

Local lesional damage to strategic white matter tracts may exert remote consequences through anatomical connections. Connectivity, however, can also be determined by the “common interest” of different brain regions working together. In that case, damage to one module will affect other network components. Changes in functional connectivity were proposed to play a compensatory role in MS, presumably contributing to the weak association between lesion load and clinical manifestations.<sup>7</sup>

Optic neuritis (ON), with its characteristic clinical manifestation, and the visual pathways, which are amenable to investigation with various structural and functional visual and imaging techniques, were recently proposed as *in vivo* models for studying the pathophysiology of tissue damage and repair in MS.<sup>8</sup>

This study investigated both anatomical and functional visual networks in patients with a first ON attack and compared them with the visual networks of patients presenting with symptoms suggestive of demyelination in other functional systems. In particular, we examined how anatomical and functional connectivity changes in the visual system following ON intertwine and whether these changes are distinct from those in patients with non-ON.

## Methods

The study was approved by the Charité-Universitätsmedizin Berlin ethics committee and was conducted in accordance with the Declaration of Helsinki.<sup>9</sup> All participants gave written informed consent. Data analysis took place from September 1, 2015, to December 1, 2015.

### Participants

Between March 11, 2011, and May 26, 2014, we prospectively recruited 18 patients with a clinically isolated syndrome (CIS) ON episode (eTable 1 in the [Supplement](#)) and 21 patients with a CIS episode in other functional systems (non-ON) (eTable 2 in the [Supplement](#)) 1 to 28 months (median, 3-4 months) following the clinical event. Based on radiological evidence for disease dissemination in space and time, 3 patients in each cohort met the 2010 revised McDonald criteria for MS.<sup>10</sup> Participants in this present study are enrolled in an ongoing prospective cohort study (107 at the time of this present study) about the disease course of CIS and MS. Inclusion criteria were an age of 18 to 65 years, the suggestive clinical and paraclinical diagnosis of CIS or MS after relevant differential diagnoses have been ruled out, the existence of complete imaging data, and no ocular comorbidities. (See eAppendix in the [Supplement](#) for further details on the patients.)

### Data Acquisition and Analysis

Visual acuity (VA) was measured with the Early Treatment Diabetic Retinopathy Study (ETDRS) chart, and the results

## Key Points

**Question** How are anatomical connectivity and functional connectivity associated with recovery after optic neuritis?

**Findings** In this study of 18 patients with optic neuritis as a clinically isolated syndrome and 21 patients with clinically isolated syndrome and damage elsewhere in the central nervous system, intact postgeniculate visual pathways were found but functional modification occurred as well, suggesting that functional network changes may be part of the recovery process.

**Meaning** Potentially adaptive modifications in functional connectivity may be important in explaining recovery following demyelinating injury, with specific evidence provided from the visual pathway.

were converted to decimal scale. Peripapillary retinal nerve fiber layer (pRNFL) thickness was recorded using spectral-domain optical coherence tomography (SPECTRALIS; Heidelberg Engineering). The affected and fellow eyes of each patient with ON were assessed separately. No significant intereye differences were seen in patients with non-ON; thus, the mean values of the data were calculated for each patient.

Visual evoked potentials (VEPs) were recorded by a trained technician on a VEP system (Dantec Keypoint; Natus). Abnormal values were defined as above 111 milliseconds. The affected and fellow eyes of each patient were assessed separately. No significant intereye differences were found in patients with non-ON; thus, the mean values of the data were calculated for each patient.

Magnetic resonance imaging (MRI) data were acquired on a 3-T MRI scanner (Magnetom Trio; Siemens) using a 12-channel head coil. Anatomical MRI sequences included high-resolution T1-weighted images and fluid-attenuated inversion recovery (FLAIR)-weighted images. Diffusion tensor imaging data were acquired using a diffusion-weighted imaging sequence. All preprocessing and tractography were performed using the mrVista software package (VISTA Lab, Stanford University). The postchiasmal afferent visual pathways, including optic tracts and optic radiations, were delineated using a probabilistic fiber-tracking algorithm (ConTrack; VISTA Lab, Stanford University).<sup>11</sup> The callosal fibers were tracked using a deterministic streamline-tracing technique algorithm (according to mrVista defaults), and the 5 most posterior fiber groups (occipital, posterior-parietal, superior-parietal, superior-frontal, and temporal) were parceled as described elsewhere.<sup>12,13</sup> White matter integrity, including fractional anisotropy (FA), and diffusion that is parallel (axial diffusivity [AD]) and perpendicular (radial diffusivity [RD]) to the primary fiber direction were extracted.

White matter lesions were manually segmented on FLAIR images and intersected with the visual pathways (optic tracts and radiations as well as splenic fibers) to calculate lesion volume. Resting-state blood oxygenation level-dependent functional MRI (fMRI) measurements were obtained with an echo-planar imaging sequence. The fMRI

data analysis was performed using the BrainVoyager QX software package, version 2.8 (Brain Innovation). Data were analyzed via independent component analysis.<sup>14</sup> For each patient, 3 regions of interest (ROIs) were defined in each hemisphere. The calcarine sulcus was defined anatomically, and the lateral occipital complex (LOC) and middle temporal (MT) regions were defined functionally as regions selectively activated by object (LOC) and motion (MT) processing. These areas were selected as representative high-order regions in the ventral (LOC) and dorsal (MT) streams. (See eAppendix in the Supplement for further details on data acquisition and analysis.)

### Statistical Analysis

Mean values of FA, AD, and RD were compared between patients with ON and those with non-ON through unpaired 2-tailed *t* tests. Significance was assessed at the 2-sided  $P < .05$  level. To assess significant differences along the fiber profiles, given the high degree of correlation between adjacent points on the tract, we used a permutation-based multiple comparisons correction.<sup>15</sup>

Pearson correlation coefficients and linear regression analysis were used to examine the associations between diffusivity measurements of the optic tracts, optic radiations and callosal occipital fibers, and functional connectivity *z* scores; between pRNFL thickness and *z* scores; between VEP P100 values and *z* scores; between pRNFL thickness and diffusivity measurements of the fiber groups; and between VEP P100 values and diffusivity measurements. Significance was assessed at the 2-sided  $P < .05$  level.

To control for the effects of time elapsed from episode owing to a greater number of patients recruited 1 to 3 months following the acute ON attack, a linear regression model was built with functional connectivity *z* scores as the dependent variables and time from episode as the independent variable. A second model was built with lesion loads in the optic tracts and radiations as the independent variables to control for effects of disease load.

## Results

### Research Cohort Characteristics

Of the 39 patients included, 18 had CIS ON, 11 (61%) of whom were women with a mean (SD) age of 32.83 (8.53) years. Of the remaining 21 patients with other CIS episodes (non-ON), 11 (52%) were women with a mean (SD) age of 30.86 (7.54) years. Visual acuity was within the normal range<sup>16</sup> at greater than 0.8 (Snellen 20/25) except for 1 patient with ON who had 0.5 (Snellen 20/40). The mean (SD) VA values were 0.92 (0.34) for the affected eyes of patients with ON, 1.19 (0.36) for the fellow eyes, and 1.08 (0.28) for the non-ON “averaged” eyes (averaged eyes refer to the mean results of the right and left eyes). A significant difference of  $P < .01$  was found between the affected and fellow eyes owing to the higher VAs recorded for the fellow eyes.

The mean (SD) pRNFL thickness of the affected eyes was reduced (83.2 [12.2]  $\mu\text{m}$ ) compared with both fellow eyes and

non-ON averaged eyes (95.0 [11.8]  $\mu\text{m}$  vs 98.0 [12.3]  $\mu\text{m}$ ;  $P < .01$ ). No difference was observed between the fellow eyes and non-ON averaged eyes.

The mean (SD) VEP P100 latencies of the affected eyes of patients with ON were prolonged compared with those of the fellow eyes (120.6 [12.9] milliseconds vs 103.2 [7.5] milliseconds;  $P < .01$ ). The mean (SD) VEP P100 latencies of the non-ON averaged eyes (109.5 [20.5] milliseconds) were not significantly different from either the affected eyes or the fellow eyes of patients with ON. This result was driven by 3 patients with non-ON who had binocular-prolonged P100 latencies; when excluded, the averaged eyes’ mean (SD) latencies were 101.5 (5.7) milliseconds and were significantly shorter than those of the ON-affected eyes at  $P < .01$ . Functional MRI data analysis was performed with and without these 3 patients; however, because no difference in results was found, they were included in all analyses. These 3 patients were not clinically diagnosed as having ON, which is in line with the notion that, in MS, prolonged latencies may occur without prior ON.<sup>17</sup>

### Anatomical Connectivity

#### Afferent Visual Pathway—Optic Tracts

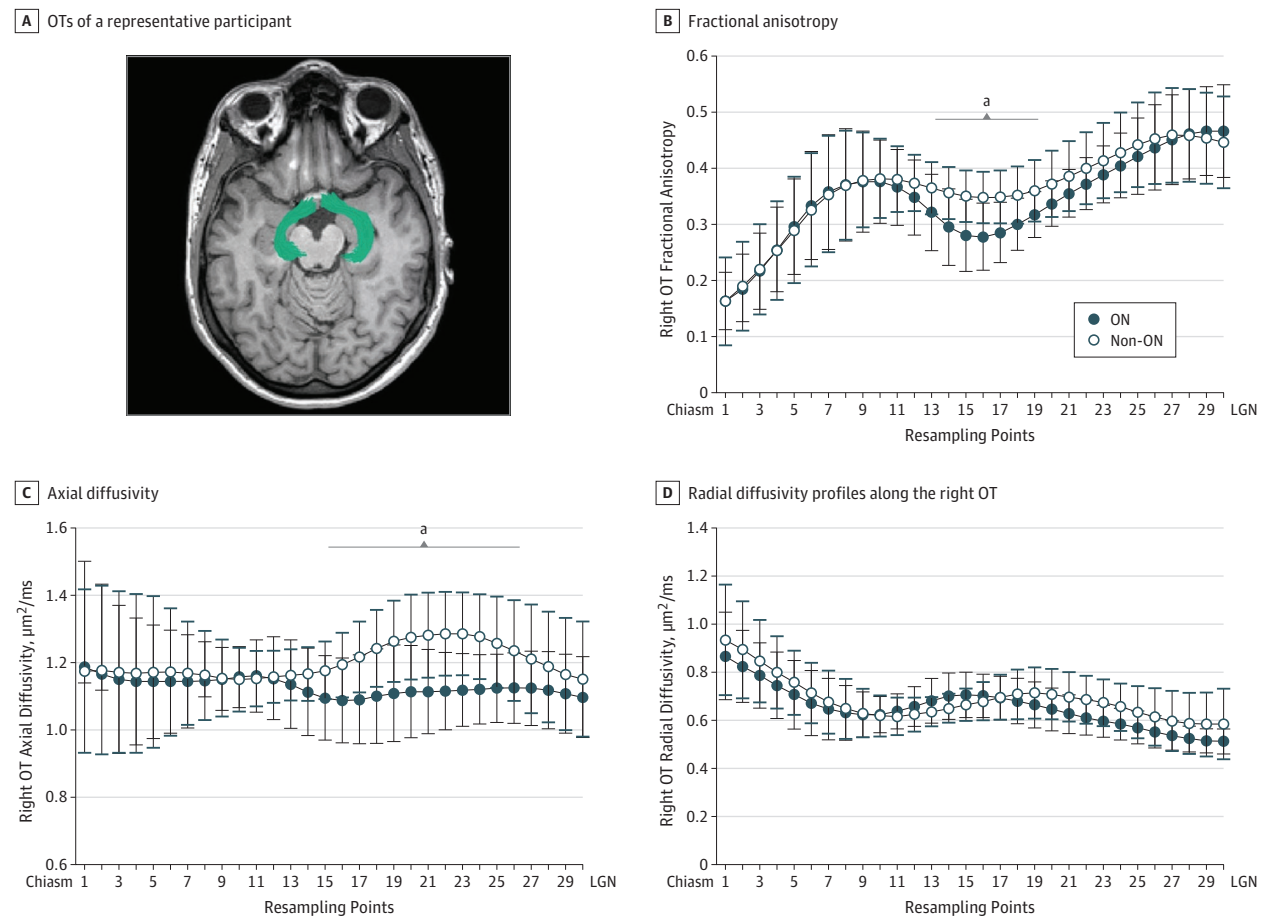
Optic tracts were delineated on a participant-by-participant basis (Figure 1A). Diffusivity measurements were analyzed along 30 resampling points along the fibers. Significantly reduced FA was found in the right optic tract in patients with ON compared with those with non-ON (mean (SD), 0.35 [0.03] vs 0.38 [0.03];  $P < .01$ ; Figure 1B). The difference is clearly seen throughout the last two-thirds of the fiber, reaching significance following a multiple comparison correction in points 13 to 20. This difference is derived from AD measurements of the tract (Figure 1C) with no significant difference observed in RD (Figure 1D). For correlation analysis, mean measurements of the entire optic tract were also calculated. A difference between cohorts was found only for AD (patients with ON, 1.12 [0.09]  $\mu\text{m}^2/\text{ms}$  vs patients with non-ON, 1.2 [0.08]  $\mu\text{m}^2/\text{ms}$ ;  $P < .01$ ). No differences were detected in the left optic tract (data not shown).

To examine whether the optic tract measurements result from the degeneration proceeding from the optic nerve, we correlated the pRNFL thickness to the fiber diffusivity measurements. Because each optic tract transmits information from the contralateral nasal hemiretina, we correlated pRNFL thickness from the nasal hemiretina of the affected eyes with diffusivity within the corresponding contralateral optic tracts, as was done previously.<sup>18</sup> Significant correlation ( $r = 0.68$ ;  $P < .01$ ) was found between the nasal pRNFL thickness and the mean FA measures in the last (posterior) third of the corresponding optic tracts. No such results were found when the pRNFL thickness was correlated with the entire optic tract or any of its other thirds. No such correlations were found in the non-ON or the ON fellow eyes.

#### Afferent Visual Pathway—Optic Radiations

Optic radiations were delineated on a participant-by-participant basis (Figure 2A). No significant differences were found between the 2 study cohorts in any fiber diffusivity data (AD, RD, and FA; Figure 2B). Sixteen patients with ON (89%)

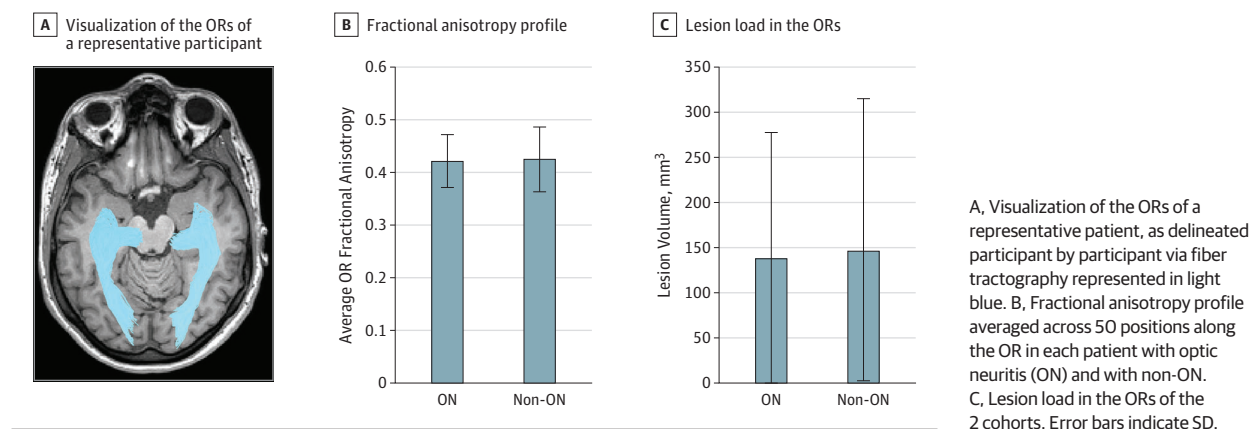
Figure 1. Optic Tract (OT) Integrity Impairment Following Damage to the Optic Nerve



A, Visualization of the OTs of a representative patient, as delineated participant by participant via fiber tractography represented in green. B, Fractional anisotropy. C, Axial diffusivity. D, Radial diffusivity profiles along the right OT. LGN indicates lateral geniculate nucleus; ON, optic neuritis. Error bars indicate SD.

<sup>a</sup> Fiber section showing significance.

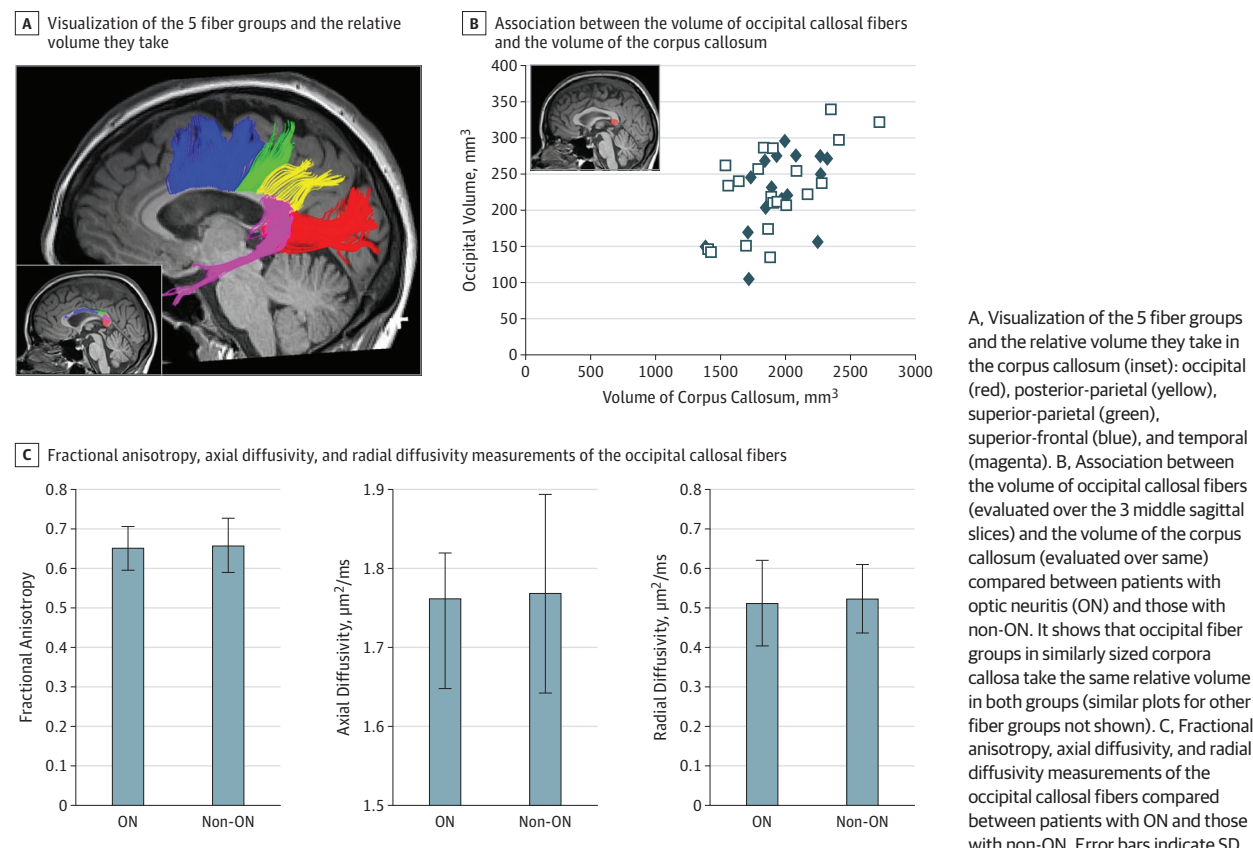
Figure 2. Absence of Transsynaptic Degeneration in the Optic Radiation (OR)



and 18 patients with non-ON (86%) had lesions within their optic radiations. The lesion volume range was 0 to 542 mm<sup>3</sup> (mean [SD], 138.34 [139.16] mm<sup>3</sup>) for patients with ON and 0 to 604 mm<sup>3</sup> (146.56 [168.47] mm<sup>3</sup>) for patients with non-ON,

and there was no difference between cohorts (Figure 2C). Despite lesion volume heterogeneity in the 2 cohorts, FA was not different, which may indicate that lesion volume has very little association with tract integrity. No correlations were found



**Figure 3. Absence of Changes in the Callosal Fibers Following Damage to the Afferent Visual Pathway**

between pRNFL thickness and any of the diffusivity data of the optic radiations.

#### Occipito-Occipital Pathway

Five fiber groups crossing the corpus callosum, the largest white matter structure in the brain that facilitates interhemispheric communication, were segmented and compared between the study cohorts (Figure 3A). These fiber groups were used to parcel the corpus callosum (Figure 3A inset). A comparison of the relative callosal volume taken by each of the 5 groups revealed no differences between the study cohorts (ie, the internal organization of the corpus callosum did not differ between patients with ON and those with non-ON) (Figure 3B, occipital group). Furthermore, no differences were observed in any of the fiber diffusivity measurements between the 2 cohorts (statistics shown in Figure 3C for the occipital group; similar analyses performed for the other fiber groups are not shown).

#### Functional Connectivity

##### Visual Resting-State Network Connectivity

For each patient, the visual network was selected. *t* Maps for those with ON and those with non-ON were created and were based on individual maps (Figure 4A). A group *t* test was conducted, and areas of significant differences were identified. Stronger in-network connectivity in the ON map was found in both low-order (calcarine sulcus) and high-order (LOC and MT)

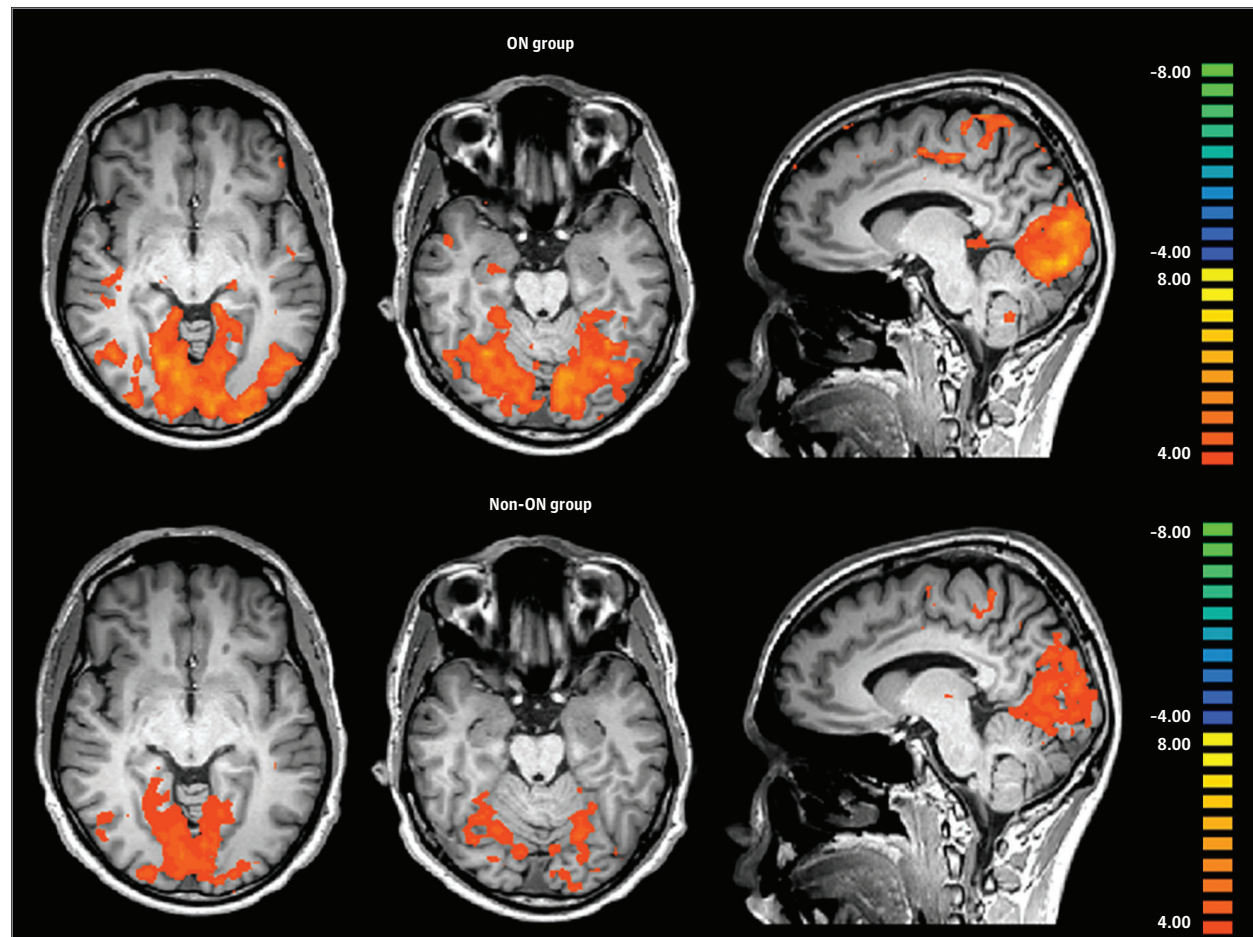
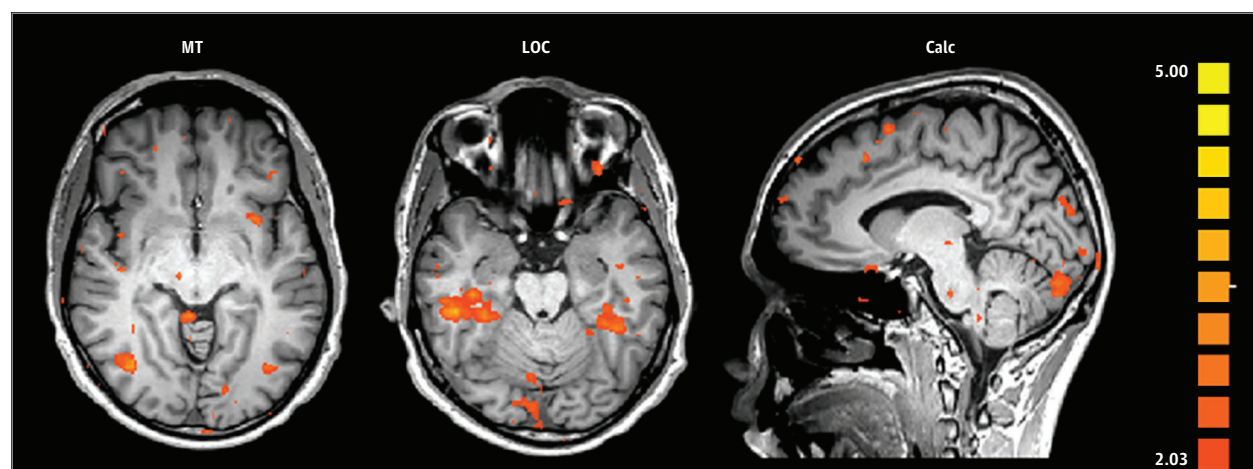
visual regions (Figure 4B). For correlation analysis purposes, *z* scores were extracted from an intersection of previously<sup>18</sup> and externally defined, localizer-based ROIs and significant voxels. The *z* score comparison of the 3 selected ROIs did not detect between-group differences.

To investigate whether the functional connectivity is influenced by the quality of the visual input, we correlated *z* scores extracted from the 3 predefined visual ROIs with VEP P100 latencies (Figure 5) and pRNFL. An inverse correlation was found between the ON intereye latency difference ( $\Delta$ VEP, defined as affected eye P100 – fellow eye P100) and functional connectivity of the right MT to the rest of the visual resting-state network (Figure 5A;  $n = 13$ ;  $r = -0.59$ ;  $P < .05$ ). A similar, although nonsignificant ( $r = -0.41$ ;  $P = .16$ ), trend was found between the ON affected eye VEP latencies and the right MT connectivity. Nonsignificance was caused by a single outlier (when removed,  $r = -0.74$ ;  $P < .01$ ), suggesting the observation regarding  $\Delta$ VEP is derived from the affected eye. No such correlation was found for the left MT or for the other ROIs.

Correlation was also found between the averaged non-ON VEP P100 latencies and the left MT connectivity (Figure 5B;  $n = 10$ ;  $r = -0.72$ ;  $P < .05$ ). It is important to note that this correlation was mainly driven by the 3 patients with prolonged latencies. No other correlation was found for the non-ON cohort's ROIs.

No correlations were found between the pRNFL thickness and the visual resting-state network *z* scores. When

Figure 4. Stronger Functional Connectivity of the Visual Resting-State Network (V-RSN) in Patients With Optic Neuritis (ON) vs Patients With Non-ON

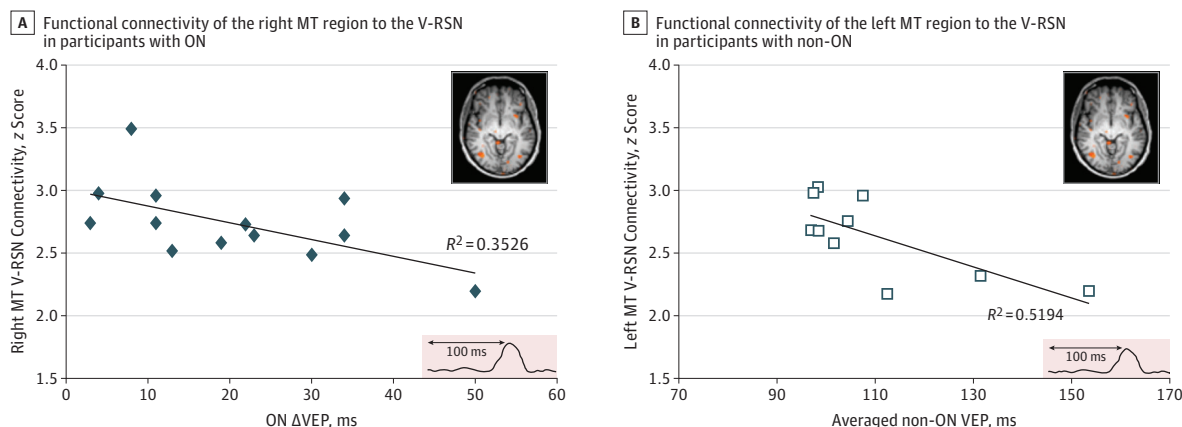
A Group V-RSN *t* mapsB Group *t* test

A, Group V-RSN *t* maps for patients with ON (top panels) and those with non-ON (bottom panels). B, Significant differences between the cohorts were detected using the group *t* test in the middle temporal (MT, left), lateral occipital complex (LOC, middle), and calcarine sulcus (Calc, right) visual regions ( $P < .05$ ).

applying the regression models, we found that none of the independent variables predicted the dependent variables with

$P < .05$ , implying that neither time from episode nor lesion load in the optic tracts or radiations affected connectivity.

**Figure 5. Correlation of Stronger Functional Connectivity of the Middle Temporal (MT) to the Visual Resting-State Network (V-RSN) With the Projection Rates Along the Visual Pathways**



A, Functional connectivity of the right MT region to the V-RSN in patients with optic neuritis (ON) as a function of the ON intereye latency difference (ie, the change in visual evoked potential (ΔVEP, defined as affected eye P100 – fellow

eye P100). B, Functional connectivity of the left MT region to the V-RSN in patients with non-ON as a function of mean VEP P100 of the 2 eyes.

## Discussion

Axonal injury was evident in the optic tracts of patients with ON, suggesting the local extension of the optic nerve damage as in wallerian degeneration. However, neither the optic radiations nor the occipital callosal fibers exhibited differences in tract integrity, which are specific to the ON cohort. Yet, in the presence of an intact postgeniculate anatomical network, the functional connectivity within the visual network was higher in patients with ON than in those with non-ON. The functional connectivity observed in the MT region, which is believed to play a major role in motion perception,<sup>19</sup> correlated with the conduction velocity along the afferent visual pathways of the ON cohort.

Similar to a previous report,<sup>18</sup> in which the visual pathways of patients with ON were compared with those of normal-sighted controls, our study shows that long-term axonal loss developed distally to the diseased optic nerve but did not proceed to the postsynaptic optic radiation. The fact that reduced optic tract integrity following ON was evident in comparison with both healthy controls and patients with non-ON supports the notion that the damage is an extension of the local optic nerve damage and not a part of a generalized demyelination or neuroaxonal damage. Differences in RD along the optic radiations were reported to be associated with intra-bundle lesion volume.<sup>18</sup> Because the control group in the present study included patients with non-ON but with similar lesion loads within their optic radiations, no such differences were detected.

Data regarding the involvement of the optic radiation following ON are contradictory. Several reports suggest that damage to the optic radiation is independent from the proximal damage,<sup>20,21</sup> but others report transsynaptic anterograde degeneration effects.<sup>22,23</sup> This contradiction can be explained by the use of different tractography methods or by differences in

scan time from the acute event. Recently, a thorough study focusing on the diffusivity dynamics of optic radiation reported that, within a longitudinally studied ON cohort, transsynaptic degeneration was observed over time.<sup>24</sup> Neither our study nor any other has referred to the visual pathway in its entirety, thus precluding inferences regarding the temporal evolution of visual pathway damage. However, in our study, the intactness of the optic radiations did not differ between cohorts, which is important in light of the functional connectivity results.

The corpus callosum was also evaluated to investigate the more distant effects of local demyelinating damage. Our in vivo approach to parcel the corpus callosum to its subdivisions enabled us to shed light on the specific morphology and functional relationships connected to the visual network.<sup>12,13</sup> Previous studies on the effect of congenital or early-age damage to the afferent visual system showed small callosal space taken by the occipital fiber group, probably resulting from arrested development of the posterior callosum. During development, there may be competition for synaptic space between different types of systems and, in the absence of a powerful visual input, visual fibers may acquire less synaptic space.<sup>25,26</sup> Unlike developmental conditions, any changes in the callosal fibers of either cohort were not observed. All fiber groups were similar between study cohorts, and no parametric or structural changes suggesting atrophy or compensatory plasticity were noted.

These functional connectivity results suggest that, following an ON episode, the spontaneous signals recorded in the entire visual network become more closely correlated in patients with ON compared with those with non-ON. Areas of stronger connectivity were found in all 3 selected regions (ie, lower [calcarine] and higher [object (LOC) and motion (MT)] visual cortical regions). These results are partially in agreement with Gallo et al,<sup>27</sup> who reported an area of stronger connectivity in the extrastriate cortex. In contrast, we



found no reduction of connectivity in the lateral middle occipital gyrus. These differences may be explained by the selection criteria. We included only patients with a single ON episode, whereas Gallo and colleagues included participants with multiple ON episodes, demonstrating an association between a higher number of recurrences and reduced functional connectivity. Two assumptions may be inferred from these reports. First, even a single ON episode, as in our cohort, is sufficient to induce functional connectivity changes despite only slightly, if any, reduced VA. Second, the increase in connectivity suggesting a compensatory mechanism is limited to a certain amount of damage, which is in line with studies in neurodegenerative diseases. In patients with minimal cognitive impairment, increased hippocampal fMRI activation can be found, suggesting the recruitment of activated neurons to compensate for the damage incurred, but in patients with Alzheimer disease, decreased functional activity in the same vicinity is displayed, suggesting a threshold for the compensational ability.<sup>28</sup>

Wu et al<sup>29</sup> reported generally reduced functional connectivity within the visual system of patients with ON compared with that in healthy controls. However, their cohort was composed of only patients with acute-stage ON (mean [SD] number of days after onset, 50 [25]). Because these patients were at their nadir of VA and damage status, it is not surprising that our results are in disagreement with theirs.

Functional connectivity between the MT region and the entire visual network was specifically correlated with the conduction velocity along the afferent visual pathways.

This was evident in the affected eyes of not only patients with ON but also those without ON, the cohort in which this result was mainly driven by 3 patients with prolonged latencies. The visual area MT is believed to play a major role in motion perception.<sup>19</sup> The sustained motion perception deficit in ON has been previously reported.<sup>30-32</sup> Furthermore, electrophysiological results suggested that demyelination was probably the cause for these deficits.<sup>33</sup> Conduction velocity in the visual pathways (measured by VEP) correlated closely with dynamic visual functions, implicating the need for rapid transmission of visual input to perceive motion. Our present results highlight and reemphasize this link between myelination and the temporal aspects of perception.

Of note, there was no correlation between conduction velocity in the fellow eyes and the MT connectivity. This finding may support the hypothesis that the prolonged latencies in the affected and fellow eyes stem from different pathophysiological mechanisms.<sup>34</sup> In brief, we previously suggested that prolonged latencies along the affected eye reflect demyelination, but visual projection via the clinically unaffected fellow eyes reflects an adaptive process that contributes to the temporal synchronization of binocular visual information in the cortex. This suggestion indicates that the cortical modulatory process in the fellow eye improves binocular functions following ON and thus emphasizes the interplay between the 2 eyes.<sup>35</sup>

### Limitations

This study is limited by its cross-sectional design and the variability in time lapse from the acute episode. However, both cohorts are equally heterogeneous in this aspect. We cannot fully rule out the possibility that the time lapse from ON was too short in some patients to allow for a full evolution of visual pathway damage. On a more general perspective, resolution and accuracy of diffusion tensor imaging is not very high; for this reason, minor differences can still be present between cohorts. Regarding the resting-state fMRI, connectivity might be influenced by changed activity in 1 nodule within the network. A previous study demonstrated that cortical activation in response to a stimulus presented to the affected eye was impaired for motion perception: the worse the motion perception, the lower the activity in the MT region.<sup>32</sup> Therefore, the observed increased connectivity in the present study further emphasizes the possibility of adaptive reorganization. It is noteworthy that the changes observed are limited to the right side of the brain. This result may be due to this specific ON cohort or its limited sample size, but another possible explanation is functional lateralization or a preference of the brain's recovery mechanisms to this particular side. Similar lateralization was previously found in visual pathways of glaucoma cohorts,<sup>36,37</sup> which was proposed to result from asymmetry in the average locations of the specific defects or from an association with hemispheric functional asymmetry in visual information processing.

### Conclusions

This study shows no anatomical differences between the visual pathways of patients with ON and those with non-ON past the first synapse of the afferent visual pathway. However, functional changes are observed with stronger connectivity in the visual network of the patients with ON, raising the possibility that, along with its recovery abilities, the brain also has modification abilities that act together to overcome an insult. Our findings highlight the importance of using a broader approach, combining the 2 complementary modalities of diffusion tensor imaging and resting-state fMRI to better define study cohorts and take potential confounders into account.

#### ARTICLE INFORMATION

**Accepted for Publication:** October 8, 2017.

**Published Online:** January 2, 2018.

doi:10.1001/jamaneurol.2017.3880

**Author Contributions:** Drs Paul and Levin contributed equally to the manuscript. Ms Backner and Dr Levin had full access to all of the data in the

study and take full responsibility for the integrity of the data and the accuracy of the data analyses.

**Study concept and design:** Backner, Raz, Paul, Levin.

**Acquisition, analysis, or interpretation of data:**

Backner, Kuchling, Massarwa, Oberwahrenbrock, Finke, Bellmann-Strobl, Ruprecht, Brandt, Zimmermann, Paul.

**Drafting of the manuscript:** Backner, Massarwa, Raz, Levin.

**Critical revision of the manuscript for important intellectual content:** Backner, Kuchling,

Oberwahrenbrock, Finke, Bellmann-Strobl,

Ruprecht, Brandt, Zimmermann, Paul, Levin.

**Statistical analysis:** Backner, Massarwa,

Oberwahrenbrock, Brandt.

**Obtained funding:** Backner, Ruprecht, Raz, Paul, Levin.



**Administrative, technical, or material support:**

Kuchling, Finke, Bellmann-Strobl, Ruprecht, Brandt, Zimmermann, Paul.

**Study supervision:** Brandt, Paul, Levin.

**Conflict of Interest Disclosures:** None reported.

**Funding/Support:** This study was funded in part by research grant 5128-A-1 from the National Multiple Sclerosis Society and by the Teva Pharmaceutical Industries Ltd as part of the Israeli National Network of Excellence in Neuroscience. Dr Paul is supported by grant DFG Exc 257 from the Deutsche Forschungsgemeinschaft. Drs Brandt and Paul are supported by Bundesministerium für Bildung und Forschung (BMBF/Neu2, 16GW0079: N2-ADVISIMS Retinal imaging in neuroimmunological disorders).

**Role of the Funder/Sponsor:** The funders had no role in the design and conduct of the study; collection, management, analysis, and interpretation of the data; preparation, review, or approval of the manuscript; and decision to submit the manuscript for publication.

**REFERENCES**

1. Charcot J-M. Histologie de la sclérose en plaques. *Gazette des hôpitaux*. 1868;41:554-555.
2. Filippi M, Rocca MA. Disturbed function and plasticity in multiple sclerosis as gleaned from functional magnetic resonance imaging. *Curr Opin Neurol*. 2003;16(3):275-282.
3. Shiee N, Bazin P-L, Zackowski KM, et al. Revisiting brain atrophy and its relationship to disability in multiple sclerosis. *PLoS One*. 2012;7(5):e37049.
4. Kutzelnigg A, Lucchinetti CF, Stadelmann C, et al. Cortical demyelination and diffuse white matter injury in multiple sclerosis. *Brain*. 2005;128(pt 11):2705-2712.
5. Azevedo CJ, Overton E, Khadka S, et al. Early CNS neurodegeneration in radiologically isolated syndrome. *Neurol Neuroimmunol Neuroinflamm*. 2015;2(3):e102.
6. Hackmak K, Weygandt M, Wuerfel J, et al. Can we overcome the 'clinico-radiological paradox' in multiple sclerosis? *J Neurol*. 2012;259(10):2151-2160.
7. Schoonheim MM, Filippi M. Functional plasticity in MS: friend or foe? *Neurology*. 2012;79(14):1418-1419.
8. Balcer LJ, Miller DH, Reingold SC, Cohen JA. Vision and vision-related outcome measures in multiple sclerosis. *Brain*. 2015;138(pt 1):11-27.
9. World Medical Association. World Medical Association Declaration of Helsinki: ethical principles for medical research involving human subjects. *JAMA*. 2013;310(20):2191-2194.
10. Polman CH, Reingold SC, Banwell B, et al. Diagnostic criteria for multiple sclerosis: 2010 revisions to the McDonald criteria. *Ann Neurol*. 2011;69(2):292-302.
11. Sherbondy AJ, Dougherty RF, Ben-Shachar M, Napel S, Wandell BA. ConTrack: finding the most likely pathways between brain regions using diffusion tractography. *J Vis*. 2008;8(9):1-16.
12. Huang H, Zhang J, Jiang H, et al. DTI tractography based parcellation of white matter: application to the mid-sagittal morphology of corpus callosum. *Neuroimage*. 2005;26(1):195-205.
13. Dougherty RF, Ben-Shachar M, Deutsch GK, Hernandez A, Fox GR, Wandell BA. Temporal-callosal pathway diffusivity predicts phonological skills in children. *Proc Natl Acad Sci U S A*. 2007;104(20):8556-8561.
14. Hyvärinen A, Oja E. Independent component analysis: algorithms and applications. *Neural Netw*. 2000;13(4-5):411-430.
15. Nichols TE, Holmes AP. Nonparametric permutation tests for functional neuroimaging: a primer with examples. *Hum Brain Mapp*. 2002;15(1):1-25.
16. International Council of Ophthalmology Visual Functions Committee. Visual acuity measurement standard. *Italian J Ophthalmol*. 1988;2(1):1-15. <http://www.icoph.org/dynamic/attachments/resources/icovisualacuity1984.pdf>. Accessed November 15, 2017.
17. Halliday AM, McDonald WI, Mushin J. Visual evoked response in diagnosis of multiple sclerosis. *Br Med J*. 1973;4(5893):661-664.
18. Raz N, Bick AS, Ben-Hur T, Levin N. Focal demyelination damage and neighboring white matter integrity: an optic neuritis study. *Mult Scler*. 2015;21(5):562-571.
19. Tootell RB, Reppas JB, Kwong KK, et al. Functional analysis of human MT and related visual cortical areas using magnetic resonance imaging. *J Neurosci*. 1995;15(4):3215-3230.
20. Dasenbrock HH, Smith SA, Ozturk A, Farrell SK, Calabresi PA, Reich DS. Diffusion tensor imaging of the optic tracts in multiple sclerosis: association with retinal thinning and visual disability. *J Neuroimaging*. 2011;21(2):e41-e49.
21. Kolbe SC, Marriott M, Walt AV, et al. Diffusion tensor imaging correlates of visual impairment in multiple sclerosis and chronic optic neuritis. *Invest Ophthalmol Vis Sci*. 2012;53(2):825-832.
22. Gabilondo I, Martínez-Lapiscina EH, Martínez-Heras E, et al. Trans-synaptic axonal degeneration in the visual pathway in multiple sclerosis. *Ann Neurol*. 2014;75(1):98-107.
23. Pfueller CF, Brandt AU, Schubert F, et al. Metabolic changes in the visual cortex are linked to retinal nerve fiber layer thinning in multiple sclerosis. *PLoS One*. 2011;6(4):e18019.
24. Tur C, Goodkin O, Altmann DR, et al. Longitudinal evidence for anterograde trans-synaptic degeneration after optic neuritis. *Brain*. 2016;139(pt 3):816-828.
25. Levin N, Dumoulin SO, Winawer J, Dougherty RF, Wandell BA. Cortical maps and white matter tracts following long period of visual deprivation and retinal image restoration. *Neuron*. 2010;65(1):21-31.
26. Hoffmann MB, Kaule FR, Levin N, et al. Plasticity and stability of the visual system in human achiasma. *Neuron*. 2012;75(3):393-401.
27. Gallo A, Esposito F, Sacco R, et al. Visual resting-state network in relapsing-remitting MS with and without previous optic neuritis. *Neurology*. 2012;79(14):1458-1465.
28. Sperling R. Functional MRI studies of associative encoding in normal aging, mild cognitive impairment, and Alzheimer's disease. *Ann N Y Acad Sci*. 2007;1097:146-155.
29. Wu GF, Brier MR, Parks CA-L, Ances BM, Van Stavern GP. An eye on brain integrity: acute optic neuritis affects resting state functional connectivity. *Invest Ophthalmol Vis Sci*. 2015;56(4):2541-2546.
30. Regan D, Kothe AC, Sharpe JA. Recognition of motion-defined shapes in patients with multiple sclerosis and optic neuritis. *Brain*. 1991;114(pt 3):1129-1155.
31. Barton JJ, Rizzo M. Motion perception in optic neuropathy. *Neurology*. 1994;44(2):273-278.
32. Raz N, Dotan S, Benoliel T, Chokron S, Ben-Hur T, Levin N. Sustained motion perception deficit following optic neuritis: behavioral and cortical evidence. *Neurology*. 2011;76(24):2103-2111.
33. Raz N, Dotan S, Chokron S, Ben-Hur T, Levin N. Demyelination affects temporal aspects of perception: an optic neuritis study. *Ann Neurol*. 2012;71(4):531-538.
34. Raz N, Chokron S, Ben-Hur T, Levin N. Temporal reorganization to overcome monocular demyelination. *Neurology*. 2013;81(8):702-709.
35. Benoliel T, Raz N, Ben-Hur T, Levin N. Cortical functional modifications following optic neuritis. *Mult Scler*. 2017;23(2):220-227.
36. Li K, Lu C, Huang Y, Yuan L, Zeng D, Wu K. Alteration of fractional anisotropy and mean diffusivity in glaucoma: novel results of a meta-analysis of diffusion tensor imaging studies. *PLoS One*. 2014;9(5):e97445.
37. Boucard CC, Hanekamp S, Čurčić-Blake B, Ida M, Yoshida M, Cornelissen FW. Neurodegeneration beyond the primary visual pathways in a population with a high incidence of normal-pressure glaucoma. *Ophthalmic Physiol Opt*. 2016;36(3):344-353.