

Double Trouble in Hereditary Neuropathy

Concomitant Mutations in the PMP-22 Gene and Another Gene Produce Novel Phenotypes

Julie A. Hodapp, MD; Gregory T. Carter, MD; Hillary P. Lipe, ARNP; Sara J. Michelson, MS, CGC; George H. Kraft, MD; Thomas D. Bird, MD

Background: Mutations in the peripheral myelin protein 22 (PMP-22) gene are the most common cause of Charcot-Marie-Tooth neuropathy and may rarely occur in combination with other neurogenetic diseases.

Objective: To characterize 3 families having a mutation in PMP-22 in addition to another neurogenetic disease mutation.

Design: Clinical, electrophysiologic, and genetic evaluations were made of 3 families with more than 1 genetic neuromuscular disease.

Setting and Patients: Family members were evaluated in neurogenetic and muscular dystrophy clinics in a university medical center setting.

Results: Three unusual families were found: (1) 2 young brothers each having a PMP-22 duplication and a missense mutation in the *GJB1* (Connexin-32) gene; (2) a 32-year-old woman having a PMP-22 duplication and a 1000-fold CTG repeat expansion in the *DMPK* gene (DM1 myotonic dystrophy); and (3) a 39-year-old man with a PMP-22 deletion and a missense mutation in the *ABCD1* gene (adrenomyeloneuropathy). The mutations were “additive,” causing a more severe phenotype than expected with each individual disease and coinciding with the important impact of each gene on peripheral nerve function.

Conclusions: Individuals having 2 separate mutations in neuromuscular disease–related genes may develop unusually severe phenotypes. Neurologists should be alert to this possibility.

Arch Neurol. 2006;63:112-117

Author Affiliations:

Departments of Rehabilitation Medicine (Drs Hodapp, Carter, and Kraft) and Neurology (Ms Michelson and Dr Bird), School of Medicine, University of Washington, and Puget Sound Health Care System, Geriatric Research Education and Clinical Center (Ms Lipe and Dr Bird), Seattle.

HEREDITARY MOTOR AND sensory neuropathy (HMSN) is a relatively common neuromuscular disorder with a prevalence of approximately 14 to 282 per million.¹ Charcot-Marie-Tooth (CMT) disease is the most common HMSN, accounting for approximately 90% of diagnosed cases.¹ There are several unique CMT phenotypes, each caused by a mutation in a different gene.^{2,3} Most often, CMT is caused by a mutation in the peripheral myelin protein 22 gene (PMP-22).⁴ PMP-22 is an important component of myelin adhesion.⁵ Duplication in the PMP-22 gene produces CMT disease type 1A (CMT1A), while PMP-22 deletions result in another subtype of HMSN, hereditary neuropathy with liability to pressure palsies (HNPP).^{6,7} Both CMT1A and HNPP are inherited in an autosomal dominant pattern.

Charcot-Marie-Tooth disease type 1A is a generalized, primarily demyelinating neuropathy in which anatomical changes occur in the myelin sheath that eventu-

ally lead to secondary axonal changes.⁸ Demyelination slows impulse conduction between nodes of Ranvier because current leakage increases the time needed for impulses to reach threshold at successive nodes of Ranvier. Thus, a severe, generalized slowing of nerve conduction velocity (NCV) along the studied nerve segment is observed.^{9,10}

Hereditary neuropathy with liability to pressure palsies is similar to CMT 1A in that a primarily demyelinating neuropathy results from a derangement in the PMP-22 gene. However, HNPP is characterized by a susceptibility to recurrent, pressure-induced, focal demyelination. Severe conduction slowing is thereby localized to common anatomical sites of compression.¹¹ Hong et al¹¹ showed that a generalized sensorimotor neuropathy, less severe than that seen in CMT1A, exists in HNPP as well.

An X-linked dominant subtype of CMT, CMTX, is caused by missense mutations in the *GJB1*/Connexin-32 gene.⁴ Connexin-32 is a component of gap junction formation within myelin.¹² Abnormal gap

junction formation results in a neuropathy with mixed demyelinating and/or axonal diagnostic features.¹³

Myotonic muscular dystrophy (MMD) is produced by an autosomal dominant trinucleotide repeat mutation in the *DMPK* gene in chromosome 19.¹⁴ Estimated incidence of MMD is about 1 case per 20 000 population.¹⁴ The trinucleotide (CTG) repeat mutation may expand as it is passed on, thereby causing the disease to manifest earlier and more severely in subsequent generations. The expanded CTG sequences seem to produce a toxic messenger RNA and alter the alternative splicing of other genes including a chloride channel and insulin receptor.^{15,16} The resultant phenotype has progressive, primarily distal, muscle weakness with myotonia often associated with cardiac arrhythmias, cataracts, frontal baldness, diabetes mellitus, and cognitive impairment.¹⁴ Electrodiagnostic (EDX) studies show electrical myotonia and signs of myopathy on needle testing.¹⁷ Combined EDX and nerve biopsy studies report evidence of a primarily axonal, peripheral polyneuropathy in MMD as well.¹⁸⁻²⁰ Severity of the characteristic neuropathy does not appear to correlate with age or duration of the disease and does not show signs of progressing.

Adrenomyeloneuropathy (AMN) is a variant of X-linked adrenoleukodystrophy, a disorder that affects at least 1 in 100 000 newborns.²¹ X-linked adrenoleukodystrophy is a phenotypically diverse disorder that can be caused by a variety of mutations in the *ABCD1* gene. This gene codes for a peroxisomal membrane protein that, when deficient, results in accumulation of saturated very long-chain fatty acids in the central and peripheral nervous systems, adrenal tissue, and plasma.^{21,22} Both disorders cause progressive neurological decline, usually combined with dysfunction of the testes and adrenal glands. X-linked adrenoleukodystrophy generally manifests in childhood and is associated with an inflammatory cerebral myelinopathy. The AMN variant generally manifests in the third decade of life and primarily involves the spinal cord, causing progressive spastic paraparesis over decades.²³ Patients who lack clear signs of inflammatory involvement of the brain are classified as having pure AMN.²² Although some debate exists, the current hypothesis regarding pathophysiology of AMN implicates a noninflammatory axonopathy involving both the long tracts of the spinal cord and peripheral nerves.^{21,22} A primarily axonal sensorimotor peripheral neuropathy has been demonstrated with EDX studies in patients with AMN.²⁴

We present 3 families with various combinations of mutations in the *PMP-22*, *GJB1/Connexin-32*, *DMPK*, and *ABCD1* genes, leading to unusual and severe phenotypes.

CASE REPORTS

FAMILY 1

An 11-year-old boy (proband 1) was the product of a normal pregnancy and delivery. He was never able to crawl, did not walk until age 2 years, and used a walker for ambulation. Electrodiagnostic studies done at age 4 years revealed low-amplitude motor responses (range, 1.0-2.4 mV) in his upper and lower extremities with motor NCV rang-

ing from 11.2 to 17.5 m/s. A videotape made during a clinical evaluation at age 8 years showed a slow, unsteady, waddling gait with significant lumbar lordosis and a tendency to fall. His spinal misalignment progressed to a marked thoracolumbar kyphoscoliosis necessitating use of a power wheelchair. Examination at age 11 years showed marked bilateral symmetric muscle weakness and atrophy that was more prominent distally. Bilateral wrist drop, bilateral foot drop, completely absent deep tendon reflexes, and impaired distal sensation were also described. Respiratory compromise developed as documented by abnormal pulmonary function test results. He developed aspiration pneumonia and died during sleep at age 11 years.

The 15-year-old brother of proband 1 reached normal developmental milestones but required heel-cord lengthening surgery at age 18 months for plantar flexion contractures. At age 8 years, when the diagnosis of hereditary neuropathy was made in his younger brother, he had EDX testing, which demonstrated slowing of motor NCV, ranging from 12.2 to 13.6 m/s in the median and tibial nerves. Compound motor action potential responses were decreased (range, 0.5-5.4 mV) in the upper and lower extremities. Sensory responses were unobtainable. In an attempt to correct wrist drop, at age 11 years he had a tendon transfer in his right hand. Examination at age 15 years showed marked distal muscle atrophy and weakness of the upper and lower limbs, with absent tendon reflexes, bilateral pes cavus foot deformity, decreased light touch sensation in his feet, and enlarged ulnar and posterior auricular nerves.

Their 41-year-old father had atrophy of the intrinsic muscles of his hands, bilateral foot drop, depressed tendon reflexes, normal sensation, and enlarged ulnar nerves. The 39-year-old mother had no neurological symptoms. Her examination results were normal except for absent ankle reflexes.

Genetic analysis was performed by Athena Diagnostics, Worcester, Mass. Family DNA testing confirmed duplication of the *PMP-22* gene (*CMT1A*) in both probands, inherited from their father. Additionally, both had a missense mutation (arg200gly) in the *GJB1/Connexin-32* gene (*CMTX*), inherited from their mother.

FAMILY 2

A 32-year-old woman was noted to have clumsiness, trouble keeping up with her peer group, foot drop, and a pigeon-toe gait starting at approximately 4 years of age. Her weakness was slowly progressive, ultimately involving both proximal and distal muscles. At the age of 9 years, formal EDX testing showed motor NCV as low as 9 m/s in the lower extremities. A presumptive diagnosis of CMT was made. At age 12 years, examination noted long, thin facial features, and the possibility of MMD was entertained because her father reportedly had a diagnosis of probable MMD. Electrodiagnostic testing again confirmed very slow NCV in bilateral upper extremities ranging from 9 to 18 m/s. However, motor unit analysis showed mixed neuropathic and myopathic features with high-frequency discharges felt to be highly suggestive of myotonia. She remained independent in mobility despite

gradually increasing weakness and sensory loss. The patient ambulated without assistive device until approximately age 26 years, at which point she began using a single point cane and ultimately a walker. At age 28 years, she obtained a manual wheelchair and was subsequently fitted for a power wheelchair because of increasing upper extremity weakness. Repeated EDX testing at age 32 years revealed markedly slow motor NCV (21 m/s in ulnar nerve), low motor amplitudes (0.1 mV in peroneal nerve, 1.0 mV in ulnar nerve), and unobtainable sensory responses (**Figure 1**). Electromyography revealed diffuse myotonic discharges, with both large-amplitude, long-duration (neuropathic) and small-amplitude, short-duration (myopathic) polyphasic motor units and early recruitment. Despite obvious motor unit morphological abnormalities, the interference pattern analysis fell within normal range. This was owing to the presence of both neuropathic and myopathic motor units (**Figure 2**) (analyzed with a Viking IVp interference pattern analysis program; Nicolet Biomedical, Madison, Wis).²⁵ Recent physical examination showed a narrow face with ptosis, temporal muscle wasting, grip and percussion myotonia of her hands, distal greater than proximal weakness, atrophy of all limbs, and absent deep tendon reflexes. She had impaired appreciation of light touch, pinprick, vibration, and position in both feet. At age 32 years, she sustained a fall at home, was unable to get up from the floor, and had respiratory arrest. After resuscitation, she developed pneumonia, became septic, and died.

Genetic analysis was performed by Athena Diagnostics. The patient possessed duplication of the *PMP-22* gene, consistent with CMT1A. Her mother also has a documented *PMP-22* duplication and a milder CMT phenotype with motor NCV in the 19- to 24-m/s range. Additionally, the proband had a 1000-fold CTG trinucleotide repeat in the *DMPK* gene on chromosome 19q13.3 (genetic analysis by University of Washington Genetics Laboratory, Seattle), producing type 1 MMD. This was presumably inherited from her father, although he is estranged and formal testing has not been documented.

FAMILY 3

A 39-year-old man had pes cavus foot deformity since childhood and was rejected from the military at age 18 years because of it. At age 35 years, he was documented to have impaired distal sensation. Evaluation ensued, including EDX studies, which revealed variable slowing of NCV in the upper and lower extremities, notable for significant focal slowing of the ulnar nerve across the elbow (31 m/s) compared with the segment below the elbow (50 m/s). The amplitudes of the motor and sensory responses were within normal limits. For this reason, molecular testing was obtained for the CMT phenotype, and he was found to have a *PMP-22* deletion indicative of the HNPP syndrome. However, on examination, he also had signs of spasticity with hyperactive tendon reflexes and bilateral Babinski responses. Results of magnetic resonance imaging of the brain and spinal cord were entirely normal. As part of his evaluation for spasticity, elevated plasma very long-chain fatty acids were discovered.

Cortisol stimulation testing results were normal. Examination at age 39 years showed that he was ambulatory without assistance but had a slow, unsteady, scissoring gait. His mental status was normal and his cranial nerves were unremarkable. Muscle bulk and strength were normal in the upper limbs, but he had bilateral muscle atrophy and weakness below the knees with pes cavus deformity. Tendon reflexes were hyperactive at the knees with bilateral sustained ankle clonus and bilateral Babinski responses. There was decreased sensation to light touch, vibration, and position in both feet.

Neither parent was available for evaluation. His father was said to have had hammertoes. His mother was reported to have no neurological problems and no known family history of neurological disability.

Genetic analysis was performed by Athena Diagnostics. DNA analysis revealed a *PMP-22* gene deletion consistent with HNPP. DNA sequencing revealed a G-to-A substitution at nucleotide 1552 in the *ABCD1* gene, causing an amino acid substitution at codon 389 (R389H) (genetic analysis by Kennedy Krieger Institute, Baltimore, Md). This mutation, associated with X-linked AMN, has been previously reported.²⁶

COMMENT

Mutations in the *PMP-22* gene causing HMSN are among the most common inherited neuromuscular disorders.¹ For this reason, it can be expected that *PMP-22* mutations will occasionally, albeit rarely, occur simultaneously with a second neuromuscular genetic mutation. We report this rare occurrence in 3 families. These rare genetic coincidences allow observation of whether such concomitant mutations are augmentative physiologically and produce a novel phenotype.

In the first family, a father with CMT1A and a mother with CMTX had 2 sons who each inherited both mutations. These sons were affected by a severe hereditary peripheral neuropathy phenotype associated with NCVs less than 20 m/s. This unusual occurrence provided insight into the effects of combined mutations in these 2 myelin-related genes. *PMP-22* gene duplications (CMT1A) result in abnormal myelin adhesion with a typical demyelinating CMT phenotype and severe slowing of NCV, while missense mutations in the *GJB1/Connexin-32* gene (CMTX) cause abnormal gap junction function resulting in a CMT phenotype usually with less severe slowing of NCV.^{4,5,11,12} The brothers in family 1 demonstrate that the simultaneous occurrence of genetic abnormalities both affecting a different aspect of myelin function are, in fact, augmentative. This combination results in a severe CMT phenotype with very slow NCV. The younger brother in this family could be characterized as having the Dejerine-Sottas syndrome, a severe demyelinating neuropathy characterized by early childhood-onset, delayed motor milestones; sensory ataxia; and extremely reduced NCVs. Dejerine-Sottas syndrome is heterogeneous and most often associated with a point mutation, not duplication, in the *PMP-22* gene.²⁷ This patient's neuropathy was so severe that he required a wheelchair by age 8 years and had kyphoscoliosis caus-

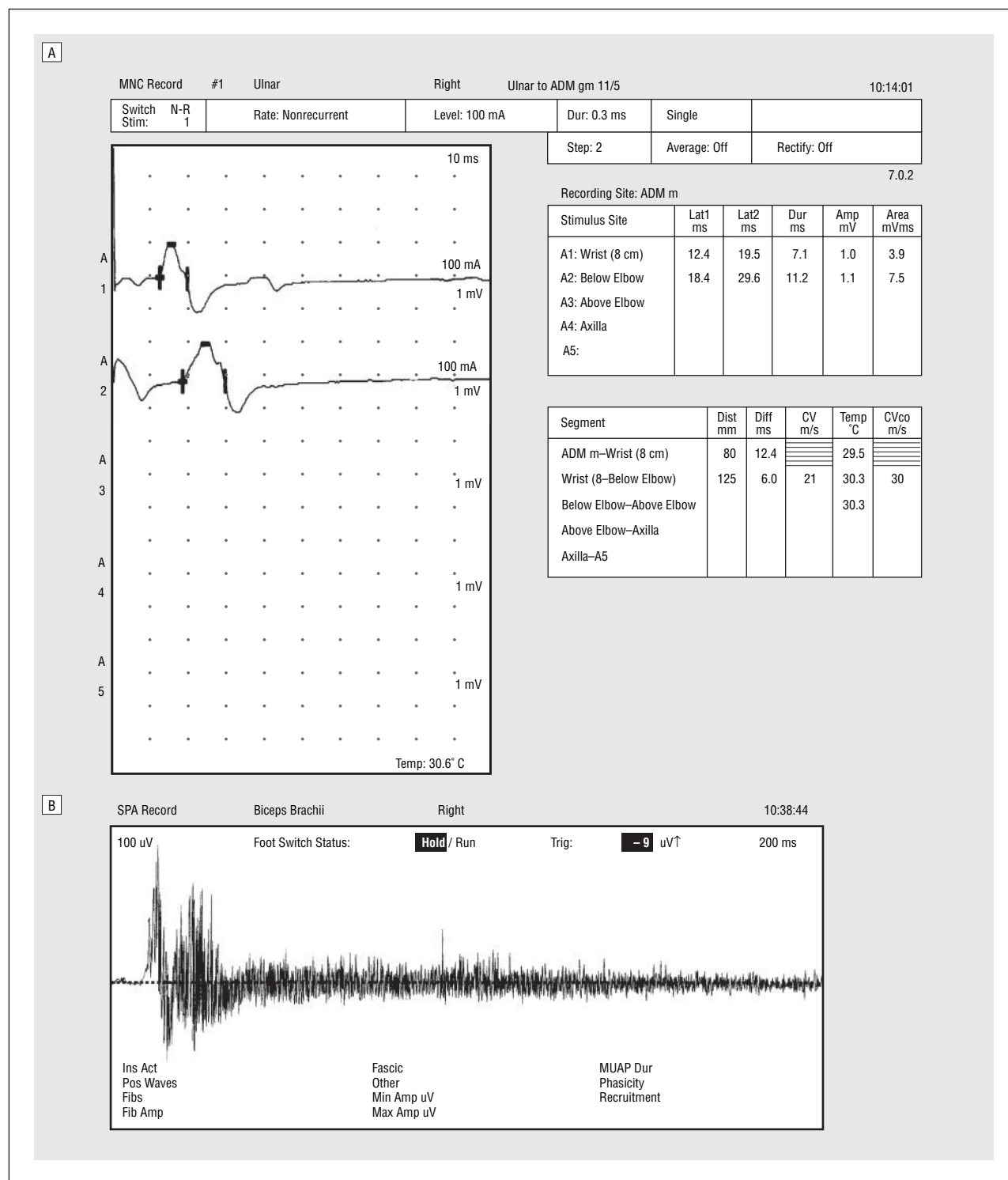


Figure 1. Right ulnar nerve motor nerve conduction study from proband in family 2 (A) and insertional-needle electromyograph of right biceps brachii from proband in family 2 (B). A, Right ulnar nerve demonstrates significantly slowed conduction velocity and decreased amplitude. Additionally, averaging of multiple right peroneal (fibular) nerve stimulations at the fibular head produced a small amplitude (0.1-mV) compound motor action potential with onset latency of 10.1 milliseconds recorded at the extensor digitorum brevis. Sensory nerve action potential responses were unobtainable in the upper and lower extremities. ADM m indicates abductor digiti minimi (manus). B, Electromyograph demonstrating electrical myotonia. This was also present in the extensor carpi radialis and first dorsal interosseus. Further needle study showed both large-amplitude, long-duration and small-amplitude, short-duration polyphasic motor units on minimal voluntary activation in these same muscles. Early recruitment was also observed.

ing respiratory compromise and death at an early age. His phenotype was much more severe than would be expected with either mutation occurring alone.³ The older brother, despite having the same genotype, had clearly

less severe clinical manifestations than his younger brother. This suggests that even in this neuropathy caused by dual genetic mutations, there are likely other genetic and/or environmental factors influencing the ultimate phe-

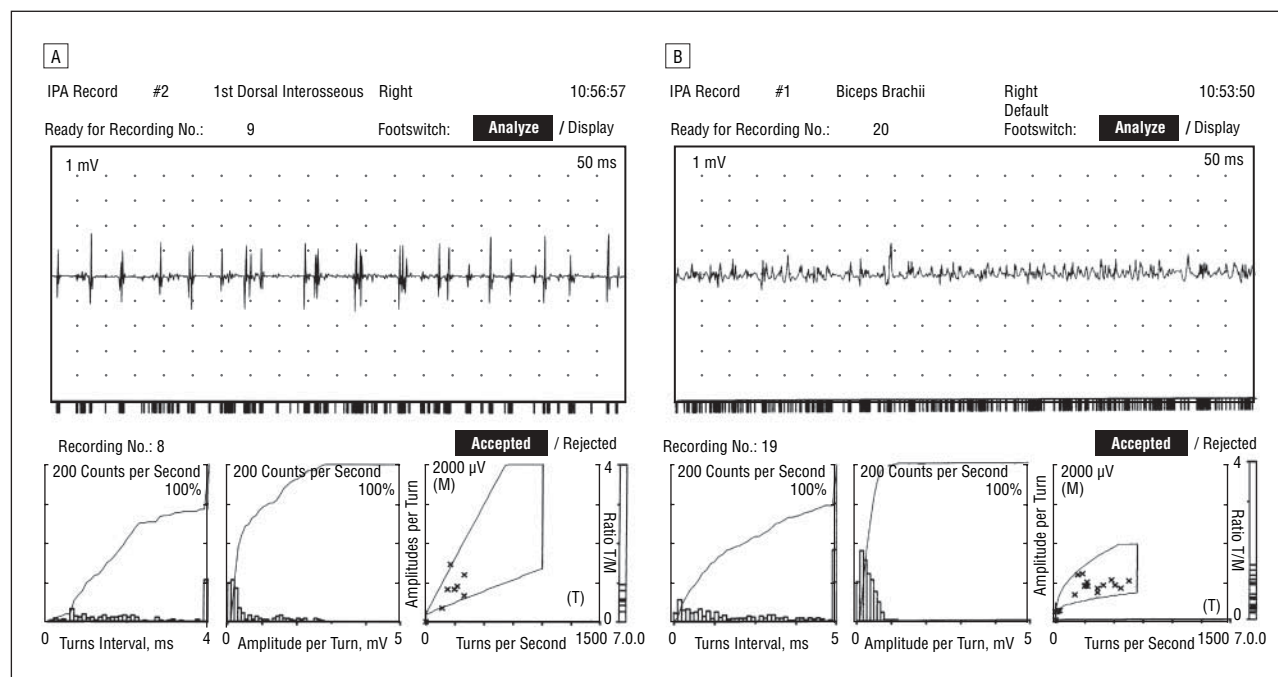


Figure 2. Interference pattern cloud analysis of proband in family 2. Recordings were made from both the right first dorsal interosseus (A) and the right biceps brachii (B). All data points fall within the normal cloud range on the turns per second–amplitude per turn graph in the lower right corner of A and B. None of the data points fall in the neuropathic range (above the normal cloud) or in the myopathic range (below the normal cloud). This represents a false-negative result because the patient has evidence, clinically and electrodiagnostically, of both peripheral neuropathy and myotonic myopathy.

notypic outcome. However, there are no obvious differences in the brothers' environment.

In the second family, there was an individual with a combination of CMT1A and MMD documented by genetic testing. Although evidence of a peripheral axonopathy has been reported in MMD based on EDX and nerve biopsy data, this patient clinically had a more severe neuropathy than is characteristically seen in MMD alone.¹⁴ On examination, she demonstrated signs of both significantly reduced peripheral sensation and myotonia with severe proximal and distal muscle weakness. Her EDX studies revealed both chronic neuropathic and myopathic motor units. Interestingly, this mixed picture of motor unit morphology resulted in normal interference cloud pattern analysis in all muscles tested, yielding a false-negative result. Her overall physical disability was more severe than usually seen with either CMT or MMD alone, and her death of respiratory failure at age 32 years emphasizes this fact. Hence, it appears that these 2 mutations have an augmentative effect primarily resulting from diffuse muscle weakness and atrophy.

The third family consisted of a single proband with signs of both neuropathy and spasticity associated with a *PMP-22* gene deletion causing HNPP and a mutation in the *ABCD1* gene associated with X-linked AMN. Hereditary neuropathy with liability to pressure palsies is characterized by recurrent pressure-induced neuropathies, while AMN is a peroxisomal disorder associated with myelopathy.^{11,23,24} An underlying sensorimotor neuropathy has been described in both disorders, with demyelinating features in HNPP and axonal features in AMN.^{11,24} Electrodiagnostic data in this case points toward a primarily demyelinating neuropathy with variable, focal slowing of motor NCVs but relative preser-

vation of motor and sensory amplitudes as would be seen in HNPP. In addition, this patient has bilateral pes cavus foot deformities that are not typical of AMN and are likely related to HNPP. Despite having distal sensory loss and pes cavus deformities, this patient's primary disability was related to his spastic gait, which is typical of AMN.²³ Overall, in this individual, both genetic mutations appear to have contributed to the phenotype; AMN caused spasticity, while HNPP led to a clinically worse peripheral neuropathy with more demyelinating features than would be expected in AMN alone.

Each of these families had probands with mutations in the *PMP-22* gene simultaneously occurring with a mutation in another neuromuscular gene. Rather than a simple expression of the expected deficits from the individual mutations, these patients had unique phenotypic manifestations, illustrating an augmentative "double trouble" effect. The most severe effect, phenotypically, was associated with double mutations in genes that both control myelin function (*PMP-22*, *GJB1/Connexin-32*). A similar early onset of neuropathy in subjects with 2 myelin gene mutations (*PMP-22* duplication, *LITAF/SIMPLE*, *EGR 2*, and *GJB1*) has been reported.^{28,29} The combination of a mutation causing peripheral neuropathy (*PMP-22*) and a myopathy (*DMPK*) resulted in an unusual "neuromyopathic manifestation" that yielded a faux-normal interference cloud pattern analysis on EDX testing. Although controversial, there is also evidence of DM1 being associated with an axonal neuropathy, and this is likely to have added to the severe phenotype of the woman in family 2.¹⁸⁻²⁰ The last case demonstrated the augmentative effect of HNPP and AMN-associated spasticity on the patient's functional status.

It seems intuitive that having 2 genetic disorders affecting the nervous system would produce a worse phe-

notype, but that is not always the case. For example, in our clinic population, we have seen 1 person who had both trisomy 21 and MMD whose cognitive and behavioral phenotype was no worse than either disorder separately, and a similar result occurred in a person having both tuberous sclerosis and Friedreich ataxia.^{30,31} However, having 2 diseases directly affecting the same part of the nervous system, such as the peripheral nerves, is more likely to have a cumulative negative effect.

In addition to allowing observation of synergistic genetic interactions, these cases also illustrate some important clinical points. When EDX testing is used to assist in the diagnosis of rare neuromuscular disorders, careful attention must be paid to the characteristics of peripheral neuropathies (axonal vs demyelinating). If the character of the identified neuropathy is not what is expected based on genetic testing, additional genetic screening for a second mutation should be considered. Additionally, in the presence of a mixed neuropathy and myopathy, some of the motor unit abnormalities may be masked or appear falsely normal on cloud analysis. Overall, these cases stress the importance of considering additional DNA testing in patients with known mutations who have unusual (especially severe) phenotypes or additional, unexplained neuromuscular problems.

Accepted for Publication: July 8, 2005.

Correspondence: Thomas D. Bird, MD, 1660 S Columbian Way, S-182-GRECC, Seattle, WA 98108 (tomnroz@u.washington.edu).

Author Contributions: *Study concept and design:* Hodapp, Carter, Kraft, and Bird. *Acquisition of data:* Hodapp, Lipe, Michelson, Kraft, and Bird. *Analysis and interpretation of data:* Hodapp, Carter, and Bird. *Drafting of the manuscript:* Hodapp, Carter, and Bird. *Critical revision of the manuscript for important intellectual content:* Hodapp, Carter, Lipe, Michelson, Kraft, and Bird. *Obtained funding:* Bird. *Administrative, technical, and material support:* Hodapp, Carter, Lipe, Michelson, Kraft, and Bird. *Study supervision:* Carter, Kraft, and Bird.

Financial Disclosure: Dr Bird is a member of the Athena Diagnostics, Inc (Worcester, Mass) Speakers' Bureau.

Funding and Support: This study was supported by Veterans Affairs Research Funds; the Muscular Dystrophy Association, Tucson, Ariz; grant U54-AR05074101 from the National Institutes of Health National Institute of Arthritis and Musculoskeletal and Skin Diseases, Bethesda, Md; and the University of Washington Center for Human Development and Disability, Seattle.

Additional Information: PMP-22 genetic analysis was performed by Athena Diagnostics; DMPK genetic analysis, by the University of Washington Genetics Laboratory; and ABCD1 genetic analysis, by Kennedy Krieger Institute, Baltimore, Md.

REFERENCES

- Emery AEH. Population frequencies of inherited neuromuscular diseases: a world survey. *Neuromuscular Disorders*. 1991;1:19-29.
- Boerkoel CF, Takashima H, Garcia CA, et al. Charcot-Marie-Tooth disease and related neuropathies: mutation distribution and genotype-phenotype correlation. *Ann Neurol*. 2002;51:190-201.
- Carter GT, Abresch RT, Fowler WM Jr, et al. Profiles of neuromuscular diseases: hereditary motor and sensory neuropathy, types I and II. *Am J Phys Med Rehabil*. 1995;74(5 suppl):S140-S149.
- Saifi GM, Szigeti K, Snipes GJ, et al. Molecular mechanisms, diagnosis, and rational approaches to management of and therapy for Charcot-Marie-Tooth disease and related peripheral neuropathies. *J Invest Med*. 2003;51:261-283.
- Carenini S, Neuberg D, Schachner M, et al. Localization and functional roles of PMP-22 in peripheral nerves of P0-deficient mice. *Glia*. 1999;28:256-264.
- Lupski JR, de Oca-Luna RM, Slaugenhaupt S, et al. DNA duplication associated with Charcot-Marie-Tooth disease type 1A. *Cell*. 1991;66:219-232.
- Chance PF, Alderson MK, Leppig KA, et al. DNA deletion associated with hereditary neuropathy with liability to pressure palsies. *Cell*. 1993;72:143-151.
- Kamholz J, Menichella D, Jani A, et al. Charcot-Marie-Tooth disease type 1: molecular pathogenesis to gene therapy. *Brain*. 2000;123:222-233.
- Carter GT, England JD, Chance PF. Charcot-Marie-Tooth disease: electrophysiology, molecular genetics and clinical management. *IDrugs*. 2004;7:151-159.
- Birouk N, Maisonobe T, Le Forestier N, et al. Charcot-Marie-Tooth disease: electromyography is still useful in diagnosis and classification. *Rev Neurol (Paris)*. 1997;153:727-736.
- Hong YH, Kim M, Kim HJ, et al. Clinical and electrophysiologic features of HNPP patients with 17p11.2 deletion. *Acta Neurol Scand*. 2003;108:352-358.
- Abrams CK, Freidin M, Bukauskas F, et al. Pathogenesis of X-linked Charcot-Marie-Tooth disease: differential effects of two mutations in connexin 32. *J Neurosci*. 2003;23:10548-10558.
- Gutierrez A, England JD, Sumner AJ, et al. Unusual electrophysiological findings in X-linked dominant Charcot-Marie-Tooth disease. *Muscle Nerve*. 2000;23:182-188.
- Harper PS. *Major Problems in Neurology: Myotonic Dystrophy*. 3rd ed. London, England: WB Saunders Harcourt Publishers Ltd; 2001.
- Mankodi A, Thornton CA. Myotonic syndromes. *Curr Opin Neurol*. 2002;15:545-552.
- Ranum LP, Day JW. Myotonic dystrophy: RNA pathogenesis comes into focus. *Am J Hum Genet*. 2004;74:793-804.
- Pfeilsticker BH, Bertuzzo CS, Nucci A. Electrophysiological evaluation in myotonic dystrophy: correlation with CTG length expansion. *Arq Neuropsiquiatr*. 2001;59:186-191.
- Jamal GA, Weir AI, Hansen S, Ballantyne JP. Myotonic dystrophy: a reassessment by conventional and more recently introduced neurophysiological techniques. *Brain*. 1986;109:1279-1296.
- Cros D, Harnden P, Pouget J, et al. Peripheral neuropathy in myotonic dystrophy: a nerve biopsy study. *Ann Neurol*. 1988;23:470-476.
- Mondelli M, Rossi A, Malanderini A, et al. Axonal motor and sensory neuropathy in myotonic dystrophy. *Acta Neurol Scand*. 1993;88:141-148.
- Moser HW. Adrenoleukodystrophy: phenotype, genetics, pathogenesis and therapy. *Brain*. 1997;120:1485-1508.
- Moser H, Dubey P, Fatemi A. Progress in X-linked adrenoleukodystrophy. *Curr Opin Neurol*. 2004;17:263-269.
- Spurek M, Taylor-Gjevve R, Van Uum S, Khandwala HM. Adrenomyeloneuropathy as a cause of primary adrenal insufficiency and spastic paraparesis. *CMAJ*. 2004;171:1073-1077.
- van Geel BM, Koelman JH, Barth PG, Ongerboer de Visser BW. Peripheral nerve abnormalities in adrenomyeloneuropathy: a clinical and electrodiagnostic study. *Neurology*. 1996;46:112-118.
- Stalberg E, Chu J, Bril V, et al. Automatic analysis of the EMG interference pattern. *Electroencephalogr Clin Neurophysiol*. 1983;56:672-681.
- Human Gene Mutation Database at the Institute of Medical Genetics in Cardiff Web site. Available at: <http://archive.uwcm.ac.uk/uwcm/mg/hgmd0.html>.
- Marques W Jr, Neto JM, Barreira AA. Dejerine-Sottas' neuropathy caused by the missense mutation PMP22 Ser72Leu. *Acta Neurol Scand*. 2004;110:196-199.
- Meggough F, de Visser M, Arts WF, et al. Early onset neuropathy in a compound form of Charcot-Marie-Tooth disease. *Ann Neurol*. 2005;57:589-591.
- Chung KW, Sunwoo IN, Kim SM, et al. Two missense mutations of EGR2 R359W and GJB1 V136A in a Charcot-Marie-Tooth disease family. *Neurogenetics*. 2005;6:159-163.
- Bird TD. Myotonic dystrophy associated with Down's syndrome (trisomy 21). *Neurology*. 1981;31:440-442.
- Walker M, Samii A, Bird TD. Coexistence of tuberous sclerosis and Friedreich's ataxia. *J Neurol Sci*. 2004;221:91-93.

atic CJD are not yet available, their development should be another major effort in the improvement of pharmacotherapy for CJD.

Accepted for Publication: September 1, 2005.

Correspondence: Carsten Korth, MD, Institute for Neuropathology, Heinrich Heine University Duesseldorf, Moorenstrasse 5, 40225 Duesseldorf, Germany (ckorth@uni-duesseldorf.de).

Author Contributions: *Study concept and design:* Korth and Peters. *Acquisition of data:* Korth. *Analysis and interpretation of data:* Korth. *Drafting of the manuscript:* Korth. *Critical revision of the manuscript for important intellectual content:* Korth and Peters. *Obtained funding:* Korth. *Administrative, technical, and material support:* Korth. *Study supervision:* Korth and Peters.

Funding/Support: This study was supported by grant 01KO0107 from the Federal Ministry of Education and Research, Germany (Dr Korth), and grant QLK2-CT-2002-81628 from the European Union (Dr Peters).

Acknowledgment: We acknowledge the work and numerous articles on prion pharmacotherapy that could not be cited in this short review because of space constraints.

REFERENCES

1. Prusiner SB. Prions. *Proc Natl Acad Sci U S A*. 1998;95:13 363-13 383.
2. Will RG. Acquired prion disease: iatrogenic CJD, variant CJD, kuru. *Br Med Bull*. 2003;66:255-265.
3. Mallucci G, Dickinson A, Linehan J, Kohn PC, Brandner S, Collinge J. Depleting neuronal PrP in prion infection prevents disease and reverses spongiosis. *Science*. 2003;302:871-874.
4. White AR, Enever P, Tayebi M, et al. Monoclonal antibodies inhibit prion replication and delay the development of prion disease. *Nature*. 2003;422:80-83.
5. Doh-ura K, Ishikawa K, Murakami-Kubo I, et al. Treatment of transmissible spongiform encephalopathy by intraventricular drug infusion in animal models. *J Virol*. 2004;78:4999-5006.
6. Otto M, Cepek L, Ratzka P, et al. Efficacy of flupirtine on cognitive function in patients with CJD: a double-blind study. *Neurology*. 2004;62:714-718.
7. Korth C, May BCH, Cohen FE, Prusiner SB. Acridine and phenothiazine derivatives as pharmacotherapeutics for prion disease. *Proc Natl Acad Sci U S A*. 2001;98:9836-9841.
8. Ryou C, Lessard P, Freyman Y, et al. In vivo efficacy of quinacrine in animal models of prion disease. Paper presented at: First International Conference of the European Network of Excellence NeuroPrion; May 24-28, 2004; Paris, France. Abstract THE-29.
9. Gayraud V, Picard-Hagen N, Viguie C, Laroute V, Andreoletti O, Toutain PL. A possible pharmacological explanation for quinacrine failure to treat prion diseases: pharmacokinetic investigations in a ovine model of scrapie. *Br J Pharmacol*. 2005;144:386-393.
10. Haik S, Brandel JP, Salomon D, et al. Compassionate use of quinacrine in Creutzfeldt-Jakob disease fails to show significant effects. *Neurology*. 2004;63:2413-2415.

Correction

Error in Text. In the Original Contribution by Hodapp et al titled "Double Trouble in Hereditary Neuropathy: Concomitant Mutations in the PMP-22 Gene and Another Gene Produce Novel Phenotypes," published in the January issue of the ARCHIVES (2006;63:112-117), on page 113 in the "Family 1" subsection of the "Case Reports" section, the genetic analysis showing the missense mutation in the *GJB1/Connexin-32* gene should be Arg220Gly instead of arg200gly.