ORIGINAL CONTRIBUTION

Evidence of Multisystem Disorder in Whole-Brain Map of Pathological TDP-43 in Amyotrophic Lateral Sclerosis

Felix Geser, MD; Nicholas J. Brandmeir, MS; Linda K. Kwong, PhD; Maria Martinez-Lage, MD; Lauren Elman, MD; Leo McCluskey, MD; Sharon X. Xie, PhD; Virginia M.-Y. Lee, PhD, MBA; John Q. Trojanowski, MD, PhD

Background: Pathological 43-kDa transactivating responsive sequence DNA-binding protein (TDP-43) has been identified recently as the major disease protein in amyotrophic lateral sclerosis (ALS), and in frontotemporal lobar degeneration with ubiquitinated inclusions, with or without motor neuron disease, but the distribution of TDP-43 pathology in ALS may be more widespread than previously described.

Objective: To determine the extent of TDP-43 pathology in the central nervous systems of patients with clinically confirmed and autopsy confirmed diagnoses of ALS.

Design: Performance of an immunohistochemical whole–central nervous system scan for evidence of pathological TDP-43 in ALS patients.

Setting: An academic medical center.

Participants: We included 31 patients with clinically and pathologically confirmed ALS and 8 control participants.

Main Outcome Measures: Immunohistochemistry and double-labeling immunofluorescence to assess the frequency and severity of TDP-43 pathology.

Results: In addition to the stereotypical involvement of upper and lower motor neurons, neuronal and glial TDP-43 pathology was present in multiple areas of the central nervous systems of ALS patients, including in the nigro-striatal system, the neocortical and allocortical areas, and the cerebellum, but not in those of the controls.

Conclusions: These findings suggest that ALS does not selectively affect only the pyramidal motor system, but rather is a multisystem neurodegenerative TDP-43 proteinopathy.

Arch Neurol. 2008;65(5):636-641

Author Affiliations: Center for Neurodegenerative Disease Research, Department of Pathology and Laboratory Medicine, Alzheimer's Disease Core Center, Institute on Aging (Drs Geser, Kwong, Martinez-Lage, Lee, and Trojanowski, and Mr Brandmeir), Department of Neurology (Drs Elman McCluskey), and Department of Biostatistics and Epidemiology (Dr Xie), University of Pennsylvania School of Medicine, Philadelphia; and the Neurosciences Institute, Albany Medical College, Albany, New York (Mr Brandmeir).

PATHOLOGICAL 43-KDA TRANSactivating responsive sequence DNA-binding protein (TDP-43) has been identified as the major disease protein in amyotrophic lateral sclerosis (ALS), and in frontotemporal lobar degeneration (FTLD) with ubiquitin-positive inclusions, with or without motor neuron disease. Indeed, TDP-43 inclusions in the central nervous system (CNS) appear to be diagnostic of these disorders, and may underlie some of their mechanisms of neurodegeneration.[1-3] Although the functions of TDP-43 are poorly understood, TDP-43 is a ubiquitously expressed, highly conserved nuclear protein that appears to be involved in transcriptional repression and alternative splicing, and may act as a scaffold for nuclear bodies through interactions with survival motor neuron proteins.[1] Amyotrophic lateral sclerosis is historically considered to be the prototypical pyramidal motor system neurodegenerative disease, and the presence of additional features has usually been considered to negate the diagnosis of classic ALS, therefore indicating ALS-Plus syndrome, according to El Escorial clinical diagnostic criteria.[4] These criteria suggests that the diagnosis of ALS requires evidence of lower and upper motor neuron degeneration, the progressive spread of symptoms, and the absence of other disease processes that might explain the degeneration of upper and lower motor neurons.[5] The whole-brain distribution of CNS degeneration and pathology in ALS is not well described. Therefore, we performed an immunohistochemical whole-brain scan for evidence of pathological TDP-43 in a large cohort of sporadic ALS patients. We found TDP-43 pathology in multiple brain areas, suggesting that ALS is a disease that not only affects the pyramidal motor system, but instead is a multisystem neurodegenerative TDP-43 proteinopathy.

©2008 American Medical Association. All rights reserved.
Downloaded From: https://jamanetwork.com/ on 02/24/2022

METHODS

PARTICIPANTS

We examined a cohort of ALS patients as well as control participants without overt neurological or cognitive dysfunction. Clinically diagnosed ALS patients were included whose diagnosis was confirmed at autopsy and was consistent with the El Escorial criteria. In 5 patients, the motor neuron disease was accompanied by cognitive impairment (ALS-dementia). The participants were longitudinally followed in the Penn ALS Center; CNS samples came from the Center for Neurodegenerative Disease Research Brain Bank at the Penn center following neuropathology diagnostic assessment, as described.[1] Informed consent for autopsy was obtained from the legal representative in accordance with the local institutional review board.

IMMUNOHISTOCHEMISTRY AND MICROSCOPIC ANALYSIS

Fresh tissues from the brain and spinal cord were fixed in 10% neutral buffered formalin, or in 70% ethanol with 150-mmol sodium chloride, paraffin-embedded, and cut into 6-µm sections. Sections were stained with hematoxylin and eosin, while immunohistochemistry was performed by means of the avidin–biotin complex detection technique (Vectastatin ABC kit; Vector Laboratories, Burlingame, California) with 3,3-diaminobenzidine as chromogen, using previously described methods.[1,6] The following primary antibodies were used: mouse monoclonal anti-ubiquitin 1510 (1:100 000) (Chemicon International, Temecula, California); rabbit polyclonal anti-TDP-43 (1:4 500) (Protein-Tech Group, Chicago, Illinois); and mouse monoclonal anti-TDP-43 (1:10 000) (Novus Biologicals, Littleton, Colorado). Sections were boiled in a pressure cooker in citrate antigen unmasking solution (Vector Laboratories) and counterstained with hematoxylin after immunohistochemistry. Double-labeling immunofluorescence was performed using the same primary antibodies and Alexa Fluor 488 and 594 conjugated secondary antibodies (Molecular Probes, Eugene, Oregon) followed by coverslipping with Vectashield-DAPI-mounting medium (Vector Laboratories), as described.[1] Digital images of immunohistochemical preparations were obtained using an Olympus BX 51 (Tokyo, Japan) microscope equipped with bright-field and fluorescence light sources with a digital camera, the DP71 (Olympus, Orangeburg, New York), and DP manager (Olympus). Digital images of immunofluorescence preparations were obtained using a Nikon TE2000 microscope (Nikon Instruments, Inc, Melville, New York) and were captured with a CoolSNAP Monochrome camera (Photometrics, Tucson, Arizona) and MetaMorph software (Molecular Devices, Downingtown, Pennsylvania). Neuropathological workup excluded all neurodegenerative diseases other than ALS, as described.[1,6]

STATISTICAL ANALYSIS

All data were analyzed using SPSS 15.0 for Windows (SPSS, Chicago, Illinois). The disease duration of the ALS patients was calculated as the median (interquartile range). The *t* test was used to compare the mean (SD) age at death of ALS patients and control participants. Severity ratings of TPD-43 pathology were performed using an arbitrary ordinal scale (0, none; 1, mild; 2, moderate; 3, severe).[6] The median rating scores were calculated from grouped data across all patients for each region. Grouped data denotes that 1 stage follows continuously into the other; therefore, they represent classes rather than clearly distinguishable values on a numerical scale.

RESULTS

We examined 31 ALS patients (13 women and 18 men). Median disease duration was 2.0 years (interquartile range, 1.0-3.0 years), and mean (SD) age at death was 58.7 (10.1) years. We also scrutinized 8 control participants (5 women and 3 men); mean (SD) age at death was 64.8 (6.6) years, without overt neurological or cognitive dysfunction. There was no significant difference in age at death when comparing ALS patients with control participants (t_{37}=-1.592, P=.12).

In addition to the stereotypical involvement of upper and lower motor neurons, pathological TDP-43 was present in multiple brain areas far beyond the pyramidal motor system, including the nigrostriatal system, neocortical and allocortical areas, and the cerebellum to a variable extent. Remarkably, none of the areas examined here were devoid of TDP-43 pathology. The frequency of TDP-43 pathology (percentage of cases in which TDP-43 was observed) is depicted in **Figure 1**, which also shows a color-coded topographical distribution scheme of pathology, based on severity ratings (**Table**). The median values of the ratings were calculated for all investigated cases. Cellular inclusions of all types were encountered throughout the CNS in the ALS patients; none were observed in the control participants. Although the number of ALS cases with associated dementia (n=5) was too small for formal statistical comparison, the pathology in various neocortical brain areas or in the hippocampus appear to be more severe in ALS-dementia than in ALS without cognitive dysfunction. There was a trend suggesting that some subcortical structures were more severely affected in ALS-dementia, and it is possible that studies of a larger cohort of ALS-dementia patients might demonstrate statistical significance for these findings. Also, the small number of patients without bulbar findings (n=4) did not significantly differ from patients with bulbar dysfunction. Neuronal cytoplasmic inclusion pathology included skein-like inclusions, Lewy body–like inclusions, and smaller, dense granules detected by multiple anti-TDP-43 antibodies (**Figure 2**). As described, the nuclei of affected neurons were devoid of the normal endogenous TDP-43 staining.[1] This also occurred in neurons with dense, diffuse, or granular cytoplasmic staining in the absence of bulky inclusions, which may reflect incipient TDP-43 inclusions or preinclusions. Presence of TDP-43 neuronal intranuclear inclusions was rare. Glial TDP-43 pathology was more frequent in the white as compared with the gray matter. In fact, oligodendroglial and, less commonly, astrocytic TDP-43-positive inclusions were encountered. Also, TDP-43 immunoreactive dystrophic neurites were widespread (Figures 1B and 2I). Double-labeling immunofluorescence studies on nigral sections showed that the Lewy body–like inclusions were TDP-43-positive and ubiquitin-positive, but some neuronal inclusions and almost all glial inclusions were positive only for TDP-43 (**Figure 3**). The cohort contained 4 cases with a family history of neurodegenerative disease, including motor neuron disease (without superoxide dismutase-1 mutations), parkinsonism, and dementia (in 2 cases). Of these, the first 2 cases were the only ones

©2008 American Medical Association. All rights reserved.
Downloaded From: https://jamanetwork.com/ on 02/24/2022

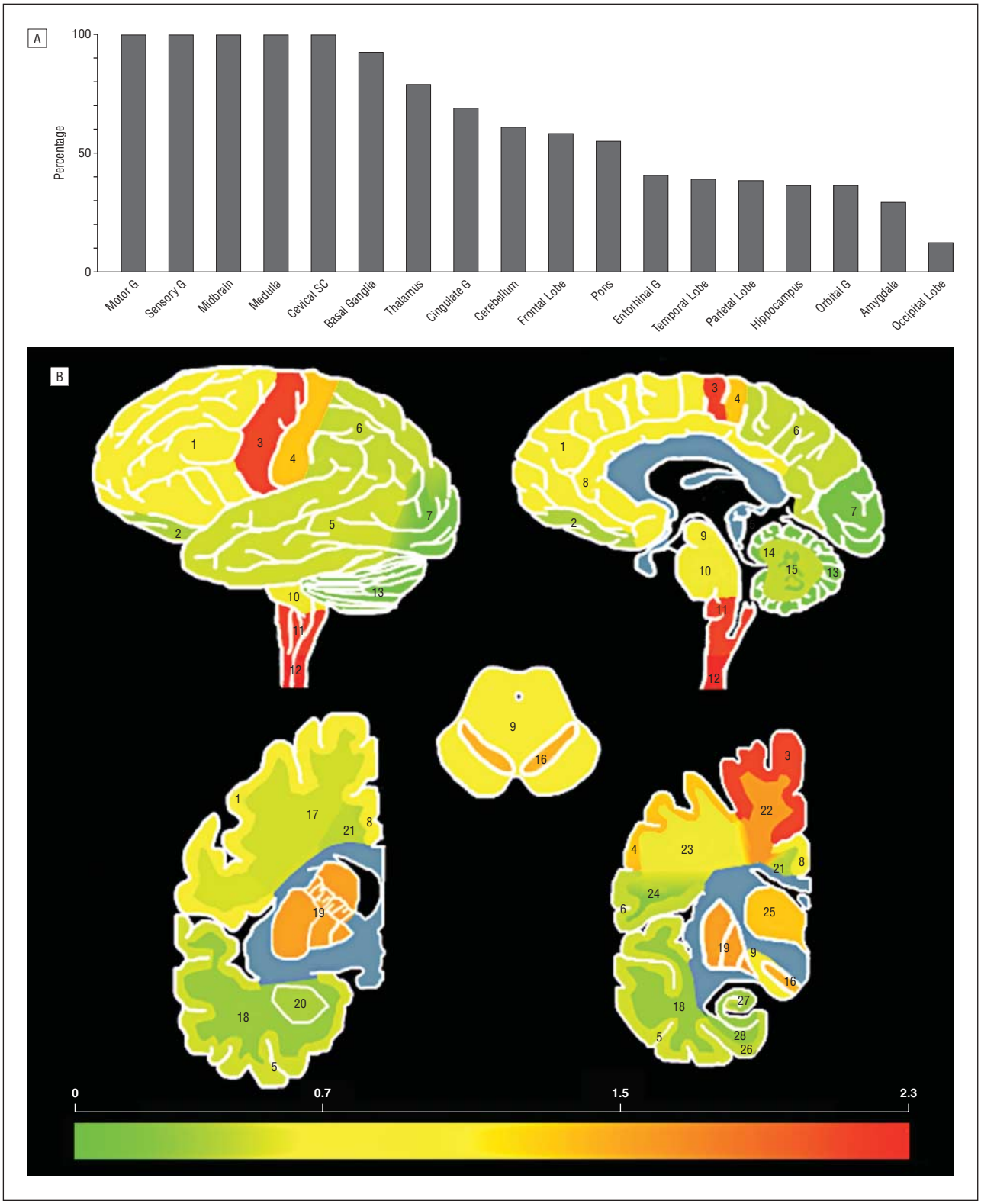

Figure 1. Frequency and severity of 43-kDa transactivating responsive sequence DNA-binding protein (TDP-43) pathology in amyotrophic lateral sclerosis (ALS). A, Bar graph of frequency (percentage of cases in which TDP-43 was observed) of pathological TDP-43 in ALS across salient brain areas. G indicates gyrus; SC, spinal cord. B, Whole-brain "heat" map of TDP-43 pathology in the central nervous system (CNS) of patients with ALS, based on the severity of TDP-43 deposits. Sagittal, lateral, coronal, and cross sections of CNS regions are shown. Colors reflect median severity scores across all cases calculated from grouped data (Table). The subjacent color scale depicts median scores from zero (green) to highest scores (red) in each region examined, and blue indicates unexamined regions. The numeral 1 indicates frontal lobe gray matter; 2, orbital gyrus gray matter; 3, motor cortex gray matter; 4, sensory gyrus gray matter; 5, temporal lobe gray matter; 6, parietal lobe gray matter; 7, occipital lobe gray matter; 8, cingulate gyrus gray matter; 9, midbrain; 10, pons; 11, medulla; 12, cervical spinal cord; 13, cerebellum gray matter; 14, cerebellum white matter; 15, dentate nucleus in the cerebellum; 16, substantia nigra; 17, frontal lobe white matter; 18, temporal lobe white matter; 19, basal ganglia; 20, amygdala; 21, cingulate gyrus white matter; 22, motor cortex white matter; 23, sensory cortex white matter; 24, parietal lobe white matter; 25, thalamus; 26, entorhinal cortex; 27, hippocampus (cornu ammonis 4 [CA4]–CA1/subiculum and dentate gyrus); and 28, entorhinal cortex white matter.

©2008 American Medical Association. All rights reserved.
Downloaded From: https://jamanetwork.com/ on 02/24/2022

Table. Frequency and Severity of TDP-43 Pathology in ALS

Area of the Brain	Sample Size, No.[a]	Frequency, %[b]	Median Severity[c]
Motor cortex gray matter	31	100	2.1
Motor cortex white matter	31	96.8	1.6
Basal ganglia	29	93.1	1.6
Thalamus	29	79.3	1.3
Substantia nigra	29	96.6	1.4
Midbrain other	29	55.2	0.6
Pons	31	54.8	0.6
Cerebellum cortex	26	11.5	0.1
Cerebellum white matter	28	42.9	0.4
Cerebellum dentate nucleus	25	24	0.3
Medulla	29	100	2.1
Cervical spinal cord	28	100	2.3
Midfrontal cortex gray matter	31	58.1	0.7
Midfrontal cortex white matter	30	43.3	0.5
Orbital grey matter	28	35.7	0.4
Orbital white matter	28	14.3	0.2
Cingulate gray matter	26	69.2	0.9
Cingulate white matter	27	29.6	0.4
Sensory cortex gray matter	6	100.0	1.3
Sensory cortex white matter	6	50.0	0.6
Temporal cortex gray matter	26	38.5	0.5
Temporal cortex white matter	26	26.9	0.3
Parietal cortex gray matter	30	40	0.5
Parietal cortex white matter	30	26.7	0.3
Occipital cortex gray matter	27	11.1	0.1
Occipital cortex white matter	26	3.8	0.0
Entorhinal cortex gray matter	29	37.9	0.4
Entorhinal cortex white matter	29	24.1	0.3
Hippocampus CA4-CA1/subiculum	28	25	0.3
Hippocampus dentate gyrus	28	35.7	0.5
Amygdala	28	28.6	0.4

Abbreviations: ALS, amyotrophic lateral sclerosis; CA, cornu ammonis; TDP-43, 43-kDa transactivating responsive sequence DNA-binding protein.
[a] Total number of cases with tissue available.
[b] Percentage of positive cases among those with available tissue.
[c] Based on all examined cases, median is calculated from grouped data (grading system: 0, none; 1, mild; 2, moderate; and 3, severe).

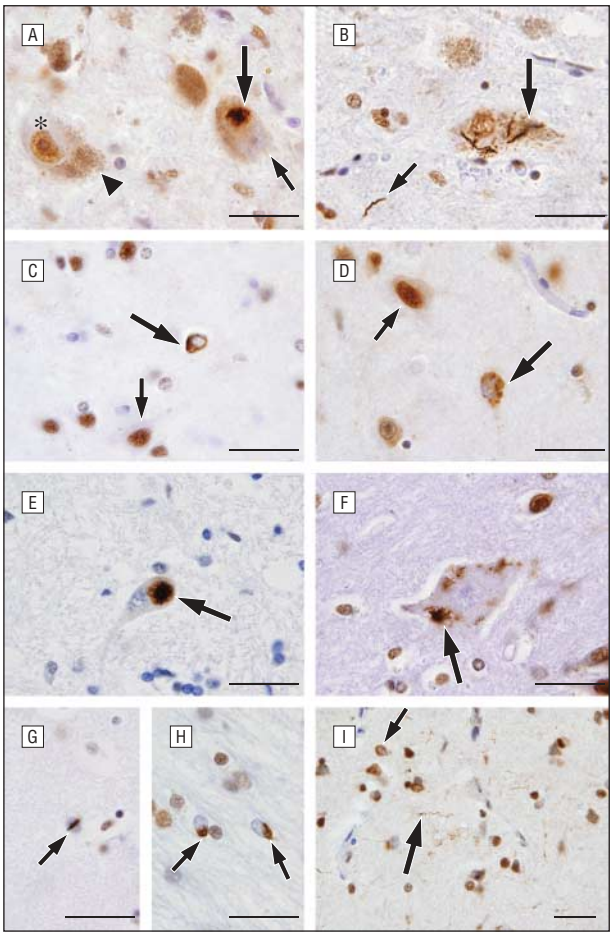

Figure 2. Anti–43-kDa transactivating responsive sequence DNA-binding protein (TDP-43) immunohistochemistry in amyotrophic lateral sclerosis (ALS) with dementia (A-E, H, I) or without dementia (F, G) (bar=20 μm). A, Lewy body–like inclusion (large arrow) in the substantia nigra; note the nucleus devoid of the endogenous TDP-43 staining ("cleared nucleus") (small arrow) that is present in the affected neuron, but not in an unaffected neuron (asterisk). The arrowhead denotes neuromelanin granules. B, Fibrillar or skein-like formations in the substantia nigra (large arrow) and short dystrophic neurite (small arrow). C, Cleared neuronal nuclei coupled with cytoplasmic ringform inclusion (large arrow) in sensory cortex; note the unaffected neuron with normal endogenous nuclear staining (small arrow). D, Cleared nuclei coupled with cytoplasmic, granular, or diffuse staining ("pre-inclusions") (large arrow) in Wernicke's area; note unaffected neuron (small arrow). E, Dentate nucleus of the cerebellum showing a Lewy body–like inclusion, coupled with a cleared nucleus (arrow). F, Motor neuron in primary motor cortex with cytoplasmic frayed inclusions (arrow) coupled with a cleared nucleus. G, Striatum showing neuronal intranuclear inclusion in a familial (superoxide dismutase-1–negative) case. H, White matter of cingulate gyrus showing 2 oligodendrocytes with cytoplasmic inclusions and cleared nuclei (arrows). I, Temporal cortex showing dystrophic neurites (long arrow) and neuronal cytoplasmic inclusions (small arrow).

that showed neuronal intranuclear inclusions. Control participants were virtually devoid of pathological TDP-43.

COMMENT

Until recently, ALS has been commonly regarded as a neurodegenerative disorder primarily involving the pyramidal motor system, but there is growing evidence that degenerative changes can occur elsewhere in the CNS of ALS patients (eg, hippocampus and nonmotor neocortical areas).[6-9] Further, degeneration in additional brain areas such as the substantia nigra and basal ganglia that are sometimes coupled with clinical evidence of dysfunction in other systems, such as somatomotor, visceromotor, autonomic, limbic, sensory, and additional cortical systems, have been described in case reports and small patient cohorts.[8,10-17] Recently, immunohistochemical studies have shown TDP-43 aggregates in upper and lower motor neurons in familial ALS cases (owing to genetic abnormalities other than those caused by superoxide dismutase-1 mutations) and in the lower motor neurons in more than 100 sporadic ALS cases.[1,3,6] Pathological TDP-43 has also been detected in the dentate gyrus of the hippocampus and the neocortex in both familial and sporadic ALS,[1,3,6] and some subcortical lesion sites have also been reported.[3,18] The full extent of TDP-43 pathology throughout the CNS was unknown in ALS, but assumed to be present mainly in upper and lower motor neurons, in keeping with the widely held concept that the pyramidal motor system is selectively involved in ALS. Moreover, clinical manifestations aside from those indicative of pyramidal motor system involvement exclude the diagnosis of classic ALS, and indicate an ALS-Plus syndrome, according to the El Escorial criteria.[4] Thus,

©2008 American Medical Association. All rights reserved.
Downloaded From: https://jamanetwork.com/ on 02/24/2022

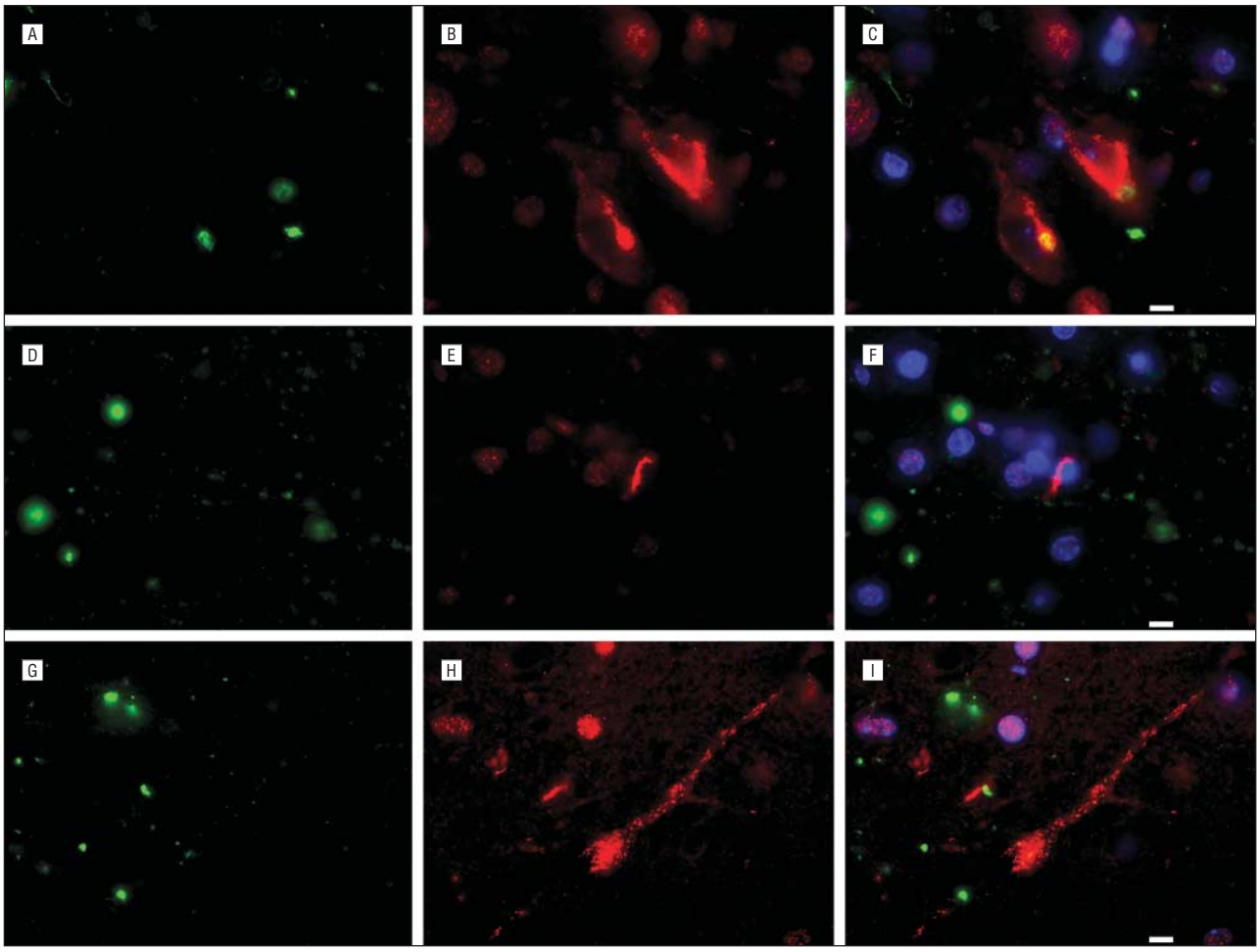

Figure 3. Weak or absent colocalization of 43-kDa transactivating responsive sequence DNA-binding protein (TDP-43) with ubiquitin immunoreactivity detected by anti–TDP-43 and anti-ubiquitin 1510 double-label immunofluorescence histochemistry in sporadic amyotrophic lateral sclerosis with dementia (bar=10μm). A-C, Transentorhinal cortex: A, 1510; B, TDP-43; and C, merged. Note ringform cytoplasmic TDP-43 immunoreactivity with focal cytoplasmic ubiquitin staining. D-F, Entorhinal white matter: D, 1510; E, TDP-43; and F, merged. Note glial inclusion stains for TDP-43, but not for ubiquitin. G-I, Entorhinal cortex: G, 1510; H, TDP-43; and I, merged. Note granular or punctate TDP-43 reactivity in neuronal cytoplasm and neurite, detected only by anti–TDP-43 antibodies.

the presence of widespread TDP-43 pathology throughout many CNS areas in a large series of 31 ALS cases suggests that TDP-43 pathology is far more extensive in this disease than previously reported. Indeed, all cases here showed gray and/or white matter TDP-43 pathology in multiple brain areas outside the pyramidal motor system. This widespread distribution indicates that both phylogenetically young and old brain areas beyond the upper and lower motor neuron system undergo TPD-43-linked neurodegeneration (Figure 1). Our finding of widespread involvement of areas outside the pyramidal motor system is substantiated by several neuroimaging studies and the growing evidence of cognitive or behavioral impairments in ALS.[19,20]

Since the acceptance of this paper, two papers[21,22] have reported genetic evidence of mutations in the TDP-43 gene (TARDBP) that are pathogenic for familial ALS in rare kindred as well as in rare cases of sporadic ALS, thereby supporting our view that ALS neurodegeneration is mechanistically linked to TDP-43 pathology.

In summary, the finding of widespread CNS deposition of pathological TDP-43 in the CNS of ALS patients implies that ALS is a multiple-system TDP-43 proteinopathy involving neurons, oligodendroglia, and astrocytes. Finally, ALS may be situated at 1 end of a broad clinicopathological spectrum of multisystem degenerations, including FTLD with ubiquitin-positive inclusions, with or without motor neuron disease, that may share similar disease mechanisms linked to pathological TDP-43.[1,23,24] Efforts to block or reverse TDP-43 pathology in ALS may lead to disease-modifying therapies for this spectrum of disorder.

Accepted for Publication: November 15, 2007.
Correspondence: John Q. Trojanowski, MD, PhD, Department of Pathology and Laboratory Medicine, University of Pennsylvania School of Medicine, Hospital of the University of Pennsylvania, 3600 Spruce St, Maloney Bldg, 3rd Flr, Philadelphia, PA 19104-4283 (trojanow@mail.med.upenn.edu).
Author Contributions: Dr Trojanowski had full access to all of the data in the study and takes responsibility for the integrity of the data and the accuracy of the data analysis. *Study concept and design:* Geser, Brandmeir, Kwong, Lee, and Trojanowski. *Acquisition of data:* Geser, Brandmeir, Martinez-Lage, Elman, McCluskey, and Trojanowski. *Analy-*

©2008 American Medical Association. All rights reserved.
Downloaded From: https://jamanetwork.com/ on 02/24/2022

sis and interpretation of data: Geser, Brandmeir, McCluskey, Xie, Lee, and Trojanowski. *Drafting of the manuscript:* Geser, Brandmeir, and Trojanowski. *Critical revision of the manuscript for important intellectual content:* Geser, Brandmeir, Kwong, Martinez-Lage, Elman, McCluskey, Xie, Lee, and Trojanowski. *Statistical analysis:* Geser, Brandmeir, and Xie. *Obtained funding:* Lee and Trojanowski. *Administrative, technical, and material support:* Brandmeir, Martinez-Lage, Elman, McCluskey, Lee, and Trojanowski. *Study supervision:* Lee and Trojanowski.

Financial Disclosure: None reported.

Funding/Support: This work was funded by grants AG10124 and AG17586 from the National Institutes of Health.

Additional Contributions: Theresa Schuck, BA, Monica Getahun, BS, Natascha Gownaris, and John Robinson, BS, provided expert technical assistance, and Manuela Neumann, MD, provided critical comments on the manuscript. Furthermore, we thank our patients and families who made this research possible.

REFERENCES

1. Neumann M, Sampathu DM, Kwong LK, et al. Ubiquitinated TDP-43 in frontotemporal lobar degeneration and amyotrophic lateral sclerosis. *Science*. 2006; 314(5796):130-133.
2. Dickson DW, Josephs KA, Amador-Ortiz C. TDP-43 in differential diagnosis of motor neuron disorders. *Acta Neuropathol*. 2007;114(1):71-79.
3. Tan CF, Eguchi H, Tagawa A, et al. TDP-43 immunoreactivity in neuronal inclusions in familial amyotrophic lateral sclerosis with or without SOD1 gene mutation. *Acta Neuropathol*. 2007;113(5):535-542.
4. El Escorial Revisited: Revised Criteria for the Diagnosis of Amyotrophic Lateral Sclerosis. World Federation of Neurology Amyotrophic Lateral Sclerosis Web site. http://www.wfnals.org/. Accessed September 4, 2007.
5. Brooks BR, Miller RG, Swash M, Munsat TL; World Federation of Neurology Research Group on Motor Neuron Diseases. El Escorial revisited: revised criteria for the diagnosis of amyotrophic lateral sclerosis. *Amyotroph Lateral Scler Other Motor Neuron Disord*. 2000;1(5):293-299.
6. Mackenzie IR, Bigio EH, Ince PG, et al. Pathological TDP-43 distinguishes sporadic amyotrophic lateral sclerosis from amyotrophic lateral sclerosis with SOD1 mutations. *Ann Neurol*. 2007;61(5):427-434.
7. Toyoshima Y, Piao YS, Tan CF, et al. Pathological involvement of the motor neuron system and hippocampal formation in motor neuron disease-inclusion dementia. *Acta Neuropathol*. 2003;106(1):50-56.
8. Ota S, Tsuchiya K, Akiyama H. "Forme fruste" of amyotrophic lateral sclerosis with dementia: a report of five autopsy cases without dementia and with ubiquitinated intraneuronal inclusions. *Neuropathology*. 2005;25(4):326-335.
9. Horoupian DS, Thal L, Katzman R, et al. Dementia and motor neuron disease: morphometric, biochemical, and Golgi studies. *Ann Neurol*. 1984;16(3):305-313.
10. Sudo S, Fukutani Y, Matsubara R, et al. Motor neuron disease with dementia combined with degeneration of striatonigral and pallidoluysian systems. *Acta Neuropathol*. 2002;103(5):521-525.
11. Seilhean D, Takahashi J, El Hachimi KH, et al. Amyotrophic lateral sclerosis with neuronal intranuclear protein inclusions. *Acta Neuropathol*. 2004;108(1):81-87.
12. Al-Sarraj S, Maekawa S, Kibble M, et al. Ubiquitin-only intraneuronal inclusion in the substantia nigra is a characteristic feature of motor neurone disease with dementia. *Neuropathol Appl Neurobiol*. 2002;28(2):120-128.
13. Mackenzie IR, Feldman H. Extrapyramidal features in patients with motor neuron disease and dementia: a clinicopathological correlative study. *Acta Neuropathol*. 2004;107(4):336-340.
14. Lawyer T Jr, Netsky MG. Amyotrophic lateral sclerosis. *AMA Arch Neurol Psychiatry*. 1953;69(2):171-192.
15. Yokota O, Tsuchiya K, Oda T, et al. Amyotrophic lateral sclerosis with dementia: an autopsy case showing many Bunina bodies, tau-positive neuronal and astrocytic plaque-like pathologies, and pallido-nigral degeneration. *Acta Neuropathol*. 2006;112(5):633-645.
16. Wilson CM, Grace GM, Munoz DG, He BP, Strong MJ. Cognitive impairment in sporadic ALS: a pathologic continuum underlying a multisystem disorder. *Neurology*. 2001;57(4):651-657.
17. Ince PG, Lowe J, Shaw PJ. Amyotrophic lateral sclerosis: current issues in classification, pathogenesis and molecular pathology. *Neuropathol Appl Neurobiol*. 1998;24(2):104-117.
18. Zhang H, Tan CF, Mori F, et al. TDP-43-immunoreactive neuronal and glial inclusions in the neostriatum in amyotrophic lateral sclerosis with and without dementia [published online ahead of print September 5, 2007]. *Acta Neuropathol*. 2008;115(1):115-122. doi:10.1007/s00401-007-0285-7.
19. Kalra S, Arnold D. Neuroimaging in amyotrophic lateral sclerosis. *Amyotroph Lateral Scler Other Motor Neuron Disord*. 2003;4(4):243-248.
20. Irwin D, Lippa CF, Swearer JM. Cognition and amyotrophic lateral sclerosis (ALS). *Am J Alzheimers Dis Other Demen*. 2007;22(4):300-312.
21. Gitcho MA, Baloh RH, Chakraverty S, et al. TDP-43 A315T mutation in familial motor neuron disease [published online ahead of print February 20, 2008]. *Ann Neurol*. doi:10.1002/ana.21344.
22. Sreedharan J, Blair IP, Tripathi VB, et al. TDP-43 mutations in familial and sporadic amphytropic lateral sclerosis [published online ahead of print February 28, 2008]. *Science*. doi:10.1126/science.1154584.
23. Mackenzie IR, Feldman HH. Ubiquitin immunohistochemistry suggests classic motor neuron disease, motor neuron disease with dementia, and frontotemporal dementia of the motor neuron disease type represent a clinicopathologic spectrum. *J Neuropathol Exp Neurol*. 2005;64(8):730-739.
24. Brownell B, Oppenheimer DR, Hughes JT. The central nervous system in motor neurone disease. *J Neurol Neurosurg Psychiatry*. 1970;33(3):338-357.

Announcement

Visit www.archneurol.com. You can send an e-mail to a friend that includes a link to an article and a note if you wish. Links will go to short versions of articles whenever possible.

©2008 American Medical Association. All rights reserved.

Downloaded From: https://jamanetwork.com/ on 02/24/2022