

## Brief Report

# Acute Panretinal Structural and Functional Abnormalities After Intravitreal Ocriplasmin Injection

Abigail T. Fahim, MD, PhD; Naheed W. Khan, PhD; Mark W. Johnson, MD

**IMPORTANCE** Ocriplasmin cleaves fibronectin and laminin, components of the vitreous gel, and is used as a pharmacologic treatment for vitreomacular traction. Laminin is also found throughout multiple retinal layers. Ocriplasmin injection may lead to acute panretinal dysfunction in some eyes, but the mechanism of this toxic reaction has not been described.

**OBSERVATIONS** We evaluated a 63-year-old woman demonstrating acute panretinal dysfunction after intravitreal ocriplasmin injection for a small macular hole with vitreomacular adhesion. Findings included visual acuity loss, visual field constriction, pupillary abnormalities, attenuated retinal arteries, loss of outer retinal signals on spectral-domain optical coherence tomography, and severely reduced electroretinography responses. B-waves were reduced more than A-waves were, suggesting postreceptoral dysfunction and decreased photoreceptor activity.

**CONCLUSIONS AND RELEVANCE** Retinal dysfunction associated with intravitreal ocriplasmin injection is not limited to the macular region and seems to involve the entire retina. Enzymatic cleavage of intraretinal laminin is a biologically plausible mechanism for acute ocriplasmin retinal toxic effects.

*JAMA Ophthalmol.* 2014;132(4):484-486. doi:10.1001/jamaophthalmol.2013.8142  
Published online February 27, 2014.

- ← Editorial page 379
- ← Related article page 487
- + Supplemental content at [jamaophthalmology.com](http://jamaophthalmology.com)

**Author Affiliations:** Department of Ophthalmology and Visual Sciences, University of Michigan, Ann Arbor.

**Corresponding Author:** Mark W. Johnson, MD, Department of Ophthalmology and Visual Sciences, University of Michigan, 1000 Wall St, Ann Arbor, MI 48105 ([markwj@med.umich.edu](mailto:markwj@med.umich.edu)).

In October 2012, the US Food and Drug Administration<sup>1</sup> approved ocriplasmin for the treatment of symptomatic vitreomacular adhesion. Ocriplasmin is a recombinant truncated form of plasmin with proteolytic activity against fibronectin and laminin, components of the vitreous gel.<sup>2</sup> The combined results of 2 phase 3 randomized clinical trials demonstrated that a single intravitreal injection of ocriplasmin resulted in resolution of vitreomacular adhesion in 26.5% of patients vs 10.1% of control subjects injected with placebo.<sup>3</sup> Reported adverse events included transient visual disturbances such as floaters, photopsias, and visual impairment. Herein, we report that such visual disturbances may be accompanied by substantial panretinal functional and structural abnormalities and propose a mechanism for this toxic reaction.

## Report of a Case

This retrospective case study was exempt from institutional review board oversight. After written informed consent, a 63-year-old woman received intravitreal ocriplasmin (0.125 mg/0.1 mL) injection in the right eye for a small macular hole with vitreomacular adhesion (Figure 1). Her preinjection visual acuity was 20/40 OD. Several hours later, she experienced brilliant white photopsias that evolved during the evening into multiple white floaters on a black background, with no dis-

cernible vision in the injected eye. The visual function recovered partially during the next 4 days, and she noted nyctalopia and a yellow tint to her vision. She was referred to us 9 days after injection with persistent visual loss in the right eye.

Visual acuity with correction measured 20/125 OD and 20/25 OS. Color vision was normal by Ishihara testing. There was 1 mm of anisocoria with the smaller pupil in the right eye. Fundus biomicroscopy of the right eye (Figure 2) demonstrated a prepapillary vitreous (Weiss) ring, with otherwise clear media. The macula exhibited a full-thickness hole with a cuff of surrounding subretinal fluid. The retinal arterioles were diffusely attenuated. The fundus periphery appeared normal. Examination of the left eye was unremarkable.

Spectral-domain optical coherence tomography of the right eye revealed an enlarged full-thickness macular hole with smooth, scalloped edges, as well as attenuation or loss of the external limiting membrane, photoreceptor ellipsoid layer, and cone outer segment tips line (Figure 2). Goldmann visual field testing revealed constriction of all isopters in the right eye compared with the left eye (eFigure in the Supplement).

Full-field electroretinography (ERG) in the right eye exhibited a severely reduced rod B-wave to less than 10% of normal amplitude and delayed implicit time (Figure 3). The dark-adapted combined rod-cone response in the right eye was reduced to approximately 50% of normal, with the B-wave more severely depressed than the A-wave compared with the

left eye. The photopic ERG and 32-Hz flicker in the right eye revealed cone responses reduced to about 40% to 50% of normal. Oscillatory potential amplitudes were severely reduced in the right eye. In the left eye, all ERG variables were within normal limits, apart from mildly reduced rod responses.

## Discussion

Our patient experienced severe visual symptoms following ocriplasmin injection and had persistent visual acuity loss, visual field constriction, anisocoria, attenuated retinal vessels, disruption or loss of outer retinal signals on spectral-domain optical coherence tomography, and severely reduced ERG responses 9 days later. To our knowledge, this is the first report

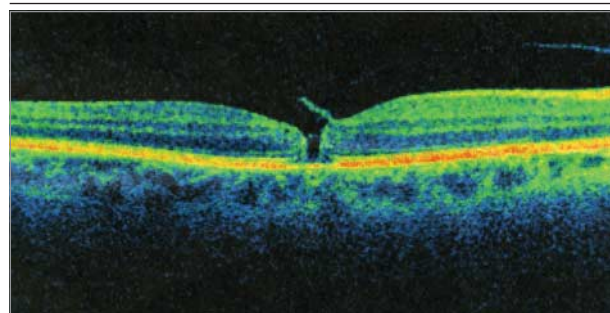
of acute severe panretinal dysfunction after ocriplasmin injection documented and quantified by fundus photography, Goldmann visual field testing, spectral-domain optical coherence tomography, and electrophysiological responses.

Of 976 patients receiving ocriplasmin injection in clinical trials, 9 patients were reported to have experienced an acute decrease in vision within 24 hours of injection.<sup>4</sup> In 8 of 9 patients, the vision returned to baseline, with a median recovery time of 2 weeks, although the range extended to 1 year. Seventeen patients were reported to have dyschromatopsia with a yellow tint. Of 141 patients with ERG data, 11 patients had decreased A-wave and B-wave amplitudes within 1 month of ocriplasmin injection. The severity of reduction was not specified. Seven patients showed resolution, while 4 patients demonstrated persistently depressed ERG responses. Freund and coauthors<sup>5</sup> recently described a patient with disruption of the ellipsoid layer after ocriplasmin injection.

Possible mechanisms of retinal injury from ocriplasmin injection include mechanical effects from a transient increase in vitreomacular traction, enzymatic activity of ocriplasmin on the retinal extracellular matrix, and other toxic effects not specific to the proteinase activity of ocriplasmin. We believe the first postulate is unlikely given the global nature of the retinal alterations compared with the focal nature of vitreomacular traction.

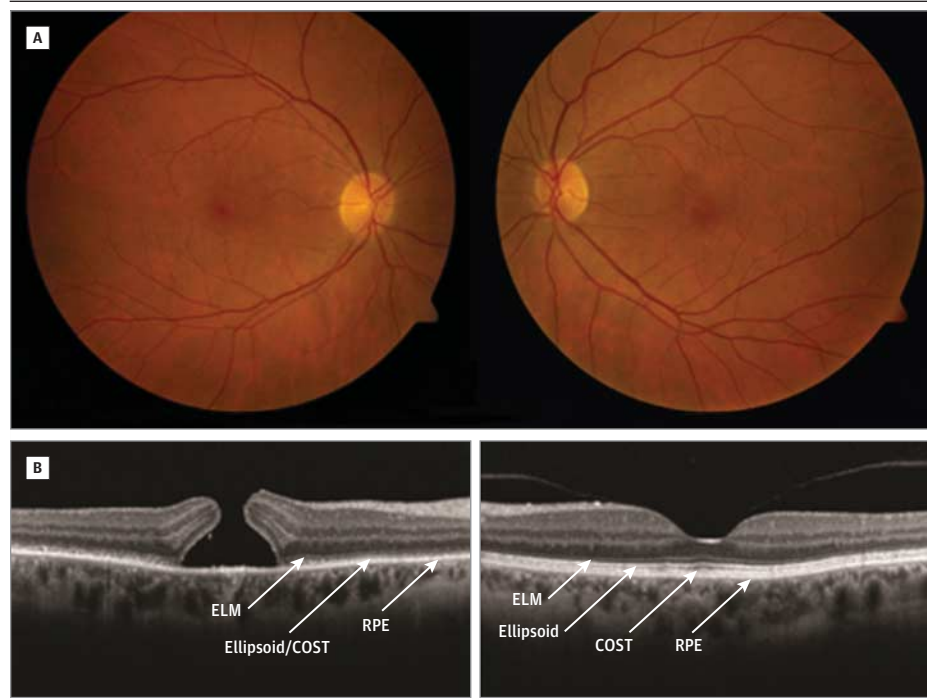
Enzymatic activity of ocriplasmin includes cleavage of fibronectin and laminin, the latter being prominent in Bruch membrane, the interphotoreceptor matrix, the external limiting membrane, the outer plexiform layer, the inner plexiform layer, and the internal limiting membrane.<sup>6</sup> In the outer plexiform layer, laminin localizes to the synaptic ribbon

Figure 1. Spectral-Domain Optical Coherence Tomography of the Right Eye Before Ocriplasmin Injection



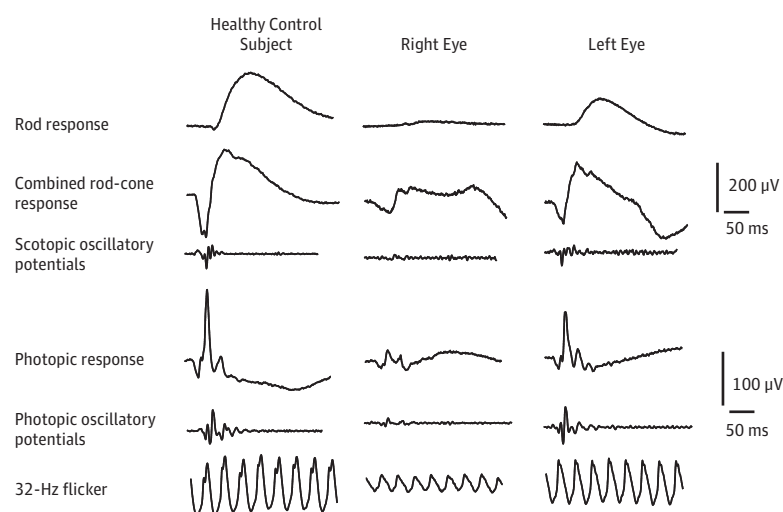
The horizontal image shows a small full-thickness macular hole with vitreous adhesion to the inner layer flap.

Figure 2. Fundus Photographs and Horizontal Spectral-Domain Optical Coherence Tomography 9 Days After Ocriplasmin Injection in the Right Eye



A, The right eye (left) demonstrates a macular hole and attenuation of the retinal vasculature compared with the left eye (right). B, The right eye (left) demonstrates enlargement of the macular hole, with subretinal fluid and a peculiar shape to the hole edges. There is significant attenuation of the external limiting membrane (ELM), ellipsoid layer, and cone outer segment tips (COST) line compared with the healthy left eye (right). The retinal pigment epithelium (RPE) appears normal in each eye.

Figure 3. Electroretinography 9 Days After Ocriplasmin Injection in the Right Eye



The rod electroretinogram is severely reduced to less than 10% of normal in the right eye and is mildly subnormal in the left eye. The combined rod-cone response shows depressed A-waves and B-waves to 50% of normal in the right eye and is normal in the left eye. The photopic bright-flash electroretinogram demonstrates depressed A-waves and B-waves to 40% of normal in the right eye and is normal in the left eye. The 32-Hz flicker electroretinogram is depressed to 50% of normal in the right eye and is normal in the left eye. Oscillatory potential amplitudes are severely reduced in the right eye.

present at synapses between photoreceptors and bipolar cells.<sup>7</sup> In laminin  $\beta 2$  chain-knockout mice, histologic examination demonstrated shortened photoreceptor outer segments and disorganized photoreceptor synapses in the outer plexiform layer.<sup>7</sup> In addition, laminin-deficient mice showed a negative waveform ERG with severely reduced B-waves. After intravitreal ocriplasmin injection in rabbits, both A-waves and B-waves were reduced in a dose-dependent manner, although the retinal histologic findings remained normal.<sup>8</sup>

In our patient, the ERG in the affected eye demonstrated panretinal dysfunction, with significant reduction in every variable. Notably, B-waves were reduced more than A-waves were, which suggests postreceptor (eg, bipolar cell) dysfunction in addition to decreased photoreceptor activity. These results are consistent with the important role of laminin in the photore-

ceptor-bipolar synaptic ribbon. In addition, rod function seemed to be more severely affected than cone function. Furthermore, spectral-domain optical coherence tomography demonstrated disruption of the ellipsoid and cone outer segment tips lines, consistent with the presence of laminin in the interphotoreceptor matrix.

Given the growing number of anecdotal reports of visual disturbances after ocriplasmin injection and the multiple lines of evidence showing retinal toxic effects in the patient described herein, physicians should exercise caution when considering ocriplasmin injection for vitreomacular adhesion. Long-term follow-up observation of this patient and similar individuals will be necessary to determine the reversibility of the anatomical and functional abnormalities that may occur acutely after injection.

#### ARTICLE INFORMATION

**Submitted for Publication:** September 13, 2013; final revision received December 18, 2013; accepted December 20, 2013.

**Published Online:** February 27, 2014.  
doi:10.1001/jamaophthalmol.2013.8142.

**Author Contributions:** Dr Johnson had full access to all the data in the study and takes responsibility for the integrity of the data and the accuracy of the data analysis.

**Study concept and design:** Johnson.

**Acquisition of data:** Khan, Johnson.

**Analysis and interpretation of data:** All authors.

**Drafting of the manuscript:** All authors.

**Critical revision of the manuscript for important intellectual content:** Fahim, Johnson.

**Study supervision:** Johnson.

**Conflict of Interest Disclosures:** None reported.

#### REFERENCES

1. US Food and Drug Administration. FDA approves Jetrea for symptomatic vitreomacular adhesion in

the eyes [press release]. Updated October 18, 2012. <http://www.fda.gov/NewsEvents/Newsroom/PressAnnouncements/ucm324369.htm>. Accessed August 3, 2013.

2. Hermel M, Dailey W, Hartzler MK. Efficacy of plasmin, microplasmin, and streptokinase-plasmin complex for the in vitro degradation of fibronectin and laminin. *Curr Eye Res*. 2010;35(5):419-424.

3. Stalmans P, Benz MS, Gandorfer A, et al; MIVI-TRUST Study Group. Enzymatic vitreolysis with ocriplasmin for vitreomacular traction and macular holes. *N Engl J Med*. 2012;367(7):606-615.

4. Dermatologic and Ophthalmic Drugs Advisory Committee. Ocriplasmin (Jetrea) briefing document. July 26, 2012. <http://www.fda.gov/downloads/advisorycommittees/committeesmeetingmaterials/drugs/dermatologicandophthalmicdrugs/advisorycommittee/ucm313091.pdf>. Accessed August 3, 2013.

5. Freund KB, Shah SA, Shah VP. Correlation of transient vision loss with outer retinal disruption following intravitreal ocriplasmin. *Eye (Lond)*. 2013;27(6):773-774.

6. Libby RT, Champlaud MF, Claudepierre T, et al. Laminin expression in adult and developing retinae. *J Neurosci*. 2000;20(17):6517-6528.

7. Libby RT, Lavalley CR, Balkema GW, Brunken WJ, Hunter DD. Disruption of laminin  $\beta 2$  chain production causes alterations in morphology and function in the CNS. *J Neurosci*. 1999;19(21):9399-9411.

8. Sakuma T, Tanaka M, Mizota A, Inoue J, Pakola S. Safety of in vivo pharmacologic vitreolysis with recombinant microplasmin in rabbit eyes. *Invest Ophthalmol Vis Sci*. 2005;46(9):3295-3299.