

Optic Perineuritis

Clinical and Radiographic Features

Valerie Purvin, MD; Aki Kawasaki, MD; Daniel M. Jacobson, MD

Background: Optic perineuritis is an uncommon variety of orbital inflammatory disease that is distinct from demyelinating optic neuritis.

Objective: To describe the clinical and radiographic features of idiopathic optic perineuritis, with particular emphasis on those features that help to distinguish this condition from optic neuritis.

Methods: We reviewed the medical records of 14 patients with optic perineuritis who were seen in 2 neuro-ophthalmology clinics.

Results: Patients ranged in age from 24 to 60 years; 5 were older than 50 years. All patients had visual loss, eye pain, or both. The visual acuity was 20/20 or better in 8 of the 15 eyes. The results of visual field testing were nor-

mal in 2 eyes, and a paracentral scotoma or an arcuate defect was seen in 7. Magnetic resonance imaging scans demonstrated circumferential enhancement around the optic nerve, sometimes with intraorbital extension. Response to corticosteroids was dramatic; however, 4 patients had a relapse with lowering of the dose.

Conclusions: In contrast to those with optic neuritis, patients with optic perineuritis are often older at onset and are more likely to show sparing of central vision. Magnetic resonance imaging scans demonstrate enhancement around, rather than within, the optic nerve. Response to corticosteroids is more dramatic than in patients with optic neuritis, and patients are more likely to experience recurrence after stopping treatment.

Arch Ophthalmol. 2001;119:1299-1306

OPTIC perineuritis (OPN), also termed periopic neuritis, is an uncommon inflammatory disorder involving the optic nerve sheath. Historically, the term has been used to describe several different clinical entities.¹ In recent years, OPN has generally been understood to represent a form of idiopathic orbital inflammatory disease, in which the specific target tissue is the optic nerve sheath.² While most cases are isolated and idiopathic, OPN occasionally occurs as a manifestation of a specific infectious or inflammatory disorder, such as Wegener granulomatosis or giant cell arteritis.³

Radiographically, OPN may simulate optic nerve sheath meningioma,⁴ but clinically it is more likely to be mistaken for acute demyelinating optic neuritis (ON). In both OPN and ON, patients typically experience acute monocular visual loss, pain with eye movement, and either a normal or a swollen optic disc. The natural history of and response to treatment for these 2 conditions, however, may differ.

It is, therefore, important to identify any clinical and radiographic features that might help in distinguishing the 2 expediently. To better characterize the clinical features of OPN, we reviewed the medical records and radiographic studies of 14 affected patients. We paid particular attention to features that might be helpful in distinguishing OPN from ON.

RESULTS

The 14 patients included 10 women and 4 men, ranging in age from 24 to 60 years (mean, 41 years; median, 39½ years) (**Table 1**). Five patients were older than 50 years at onset. Ocular involvement was monocular when first seen in 13 patients and binocular in 1 (patient 12). Thus, data for 15 eyes were analyzed.

All patients had symptoms of visual loss, eye pain, or both. Eight patients had visual loss and eye pain that was commonly exacerbated by eye movement. Pain was absent in 1 patient (patient 2) at onset but developed 3 months later. Pain was not associated with subjective visual loss

From the Midwest Eye Institute and the Departments of Neurology and Ophthalmology, Indiana University Medical Center, Indianapolis (Drs Purvin and Kawasaki); and the Marshfield Clinic, Marshfield, Wis (Dr Jacobson).

PATIENTS AND METHODS

The diagnosis of OPN was made in patients who had an acute optic neuropathy and/or disc edema plus either radiographic demonstration of enhancement of the optic nerve sheath or histopathologic evidence of perineural inflammation. We excluded patients with clinical or radiographic evidence of a more widespread orbital process (eg, significant exophthalmos or prominent enlargement or enhancement of extraocular muscles). The presence of subtle orbital abnormalities was not considered an exclusionary factor. Patients were also excluded if they had an established systemic disorder associated with orbital inflammation or if their or a subsequent clinical course evaluation revealed a specific systemic illness as the cause of their optic nerve sheath inflammation. Patients were followed up for a long enough period to ensure that an infectious or neoplastic leptomeningeal process was not present.

We analyzed symptoms, optic nerve function (visual acuity, color vision, and visual field), optic disc appearance, and radiographic findings. Response to treatment and long-term course were also studied.

All patients underwent laboratory testing to exclude specific systemic inflammatory diseases. In all patients, the complete blood cell count, the erythrocyte sedimentation rate, and the levels of antinuclear antibodies and angiotensin-converting enzyme were determined; a syphilis serologic test was performed; and a chest x-ray film was obtained. All patients underwent magnetic resonance imaging (MRI) of the head and orbits with fat suppression and contrast infusion. In addition, 7 patients underwent testing for antineutrophil cytoplasmic antibodies (including all patients with intracranial extension), 3 were tested for Lyme disease, and 3 underwent a lumbar puncture. A biopsy of the optic nerve lesion was performed in 2 patients.

in 5 eyes (patients 1, 4, 9, 12, and 13). Visual loss was variably described as blurring, dimming, splotches, or a "spot" in vision.

Pertinent findings are summarized in Table 1. The visual acuity when first seen was 20/20 or better in 8 (53%) of the 15 eyes. The results of the visual field examination were normal in 2 (13%) of the 15 eyes. Three eyes demonstrated an arcuate defect, and 4 had a paracentral scotoma. A central scotoma or central depression was found in 3 eyes, and only a remaining peripheral island was seen in 2. Disc edema was observed in 10 eyes. Mild motility disturbance was found in 4 eyes (patients 5, 7, 9, and 14). Mild ptosis was seen in 2 patients (patients 6 and 9), and developed later in the course of 2 additional eyes (patients 2 and 14).

Magnetic resonance imaging scans demonstrated enhancement around the intraorbital optic nerve in 13 patients. In 1 patient (patient 14), enhancement appeared to involve the full thickness of the optic nerve, and in this patient the diagnosis was based on pathologic examination results. In another patient (patient 8), the MRI scan showed sheath and optic nerve enhancement. There

was intracranial extension in 3 patients (patients 2, 8, and 14). None of the scans revealed white matter lesions.

All patients had normal laboratory test results, except 1 (patient 7) in whom the fluorescent treponemal antibody absorption test result was weakly positive. In this patient, the results of confirmatory serologic tests (the VDRL test and microhemagglutination-treponemal pallidum) and the cerebrospinal fluid fluorescent treponemal antibody absorption test were negative. A biopsy specimen of the optic nerve lesion in 2 patients (patients 2 and 14) showed acute and chronic inflammatory changes without granulomas or vasculitis (**Figure 1**). All 3 patients with intracranial extension underwent an expanded evaluation for granulomatous disease, including testing for antineutrophil cytoplasmic antibodies (perinuclear-antineutrophil cytoplasmic antibody and cytoplasmic-antineutrophil cytoplasmic antibody) and chest radiography. The results of these studies were normal.

Twelve patients were treated initially with prednisone, typically 60 or 80 mg/d, and 2 were treated initially with indomethacin. All experienced dramatic relief of eye pain, usually within 24 hours of starting treatment, and prompt improvement of vision (within days of initiating corticosteroid therapy). Four patients had a relapse when the corticosteroid dose was reduced, necessitating the use of additional treatment modalities, including intravenous methylprednisolone (2 patients), peribulbar corticosteroids (1 patient), azathioprine (2 patients), and radiation therapy (2 patients). The final visual acuity was 20/25 or better in 12 (80%) of the 15 eyes. Two patients (patients 2 and 14) experienced a poor visual outcome, in each instance associated with a delay in initiating corticosteroid treatment (**Table 2**).

Follow-up intervals ranged from 1 month to 6 years (mean, 12½ months; median, 9½ months) (Table 2).

PATIENT 1

A 26-year-old woman developed right retro-orbital pain exacerbated by eye movement and mild photophobia 2 weeks following an upper respiratory tract infection. The results of an ophthalmologic examination 2 weeks after onset revealed right optic disc edema and subjective color desaturation; otherwise, the test results of optic nerve function were normal. An MRI scan showed enhancement around the right optic nerve (**Figure 2**). Two weeks later, she began treatment with prednisone, 40 mg/d, which was tapered over 12 days. This brought prompt relief of pain, but the visual acuity declined from 20/20 to 20/40 OD. Eight weeks after the onset of symptoms, she was seen in neuro-ophthalmologic consultation. Her visual acuity was 20/80 OD and 20/20 OS. Goldmann perimetry in the right eye showed an absolute inferior arcuate scotoma plus a smaller superior scotoma (**Figure 3**). The visual field in the left eye was normal. There was a +2 right relative afferent pupillary defect. The results of external biomicroscopy and ocular motility examinations were normal. The results of a fundus examination revealed moderate hyperemic right optic disc edema and a normal left optic disc (**Figure 4**).

Additional laboratory testing included the determination of the complete blood cell count, the erythrocyte

Table 1. Clinical Features When Initially Seen*

Patient No./ Sex/Age, y	Symptoms	Medical History	VA in the Involved Eye	VF Findings	Optic Disc Findings	Other Examination Findings	MRI Findings
1/F/26	Pain with EM	Preceding URTI	20/20	Inferior arcuate defect	Edema	...	ONS enhancement and within-orbital fat
2/M/37	Foggy vision and pain 3 mo later	None	20/60	Inferior paracentral scotoma	Normal	Mild ptosis and decreased up- gaze later	ONS enhancement at the apex with an intracranial extension
3/M/53	Pain with EM and "splotches" with exercise	Remote CRVO	20/20	Superior arcuate defect	Normal	...	Thickened ONS with enhancement
4/F/32	Pain on EM	Asthma	20/20	Superior paracentral scotoma	Normal	...	ONS enhancement
5/F/31	Pain with EM, blurring, and diplopia	None	20/20	Normal	Edema	Small left hypertropia	ONS enhancement
6/F/32	Pain on EM and film over vision	None	20/25	Inferior paracentral scotoma	Normal	Slight ptosis	Subtle ONS enhancement
7/F/55	Pain, diplopia, and a "spot" in vision	Postoperative DVT	20/300	Central scotoma	Normal	Mild abduction deficit and right HT	ONS enhancement at the apex
8/F/60	Decreased vision and pain on EM	HT and osteoarthritis	20/40	Small central scotoma	Moderate edema	1-mm ptosis	Enhancement of the optic nerve and orbital fat
9/F/57	Pain with EM, slight ptosis, and conjunctival injection	Meniere disease and a preceding febrile illness	20/30	Enlarged blind spot	Mild edema	Slight abduction deficit, slight ptosis, and mild injection over MR	ONS and ON enhancement with an intracranial extension
10/M/33	Pain with EM and cloudy vision	None, but a preceding URT	20/20	Inferior arcuate defect	Moderate disc edema	Mild injection over LR and 0.5-mm exophthalmos	ONS enhancement and fat
11/F/51	Cloudy vision and eye pain	None	LP	Temporal island	Mild to moderate edema	...	ONS enhancement
12/M/42	Eye ache in both eyes and mild dimming in the right eye	None	20/20 OD and 20/15 OS	Paracentral depression in the right eye and normal in the left eye	Mild edema in both eyes	...	ONS enhancement and fat
13/F/24	Eye pain	Asthma	20/15	Mild central depression	Mild edema	...	ONS enhancement and fat
14/F/42	Eye pain for 6 mo and decreased vision in the left eye (left ptosis 3 mo after onset)	None	CF	Temporal island	Edema and pallor	Ptosis, eyelid edema, ophthalmoparesis, and 2-mm exophthalmos	Thickening and enhancement of the optic nerve with intracranial involvement

*VA indicates visual acuity; VF, visual field; MRI, magnetic resonance imaging; EM, eye movement; URTI, upper respiratory tract infection; ONS, optic nerve sheath; CRVO, central retinal vein occlusion; DVT, deep vein thrombosis; HT, hypertension; MR, medial rectus; ON, optic nerve; LR, lateral rectus; LP, light perception; CF, counting fingers; and ellipses, data not applicable.

sedimentation rate, and the levels of antinuclear antibodies and angiotensin-converting enzyme and the performance of a syphilis serologic test and chest radiography; the results of all tests were normal or negative. Corticosteroid treatment was reinstituted, starting this time at 80 mg/d and decreasing by 20 mg/wk. The results of reexamination 4 weeks later showed improvement of the visual acuity to 20/20 OD. The visual field was also much improved, showing only mild central depression. Right optic disc edema had resolved, and the disc was mildly pale.

PATIENT 2

A 37-year-old previously healthy man experienced "foggy" vision in his left eye accompanied by a few sparkles of light. He had a sensation of heaviness of the involved eye but no actual eye pain and no discomfort with eye move-

ment. The results of an eye examination 2 weeks after onset showed a visual acuity of 20/60 OS, with a 0.9-log unit relative afferent pupil defect and normal optic discs. Goldmann perimetry in the left eye revealed mild central depression and a small scotoma inferior to fixation.

Laboratory test results were all normal or negative, and an MRI scan of the head and orbits was interpreted as normal. Reexamination 5 weeks later showed no change in visual acuity, but visual field testing revealed mild additional central depression in the left eye. He received a course of prednisone, 80 mg/d, which was tapered over 4 weeks. Optic nerve function improved; however, 2 months later he experienced abrupt onset of severe left retro-orbital pain with worsening of vision. He did not seek medical attention until 1 month later, at which time an MRI scan demonstrated enhancement around the apical portion of the left optic nerve with extension intracranially (**Figure 5**).

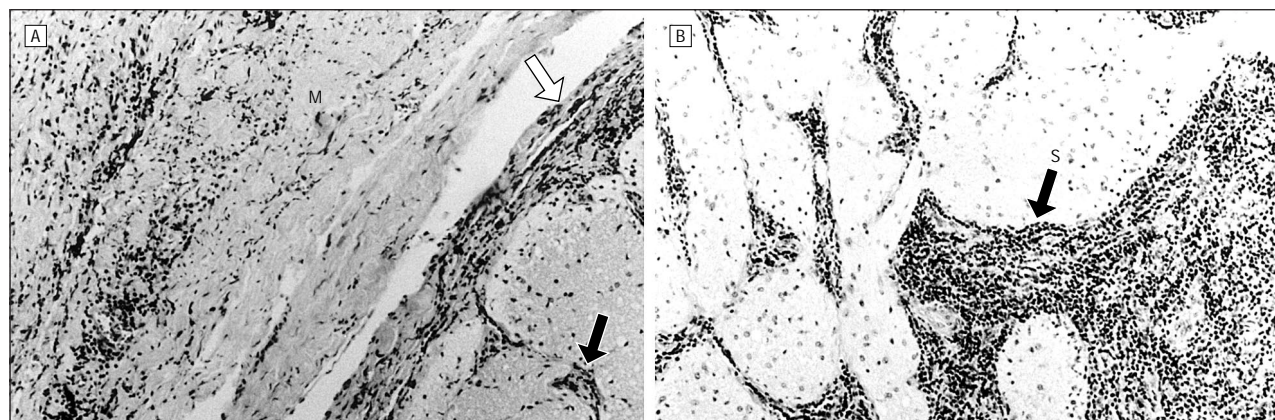


Figure 1. Patient 14. An excisional biopsy specimen of the left optic nerve of a 42-year-old otherwise healthy woman who experienced progressive painful visual loss in the affected eye over 6 months, unresponsive to corticosteroids. A malignant optic nerve glioma was suspected. A, A low-magnification axial photomicrograph of the optic nerve and sheath complex showing marked thickening of the perioptic meninges (M) and, to a less dramatic extent, the pia mater (white arrow) due to fibrosis and inflammatory infiltration. The infiltrate also extends into the pial septa (black arrow) (hematoxylin-eosin, original magnification $\times 10$). B, There is marked expansion of the pial septa (S) by the chronic inflammatory cell infiltrate. The parenchyma of the adjacent optic nerve is slightly infiltrated by lymphocytes (hematoxylin-eosin, original magnification $\times 10$).

Table 2. Clinical Course*

Patient No.	Treatment	Course	Final Visual Acuity	Follow-up Interval
1	Prednisone	Low-dose prednisone for 12 d: decreased pain but persistent edema and worse vision; then high-dose prednisone for 4 wk: resolution of disc edema and improved vision; 2 more recurrences again responded to prednisone	20/20	1½ y
2	Prednisone, IV methylprednisolone, RT, and azathioprine	Initial good response to prednisone; mild ptosis and motility disturbance 3 mo after onset; lost to follow-up for 1 mo; worse vision responded only modestly to IV corticosteroids; biopsy specimen showed inflammatory cells; stable following RT, taking prednisone and azathioprine	CF	2 y
3	Prednisone, IV methylprednisolone, peribulbar corticosteroids, azathioprine, and RT	Multiple recurrences with good response to corticosteroids each time; following RT for corticosteroid dependency, stable for 2 y while taking prednisone and azathioprine	20/25	5 y
4	Prednisone	Pain gone in 2 d, and dose tapered over 3 mo	20/20	7 mo
5	Indomethacin	Resolved and stable following treatment	20/20	4 mo
6	Indomethacin	Improved over 4 wk and no recurrence since	20/20	3 y
7	Prednisone	Favorable response to prednisone and stable since	20/25	2 y
8	IV methylprednisolone and prednisone	Initial response to brief oral prednisone therapy, but vision worsened when stopped; repeated treatment with a high dose IV brought prompt pain relief and visual recovery; recovery was maintained over a 2-mo taper and since	20/15	6 mo
9	Prednisone	Pain gone in a few days, optic nerve function normalized, slowly tapered over a few months, and stable since	20/15	4½ mo
10	Prednisone	Pain resolved in 2 h, and vision better in 1 wk; unavailable for further follow-up	20/15	1 mo
11	Prednisone	Pain resolved in 2 d, and vision improved in 3 d; residual decreased visual acuity and inferior arcuate defect	20/50	12 mo
12	Prednisone	Pain resolved in 1 d, and vision improved in 2 d; dose was slowly tapered	20/20 OU	2 mo
13	Prednisone	Improved with corticosteroids, which were slowly tapered	20/15	4 mo
14	Prednisone	6-mo progression before diagnosis, excisional biopsy specimen showed fibrosis and inflammation, and stable since	NLP	6 y

*IV indicates intravenous; RT, radiation therapy; CF, counting fingers; and NLP, no light perception.

In retrospect, enhancement around the apical optic nerve could be identified on his initial scan as well.

His visual acuity had declined to hand motions OS, with a large dense central scotoma. He enjoyed only a modest response to intravenous methylprednisolone followed by oral prednisone. His vision worsened again 2 months later, at which time he received a course of radiation therapy consisting of 2520 rads (25.2 Gy) in 14 fractions. Recurrence of pain 4 months later was treated with low-dose alternate-day prednisone plus azathio-

prine. He has been stable for 18 months, since beginning this regimen.

COMMENT

Optic perineuritis was first described by Edmunds and Lawford² in 1883. These researchers distinguished between 2 forms of the disorder: exudative and purulent. The exudative form consisted of a localized nonsuppurative pachymeningitis.¹ The purulent form was associ-

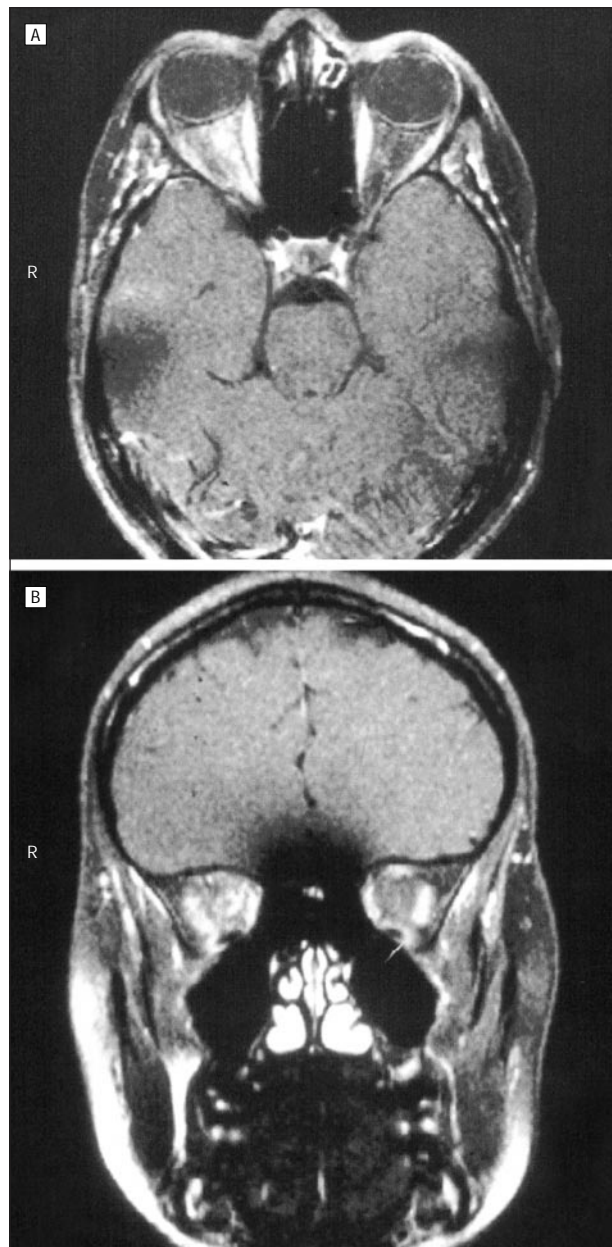


Figure 2. Patient 1. Magnetic resonance imaging scan of the head and orbits, with contrast infusion and fat suppression. A, The axial view shows enhancement around the right intraorbital optic nerve with some “streakiness” of the surrounding orbital fat. R indicates right side. B, The coronal view confirms that the enhancement is around, rather than within, the optic nerve.

ated with leptomeningitis that had extended to involve the subarachnoid space surrounding the optic nerves. In many such cases of OPN, optic nerve function has been said to be normal, an observation consistent with the concept that the inflammatory infiltrate is loosely organized around the optic nerve.

More recently, the term OPN has been used to designate a form of orbital inflammatory disease in which the main focus of the inflammatory response is the optic nerve sheath.⁶ Other focal forms of orbital inflammatory disease include periscleritis, orbital myositis, and dacryoadenitis.⁷ Dutton and Anderson⁴ described the clinical, radiographic, and pathologic features of 4 patients with OPN

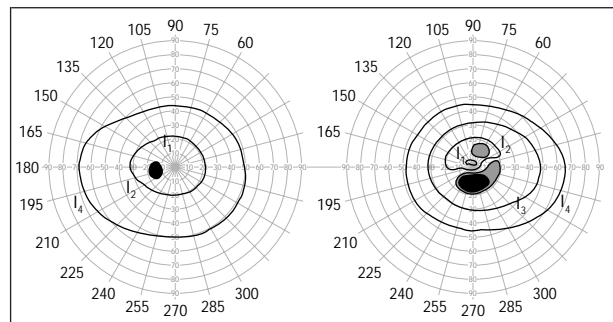


Figure 3. Patient 1. Goldmann perimetry in the right eye shows an absolute inferior arcuate scotoma and a smaller less dense scotoma in the superior Bjerrum area. The field in the left eye is normal.

in whom enlargement of the intraorbital optic nerve was thought to represent an optic nerve sheath meningioma. Biopsy specimens, however, demonstrated inflammatory infiltration of the dural sheath in 2 patients and dense perineural fibrous tissue in the other 2. None were associated with a specific inflammatory disorder. Of the 4 patients, 3 differed clinically from patients with optic nerve sheath meningioma in that head and eye pain was prominent. Only 1 of the 4 patients was treated with corticosteroids, which stabilized vision for 6 months until complications led to their discontinuance. A patient with bilateral idiopathic optic nerve sheath inflammation, described by Margo et al,⁸ did not experience a beneficial response to corticosteroids. A full-thickness biopsy specimen of the more severely involved optic nerve revealed chronic inflammation of the optic nerve sheath with vasculitic changes and necrobiotic granulomas. Visual loss was attributed in large part to secondary ischemic infarction of the optic nerve, presumably due to circumferential compression of the optic nerve periphery by the mass of the thickened optic nerve sheath.⁸ Two similar patients, in whom visual loss was due to vascular occlusion, were described by Winterkorn et al⁹; however, a biopsy was not performed.

The pathologic changes of the optic nerve sheath and the optic nerve that were present in our patients and in those that have been previously described suggest that the clinically defined entity of OPN likely encompasses a spectrum of disorders. Regardless of what unknown process incites the initial inflammatory process in idiopathic cases, the common pathologic reaction consists of marked thickening of the optic nerve sheath due to nonspecific fibrosis.⁴ Various stages of predominantly lymphocytic infiltration are usually present. In the case reported by Margo et al,⁸ foci of degenerating (necrobiotic) collagen were present in the optic nerve sheath. Of the 4 patients described by Dutton and Anderson,⁴ 1 showed granulomatous inflammation in the sheath. Visual loss in those patients in whom a biopsy of the optic nerve was performed or in whom the optic nerve was excised correlated with the presence of either optic nerve demyelination^{7,10} or infarction.⁸ Perivascular lymphocytic infiltration of small optic nerve vessels (vasculitis) has been identified in some patients.^{7,11}

In most cases of suspected OPN, an optic nerve biopsy is not indicated. The diagnosis is typically based on a combination of clinical and radiographic findings. Neuroimaging in patients with OPN typically shows a characteristic pattern of enhancement around the optic nerve

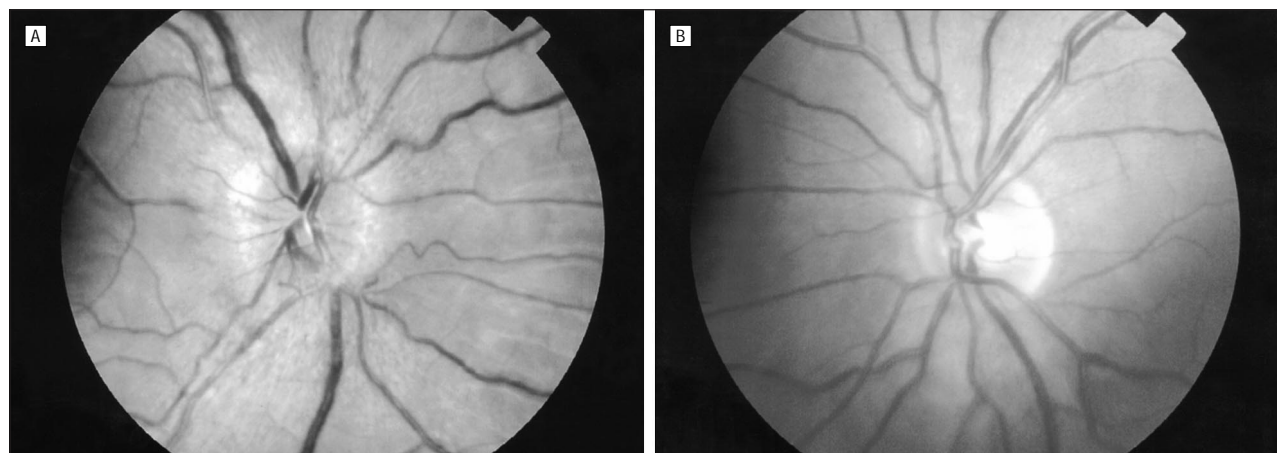


Figure 4. Patient 1. Fundus photographs taken 8 weeks after the onset of symptoms show persistent right optic disc edema (A) and a normal left optic disc (B).

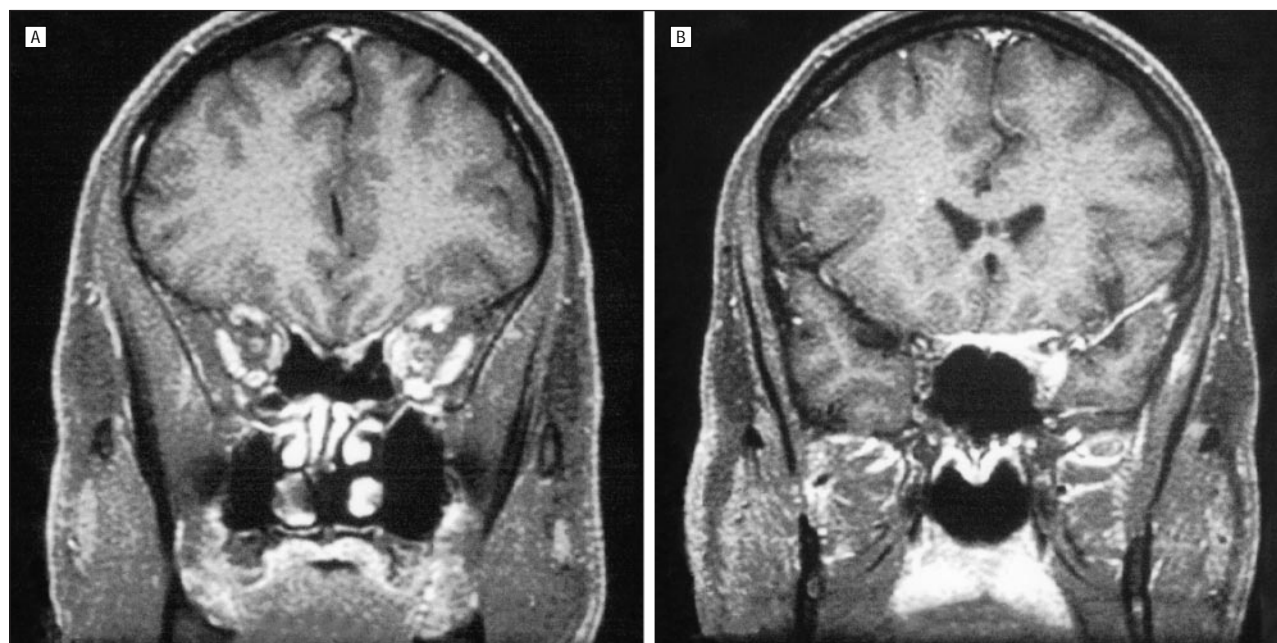


Figure 5. Patient 2. A magnetic resonance imaging scan with contrast infusion obtained 4 months after the onset of visual symptoms. A, The coronal view through the orbital apex shows enhancement around the left optic nerve. There is also mild enlargement and enhancement of extraocular muscles. B, The coronal view more posteriorly demonstrates extension of the inflammatory process intracranially to the anterior cavernous sinus and along the planum sphenoidale.

(“tramtrack” on axial views and “doughnut” on coronal views). In addition, MRI scans in some cases show streaky enhancement of orbital fat (Figure 2). These radiographic changes are not found in patients with typical demyelinating ON. In occasional cases of OPN, the substance of the optic nerve also shows enhancement,¹² presumably due to inflammation of intraneural pial septa as well as the nerve sheath. Two of our patients exhibited this finding, with histopathologic correlation demonstrated in 1. In some patients, close inspection may reveal subtle enhancement of extraocular muscles and/or sclera in addition to the characteristic changes in the optic nerve sheath (Figure 5). A careful inspection for these changes may be particularly helpful in cases in which the perineural findings are subtle or indeterminant and particularly in those scans that demonstrate intraneural enhancement. Computed tomographic scanning does not usually provide sufficient spatial resolution to distin-

guish perineural enhancement from the intraneural enhancement seen in demyelinating ON. Recent advances in MRI, specifically the use of dedicated orbital views with fat suppression and gadolinium, have enabled us to make this distinction. Accordingly, we suspect that the prevalence of this disorder has been underestimated. In the pre-MRI era, some cases of OPN may have been diagnosed as being “atypical corticosteroid-responsive ON.”

Based on shared clinical features, patients with OPN are likely to be misdiagnosed initially as having ON. Similar to those with ON, most patients with OPN are women (71% [10 of 14 patients] in our series) and most experience acute monocular visual loss accompanied by eye pain. In patients with both disorders, eye pain is commonly exacerbated by eye movement. Disc edema is often present in patients with both conditions (found in 10 of the 15 eyes in our series). Treatment considerations and prognosis, however, differ for these 2 disorders, particularly regard-

ing the future development of multiple sclerosis. Based on our data, we found several features to be helpful in distinguishing OPN from ON (**Table 3**).

The age distribution of patients with OPN is broader, and the average age is older than in patients with ON. Our patients' age ranged from 24 to 60 years (mean, 41 years). The average age of patients with ON is 33½ years; only 15% of cases occur in individuals older than 50 years.¹³ In contrast, 5 (36%) of our 14 patients were older than 50 years.

The tempo and pattern of visual loss also differed in our patients compared with those with ON. In contrast to visual loss in patients with ON, which usually occurs over several days, visual loss in many of our patients with OPN progressed for several weeks before they were correctly diagnosed and treatment was initiated. Although occasional patients with ON demonstrate sparing of central vision, we found this to be a common pattern in patients with OPN. The visual acuity was 20/20 in 8 (53%) of the 15 eyes. The results of visual field testing were normal in 3 eyes; a paracentral scotoma was seen in 4, and an arcuate defect was seen in 3. Thus, 10 of the 15 eyes demonstrated sparing of central vision. In contrast, in a study of 103 patients with ON, Perkin and Rose¹³ found only 4.2% to have central sparing. In keeping with their tendency to spare central vision, the degree of dyschromatopsia was less than typically seen in patients with ON.

Mild motility disturbance, due to extraocular muscle inflammation, is occasionally a helpful feature. Four of the 14 patients had abnormal ocular motility, based either on eliciting a history of diplopia or on examination findings. One of these 4 and an additional patient exhibited mild ptosis in the involved eye, and 2 others developed mild ptosis later in their course. These are not typical features of ON (unless there is associated brainstem involvement due to multifocal demyelinating disease), and their presence in a patient suspected of having ON should suggest the alternative diagnosis of OPN.

Finally, the response to treatment may help in differentiating OPN from ON. Of our 14 patients with OPN, 12 were treated with corticosteroids, and all demonstrated dramatic relief of pain on initiating treatment, typically within hours and all within a day. Visual loss also showed prompt recovery. Relapse following discontinuation of treatment, however, was common. These features, particularly the recurrence of pain and/or visual loss on corticosteroid tapering, should suggest a diagnosis of OPN rather than ON. Specific inflammatory and neoplastic entities, such as sarcoidosis, lymphoma, leptomeningeal carcinomatosis, and some fungal infiltrations, may demonstrate a similar response to treatment. These disorders, however, soon declare themselves by demonstrating recurrence and progression with or without continued corticosteroid treatment.

The prognosis for visual outcome in patients with OPN is generally excellent. This is greatly influenced, however, by the interval between the onset of visual loss and the initiation of treatment. In 2 patients with a poor visual outcome, treatment was delayed by a month or more.

Table 3. Features That Distinguish Optic Neuritis From Optic Perineuritis

Feature	Optic Neuritis	Optic Perineuritis
Age at onset	Usually young adults (only 15% are >50 y)	Broader range (36% are >50 y)
Visual loss	Usually central	Often paracentral or arcuate
Time course	Progression over days	Progression over weeks
Natural history	Spontaneous recovery	Progressive visual loss
Response to corticosteroid treatment	Variable; uncommon relapse after stopping	Prompt and dramatic; common relapse after brief treatment
Magnetic resonance imaging scan findings	Optic nerve enhancement with or without white matter lesions	Perineural enhancement and "streaky" fat with or without extraocular muscle enhancement

The other factor that influences prognosis is the frequency of recurrent attacks. Initiating treatment with higher doses of corticosteroids (eg, prednisone, 80 mg/d) and more prolonged treatment at this level appear to lessen the likelihood of recurrent attacks.

The possibility of OPN should be considered in all patients in whom ON is diagnosed. Magnetic resonance imaging is particularly important in patients with clinical findings that are atypical for demyelinating ON. Specifically, these would include age older than 45 years, sparing of central vision, visual loss progressing for longer than 2 weeks, persistence of disc edema, recurrence of pain, and visual loss after discontinuing corticosteroid therapy. Patients in whom pain is particularly severe or is out of proportion to visual loss might also be considered in this category. Careful scrutiny, in terms of history and physical examination, for evidence of orbital involvement (diplopia, subtle ptosis, and chemosis) may also help to identify these patients.

It is important to accurately distinguish between OPN and ON for 2 reasons. First, the prognosis is different in these disorders. Patients with ON are at high risk of developing multiple sclerosis and should be counseled accordingly. Patients with OPN, in contrast, are not at increased risk for demyelinating disease but are likely to experience a recurrence of visual loss in the future. Second, treatment considerations differ for the 2 entities. Corticosteroids have not been shown to influence the visual outcome in patients with ON and, therefore, many patients with ON are managed expectantly (ie, without treatment). Patients with OPN, however, will continue to lose vision, in some cases irreversibly, unless treated with corticosteroids or other anti-inflammatory agents. Furthermore, the dosage and route of administration differ. The recommended regimen for OPN (oral prednisone, 80 mg/d) is contraindicated in patients with ON because of the association of this treatment with recurrences of ON. On the other hand, the rather short (2-week) course of corticosteroid treatment used in patients with ON is not long enough to achieve lasting remission in most patients with OPN.

Accepted for publication February 1, 2001.

Corresponding author and reprints: Valerie A. Purvin, MD, Midwest Eye Institute, 201 Pennsylvania Pkwy, Indianapolis, IN 46280 (e-mail: Vpurvin@iupui.edu).

REFERENCES

1. Miller NR, Newman NJ. *Walsh and Hoyt's Clinical Neuro-ophthalmology*. 5th ed. Baltimore, Md: Williams & Wilkins; 1998.
2. Kennerdell JS, Dresner SC. The nonspecific orbital inflammatory syndromes. *Surv Ophthalmol*. 1984;29:93-103.
3. Nassani S, Cocito L, Arcuri T, Favale E. Orbital pseudotumor as a presenting sign of temporal arteritis. *Clin Exp Rheumatol*. 1995;13:367-369.
4. Dutton JJ, Anderson RL. Idiopathic inflammatory peri optic neuritis simulating optic nerve sheath meningioma. *Am J Ophthalmol*. 1985;100:424-430.
5. Edmunds W, Lawford JB. Examination of optic nerve from cases of amblyopia in diabetes. *Trans Ophthalmol Soc U K*. 1883;3:160-162.
6. Rootman J. *Diseases of the Orbit*. Philadelphia, Pa: JB Lippincott Co; 1988.
7. Rush JA, Kennerdell JS, Donin JF. Acute periscleritis: a variant of idiopathic orbital inflammation. *Orbit*. 1982;4:221-230.
8. Margo CE, Levy MH, Beck RW. Bilateral idiopathic inflammation of the optic nerve sheaths. *Ophthalmology*. 1989;96:200-206.
9. Winterkorn JMS, Odel JG, Behrens MM, Hilal S. Large optic nerve with central retinal artery and vein occlusions from optic neuritis/perineuritis rather than tumor. *J Neuroophthalmol*. 1994;14:157-159.
10. Hykin PG, Spalton DJ. Bilateral perineuritis of the optic nerves. *J Neurol Neurosurg Psychiatry*. 1991;54:375-376.
11. Zhang TL, Shao SF, Zhang T, et al. Idiopathic inflammation of optic nerve simulating optic nerve sheath meningioma: CT demonstration. *J Comput Assist Tomogr*. 1987;11:360-361.
12. Fay AM, Kane SA, Kazim M, et al. Magnetic resonance imaging of optic perineuritis. *J Neuroophthalmol*. 1997;17:247-249.
13. Perkin GD, Rose FC. *Optic Neuritis and Its Differential Diagnosis*. New York, NY: Oxford University Press Inc; 1979:22.

ARCHIVES Web Quiz Winner

Congratulations to the winner of our May quiz, Noemi Lois, MD, PhD, Retina Service, Ophthalmology Department, Aberdeen Royal Infirmary, Aberdeen, Scotland. The correct answer to our May challenge was juxtafoveal retinal pigment epithelial hamartoma. For a complete discussion of this case, see the Clinicopathologic Reports, Case Reports, and Small Case Series section in the June ARCHIVES (Holz FG, Alexandridis E, Völcker HE, Dithmar S, Grossniklaus HE. Spontaneous incomplete avulsion of juxtafoveal retinal pigment epithelial hamartoma. *Arch Ophthalmol*. 2001;119:903-907).

Be sure to visit the *Archives of Ophthalmology* World Wide Web site (<http://www.archophthalmol.com>) and try your hand at our Clinical Challenge Interactive Quiz. We invite visitors to make a diagnosis based on selected information from a case report or other feature scheduled to be published in the following month's print edition of the ARCHIVES. The first visitor to e-mail our Web editors with the correct answer will be recognized in the print journal and on our Web site and will also receive a free copy of the book *The Art of JAMA II*.

