

# Results After Lens Extraction in Patients With Diabetic Retinopathy

## Early Treatment Diabetic Retinopathy Study Report Number 25

Emily Y. Chew, MD; William E. Benson, MD; Nancy A. Remaley, MS; Anna A. Lindley, PhD; Thomas C. Burton, MD; Karl Csaky, MD, PhD; George A. Williams, MD; Frederick L. Ferris III, MD; for the Early Treatment Diabetic Retinopathy Study Research Group

**Objective:** To assess the visual results after surgical lens removal in patients with diabetic retinopathy.

**Design:** A multicenter randomized clinical trial designed to assess the effect of photocoagulation and aspirin in patients with mild to severe nonproliferative or early proliferative diabetic retinopathy and/or macular edema.

**Participants:** Of the 3711 patients enrolled in the Early Treatment Diabetic Retinopathy Study, lens surgery was performed on 205 patients (270 eyes) during follow-up that ranged from 4 to 9 years.

**Outcome Measurements:** Visual acuity, macular edema status, and degree of diabetic retinopathy. In addition, risk factors associated with lens extraction and with poor postoperative visual acuity (worse than 20/100) were assessed.

**Results:** The risk of lens extraction increased with increasing age, female sex, and baseline proteinuria. Ocular variables associated with increased risk of lens surgery included poor baseline visual acuity and vitrectomy performed during the course of the study. At 1 year after lens surgery, visual acuity improvement of 2 or more lines from preoperative levels occurred in 64.3% of the operated-on eyes assigned to early photocoagulation and 59.3% of eyes assigned to deferral of photocoagulation. In eyes assigned to early photocoagulation, 46% of eyes achieved visual acuity better than 20/40; 73%, better than 20/100; and 8%, 5/200 or worse at 1 year after surgery. Visual acuity results for eyes assigned to deferral of laser photocoagulation at 1 year were not as favorable; 36% achieved visual acuity better than 20/40; 55%, better than 20/100;

and 17%, 5/200 or worse at 1 year after surgery. Evaluation of 1-year postoperative visual acuities for all eyes with mild to moderate nonproliferative diabetic retinopathy at the annual visit before lens surgery showed that 53% were better than 20/40; 90%, better than 20/100; and 1%, 5/200 or worse. However, for eyes with severe nonproliferative or worse retinopathy at the annual visit before lens surgery, only 25% were better than 20/40; 42%, better than 20/100; and 22%, 5/200 or worse at 1 year after lens surgery. There was little change in visual acuity between 1 and 2 years postoperatively. Increased severity of retinopathy and poor visual acuity before surgery were associated with visual acuity of worse than 20/100 at 1 year after surgery. Lens surgery was associated with a borderline statistically significant increased risk of progression of diabetic retinopathy in the adjusted analyses ( $P = .03$ ). No statistically significant long-term increased risk of macular edema was documented after lens surgery.

**Conclusions:** Visual acuity results after lens surgery in patients in the Early Treatment Diabetic Retinopathy Study were better than published results for similar patients. This may be because of more intensive photocoagulation for lesions of diabetic retinopathy in the Early Treatment Diabetic Retinopathy Study than in previously reported studies. Although patients with severe nonproliferative retinopathy or worse before lens surgery had poorer visual results, visual improvement was seen in 55% of these patients at 1-year follow-up. The main causes of poor visual results in eyes after lens surgery were complications of proliferative retinopathy and/or macular edema.

*Arch Ophthalmol.* 1999;117:1600-1606

The affiliations of the authors appear in the acknowledgment section at the end of the article.

CATARACT is a major cause of visual loss in patients with diabetes mellitus.<sup>1</sup> Results of lens surgery in persons with diabetic retinopathy have been reported to be less favorable than those in nondiabetic persons. These published reports suggest that postoperative visual acuity of 20/200 or worse may occur in 28% to 50% of patients with diabetic retinopathy.<sup>2,3</sup> Accelerated progression of diabetic retinopathy has been reported after lens surgery.<sup>4,5</sup>

The Early Treatment Diabetic Retinopathy Study (ETDRS) was a randomized clinical trial designed to assess the effect of photocoagulation and aspirin in the treatment of patients with mild to severe nonproliferative or early proliferative diabetic retinopathy and/or macular edema. This prospective study with 4 to 9 years of follow-up offered an opportunity to study

## SUBJECTS AND METHODS

From April 1980 to July 1985, the ETDRS enrolled 3711 patients with diabetes mellitus who met the following ocular criteria: (1) no macular edema, visual acuity of 20/40 or better, and moderate or severe nonproliferative or early proliferative diabetic retinopathy; or (2) macular edema, visual acuity of 20/200 or better, and mild, moderate, or severe nonproliferative or early proliferative diabetic retinopathy.<sup>6</sup> All patients were bilaterally phakic, and the refractive medium of each eye was clear enough to allow good-quality stereoscopic fundus photographs. Red reflex photographs were taken of each eye to exclude marked cataract that impaired the quality of the stereoscopic fundus photographs. Patients were scheduled for follow-up examinations at 4-month intervals, and slitlamp biomicroscopy was performed according to protocol.<sup>6</sup> Informed consent was obtained from each patient before enrolling in the study.

All patients were assigned randomly to receive aspirin, 650 mg/d, or placebo. One eye of each patient was assigned randomly to early photocoagulation and the other eye to deferral of photocoagulation, ie, photocoagulation only if "high-risk" proliferative diabetic retinopathy developed during follow-up. Details of the study design and strategies of photocoagulation have been described previously.<sup>7,8</sup> The assessment of different types of cataract (nuclear, cortical, or posterior subcapsular), either clinically or photographically, was not included in the design of this study. There were no defined criteria for lens extraction in the protocol. Lens surgery was determined to be necessary by the study ophthalmologist. The technique of lens surgery (intracapsular or extracapsular lens

surgery, phacoemulsification, lens implantation, or capsulotomy), the intraoperative complications, and postoperative course were not documented on the ETDRS data forms.

Best-corrected visual acuity was measured with logarithmic visual acuity charts at baseline and each subsequent follow-up visit scheduled at 4-month intervals.<sup>9</sup> A standardized protocol for the collection of visual acuity measurement was used in all clinical centers. The protocol specified that visual acuity examiners be trained and certified and that they be masked to treatment assignment.<sup>6</sup>

The Cox proportional hazards model was used to assess the potential risk factors associated with lens surgery and to assess the significance of lens surgery as a potential risk factor for a 2-step worsening of retinopathy in eyes assigned to deferral of photocoagulation. Lens surgery during follow-up was entered into this model as a time-dependent covariate. Relative risks and 99% confidence intervals (CIs) were estimated. A relative risk equal to 1.0 indicates no association with the risk factor (eg, a 2-step increase in retinopathy severity). A relative risk greater than 1 indicates an increased risk, and a relative risk less than 1 indicates a decreased risk. The generalized estimating equations (GEE) approach to logistic regression was used to assess the risk of progression of retinopathy after lens surgery in eyes of patients who underwent unilateral lens surgery.<sup>10</sup> The GEE approach was also used to identify risk factors associated with decreased visual acuity for all eyes after lens surgery.

Because of multiple outcome variables and multiple comparisons, a *P* value between .05 and .01 was considered suggestive of an association and a *P* value of .01 or less was considered statistically significant in these analyses. In addition, 99% CIs were used in all the ETDRS analyses.

the visual acuity and the course of the retinopathy after lens surgery in 205 patients with diabetic retinopathy.

### RESULTS

#### RISK FACTORS ASSOCIATED WITH LENS EXTRACTION

Lens surgery occurred in 270 eyes of 205 persons during follow-up. **Table 1** compares baseline characteristics for patients with and without lens surgery. Those having surgery were more likely to be white, to be older, and to have had type 1 diabetes mellitus. With the use of the data from the entire cohort of patients (*n* = 3711), a Cox proportional hazards model was performed to determine the risk factors associated with having lens surgery in this population. Univariate analyses were performed on selected ocular variables (visual acuity, severity of retinopathy, presence of non-high-risk proliferative diabetic retinopathy, macular edema, intraocular pressure, and assignment of laser photocoagulation [early focal, early scatter, or deferred]) and general variables (age, sex, race, type and duration of diabetes, assignment of aspirin use, blood pressure at baseline, diuretic use, body mass index [calculated as weight in kilograms divided by the square of height in meters], smoking, glycosylated hemoglobin concentration, proteinuria, and serum cholesterol level). Risk fac-

tors that were significant at *P* < .10 were placed in the final model. The significant risk factors in the final multivariable analyses are shown in **Table 2**.

For every increase in age by 10 years, there was a 66% increase in the risk of lens surgery. This means that the risk of lens surgery was increased by almost 5-fold in a 55-year-old compared with that of a 25-year-old. Women had a 41% increased risk of lens extraction compared with men, and patients with proteinuria had a 52% increased risk.

Ocular risk factors associated with increased risk of lens surgery included poor visual acuity at baseline. Each decrease of 10 letters (or 2 lines of vision) was associated with a 32% increased risk of lens surgery.

An additional analysis was performed with the baseline variables and the nonbaseline variable of vitrectomy. With this additional factor, the previous results of the Cox proportional hazards model were not changed. Patients who had vitrectomy during the course of the study before the cataract surgery had more than a 7-fold increase in the risk of lens extraction compared with patients who did not have the procedure.

#### PHOTOCOAGULATION BEFORE LENS EXTRACTION

The proportions of eyes that received focal and/or scatter photocoagulation are shown in **Table 3**. Eyes as-

**Table 1. Baseline Characteristics of Patients With and Without Lens Surgery**

	Lens Surgery	
	Yes (n = 205)	No (n = 3506)
Sex, % male	43.3	57.2*
Race, % white	79.5	76.2
Age at entry, mean ± SD, y	54 ± 12	47 ± 14†
Age at diagnosis, y	38 ± 15	32 ± 16†
Duration of diabetes, y	16 ± 8	15 ± 7
Type of diabetes, ‡ %		
Type 1	17.1	31.2†
Mixed	45.4	38.1
Type 2	37.6	30.7
Positive urine protein, %	30.9	28.2
Glycosylated hemoglobin	0.12 ± 0.03	0.12 ± 0.03

\*P < .01.

†P < .001.

‡Type 1: age at diagnosis of diabetes at 30 years or younger, started continuous insulin use within 1 year of diagnosis, and percentage of desirable weight lower than 120%. Type 2: age at diagnosis of diabetes older than 30 years and never or only intermittently used insulin, or age at diagnosis of diabetes older than 40 years and percentage of desirable weight at 120% or greater. The remaining patients are designated as "mixed."

**Table 2. Significant Risk Factors Associated With Lens Extraction\***

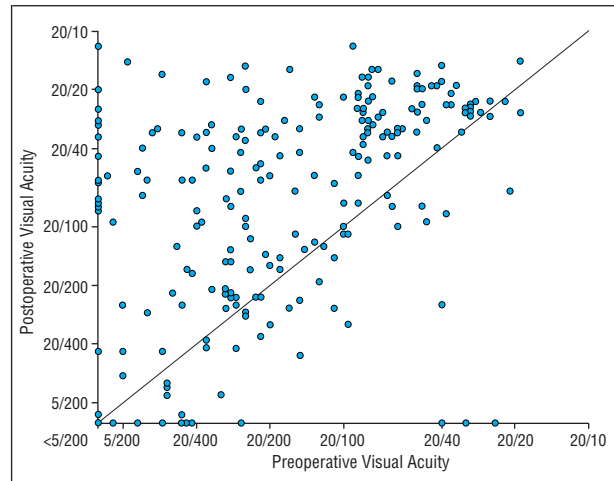
Variable	Relative Risk (99% CI)	P
Visual acuity at randomization visit (each 10 letters)	1.32 (1.17-1.48)	<.001
Age (each 10 years)	1.66 (1.34-2.04)	<.001
Female sex	1.41 (1.02-1.97)	.007
Vitrectomy	7.57 (4.86-11.77)	<.001
Proteinuria	1.52 (1.08-2.16)	.002

\*Proportional hazard of cataract surgery (n = 268) among 7394 eyes from the Early Treatment Diabetic Retinopathy Study, 99% confidence intervals (CIs), and P values.

**Table 3. Rates of Laser Photocoagulation Before Lens Surgery**

Laser Photocoagulation	No. (%)	
	Eyes Assigned to Early Photocoagulation	Eyes Assigned to Deferral of Photocoagulation
None	0 (0)	51 (35.2)
Focal only	15 (12.0)	33 (22.8)
Scatter only	14 (11.2)	30 (20.7)
Focal and scatter	96 (76.8)	31 (21.4)
<b>Total</b>	<b>125 (100.0)</b>	<b>145 (100.0)</b>

signed to early photocoagulation were more likely than eyes assigned to deferral of photocoagulation to have received scatter and/or focal photocoagulation before lens surgery. However, 64.8% of eyes assigned to deferral of photocoagulation also had scatter and/or focal photocoagulation before lens surgery.



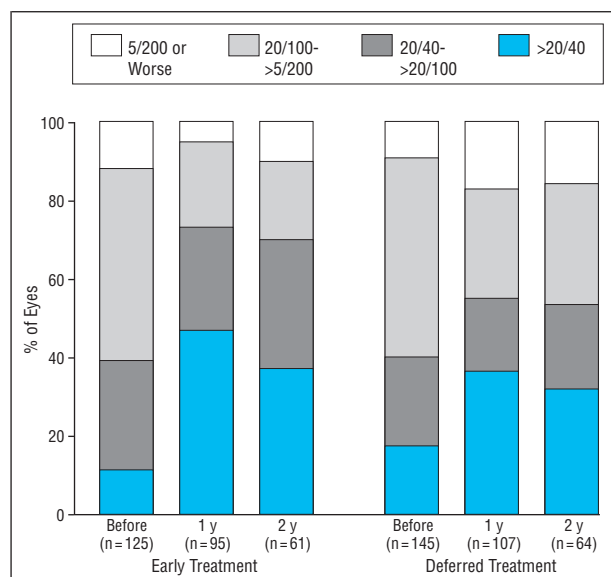
**Figure 1.** Preoperative and postoperative visual acuities of the 270 eyes (205 patients) that underwent lens surgery. Visual acuity improved in a majority of the operated-on eyes.

## VISUAL ACUITY AFTER LENS SURGERY

A large proportion of all the operated-on eyes had improved visual acuity postoperatively, as shown on the scatterplot in **Figure 1**. After lens surgery, 64% of the operated-on eyes assigned to early photocoagulation and 49% of the eyes assigned to deferral of photocoagulation had 2 or more lines (10 or more letters) of improvement in visual acuity at 1 year compared with the visual acuity at the preoperative visit. Twenty-six percent experienced little change in visual acuity (<10-letter change between preoperative and postoperative visual acuity), while 10% had experienced 2 or more lines (10 or more letters) of deterioration in visual acuity at 1 year after the surgery in eyes assigned to photocoagulation. For eyes assigned to deferral of photocoagulation, 36% experienced little change, while 15% had a decrease of 2 or more lines (10 or more letters) of visual acuity at 1 year after surgery.

Comparing 1-year postoperative visual acuity with preoperative visual acuity showed that 54% of the eyes assigned to early photocoagulation and 47% of the deferral group had a visual acuity gain of 3 or more lines (15 or more letters). Three-line visual acuity loss rates at 1 year in eyes assigned to early photocoagulation and eyes assigned to deferral of photocoagulation were 5% and 11%, respectively.

Eyes assigned to early photocoagulation had a trend toward a better visual acuity outcome after lens surgery than eyes assigned to deferral, but this was not statistically significant (P = .04). At 1 year after lens surgery, 46% of these eyes assigned to early photocoagulation achieved visual acuity better than 20/40; 73%, better than 20/100; and 5%, 5/200 or worse (**Figure 2**). Visual acuity at 1 year after lens surgery for eyes assigned to deferral of laser photocoagulation was somewhat less favorable, with 36% achieving visual acuity better than 20/40; 55%, better than 20/100; and 17%, 5/200 or worse (**Figure 2**). The visual acuity results were similar at the second annual visit after lens surgery, and the differences between the early photocoagulation and deferral groups were not statistically significant.

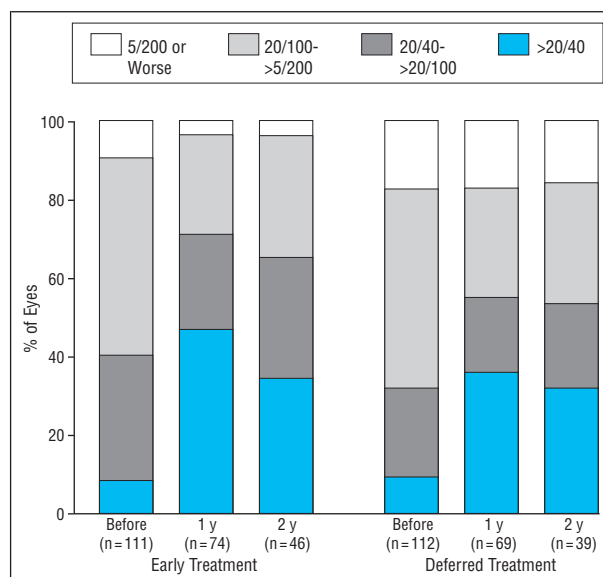


**Figure 2.** Distribution of visual acuity before and 1 and 2 years after lens extraction for all eyes, stratified according to the random assignment of laser photocoagulation at baseline, both early and deferred treatment.

Most of the lens surgery was done because of cataract; however, some may have been performed because of lens opacity that developed during or after vitrectomy. To evaluate a more direct effect of primary lens surgery on vision, analyses were performed with the exclusion of patients who had both vitrectomy and lens surgery. These results showed a smaller proportion of eyes with poor visual acuity of 5/200 or worse at 1 year after surgery: only 3% for eyes assigned to early photocoagulation and 5% for eyes assigned to deferral of photocoagulation (**Figure 3**). Patients who had both lens surgery and vitrectomy had poorer visual results after surgery; 30% of eyes assigned to early photocoagulation and 55% of eyes assigned to deferral had visual acuity of 5/200 or worse at 1 year after surgery.

#### THE EFFECT OF LENS SURGERY ON MACULAR EDEMA

Stereoscopic fundus photographs and fluorescein angiograms performed at annual visits were used to assess the effect of lens surgery on macular edema. The presence or absence of clinically significant macular edema before and after lens surgery was assessed by means of the gradings of the annual fundus photographs that bracketed the date of the operation. There was no statistically significant difference in the proportions of eyes with clinically significant macular edema before (29%) or after (31%) lens surgery. The proportion of eyes with clinically significant macular edema after cataract surgery was not markedly different from the proportion of eyes that did not have lens extraction. The proportion of eyes with clinically significant macular edema documented on stereoscopic fundus photographs in all ETDRS patients treated with photocoagulation was nearly 30% at the first annual visit. The proportions of eyes with cystoid changes associated with macular edema graded in fundus photographs taken before and after lens extraction were also not markedly different (2% preoperatively and 6% postoperatively). Clinical assessment of macular edema



**Figure 3.** Distribution of visual acuity before and 1 and 2 years after lens extraction for all eyes, excluding eyes treated with concurrent lensectomy and vitrectomy. The results are stratified according to the random assignment of laser photocoagulation at baseline, both early and deferred treatment.

4 months before and after lens surgery also showed no statistically significant difference (42% vs 45%, respectively).

#### RISK OF PROGRESSION OF RETINOPATHY AFTER LENS SURGERY

The results of the Cox proportional hazards model analyses of all eyes assigned to deferral of photocoagulation, including the 145 eyes that had lens extraction, showed that lens surgery, when entered into the model as a time-dependent covariable, was not associated with a statistically significant increased risk of a 2-step worsening of diabetic retinopathy. This model was adjusted for age, duration of diabetes, baseline retinopathy severity, and baseline glycosylated hemoglobin concentration. The odds ratio (OR) of an association of lens surgery and a 2-step progression of retinopathy was 1.50, with a 99% CI of 0.78 to 2.08 ( $P = .13$ ).

We also assessed the possible association of lens surgery with worsening retinopathy by means of GEEs. In the 140 patients with unilateral lens surgery, the GEE results, adjusted for severity of retinopathy at baseline and treatment assignment, showed that the eye with lens surgery had a strong trend toward increased risk of a 2-step progression of diabetic retinopathy when compared with the eye that did not undergo surgery. However, this trend (OR, 2.1; 99% CI, 0.9-5.7;  $P = .03$ ) failed to reach the predetermined statistical significance level of .01. Also, the assessment of the severity of retinopathy in the preoperative fundus photographs may have been compromised to an unknown degree by media opacity, resulting in a biased comparison.

#### DEVELOPMENT OF IRIS AND ANTERIOR CHAMBER NEOVASCULARIZATION

In the eyes that underwent lens surgery, 23 had developed iris and anterior chamber neovascularization, 7 before and 16 after cataract surgery. This rate of iris neo-



**Table 4. Severity of Retinopathy at Annual Visit Before Lens Extraction\***

	No. (%)	
	Immediate	Deferred
NPDR		
Mild	48 (47.1)	31 (25.4)
Moderate	17 (16.7)	30 (24.6)
Severe	2 (2.0)	6 (4.9)
PDR	34 (33.3)	51 (41.8)
VH/PRH on fundus examination and no photograph	1 (1.0)	4 (3.3)
<b>Total</b>	<b>102 (100.0)</b>	<b>122 (100.0)</b>
No grade (not gradable, or no photograph and/or examination)	23	23

\*NPDR indicates nonproliferative diabetic retinopathy; PDR, proliferative diabetic retinopathy; and VH/PRH, vitreous hemorrhage or preretinal hemorrhage.

**Table 5. Risk Factors Associated With Visual Acuity Less Than 20/100 1 Year After Lens Extraction (Multivariate Analysis)\***

	OR (99% CI)	P
Retinopathy level before lens extraction		
Mild NPDR	1.0	.001
Moderate-severe NPDR	3.4 (0.9-13.5)	
PDR	5.8 (1.6-20.8)	
Preoperative visual acuity†		
>20/100	1.0	<.001
20/100-20/400	8.7 (2.4-32.0)	
<20/400	12.6 (2.5-63.6)	

\*OR indicates odds ratio; CI, confidence interval; NPDR, nonproliferative diabetic retinopathy; and PDR, proliferative diabetic retinopathy.

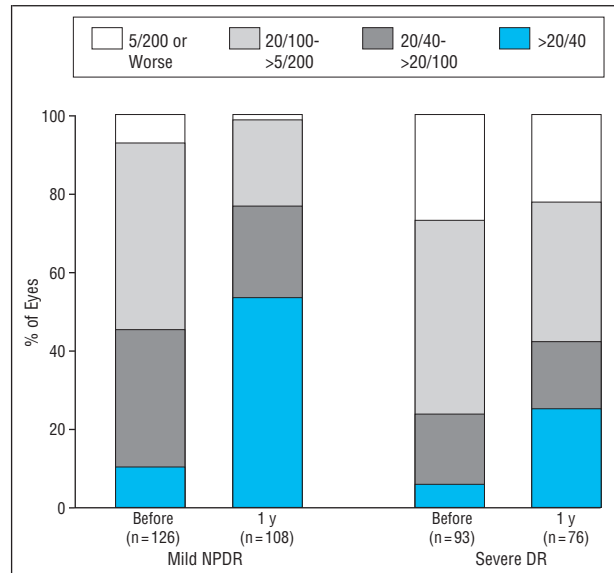
†Visual acuity as assessed at last visit before lens surgery.

vascularization (9%) is significantly higher than for the study as a whole (1.9% [141/7422]) ( $P = .001$ ).

Not surprisingly, iris neovascularization was associated with a poor visual outcome. Seventy percent (16/23) of eyes with lens surgery and iris neovascularization had visual acuity of less than 5/200 at 1 year after lens surgery. Thirteen of these 23 eyes with iris neovascularization and lens surgery also had vitreous surgery. All 13 had visual acuity of less than 5/200 at 1 year after lens surgery.

#### RISK FACTORS ASSOCIATED WITH VISUAL ACUITY WORSE THAN 20/100 AFTER LENS SURGERY

Possible risk factors associated with a poor visual outcome (visual acuity never 20/100 or better after lens surgery) were assessed by GEE analysis. The risk factors assessed included the following systemic characteristics: age, sex, race, body mass index, type of diabetes, duration of diabetes, blood pressure, fasting serum cholesterol level, urine proteinuria, and glycosylated hemoglobin concentration. Other risk factors included current cigarette smoking, diuretic use, and treatment group assignment (both photocoagulation and aspirin). Ocular risk factors included macular edema at baseline, reti-



**Figure 4.** Distribution of visual acuity before and 1 year after lens extraction for all eyes, stratified by the severity of retinopathy before lens extraction. Mild NPDR represents mild to moderate nonproliferative diabetic retinopathy; severe DR, severe nonproliferative retinopathy to proliferative retinopathy with or without vitreous or preretinal hemorrhage.

nopathy severity before lens surgery (**Table 4**), intraocular pressure, and preoperative visual acuity.

The multivariable model identified 2 statistically significant risk factors. These were more severe diabetic retinopathy preoperatively ( $P = .001$ ) and decreased visual acuity before lens surgery ( $P < .001$ ) (**Table 5**). Patients with moderate to severe nonproliferative diabetic retinopathy and proliferative diabetic retinopathy had an increased risk of poor visual results when compared with patients with mild nonproliferative retinopathy (OR, 3.8; 99% CI, 0.9-13.5; and OR, 5.8; 99% CI, 1.6-20.8, respectively). It is expected that poor visual acuity before lens surgery is more likely to be associated with poor visual acuity outcome after surgery. Patients with poor preoperative visual acuity had an increased risk of decreased postoperative visual acuity (OR, 12.6; 99% CI, 2.6-63.5 for eyes having preoperative visual acuity worse than 20/400 compared with eyes having preoperative visual acuity of 20/100 or better).

The importance of the severity of retinopathy at the time of cataract surgery is seen in the visual acuity results at 1 year after surgery (**Figure 4**). Comparing the eyes with mild nonproliferative diabetic retinopathy before surgery with the eyes with more severe retinopathy showed that the proportion of eyes with visual acuity better than 20/40 at 1 year after surgery was 53% vs 25% ( $P < .001$ ). More strikingly, only 1% of the eyes with mild nonproliferative diabetic retinopathy had visual acuity worse than 5/200 1 year after surgery compared with 22% of the eyes with more severe retinopathy ( $P < .001$ ).

#### CAUSES OF VISION LOSS

In the 11 eyes with mild to moderate retinopathy before lens surgery and visual acuity of 20/200 or worse at 1 year after surgery, macular edema accounted for the poor visual acuity in 8 eyes (73%). In contrast, of the 37 eyes

with severe nonproliferative retinopathy or worse before lens surgery and visual acuity of 20/200 or worse at 1 year after surgery, vitreous hemorrhage and/or traction retinal detachment that required vitrectomy accounted for the poor visual acuity in 20 eyes (54%). Nine of these 20 eyes had lens surgery at the time of vitrectomy, 8 after, and 3 before the vitrectomy. The remaining 17 (43%) of these 37 eyes had poor visual outcome secondary to macular edema associated with hard exudate plaques in the center of the fovea.

#### COMMENT

The risk factors associated with lens extraction in the ETDRS included increasing age, female sex, and baseline proteinuria. Age and female sex were previously reported to be significant risk factors associated with cataracts.<sup>11-13</sup> Similar to the results of the risk factor analysis of cataract extraction in the Wisconsin Epidemiologic Study of Diabetic Retinopathy, proteinuria at baseline was a significant risk factor associated with cataract development in the ETDRS.<sup>14</sup> Proteinuria at baseline may be an important marker of other unknown metabolic effects of diabetes that may increase the risk of development of cataract.

There are limitations to using a study such as the ETDRS for the analyses of risk factors because patients were highly selected. Patients had to be in relatively good health, be willing to enter a clinical trial, and have specified levels of diabetic retinopathy. The lens of each patient in the ETDRS had to have sufficient clarity to allow quality fundus photographs. There are also limitations to the study regarding the visual acuity results. The lens surgery occurred relatively late in the course of the study; thus, 20% finished the study before their first annual follow-up and 49% before their second annual follow-up visit after surgery. However, strengths of the data from the ETDRS cohort of patients include the low rate of losses to follow-up, the availability of the best-corrected visual acuities throughout the study, good documentation of retinopathy severity at annual intervals, and the enrollment of patients with retinopathy at clinically important stages.

There are interesting similarities and differences of our results compared with other published data. The findings of the risk factor analyses for lens extraction were similar to those of the Wisconsin Epidemiologic Study of Diabetic Retinopathy, a population-based study.<sup>14</sup> The visual acuity results of patients who had lens surgery in the ETDRS seem generally better than in previously published series.<sup>2,3,15,16</sup> However, the lack of uniformity in the classification of the diabetic retinopathy used by other investigators makes it difficult to compare our results with published results. In addition, the duration of follow-up in other studies was variable, and the sample sizes were often small. In one previously published series in which eyes were classified as having nonproliferative retinopathy with or without macular edema, the proportion of patients with visual acuity worse than 20/100 ranged from 25% to 31%.<sup>2</sup> In another study, which included only eyes with "background diabetic retinopathy" at the time of lens surgery, 50% (16/32) of patients had visual acuity of 20/100 or worse on follow-up.<sup>9</sup> In the ETDRS, only 11%

of patients with mild to moderate nonproliferative retinopathy before cataract had this level of visual acuity at 1 year of follow-up.

The visual acuity results at 1 year after lens surgery for ETDRS patients with severe nonproliferative retinopathy or worse at the annual visit before lens surgery were worse than for eyes with less severe retinopathy. Again, study methods make comparison with previously published studies difficult. However, in several case series that included eyes with more severe retinopathy at the time of lens surgery, the proportion of eyes with visual acuity worse than 20/200 postoperatively ranged from 25% to 50%.<sup>2,9,15-19</sup> Severity of retinopathy at the time of lens removal is the most important predictor of poor visual acuity outcome in previously reported studies<sup>19</sup> and in ETDRS patients. However, even in the group of ETDRS patients with more severe retinopathy, a large proportion (55%) did improve by 2 lines of vision, with 25% achieving visual acuity of 20/40 or better and 42% achieving 20/100 or better.

The random assignment of 1 eye of each ETDRS patient to immediate photocoagulation was one of the variables included in the multivariable regression analyses for risk factors associated with poor visual acuity after lens surgery. Although eyes assigned to the early photocoagulation group in general had a better outcome after lens surgery than eyes in the deferral of photocoagulation group (46.3% vs 36.4% with visual acuity better than 20/40 at 1 year after surgery), early photocoagulation was not a statistically significant risk factor in the multivariable regression analysis. However, early scatter photocoagulation was associated with less severe retinopathy before lens surgery. In addition, because the study design required scatter photocoagulation for all eyes that reached high-risk proliferative retinopathy, and because the study protocol eventually recommended focal photocoagulation for eyes assigned to deferral of photocoagulation that had clinically significant macular edema, a majority of patients (81% of eyes in this report) received some photocoagulation before lens surgery. Two thirds of these eyes had focal photocoagulation and almost half had scatter before lens surgery.

The proportion of patients treated with photocoagulation for lesions of diabetic retinopathy before lens surgery appears to be much higher in the ETDRS patients than in previously published series. Prior photocoagulation may be one of the reasons for the apparently relatively good visual results in the ETDRS series of patients. Photocoagulation in patients with severe nonproliferative diabetic retinopathy or clinically significant macular edema should be considered before lens surgery when possible. If this is not feasible, photocoagulation should be considered soon after lens surgery.

Although it was reported in previous studies, we did not observe an increased rate of macular edema after lens surgery. The rates of macular edema preoperatively and postoperatively were nearly identical in both the 4-month clinical assessment and the annual photographic assessment. Because of the timing of these assessments, an accelerated rate of macular edema development immediately after lens surgery cannot be ruled out. In the long term, however, there were no demonstrable increased rates

of macular edema after surgery. It is possible that the rate of macular edema was not increased, but that the severity of edema after surgery was increased. It is also possible that the high rate of focal photocoagulation performed before surgery may have had a protective effect on the development of postoperative macular edema in the ETDRS population.

Macular edema, especially when associated with extensive hard exudate or fibrous plaque, accounted for a large proportion of eyes with poor postoperative visual acuity. In a previous report of the ETDRS results, elevated serum lipid levels were associated with an increased risk of retinal hard exudate.<sup>20</sup> Although retinal hard exudate usually accompanied diabetic macular edema, increasing amounts of exudate appear to be independently associated with an increased risk of visual impairment. Treatment of preexisting macular edema and the often accompanying elevated serum lipid levels before lens surgery seems indicated.<sup>20,21</sup>

Previous studies have reported an acceleration of retinopathy severity after lens surgery, while 1 prospective study found no increased risk of progression associated with lens extraction.<sup>22</sup> Our study found a nonstatistically significant trend toward an increased risk of worsening retinopathy after lens surgery, by means of both the Cox proportional hazards model and the GEE model. Differences between our results and those previously published may be related to a difference in the methods of analysis or the considerable differences in the populations studied. Many of the previous studies did not adjust for baseline retinopathy, duration of diabetes, or degree of glucose control. A more important difference may be related to the amount of photocoagulation before lens surgery in our study compared with previous studies. We performed our proportional hazards analyses on eyes that were assigned to deferral of photocoagulation, but even in this group, 65% of the 145 eyes had received some photocoagulation before the lens surgery. This extensive degree of photocoagulation may have been responsible for less progression of retinopathy than previously reported, especially in patients with type 2 diabetes mellitus.<sup>23</sup>

No systemic risk factors were found to be associated with poorer visual acuity at the annual visit after lens surgery. The ocular risk factors associated with poor postoperative visual acuity included more severe retinopathy and poor preoperative visual acuity.

The relatively good visual outcome for ETDRS patients after lens surgery is encouraging. The high rate of photocoagulation before lens surgery in ETDRS patients may be partially responsible for these encouraging results. On the basis of these data, one might initiate photocoagulation before (when possible) or soon after lens surgery for patients with severe nonproliferative retinopathy or worse and for all patients with macular edema. Patients with severe nonproliferative retinopathy or worse before lens surgery, regardless of photocoagulation status, should be warned of a guarded prognosis.

Accepted for publication June 4, 1999.

From the Division of Biometry and Epidemiology (Drs Chew, Lindley, and Ferris and Ms Remaley) and Laboratory of Immunology (Dr Csaky), National Eye Institute, Na-

tional Institutes of Health, Bethesda, Md; Jefferson Medical College, Philadelphia, Pa (Dr Benson); and William Beaumont Hospital, Royal Oak, Mich (Dr Williams). Dr Burton is in private practice in Milwaukee, Wis. A list of the Early Treatment Diabetic Retinopathy Study investigators appears at the end of ETDRS Report No. 7 (Ophthalmology. 1991;98:741-756).

The ETDRS was supported by contracts from the National Eye Institute, National Institutes of Health, Bethesda, Md, and the US Department of Health and Human Services, Washington, DC.

Reprints: Emily Y. Chew, MD, National Institutes of Health, Bldg 31, Room 6A52, 31 Center Dr, Mail Stop MSC-2510, Bethesda, MD 20892-2510 (e-mail: echew@nei.nih.gov).

## REFERENCES

1. Klein R, Klein BEK, Moss SE. Visual impairment in diabetes. *Ophthalmology*. 1984; 91:1-8.
2. Benson WE, Brown GC, Tasman W, McNamara JA, Vander JF. Extracapsular lens surgery with placement of a posterior chamber lens in patients with diabetic retinopathy. *Ophthalmology*. 1993;100:730-738.
3. Schatz H, Atienza D, McDonald R, Johnson RN. Severe diabetic retinopathy after cataract surgery. *Am J Ophthalmol*. 1994;117:314-321.
4. Cuncliffe IA, Flanagan DW, George NDL, et al. Extracapsular lens surgery with lens implantation in diabetics with and without proliferative retinopathy. *Br J Ophthalmol*. 1991;75:9-12.
5. Jaffe GJ, Burton TC, Kuhn E, Prescott A, Hartz A. Progression of nonproliferative diabetic retinopathy and visual outcome after extracapsular lens surgery and intraocular lens implantation. *Am J Ophthalmol*. 1992;114:448-456.
6. Early Treatment Diabetic Retinopathy Study Research Group. Early Treatment Diabetic Retinopathy Study design and baseline patient characteristics: Early Treatment Diabetic Retinopathy Study Report No. 7. *Ophthalmology*. 1991;98:741-756.
7. Early Treatment Diabetic Retinopathy Study Research Group. Treatment techniques and clinical guidelines for photocoagulation of diabetic macular edema: Early Treatment Diabetic Retinopathy Study Report No. 2. *Ophthalmology*. 1987; 94:761-774.
8. Early Treatment Diabetic Retinopathy Study Research Group. Techniques for scatter and local photocoagulation treatment of diabetic retinopathy: Early Treatment Diabetic Retinopathy Study Report No. 3. *Int Ophthalmol Clin*. 1987;27: 254-264.
9. Ferris FL III, Kassof A, Bresnick GH, Bailey I. New visual acuity charts for clinical research. *Am J Ophthalmol*. 1982;94:91-96.
10. Zeger S, Liang KY, Albert PS. Models for longitudinal data: a generalized estimating equation approach. *Biometrics*. 1988;44:1049-1060.
11. Klein BEK, Klein R, Moss SE. Prevalence of cataracts in a population-based study of persons with diabetes. *Ophthalmology*. 1985;92:1191-1196.
12. Hiller R, Sperduto RD, Ederer F. Epidemiologic associations with nuclear, cortical and posterior subcapsular cataracts. *Am J Epidemiol*. 1986;124:916-925.
13. Leske CM, Sperduto RD. The epidemiology of senile cataracts: a review. *Am J Epidemiol*. 1983;118:142-165.
14. Klein BEK, Klein R, Moss SE. Incidence of cataract surgery in the Wisconsin Epidemiologic Study of Diabetic Retinopathy. *Am J Ophthalmol*. 1995;119:295-300.
15. Hykin PG, Gregson RMC, Stevens JD, Hamilton PAM. Extracapsular lens surgery in proliferative diabetic retinopathy. *Ophthalmology*. 1993;100:394-399.
16. Pollack A, Dotan S, Oliver M. Course of diabetic retinopathy following lens surgery. *Br J Ophthalmol*. 1991;75:2-8.
17. Aeillo LM, Wand M, Liang G. Neovascular glaucoma and vitreous hemorrhage following lens surgery in patients with diabetes mellitus. *Ophthalmology*. 1983; 90:814-820.
18. Pollack A, Leiba H, Bukelman A, Abrahami S, Oliver M. The course of diabetic retinopathy following lens surgery in eyes previously treated by laser photocoagulation. *Br J Ophthalmol*. 1992;76:228-231.
19. Dowler JG, Hykin PG, Lightman SL, Hamilton AM. Visual acuity following extracapsular cataract extraction in diabetes: a meta-analysis. *Eye*. 1995;9:313-317.
20. Chew EY, Klein ML, Ferris FL III, et al. Association of elevated serum lipid levels with retinal hard exudate in diabetic retinopathy: Early Treatment Diabetic Retinopathy Study (ETDRS) Report 22. *Arch Ophthalmol*. 1996;114:1079-1084.
21. The Early Treatment Diabetic Retinopathy Study Research Group. Photocoagulation for diabetic macular edema: Early Treatment Diabetic Retinopathy Study Report Number 1. *Arch Ophthalmol*. 1985;103:1796-1806.
22. Wagner T, Knaflic D, Rauber M, Mester U. Influence of cataract surgery on the diabetic eye: a prospective study. *Ger J Ophthalmol*. 1996;5:79-83.
23. Ferris FL. Early photocoagulation in patients with either type I or type II diabetes. *Trans Am Ophthalmol Soc*. 1996;94:505-537.