

Mutation Analysis of 3 Genes in Patients With Leber Congenital Amaurosis

Andrew J. Lotery, MD, FRCOphth; P. Namperumalsamy, MD, MS; Samuel G. Jacobson, MD, PhD; Richard G. Weleber, MD; Gerald A. Fishman, MD; Maria A. Musarella, MD; Creig S. Hoyt, MD; Elise Héon, MD; Alex Levin, MD; James Jan, MD; Byron Lam, MD; Ronald E. Carr, MD; Alan Franklin, MD, PhD; S. Radha, PhD; Jeaneen L. Andorf, BA; Val C. Sheffield, MD, PhD; Edwin M. Stone, MD, PhD

Objective: To assess the frequency of mutations in the *CRX*, *GUCY2D*, and *RPE65* genes in patients with Leber congenital amaurosis (LCA).

Patients: One hundred seventy-six probands with a clinical diagnosis of LCA were from 9 countries, with the largest subgroup being 39 probands from India.

Methods: Samples were screened with single-strand conformation polymorphism analysis followed by DNA sequencing of 3 genes (*CRX*, *GUCY2D*, and *RPE65*) known to be associated with LCA.

Results: Of the 176 probands, 28 (15.9%) harbored possible disease-causing mutations. The relative contribution of each gene to the total number of mutations was as follows: *CRX*, 2.8%; *GUCY2D*, 6.3%; and *RPE65*, 6.8%. No patients who harbored mutations in these genes had

associated systemic abnormalities. Molecular diagnosis allowed definitive genetic counseling in a family affected with Best disease and LCA.

Conclusions: Molecular diagnosis may be of benefit to patients affected with LCA. The relative paucity of mutations found in this study suggests that more LCA-associated genes remain to be discovered.

Clinical Relevance: Molecular diagnosis can confirm and clarify the diagnosis of LCA. As genotype data accumulate, clinical phenotypes associated with specific mutations will be established. This will facilitate the counseling of patients on their visual prognosis and the likelihood of associated systemic anomalies.

Arch Ophthalmol. 2000;118:538-543

LEBER CONGENITAL amaurosis (LCA) is a term used to refer to a group of disorders characterized by severe visual impairment in the first year of life, nystagmus, and a markedly abnormal electroretinogram. The fundus appearance can initially be normal, but macular colobomas, optic disc edema, bone-spicule-like pigmentation, and vascular attenuation are observed.¹⁻³ Most of the genes that cause the clinical phenotype known as LCA are transmitted in an autosomal recessive fashion. A small but significant fraction of patients with LCA will have additional neurologic problems, including developmental delay. An equally small percentage of children who are initially diagnosed as having LCA will retain surprisingly good visual function for decades. This wide range of potential clinical outcomes can make it difficult to provide specific prognostic information in individual cases. There is no medical or surgical intervention that can alter the course of LCA.

In 1996, a significant advance in the understanding of LCA occurred when Perrault and coworkers⁴ identified the first gene whose mutation was capable of causing the LCA phenotype, retinal guanylate cyclase (*GUCY2D*). This was followed in successive years by the identification of 2 additional LCA-causing genes, the retinal pigment epithelium-specific gene known as *RPE65*⁵ and the photoreceptor-specific homeobox gene known as *CRX*.⁶ Recently, the *TULP1* gene encoding the Tubby-like protein 1 has also been shown to produce an LCA phenotype but only in a single Dominican family.⁷ The identification of these disease genes raised the possibility of identifying specific genotype-phenotype correlations that could be used to provide more accurate diagnostic and prognostic information to patients. Improved understanding of a disease gene also has the potential to provide sufficient new insight into the pathophysiological features of a disease so that effective therapy can be developed.

Affiliations of the authors appear at the end of the article.

PATIENTS AND METHODS

Informed consent was obtained from all study patients or their legal guardians. One hundred patients were from the United States, 39 from India, 28 from Canada, 3 from Israel, 2 from Switzerland, 1 from Italy, 1 from Jordan, 1 from Pakistan, and 1 from Honduras. DNA was extracted from peripheral blood using a previously described protocol.⁸ The proband of each family was screened for mutations in the coding sequence of the *GUCY2D*, *RPE65*, and *CRX* genes by single-strand conformation polymorphism analysis. Ninety-six control subjects from Iowa were screened in an identical fashion for each gene. An additional 47 control patients were from India. These Indian control samples were screened for variations in the 5 exons, in which sequence variations were found in affected Indian patients. The primer sequences used for the single-strand conformation polymorphism screening have been previously described.^{4,5,9} The polymerase chain reaction amplification products were denatured for 3 minutes at 94°C and then electrophoresed on 6% polyacrylamide–5% glycerol gels at 25 W for about 3 hours. The gels were then stained with silver nitrate.¹⁰ Polymerase chain reaction products from samples with aberrant migration patterns were then sequenced bidirectionally with fluorescent dideoxynucleotides on an automated sequencer (model 377; Applied Biosystems, Foster City, Calif). The clinical records of patients who were found to harbor a sequence change were reviewed, and this phenotypic information was correlated with the associated genotype wherever possible. Refractions were calculated as spherical equivalents in diopters (D). Two patients harboring *CRX* gene mutations (**Table 1**) have been described previously^{6,12} and are included in this report because they were part of the original cohort.

This study was undertaken to determine the frequency of mutations in the *GUCY2D*, *RPE65*, and *CRX* genes in 176 individuals affected with LCA and to look for genotype-phenotype correlations that might be clinically useful. During this study, we were able to deduce a full molecular explanation for a challenging set of clinical findings that we observed in one of the families. This family is described in detail to demonstrate the potential utility of molecular diagnosis in the management of rare, clinically heterogeneous disorders such as LCA.

RESULTS

A family of Jordanian ancestry consisting of 2 parents and 3 sons was initially seen for diagnosis and genetic counseling. The parents, who were first cousins, each had a normal visual acuity. They also had essentially normal fundus examination results, although careful biomicroscopy revealed subtle yellow dots at the level of the retinal pigment epithelium in their maculae. Of the 3 sons, the eldest was aged 16 years and had a history of con-

Table 1. Probable Disease-Causing Mutations Observed in Patients With Leber Congenital Amaurosis*

Gene	Sequence Changes	Nonconservative Changes
<i>CRX</i>	Ala56Thr	1
<i>CRX</i>	Ala158Thr	1
<i>CRX</i>	2-bp del (ag) codon 168†	1
<i>CRX</i>	Ala158Thr	1
<i>CRX</i>	1-bp del (g), codon 217†	1
<i>GUCY2D</i>	Homozygous Arg1064Gly	1
<i>GUCY2D</i>	Homozygous Tyr770Cys	0
<i>GUCY2D</i>	Arg684Stop	1
<i>GUCY2D</i>	Arg684Gln	1
<i>GUCY2D</i>	10-bp dup, codon 502	1
<i>GUCY2D</i>	Arg792Trp	1
<i>GUCY2D</i>	Arg792Trp	1
<i>GUCY2D</i>	Arg792Trp	1
<i>GUCY2D</i>	Met797Leu	0
<i>GUCY2D</i>	Met797Leu	0
<i>GUCY2D</i>	1-bp del (c), codon 991	1
<i>RPE65</i>	Homozygous Glu462Stop, <i>RPE65</i> , and homozygous Gly222Val, bestrophin	1
<i>RPE65</i>	Asn321Lys	1
<i>RPE65</i>	65 +5g→a, splice site‡	1
<i>RPE65</i>	65 +5g→a, splice site‡	1
<i>RPE65</i>	1-bp del (g), codon 46	1
<i>RPE65</i>	1-bp ins (±), codon 357 and Ala393Gly	2
<i>RPE65</i>	Ala434Val§	0
<i>RPE65</i>	Homozygous 20-bp del, codon 97, exon 4	1
<i>RPE65</i>	65 +5g→a, splice site‡ and 1-bp del (g), codon 298	1
<i>RPE65</i>	Homozygous Val287Phe	0
<i>RPE65</i>	Homozygous Arg91Trp§	1
<i>RPE65</i>	Homozygous 65 +5g→a, splice site‡	1

*Each row in this table refers to an individual patient. bp indicates base pair; del, deletion; dup, duplication; c, constitutional anomaly; +, gain; →, from-to; and ins, insertion.

†Patients who have been previously described.^{6,12}

‡These patients harbor a mutation that was previously reported by Gu et al.¹⁶ The +5g→a is part of the consensus splice donor sequence and is conserved in 84% of the sites.¹¹ This change in the consensus sequence may cause a cryptic splice site, which may then translate an incorrect protein product, premature termination, or both.

§These patients harbor a mutation previously reported by Morimura et al.²

||These patients harbor a mutation previously reported by Marliens et al.⁵

genital esotropia. His visual acuity was 20/25 OU. He had several subretinal gliotic nodules in the macula of each eye in addition to some yellow deposits at the level of the retinal pigment epithelium (**Figure 1, A**). The middle brother was aged 13 years and had a visual acuity of 20/20 OU. He had subtle yellow deposits in each macula that were more prominent than those of his parents but much less prominent than those of his older brother (**Figure 1, B**). The youngest brother was aged 9 years. His visual acuity was counting fingers OU. Historically, he had searching, wandering eye movements since the first year of life and a nonrecordable electroretinogram. His fundus examination revealed absence of the foveal light reflex and a diffusely abnormal retinal pigment epithelium (**Figure 1, C**).

Electro-oculography was performed on the parents and the elder brothers. The Arden ratios (normal, >1.8) were

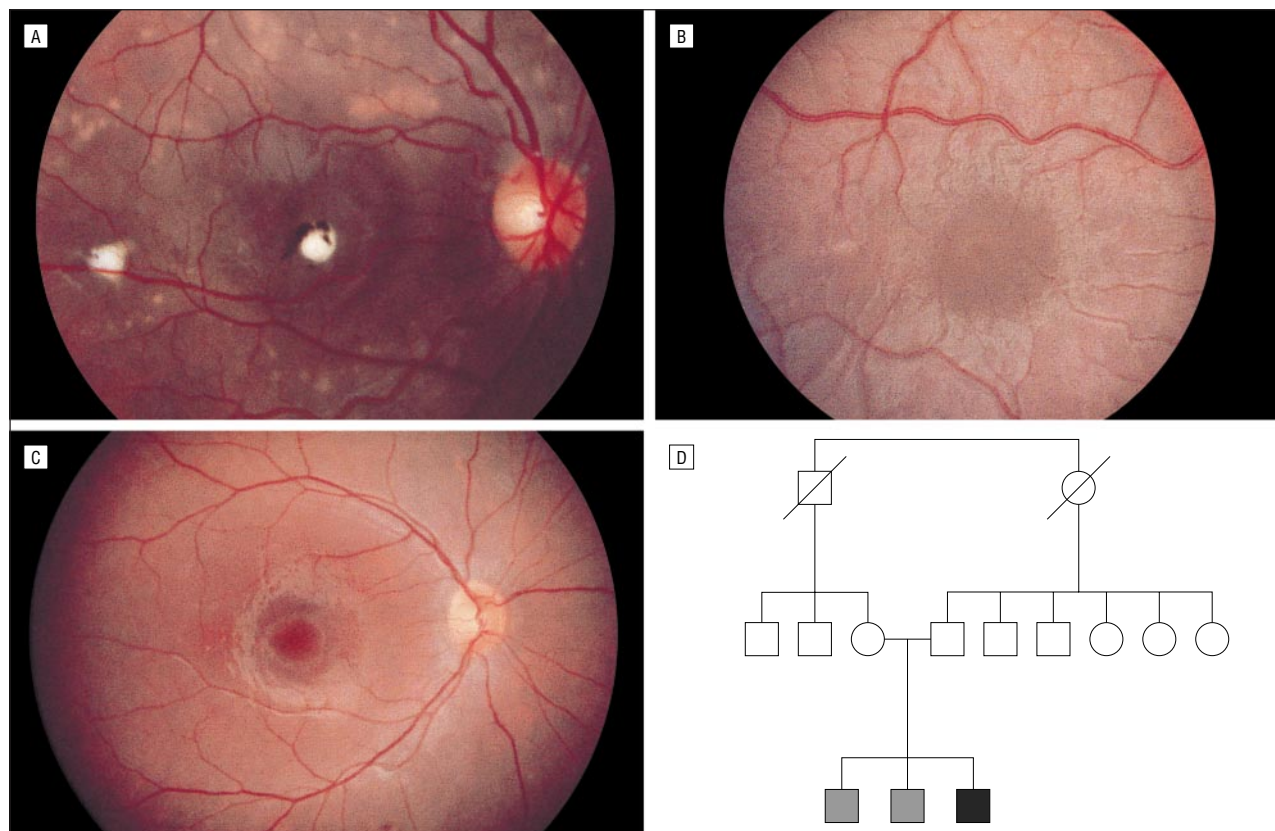


Figure 1. A Jordanian family with mutations in 2 genes. A, The eldest brother has a homozygous bestrophin mutation. B, The middle brother is heterozygous for the same bestrophin mutation. C, The youngest brother is homozygous for an RPE65 mutation and the same bestrophin mutation. D, Family pedigree. The elder brothers are shaded gray; the youngest, black.

found to be abnormal in all 4 individuals: father, 1.4 OD, 1.3 OS; mother, 1.5 OD, 1.2 OS; eldest brother, 1.0 OD, 1.0 OS; and middle brother, 1.3 OD, 1.6 OS. The clinical and electrophysiologic findings suggested that the parents and the elder brothers might be affected with a mild form of Best disease and that the LCA phenotype in the youngest brother might be due to 2 copies of a Best disease allele. However, linkage analysis revealed the middle brother and the youngest brother to have the same haplotypes at the Best locus, which ruled out this explanation.

The discovery of the Best disease gene (*VMD2*)¹³ and the discoveries of 3 genes responsible for some cases of LCA allowed the findings in this family to be studied at the gene level. This family was screened for mutations in the *VMD2*, *RPE65*, *CRX*, and *GUCY2D* genes. The parents were found to be heterozygous for a bestrophin mutation (Gly222Val) and an *RPE65* mutation (Glu462stop). The eldest brother was found to be homozygous for the *VMD2* mutation (Gly222Val), while the middle brother was found to be heterozygous for this same mutation. The youngest brother was found to be homozygous for an *RPE65* mutation (Glu462stop) and the Gly222Val *VMD2* mutation (Figure 1, D).

One hundred ten instances of 35 different coding sequence variations were observed in this study. Of these, 19 were judged to be probable disease-causing mutations because they: (1) would be expected to alter the amino acid sequence of the proteins encoded by the *CRX*, *GUCY2D*, or *RPE65* gene in a nonconservative fashion;

(2) were present in 1 or more patients with LCA; and (3) were not present in control individuals. These are the same criteria used in similar studies.^{14,15} Four additional sequence variations were identified as possible disease-causing mutations for the same reasons except that the amino acid alterations were conservative. Of the 176 probands, 28 (15.9%) were found to harbor at least 1 of these probable or possible disease-causing mutations. The relative contribution of each gene to the total number of mutations was as follows: *CRX*, 2.8%; *GUCY2D*, 6.3%; and *RPE65*, 6.8%. Nonconservative changes were found in 5 of 5 patients with *CRX*, 8 of 11 patients with *GUCY2D*, and 10 of 12 patients with *RPE65* gene mutations. Two mutations (presumably in different alleles) were found in 0 of 5 patients with *CRX* mutations, 2 of 11 patients with *GUCY2D* mutations, and 7 of 12 patients with *RPE65* mutations. Thus, evidence for 2 abnormal alleles was found in 9 (32%) of the probands who harbored probable or possible disease-causing mutations (Table 1). Four of the sequence variations we observed have been previously reported (Table 1).^{2,5,6,16}

Three of the probands with probable or possible disease-causing sequence variations had an affected sibling available for study. In these families, the mutant alleles segregated as expected for an autosomal recessive disease (Figure 2).

Some clinical details of patients with probable disease-causing mutations are shown in Table 2. The visual acuities of these patients ranged from 20/50 to no

light perception (Table 2). No patients who harbored mutations in 1 of these 3 genes were found to have mental retardation, neurologic abnormalities, developmental delay, or macular colobomas.

COMMENT

The identification of any disease-causing gene has several potential benefits for affected patients, including (1) more accurate diagnosis; (2) more accurate prognosis; (3) insight into the pathophysiological mechanism, which may allow the development of efficacious treatment; (4) the development of novel therapies; and (5) the creation of transgenic animal models, which can be used to evaluate existing or novel therapies relatively quickly. The potential value of molecular diagnosis for patients affected with the clinical phenotype of LCA is well illustrated by the Jordanian family who harbored mutations in the *RPE65* and *VMD2* genes (Figure 1). It would have been virtually impossible to counsel this family based on clinical information alone.

A major challenge for a large mutation screening study such as this one is to determine which of the observed sequence variations are actually responsible for disease. Inference of pathogenicity of an individual sequence change is usually based on a combination of the

following: (1) the relative frequency of an allele in the disease population with respect to a control population; (2) cosegregation with disease within families; and (3) specific features of the mutation itself, including the degree to which it would be expected to alter the function of the gene's protein product. Although in principle it is possible to apply many of these arguments regardless of the inheritance pattern of the disease, in actual practice, autosomal recessive diseases are more challenging than the other 2 common mendelian inheritance patterns. The reasons for this are numerous and include the following: (1) 2 mutant alleles are present in affected patients with recessive diseases; (2) recessive diseases are frequently caused by loss of function alleles,¹⁷ which include mutations that occur outside the coding sequence; (3) families affected with dominant diseases tend to have a higher proportion of affected individuals, allowing greater testing for segregation of the disease; and (4) heterozygous carriers of recessive disease in the normal population make it more difficult to statistically argue for an allele's pathogenicity based on its absence from the normal population. Most of these difficulties can be overcome if a sufficiently large population affected with the disease can be studied.

Similarly, there are several obstacles to discerning the phenotype associated with autosomal recessive alleles. In dominant diseases and X-linked recessive diseases, only a single mutant allele is present in an affected individual and the phenotype associated with this allele can thus be reasonably ascribed to its presence. In contrast, 2 different alleles are likely to be present in a patient with an autosomal recessive disease from an outbred population. This makes it difficult to discern the contribution that each mutant allele makes to the overall phenotype.

Moreover, since no mutation detection strategy is 100% sensitive, one is not infrequently faced with interpreting apparent heterozygosity in affected patients. For example, *CRX* is known to cause autosomal dominant

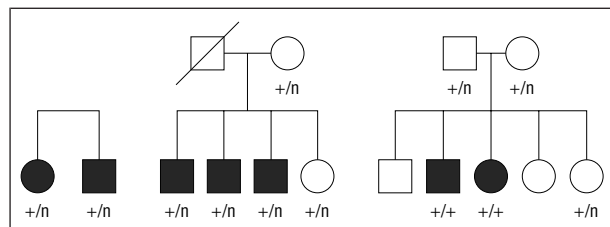


Figure 2. Pedigree drawings from 3 families demonstrating segregation of mutant alleles (+) as expected for an autosomal recessive disease. The normal alleles are signified by an "n." Affected individuals are shaded black.

Table 2. Clinical Details of Patients With Probable Disease-Causing Mutations*

Patient No.	Age, y	Sequence Variation	Gene	Refraction, D		Visual Acuity	
				OD	OS	OD	OS
1	1	Ala56Thr	<i>CRX</i>	5.5	5.5	LP	LP
2	20	2-bp del (ag), codon 168	<i>CRX</i>	-4.4	-4.6	20/800	20/800
3	7	1-bp del (g), codon 217	<i>CRX</i>	-0.5	-0.5	CF	CF
4	9	Arg684Gln	<i>GUCY2D</i>	4.0	4.0	20/1333	20/1333
5	18	10-bp dup, codon 502	<i>GUCY2D</i>	1.5	1.5	NLP	NLP
6	36	1-bp del of (g), codon 46	<i>RPE65</i>	2.0	1.8	20/1125	20/3000
7	16	1-bp ins (t), codon 357, and Ala393Glu	<i>RPE65</i>	-1.6	-1.3	20/600	20/1200
8	7	1-bp ins (t) and Ala393Glu	<i>RPE65</i>	-0.5	-1.0	20/50	20/50
9	37	Ala434Val	<i>RPE65</i>	1.8	2.0	HM	20/400
10	37	Ala434Val	<i>RPE65</i>	3.8	3.4	20/400	20/480
11	38	Ala434Val	<i>RPE65</i>	2.5	2.5	20/200	20/200
12	35	Homozygous 65 +5g→a, splice site	<i>RPE65</i>	1.3	2.3	HM	HM
13	44	65 +5g→a, splice site	<i>RPE65</i>	2.0	3.0	20/4000	20/800
14	7	Homozygous 20-bp del, codon 97	<i>RPE65</i>	0.8	0.8	20/200	20/200
15	2	65 +5g→a, splice site, and 1-bp del (a), codon 298	<i>RPE65</i>	2.0	2.0	LP	LP
16	2	Homozygous Val 287Phe	<i>RPE65</i>	2.0	2.3	CUSM	CUSM
17	14	Homozygous Arg 91 Trp	<i>RPE65</i>	-1.0	-0.5	20/4000	20/4000

*The phenotypes of patients 2 and 3 were previously reported.¹² D indicates diopters; bp, base pair; del, deletion; dup, duplication; ins, insertion; CUSM, central unstable maintained vision; CF, counting fingers; HM, hand movements; LP, light perception; and NLP, no light perception.

and recessive LCA, cone rod dystrophy, and retinitis pigmentosa.^{6,18,19} Mutations in the *GUCY2D* gene have been found in patients with autosomal dominant cone rod dystrophy,²⁰ and mutations in the *RPE65* gene have been associated with autosomal recessive retinitis pigmentosa. Thus, the presence of a single heterozygous sequence change in the *CRX* or *GUCY2D* gene of an isolated patient with a retinal degeneration has at least 4 possible explanations: (1) it may represent a dominant disease-causing allele, (2) it may represent the only detectable member of a pair of recessive disease-causing alleles, (3) it may represent one member of a pair of digenic disease-causing alleles, and (4) it may represent a non-disease-causing polymorphism that has no role at all in the patient's retinal disease.

DIGENIC INHERITANCE, although possible, is unlikely to be involved in a large fraction of LCA cases for the following reasons. Vertical transmission and variable expressivity are rarely reported in LCA pedigrees.⁵ In addition, in the present study, we did not observe a single case of double heterozygosity as might be expected if any 2 of these 3 genes commonly causes disease via a digenic mechanism. The Jordanian family described in this article represents an extraordinary chance occurrence of 2 inherited retinal diseases. This differs significantly from true digenic disease in that the disease phenotype in each of the 3 siblings in the Jordanian family is fully explained by the presence of mutations in only a single gene (*VMD2* in the elder siblings and *RPE65* in the youngest).

In this study, we screened 176 unrelated individuals with the clinical diagnosis of LCA to determine the frequency and type of sequence variations present in 3 genes previously associated with this phenotype. The most striking result is one that has been noted in other studies: most patients affected with LCA do not exhibit coding sequence variations in these 3 genes. Thus, although it is certain that some disease-causing alleles have been missed by our assays, it is also quite likely that additional genes capable of causing the phenotype of LCA must exist. In this study, the median visual acuity of patients with mutations in these 3 genes was 20/2000, with a range from 20/50 to no light perception.

We were able to correlate visual acuity and refraction with the genotype in 17 patients and compare our results with those of previous reports. Leber congenital amaurosis has been associated with hyperopia in several clinical studies²¹⁻²³ and in a genotype-phenotype study.²⁴ In our patients (Table 2), the mean refraction was hyperopic for all 3 genes (*CRX*, +0.2 D; *GUCY2D*, +2.8 D; and *RPE65*, +1.3 D), but the range of refractions was broad (*CRX*, -0.5 to +5.5 D; *GUCY2D*, +1.5 to +4.0 D; and *RPE65*, -1.6 to +3.8 D). Macular colobomas, neurologic abnormalities, and developmental delay have been associated with the diagnosis of LCA. Interestingly, none of the patients who exhibited sequence variations in these 3 genes exhibited any of these clinical features. This suggests that these abnormalities are more commonly associated with other genetic causes of LCA.

In a clinical series²³ of 75 patients in whom LCA was initially diagnosed, it was discovered that misdiagnosis occurred in 30 of these patients. Common revised diagnoses included congenital stationary night blindness, achromatopsia, Joubert syndrome, Zellweger syndrome, and infantile Refsum disease. A 40% clinical misdiagnosis rate illustrates the potential value of molecular diagnosis of this disease.

Thirty-nine of the patients in this study were from India, where the relatively high rate of consanguinity²⁵⁻²⁸ makes it more likely that individuals affected with recessive disease will be homozygous for their mutant allele. The relative paucity of mutations in these 3 genes in the Indian patients suggests that 1 or more additional genes is responsible for a relatively larger fraction of the Indian population with LCA than in western countries. This underscores the need to conduct mutation screens in a global fashion because certain genes may be more easily discovered and characterized in some populations than in others. Moreover, genes that may cause LCA commonly in one country may cause it less commonly but still significantly in another. Study of populations with a higher rate of consanguineous marriages and, hence, a higher frequency of homozygous affected individuals will also allow better recognition of genotype-phenotype relations for specific alleles.

In summary, a sample of 176 families gathered from 9 different countries is sufficient only for a preliminary assignment of pathogenicity of certain alleles and for the most general genotype-phenotype correlations. Nevertheless, molecular diagnosis may be of significant value in counseling the families of some individuals affected with LCA.

Accepted for publication November 19, 1999.

From the Departments of Ophthalmology and Visual Sciences (Drs Lotery, Franklin, and Stone and Mrs Anderson) and Pediatrics (Dr Sheffield), University of Iowa Hospitals and Clinics, Iowa City; Aravind Eye Hospital, Madurai, India (Drs Namperumalsamy and Radha); Department of Ophthalmology, Scheie Eye Institute, Philadelphia, Pa (Dr Jacobson); Department of Ophthalmology and Molecular and Medical Genetics, Casey Eye Institute, Portland, Ore (Dr Weleber); Department of Ophthalmology and Visual Sciences, University of Illinois Eye and Ear Infirmary, Chicago (Dr Fishman); and Departments of Ophthalmology, Long Island College Hospital, New York, NY (Dr Musarella), University of California, San Francisco (Dr Hoyt), the Eye Research Institute of Canada (Dr Héon) and the Hospital for Sick Children (Dr Levin), Toronto, Ontario, the British Columbia Children's Hospital, Vancouver (Dr Jan), Bascom Palmer Eye Institute, Miami, Fla (Dr Lam), and New York University, New York (Dr Carr).

This study was supported in part by grants EY10539 and EY05627 from the National Institutes of Health, Bethesda, Md; the Foundation Fighting Blindness, Hunt Valley, Md; the Grousbeck Family Foundation, San Francisco, Calif; the Carver Charitable Trust, Muscatine, Iowa; the Daniel Matzkin Research Fund; and an unrestricted grant from Research to Prevent Blindness Inc, New York, NY.

We thank William Scott, MD, Douglas Fredrick, MD, Ehud Zamir, MD, Saul Merin, MD, Francis Munier, MD, Arlene Drack, MD, Terry Schwartz, MD, Jean Bennett, MD,

Benedetto Falsini, MD, and Michael Vaphiades, MD, for sharing their patients with us for this study; and Luan Streb, Kim Vandenburg, Christine Taylor, Heidi Haines, Louisa Af-fatigato, Robin Hockey, Gretel Beck, and David B. Hanna for their excellent technical assistance.

Reprints: Edwin M. Stone, MD, PhD, Department of Ophthalmology and Visual Sciences, University of Iowa Hospitals and Clinics, 200 Hawkins Dr, Iowa City, IA 52242 (e-mail: edwin-stone@uiowa.edu).

REFERENCES

1. Flynn JT, Cullen RF. Disc oedema in congenital amaurosis of Leber. *Br J Ophthalmol*. 1975;59:497-502.
2. Morimura H, Fishman GA, Grover SA, Fulton AB, Berson EL, Dryja TP. Mutations in the *RPE65* gene in patients with autosomal recessive retinitis pigmentosa or Leber congenital amaurosis. *Proc Natl Acad Sci U S A*. 1998;95:3088-3093.
3. Margolis S, Scher BM, Carr RE. Macular colobomas in Leber's congenital amaurosis. *Am J Ophthalmol*. 1977;83:27-31.
4. Perrault I, Rozet JM, Calvas P, et al. Retinal-specific guanylate cyclase gene-mutations in Leber's congenital amaurosis. *Nat Genet*. 1996;14:461-464.
5. Marlhens F, Bareil C, Griffon JM, et al. Mutations in *RPE65* cause Leber's congenital amaurosis. *Nat Genet*. 1997;17:139-141.
6. Freund CL, Wang QL, Chen S, et al. De novo mutations in the *CRX* homeobox gene associated with Leber congenital amaurosis. *Nat Genet*. 1998;18:311-312.
7. Lewis CA, Battle IR, Battle KG, et al. Tubby-like protein 1 homozygous splice-site mutation causes early-onset severe retinal degeneration. *Invest Ophthalmol Vis Sci*. 1999;40:2106-2114.
8. Buffone GJ, Darlington GJ. Isolation of DNA from biological specimens without extraction with phenol. *Clin Chem*. 1985;31:164-165.
9. Freund CL, Gregory-Evans CY, Furukawa T, et al. Cone-rod dystrophy due to mutations in a novel photoreceptor-specific homeobox gene (*CRX*) essential for maintenance of the photoreceptor. *Cell*. 1997;91:543-553.
10. Bassam BJ, Caetano-Anolles G, Gresshoff PM. Fast and sensitive silver staining of DNA in polyacrylamide gels. *Anal Biochem*. 1991;196:80-83.
11. Krawczak M, Reiss J, Cooper DN. The mutational spectrum of single base-pair substitutions in mRNA splice junctions of human genes: causes and consequences. *Hum Genet*. 1992;90:41-54.
12. Jacobson SG, Cideciyan AV, Huang Y, et al. Retinal degenerations with truncation mutations in the cone-rod homeobox (*CRX*) gene. *Invest Ophthalmol Vis Sci*. 1998;39:2417-2426.
13. Petrukhin K, Koisti MJ, Bakall B, et al. Identification of the gene responsible for Best macular dystrophy. *Nat Genet*. 1998;19:241-247.
14. Stone EM, Fingert JH, Alward WM, et al. Identification of a gene that causes primary open angle glaucoma. *Science*. 1997;275:668-670.
15. Stone EM, Webster AR, Vandenburg K, et al. Allelic variation in *ABCR* associated with Stargardt disease but not age-related macular degeneration. *Nat Genet*. 1998;20:328-329.
16. Gu SM, Thompson DA, Srikumari CR, et al. Mutations in *RPE65* cause autosomal recessive childhood-onset severe retinal dystrophy. *Nat Genet*. 1997;17:194-197.
17. Strachan T, Read AP. *Human Molecular Genetics*. Oxford, England: BIOS Scientific Publishers Ltd; 1996.
18. Sohocki MM, Sullivan LS, Mintz-Hittner HA, et al. A range of clinical phenotypes associated with mutations in *CRX*, a photoreceptor transcription-factor gene. *Am J Hum Genet*. 1998;63:1307-1315.
19. Swaroop A, Wang QL, Wu W, et al. Leber congenital amaurosis caused by a homozygous mutation (R90W) in the homeodomain of the retinal transcription factor *CRX*: direct evidence for the involvement of *CRX* in the development of photoreceptor function. *Hum Mol Genet*. 1999;8:299-305.
20. Kelsell RE, Gregory-Evans K, Payne AM, et al. Mutations in the retinal guanylate cyclase (*RETGC-1*) gene in dominant cone-rod dystrophy. *Hum Mol Genet*. 1998;7:1179-1184.
21. Dagi LR, Leys MJ, Hansen RM, Fulton AB. Hyperopia in complicated Leber's congenital amaurosis. *Arch Ophthalmol*. 1990;108:709-712.
22. Smith D, Oestreicher J, Musarella MA. Clinical spectrum of Leber's congenital amaurosis in the second to fourth decades of life. *Ophthalmology*. 1990;97:1156-1161.
23. Lambert SR, Kriss A, Taylor D, Coffey R, Pembrey M. Follow-up and diagnostic reappraisal of 75 patients with Leber's congenital amaurosis. *Am J Ophthalmol*. 1989;107:624-631.
24. Perrault I, Rozet JM, Ghazi I, et al. Different functional outcome of *RETGC1* and *RPE65* gene mutations in Leber congenital amaurosis. *Am J Hum Genet*. 1999;64:1225-1228.
25. Badaruddoza, Afzal M, Ali M. Inbreeding effects on the incidence of congenital disorders and fetal growth and development at birth in north India. *Indian Pediatr*. 1998;35:1110-1113.
26. Surender S, Prabakaran B, Khan AG. Mate selection and its impact on female marriage age, pregnancy wastages, and first child survival in Tamil Nadu, India. *Soc Biol*. 1998;45:289-301.
27. Yasim, Naidu JM, Mascie-Taylor CG. Consanguinity and its relationship to differential fertility and mortality in the Kotia: a tribal population of Andhra Pradesh, India. *J Biosoc Sci*. 1997;29:171-180.
28. Reddy PH, Modell B. The Baigas of Madhya Pradesh: a demographic study. *J Biosoc Sci*. 1997;29:19-31.

Correction

Error in Byline and Affiliations. In the article by Friedlander et al titled "Optic Neuropathy Preceding Acute Retinal Necrosis in Acquired Immunodeficiency Syndrome," published in the December 1996 issue of the ARCHIVES (1996;114:1481-1485), the name of the fourth author was misspelled in the byline and the affiliations paragraph on page 1481. In the byline, the fourth author's name should have read as follows: "J. Fernando Arevalo, MD." Likewise, the affiliations paragraph should have read as follows: "From the Departments of Pathology, University of California, San Diego, La Jolla (Drs Friedlander, Rahhal, Ericson, Arevalo, Levi, and Freeman), St Thomas' Hospital, London, England (Drs Hughes and Graham), and University of Pittsburgh, Pittsburgh, Pa (Dr Wiley). Dr Friedlander is now with the Department of Ophthalmology, University of Illinois, Illinois Eye and Ear Infirmary, Chicago." The journal regrets the errors.