

Long-term Effect of Nd:YAG Laser Posterior Capsulotomy on Intraocular Pressure

Jayne Ge, MD; Martin Wand, MD; Robert Chiang, MD;
Augusto Paranhos, MD; M. Bruce Shields, MD

Objective: To study the long-term effect of Nd:YAG capsulotomy on intraocular pressure (IOP).

Methods: We reviewed the records of patients with bilateral pseudophakia who received Nd:YAG capsulotomy in only 1 eye. Using the Wilcoxon rank sum test, we compared the mean change in IOP in eyes before and after capsulotomy with that of the noncapsulotomy eyes at corresponding time intervals. Using multiple regression tests, we analyzed the factors significantly associated with postcapsulotomy long-term IOP increases.

Results: The study included 100 patients who were followed up for a median of 1.5 years after capsulotomy. The mean \pm SD age of the study group was 76 ± 7 years, and 37 patients had glaucoma. The changes in IOP in the

eyes treated with capsulotomy were significantly higher than those in noncapsulotomy eyes at each time interval following capsulotomy. The long-term IOP increase was significantly associated with the IOP increase measured 1 hour after the capsulotomy ($P = .001$). Patients with glaucoma were more likely to require long-term additional glaucoma medication than were nonglaucoma patients to require initial glaucoma therapy after the capsulotomy ($P = .002$).

Conclusion: After Nd:YAG capsulotomy, long-term IOP is often elevated above precapsulotomy baselines, especially in glaucoma patients or patients who experience a significant IOP increase within hours after the capsulotomy.

Arch Ophthalmol. 2000;118:1334-1337

SHORT-TERM increases in intraocular pressure (IOP) after an Nd:YAG laser posterior capsulotomy are well documented.¹⁻⁴ However, we have found only a few published studies that address the intermediate and long-term changes in IOP after capsulotomy.⁵⁻⁷ To further evaluate the long-term influence of capsulotomy on IOP, we retrospectively compared long-term changes in IOP of capsulotomy-treated eyes with untreated fellow eyes of patients with bilateral pseudophakia.

RESULTS

One hundred patients were included in the study, of which 74 were women. The mean \pm SD age was 76 ± 7 years, ranging from 56 to 93 years. In 54 patients, the left eye received the capsulotomy. The **Table** lists the pertinent medical and ocular histories. Hypertension and diabetes were the most prevalent systemic diseases. Thirty-seven patients had glaucoma, 20 of whom had prior argon laser trabeculoplasty, and 1 had prior trabeculectomy. The average

time between cataract extraction and capsulotomy was 24 months, and the median follow-up duration after capsulotomy was 1.5 years, ranging from 1 month to 10 years. The average baseline precapsulotomy IOP of the eyes undergoing capsulotomy, as well as the fellow eyes, was 16.3 mm Hg ($P = .98$). There were also no significant differences associated with the number of glaucoma medications taken preoperatively between the capsulotomy and control eyes of patients with preexisting glaucoma ($P = .21$).

The IOP 1 hour after the capsulotomy was 17.5 mm Hg, significantly higher than the baseline of 16.3 mm Hg ($P = .002$). **Figures 1, 2, and 3** show the IOP changes in the capsulotomy and fellow eyes at each follow-up for the entire group and for the subgroups with and without preexisting glaucoma. For the group as a whole, the average IOP increases in the capsulotomy eyes were significantly larger than those of the fellow eyes at all time intervals after the capsulotomy. An IOP increase of more than 3 mm Hg between the baseline and final IOP was found in 21% of eyes receiving the cap-

From the Department of Ophthalmology and Visual Science, Yale University School of Medicine, New Haven, Conn (Drs Ge, Chiang, Paranhos, and Shields); and the Departments of Ophthalmology, University of Connecticut School of Medicine, Farmington, and Hartford Hospital, Hartford, Conn (Dr Wand).

PATIENTS AND METHODS

We reviewed the medical records of patients with bilateral pseudophakia, with or without glaucoma, who had undergone capsulotomy in 1 eye between January 1985 and December 1997. All laser procedures had been performed by one of us (M.W.). The decision to perform the capsulotomy was based entirely on the severity of the capsular opacification, without consideration of the severity of glaucoma damage in the eyes with preexisting glaucoma. Most patients were premedicated with apraclonidine hydrochloride, tropicamide, and dexamethasone sodium phosphate, and postmedicated with apraclonidine hydrochloride, pilocarpine hydrochloride, and dexamethasone sodium phosphate, and sent home while receiving a mild steroid drop such as fluorometholone acetate for 1 week. Glaucoma patients continued to receive their precapsulotomy medications. Data collected included age, sex, medical history, ocular history, presence or absence of glaucoma, glaucoma medications taken at the time of capsulotomy, history of previous trabeculectomy, time between cataract surgery and capsulotomy, number of laser applications, and total energy used in the procedure. Each patient signed an informed consent form prior to the capsulotomy.

The IOP of both eyes was measured before the capsulotomy, the day of the procedure (both before and 1 hour after), and at specific intervals during the follow-up period. The 2 preoperative IOP measurements were averaged to establish the baseline precapsulotomy pressure. The follow-up period was divided into time intervals: 0 to 1 month, 2 to 3 months, 4 to 6 months, 7 to 12 months, 1 to 2 years, 2 to 3 years, and beyond 3 years. An average IOP was calculated for each time interval. Pressures for both eyes were collected until the last follow-up, until the second

eye underwent capsulotomy, or until either eye required additional pressure-lowering intervention.

Only patients who were followed up longer than 1 month postcapsulotomy were included in the study. Patients excluded were those who had a complicated cataract extraction, had undergone combined cataract extraction and trabeculectomy, or had a history of IOP-altering events such as retinal detachment or prolonged corticosteroid administration.

To compare the IOP changes in all follow-up periods between capsulotomy and noncapsulotomy eyes, a Wilcoxon rank sum test was used, since the distribution of the IOPs was not normal by the Kolmogorov-Smirnov test. A *P* value of .05 was considered statistically significant. The IOP changes were evaluated for the group as a whole, and then for glaucoma and nonglaucoma subgroups. The results of these statistical studies were plotted on line graphs. Multiple regression tests were used to analyze the factors associated with the magnitude of the changes between the baseline and final IOPs. The dependent variable was defined as the difference between the 2 IOP measurements. The independent variables were as follows: patient age, total energy used in the capsulotomy, presence or absence of glaucoma, previous trabeculectomy, use of glaucoma medications, baseline IOP, IOP 1 hour after the capsulotomy, and the time between cataract extraction and capsulotomy. The requirements for initial glaucoma medication for patients without preexisting glaucoma and for additional medication for those with preexisting glaucoma were compared using a χ^2 test. The percentage of eyes with an increase in IOP of greater than 3 mm Hg at the final visit was compared between patients with and without preexisting glaucoma using the Fisher exact test. New ocular diagnoses made during the study period and reasons for termination of visits were also recorded.

sulotomy (**Figure 4**). **Figure 5** shows the time at which the increase in IOP took place after the capsulotomy, and the steady increase in IOP from that point.

Multiple regression tests suggest that the IOP 1 hour after the capsulotomy was the only independent variable that was significantly associated with the IOP change between the baseline and final measurements. Simple linear regression evaluating this influence returned a power of 0.328 and a *P* value of .001. All other independent variables tested were not significantly associated with long-term increases in IOP after capsulotomy.

Seventeen capsulotomy eyes (17%) required either initiation of or additional glaucoma medications during the follow-up period, while only 1 noncapsulotomy eye (1%) required additional glaucoma medication. Four (6%) of the 63 eyes without preexisting glaucoma required initial glaucoma medication, and 13 (35%) of 37 eyes with preexisting glaucoma required initial or additional glaucoma medications (*P* = .002). Of those patients whose final IOP was greater than 3 mm Hg above baseline, 10 had preexisting glaucoma and 8 did not (*P* = .14).

COMMENT

A review of the literature revealed several studies that addressed IOP changes after Nd:YAG capsulotomy. In a US

Medical and Ocular History*

	No. of Patients
Medical history	
Diabetes	9
Hypertension	25
None	38
Ocular history	
POAG	35
CACG	2
Prior ALT	20
Prior trabeculectomy	1
Glaucoma medications (precapsulotomy)	
Bilateral	25
Unilateral	2
None	73

*POAG indicates primary open-angle glaucoma; CACG, chronic angle-closure glaucoma; and ALT, argon laser trabeculectomy.

Food and Drug Administration report of 2110 Nd:YAG capsulotomies, the major postoperative complication was elevation of IOP.¹ The maximum IOP increase occurred between 1.5 and 4 hours, and usually returned to baseline within 24 hours after treatment. Between the third and sixth month after laser treatment, 1% of the patients had persistent elevation of pressure. Steinert et al⁸

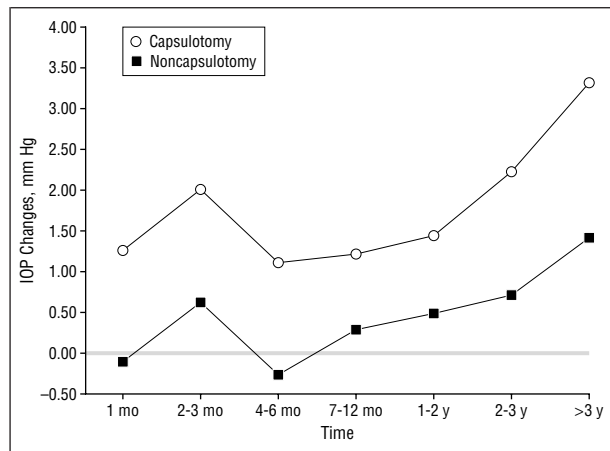


Figure 1. Both groups: Intraocular pressure (IOP) changes compared with baseline precapsulotomy IOPs at intervals after capsulotomy in the capsulotomy and fellow noncapsulotomy eyes.

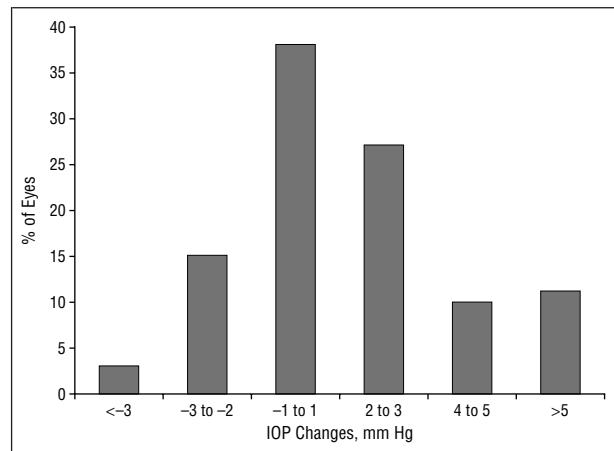


Figure 4. Stratification based on the magnitude of change in final intraocular pressure (IOP) compared with baseline precapsulotomy IOPs.

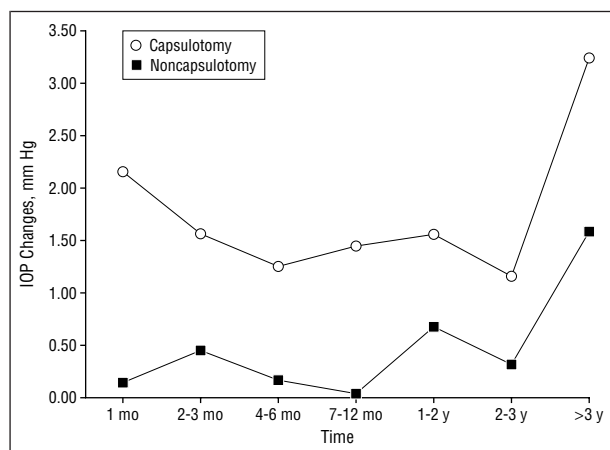


Figure 2. Glaucoma group: Intraocular pressure (IOP) changes compared with baseline precapsulotomy IOPs at intervals after capsulotomy in the capsulotomy and fellow noncapsulotomy eyes.

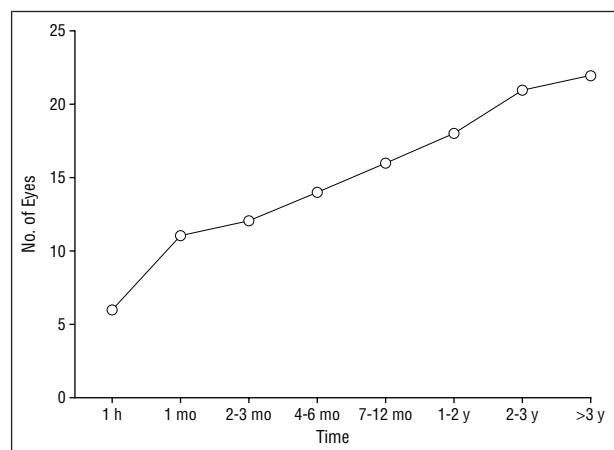


Figure 5. Cumulative postcapsulotomy follow-up intervals showing the number of eyes with an increase of more than 3 mm Hg from the baseline precapsulotomy IOP over time.

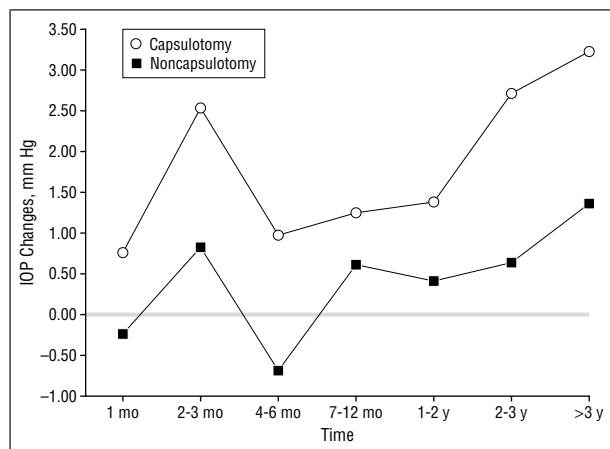


Figure 3. Nonglaucoma group: Intraocular pressure (IOP) changes compared with baseline precapsulotomy IOPs at intervals after capsulotomy in the capsulotomy and fellow noncapsulotomy eyes.

estimated an incidence of glaucoma developing in 1% to 6% of patients after capsulotomy.

Leys et al⁵ studied 67 eyes of 65 patients for 2 months after capsulotomy and documented a statistically signifi-

cant decrease in IOP compared with the precapsulotomy IOP. Fourman et al⁶ compared the IOP of 209 pseudophakic eyes without capsulotomy with 237 pseudophakic eyes with capsulotomy, studied them for approximately 3 years, and found that a late-onset rise in IOP was significantly more frequent in the group with capsulotomy. Jahn et al⁷ studied 150 patients who were unilaterally pseudophakic. They found that the 75 patients who were treated with Nd:YAG capsulotomy had an average increase in IOP of 2 mm Hg compared with the 75 untreated patients at an average follow-up of 28 months. However, their study specifically excluded patients with glaucoma, and used separate treatment and control groups. Our study included patients with preexisting glaucoma and used the fellow eyes of the treated patients as controls.

We found a significant and sustained elevation of IOP after Nd:YAG laser posterior capsulotomy that lasted for up to 3 years or more. The difference between baseline and final IOP was significantly associated with the IOP measured 1 hour after the capsulotomy. Seventeen percent of patients required initiation of or additional pressure-lowering medications after the capsulotomy. Glaucoma patients were more likely to require initial or ad-

ditional glaucoma medications for long-term IOP control after capsulotomy than were nonglaucomatous patients to require initial glaucoma therapy.

A few studies in the literature have examined the short-term IOP changes after Nd:YAG capsulotomy in glaucomatous vs nonglaucomatous eyes. Flohr et al³ found that a short-term IOP elevation after capsulotomy was more common in glaucomatous than in nonglaucomatous eyes, while Slomovic et al⁴ found just the opposite. The latter study suggested that in patients with no prior history of glaucoma, the use of prophylactic antiglaucoma medications was not indicated, since the IOP elevation within the first 24 hours appeared to be a self-limited process in most cases, and the use of medications may have masked a sustained or late-onset IOP elevation. Although multiple regression analysis in our study did not show an association between preexisting glaucoma and long-term postcapsulotomy pressure elevation, the glaucomatous eyes required more pressure-lowering medications than the nonglaucomatous eyes. We attribute this discrepancy to the lower threshold for treating patients with preexisting glaucoma, most of whom already had compromised optic nerve heads. In any case, we believe that eyes with preexisting glaucoma should be monitored with extra caution after capsulotomy.

Of the risk factors that we studied, the long-term IOP increase in our study was significantly related to only the IOP measurement 1 hour after the capsulotomy. It is, therefore, important to observe those patients with a short-term IOP rise more closely for longer periods of time to prevent optic nerve damage from persistent IOP elevation.

In summary, Nd:YAG capsulotomy can cause sustained increases in IOP, especially in patients with preexisting glaucoma and with early postcapsulotomy IOP elevation. Careful, long-term follow-up of IOP and appropriate treatment are important in the postoperative management of these patients.

Accepted for publication March 27, 2000.

Corresponding author: Martin Wand, MD, Consulting Ophthalmologists, 85 Seymour St, Hartford, CT 06106 (e-mail: nodhilwand@aol.com).

REFERENCES

1. Stark JW, Worthen D, Holladay JT, Murray G. Neodymium:YAG lasers: an FDA report. *Ophthalmology*. 1985;92:209-212.
2. Channell MM, Beckman H. Intraocular pressure changes after neodymium-YAG laser posterior capsulotomy. *Arch Ophthalmol*. 1984;102:1024-1026.
3. Flohr MJ, Robin AL, Kelley JS. Early complications following Q-switched neodymium:YAG laser posterior capsulotomy. *Ophthalmology*. 1985;92:360-363.
4. Slomovic AR, Parrish RK. Acute elevations of intraocular pressure following Nd:YAG laser posterior capsulotomy. *Ophthalmology*. 1985;92:973-976.
5. Leys M, Pameijer JH, deJong P. Intermediate-term changes in intraocular pressure after Neodymium-YAG laser posterior capsulotomy. *Am J Ophthalmol*. 1985;100:332-333.
6. Fourman S, Apisson J. Late-onset elevation in intraocular pressure after Neodymium-YAG laser posterior capsulotomy. *Arch Ophthalmol*. 1991;109:511-513.
7. Jahn C, Emke M. Long-term elevation of intraocular pressure after Nd:YAG laser posterior capsulotomy. *Ophthalmologica*. 1996;210:85-89.
8. Steinert RF, Puliafito CA, Kumar SR, Dudak SD, Patel S. Cystoid macular edema, retinal detachment, and glaucoma after Nd:YAG laser posterior capsulotomy. *Am J Ophthalmol*. 1991;112:373-380.