

# A New Lamellar Wound Configuration for Penetrating Keratoplasty Surgery

Massimo Busin, MD

A modified penetrating keratoplasty procedure with a new lamellar configuration of the surgical wound was performed on 8 eyes with endothelial decompensation. This technique allows complete suture removal by 3 months postoperatively, substantially shortening the time necessary for visual rehabilitation. Refractive astigmatism before and after suture removal was minimized to 4 diopters or less in all of the eyes in our preliminary series. Because the anterior surface of the donor button is smaller than the posterior one (diameter, 7.0 mm and 9.0 mm, respectively), more endothelial cells can be transplanted while maintaining the anterior graft surface at a safe distance from the corneoscleral limbus. Finally, no expensive instrumentation is required for this procedure except for an artificial anterior chamber if whole globes are not available. The surgical technique and clinical results are presented in this article.

*Arch Ophthalmol.* 2003;121:260-265

During the past decades, penetrating keratoplasty (PK) surgery has undergone continuous refinement. Various instruments have been developed to improve the quality of trephination in both donor and recipient corneas, and countless suturing techniques have been used to reduce tissue distortion and minimize postoperative refractive errors.<sup>1-9</sup> Nevertheless, to date, the basic concept of cutting a donor disc with a “perfect” margin to fit into a “perfect” hole has remained the same. This method produces a vertical, edge-to-edge PK wound. Regardless of how perfectly the donor and recipient cornea fit, this type of wound requires relatively tight sutures to hold the edges together until the healing is sufficient to withstand the effect of the intraocular pressure; this usually takes at least 1 year.

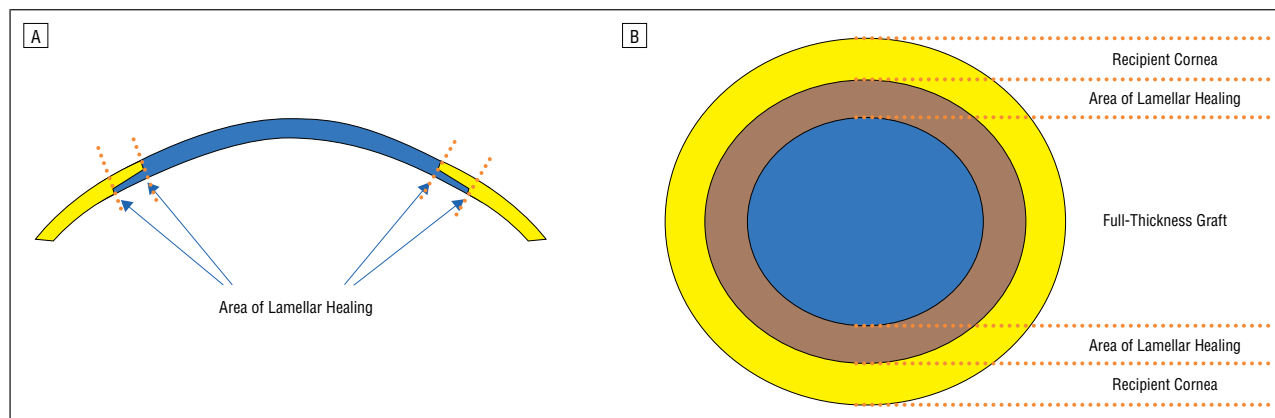
Because of this approach, refraction is not stable, and astigmatism (often of the irregular type) cannot be adequately corrected in many patients as long as the sutures are present.<sup>1-9</sup> In addition, when the sutures are removed, substantial changes in refraction are frequently seen, possi-

bly resulting in anisometropia and/or high-degree astigmatism.<sup>10-14</sup> Finally, wound dehiscence occurs after suture removal in up to 4% of cases, even if this is done more than 1 year after surgery.<sup>15-18</sup>

In recent years, different types of lamellar keratoplasty (LK) procedures have gained popularity among corneal surgeons in an attempt to transplant selected layers of the cornea, speeding wound healing while optimizing postoperative refraction.<sup>19,20</sup> With these methods a horizontal, surface-to-surface surgical wound results, and the intraocular pressure tends to make the layers adhere to each other rather than gape. Tight suturing is not necessary, and removal can safely be performed much earlier than after conventional PK surgery. However, the presence of a lamellar tissue interface may reduce the quality of vision after LK compared with that obtained following PK surgery.

To combine the optical superiority of PK with the wound-healing advantages of LK, the standard PK technique was modified by using a full-thickness donor graft in conjunction with a peripheral lamellar wound configuration (**Figure 1**). The surgical technique and the results obtained in 8 eyes of 8 patients with endothelial decompensation are presented in this article.

From the Departments of Ophthalmology, Casa di Cura Villa Serena Hospital, Forlì, Italy, and Ospedale S Carlo di Nancy, Rome, Italy.



**Figure 1.** Schematic representation of the cornea after a nut-and-bolt keratoplasty procedure. Both in the cross section (A) and the frontal view (B), the annular area of lamellar healing is outlined between the recipient corneal bed (outside) and the full-thickness part of the graft (inside).

**Table 1. Preoperative Data Collected From Patients Undergoing Modified Penetrating Keratoplasty Surgery**

Patient No.	1	2	3	4	5	6	7	8
Age, y	68	81	94	63	77	78	72	84
Sex	M	M	F	F	M	F	F	F
Preoperative diagnosis	PBK	PBK	PBK	Fuchs dystrophy	PBK	PBK	PBK	ABK
Preoperative visual acuity*	HM	HM	CF	HM	HM	CF	CF	HM

Abbreviations: ABK, aphakic bullous keratopathy; CF, counting fingers; HM, hand motions; PBK, pseudophakic bullous keratopathy.

\*Not improvable because of corneal edema.

## METHODS

The use of a modified PK procedure in 8 consecutive patients with endothelial decompensation (aphakic bullous keratopathy,  $n=1$ ; pseudophakic bullous keratopathy,  $n=6$ ; and Fuchs endothelial corneal dystrophy,  $n=1$ ) is reported. All procedures were performed by the same surgeon (M.B.) between September and November 2001, and the results were evaluated in a prospective study, described as follows.

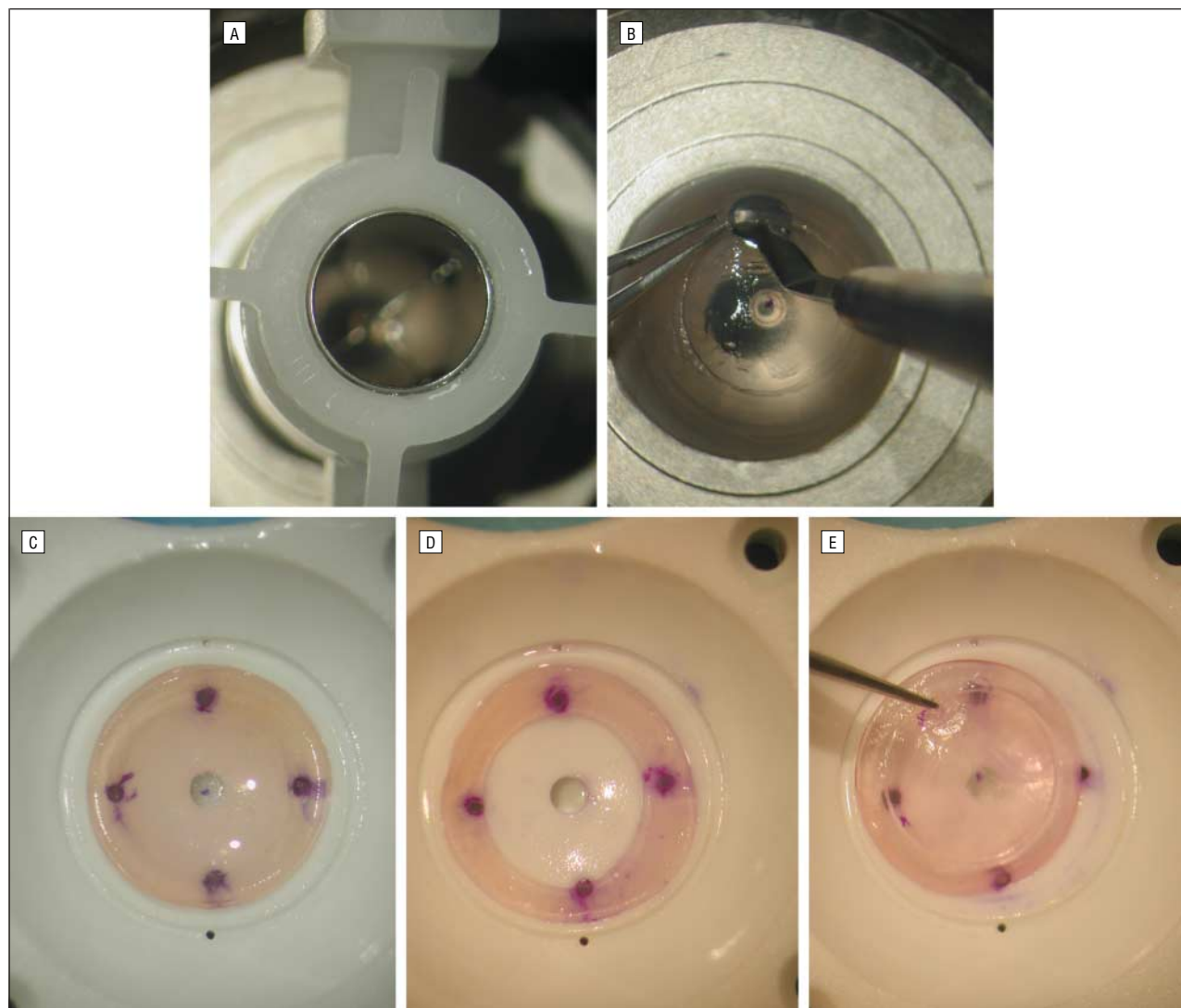
Preoperatively, the medical history of each patient was recorded, and a complete eye examination was performed including visual acuity testing, slitlamp examination, retinoscopy, and B-scan ultrasonography when necessary ( $n=2$ ). Details regarding preoperative data are given in **Table 1**. Postoperatively, patients were seen twice a week until reepithelialization was completed, which occurred within 2 weeks of surgery in all cases. Uncorrected visual acuity was measured every week postoperatively. One month after surgery, patients underwent refraction, and uncorrected and best spectacle-corrected visual acuity were determined. In addition, keratometry and corneal topography analysis were obtained. Monthly examinations were performed thereafter. Sutures were removed 3 months after surgery in all cases. Each patient underwent a repeated complete eye examination 1 month after suture removal.

## Surgical Technique

A detailed consent form was signed by all 8 patients undergoing surgery. All patients were sedated with 3 mL of intravenous droperidol immediately prior to anesthetic injection. Local anesthesia was administered with a peribulbar injection of a mixture of 2% lidocaine and 0.5% bupivacaine hydrochloride.

The donor button was mounted on an artificial anterior chamber (Moria, Paris, France) after a viscoelastic substance was placed on the endothelium. The geometric center of the cornea was marked, and a 7.0-mm Barron suction trephine was used to make a circular, 0.3-mm-deep incision (**Figure 2A**). A lamellar stromal dissection was carried out with a bevel-up knife from the base of the incision all the way to the limbus (**Figure 2B**). Then the cornea was removed from the artificial anterior chamber and placed on the plate of a Barron suction punch with the endothelial side up, taking care to align the mark of the geometric center with the central hole of the punch. A 9.0-mm donor button was punched out (**Figure 2C**). The previous lamellar dissection allowed a superficial annular stromal lamella, 0.3 mm in thickness, to be removed in the area between 7.0 and 9.0 mm in diameter (**Figure 2D**). The donor button obtained this way consisted of a central, full-thickness part, 7.0 mm in diameter, surrounded by a peripheral lamellar wing of deep stroma and endothelium that was 1.0 mm in width

(**Figure 2E**). A McNeill-Goldman ring<sup>21</sup> was used to fixate the globe. The recipient bed was prepared to closely conform to the shape of the donor button. A 7.0-mm Barron suction trephine was used to cut a circular incision 0.3 mm in depth (**Figure 3A**). A lamellar stromal dissection was carried out with a bevel-up knife from the base of the incision about 1 mm peripherally (**Figure 3B**). The anterior chamber was then entered, and corneal scissors were used to complete the excision of the corneal button at the peripheral end of the posterior lamellar stromal dissection (**Figure 3C**). The donor button was positioned by sliding the peripheral wing under the 1.0-mm-wide superficial stromal lip of the recipient bed. Four 10-0 nylon cardinal sutures were put in place. Each suture exited the donor button at the base of the wing and was then passed through the superficial recipient lamellae at the end of the dissection. This way, the wing was left free to adhere to the posterior surface of the dissected recipient cornea, an effect of the intraocular pressure. Contrary to what is typically observed with conventional PK surgery, the injection of balanced salt solution into the anterior chamber showed that the surgical wound was already completely watertight (**Figure 3D**). The procedure was completed with a single 10-0 nylon running suture, each bite of which was passed in a fashion similar to that previously described for the cardinal sutures. Finally, the cardinal sutures were removed (**Figure 3E**). Addi-



**Figure 2.** Preparation of the donor button. A, Partial trephination of the donor cornea mounted on the artificial chamber. B, Lamellar dissection from the base of the incision all the way to the limbus. C, Donor button, 9.0 mm in diameter, with the endothelial side up. D, Superficial annular stromal lamella, 0.3 mm in thickness, removed from the donor button in the area between 7.0 and 9.0 mm of diameter. E, Donor button consisting of a central, full-thickness part, 7.0 mm in diameter, surrounded by a peripheral lamellar wing of deep stroma and endothelium, 1.0 mm in width.

tional procedures performed in combination with PK surgery in this series included anterior vitrectomy (n=4), anterior vitrectomy combined with the exchange of the intraocular lens implant (n=1), anterior vitrectomy combined with intraocular lens implantation (n=1), and pupilloplasty (n=1). After surgery the patients underwent pressure patching overnight. Beginning the next morning, 0.1% dexamethasone sodium phosphate and gentamicin sulfate antibiotic eyedrops were administered every 2 hours and tapered for 10 weeks.

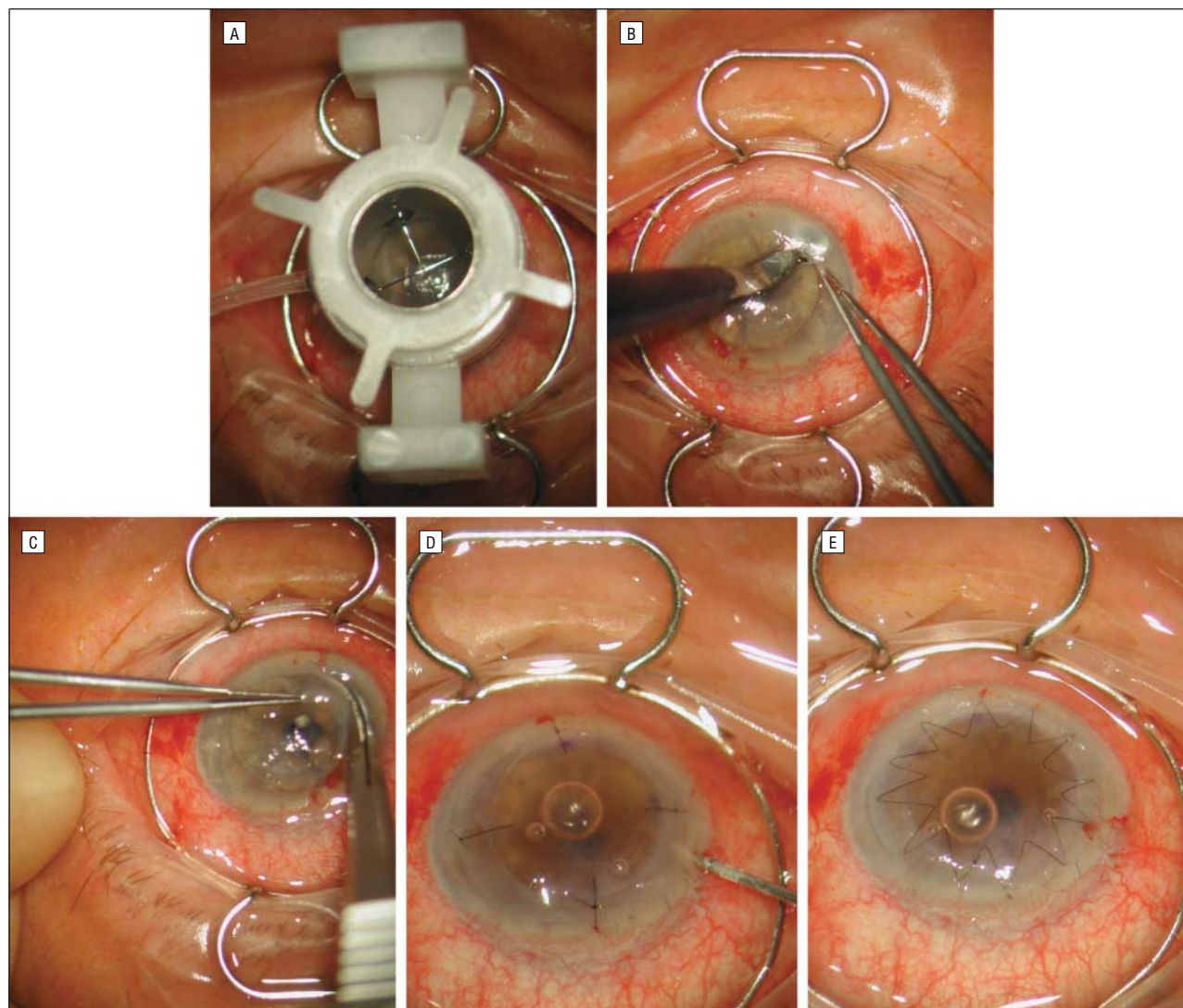
## RESULTS

Surgery was uneventful in all patients. All corneas gradually cleared

with time, and reepithelialization was completed within 2 weeks of surgery. Data recorded preoperatively, 1 month after surgery, and 1 month after suture removal are summarized in Tables 1 to 3. The 10-0 nylon running suture was removed 3 months after surgery in all patients (**Figure 4**). As early as 1 month after surgery (**Table 2**), an uncorrected visual acuity of at least 20/200 in the affected eye was recorded in all but 1 patient (patient 4 in the tables), who had high-degree myopia. Best spectacle-corrected visual acuity ranged between 20/100 and 20/40. One month after suture removal (**Table 3**), both uncorrected and

spectacle best-corrected visual acuity further improved, and 6 of 8 patients could see 20/60 or better with spectacle correction. Reasons for best-corrected vision worse than 20/60 were macular myopic degeneration (patient 4) and cystoid macular edema (patient 8). One month after surgery (**Table 2**), the refractive spherical equivalent ranged from +0.75 diopters (D) to -8.5 D. Mean keratometric readings ranged from 40.5 D to 44.5 D. The refractive astigmatic error was 4 D or less in all cases. Computerized analysis of corneal topography showed regular morphologic characteristics of the astigmatism in all patients at all





**Figure 3.** Main surgical steps of the nut-and-bolt keratoplasty procedure. A, Partial trephination of the recipient bed, 7.0 mm in diameter (same as for the donor cornea) and 0.3 mm in depth. B, Lamellar stromal dissection carried out from the base of the incision about 1 mm peripherally. C, Excision of the corneal button using corneal scissors at the peripheral end of the posterior lamellar stromal dissection. D, Injection of balanced salt solution into the anterior chamber shows that the surgical wound is perfectly watertight with just 4 cardinal sutures in place. E, A single running 10-0 nylon suture is used to complete the procedure.

examination times (**Figure 5**). Surprisingly, suture removal did not substantially affect refraction in any patient (Table 3). Again, refractive astigmatism was 4 D or less in all cases. Notably, the preoperative spectacle cylinder in patient 4 was 4 D.

#### COMMENT

Despite the excellent prognosis of PK, visual rehabilitation of patients undergoing this procedure is slow and frequently hampered by high-degree astigmatism, often of the irregular type.<sup>1-9</sup> Factors including host-graft disparity, trephination technique, and suturing technique are believed to affect the regularity of graft

curvature. In addition, even if all other variables could theoretically be optimized, recovery of vision can be delayed by corneal distortion secondary to the presence of sutures; some degree of tension-induced tissue rolling is necessary to obtain a watertight wound. Healing of these vertical, edge-to-edge corneal wounds requires a minimum of 6 months and typically 1 year in adults. In a relatively high number of patients, stable vision is not achieved until many months after PK surgery, often following suture removal.<sup>1-14</sup>

Lamellar keratoplasty has been proposed in different forms as an alternative surgical treatment for various corneal diseases. Compared with

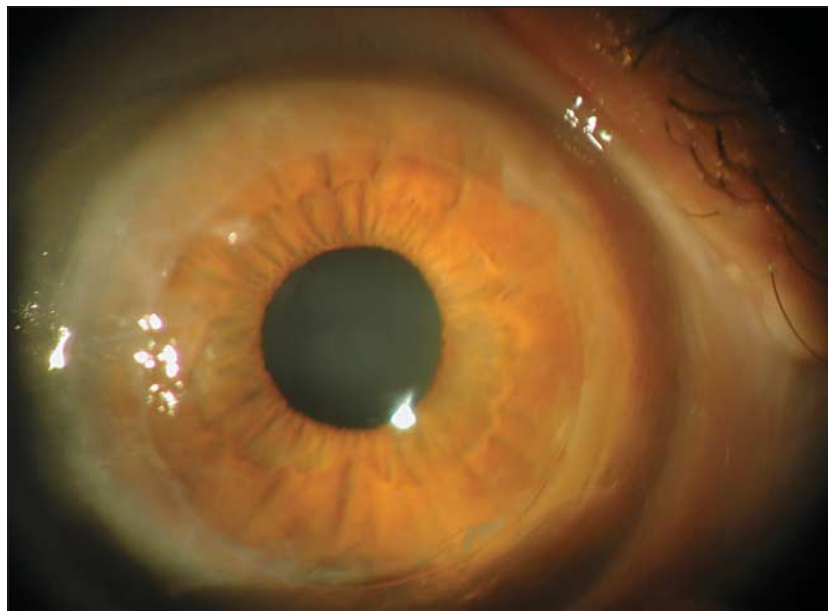
PK, LK offers the substantial advantage of creating a horizontal, surface-to-surface type of surgical wound. Intraocular pressure helps the surfaces adhere to one another, so the sutures require minimal tension and may be removed 2 to 4 months after surgery. To date, however, most of these methods have not gained popularity, mainly because of the lower postoperative optical quality of the cornea. The use of the microkeratome to perform lamellar dissections in laser-assisted in situ keratomileusis has shown that LK can result in postoperative visual acuity of 20/20. We recently published the initial results of endokeratoplasty, a posterior LK procedure aimed at transplanting the posterior stroma and en-

endothelium in decompensated corneas.<sup>20</sup> Although these results are promising, some concern remains for the sudden considerable decrease in intraocular pressure (from more than 60 mm Hg when using the microkeratome to 0 mm Hg after the anterior chamber is entered) during the procedure, as well as the relatively limited amount of transplanted endothelium (the donor button does not exceed 7.0 mm in diameter). In addition, the need for special instrumentation noticeably increases the cost of surgery, and not all surgeons have access to a microkeratome.

The surgical technique described in this article is designed to combine the advantages of PK and LK techniques. For this reason, 2 distinct components are assembled in the donor button, which is shaped like a "reversed mushroom." The central, full-thickness part, 7.0 mm in diameter, maintains the optical advantages of grafts used for conventional PK surgery while remaining confined within a safe distance from the corneoscleral limbus. The peripheral wing of deep stroma and endothelium, 1 mm in width, creates an annular area of lamellar healing

around the full-thickness component. Because both the donor and recipient corneas undergo dissection by hand, the healing process is similar to that in clear-cornea cataract surgery except that the wound is extended for 360° instead of being limited to the area of the tunnel. In this procedure, sutures merely prevent the donor button from sliding out of position. They need not be as tight as when they seal the surgical wound because the intraocular pressure tends to push the healing surfaces together. Our series demonstrated that with this method, it is possible to have a full-thickness graft completely free of sutures as early as 3 months after surgery, thus significantly shortening the time necessary for visual rehabilitation.

The degree of astigmatism recorded both before and after suture removal was low in almost all patients; the only patient with a relatively high value (4 D) had a similar preoperative spectacle correction. Corneal topography (Figure 5) confirmed this data and further supports the favorable comparison with conventional PK surgery. The nut-and-bolt type of fitting obtained between the donor and recipient corneas with our PK modification, as well as the consequent relative laxity of the suturing technique used, may be the main reasons for this finding. However, this wound construction is only one of many possible techniques based on the nut-and-



**Figure 4.** Clinical picture of patient 4 in this series, 1 day after suture removal. The graft is crystal clear in its full-thickness part, surrounded by the hazier annular area of lamellar healing.

**Table 2. Data Collected 1 Month Postoperatively From Patients Undergoing Modified Penetrating Keratoplasty Surgery**

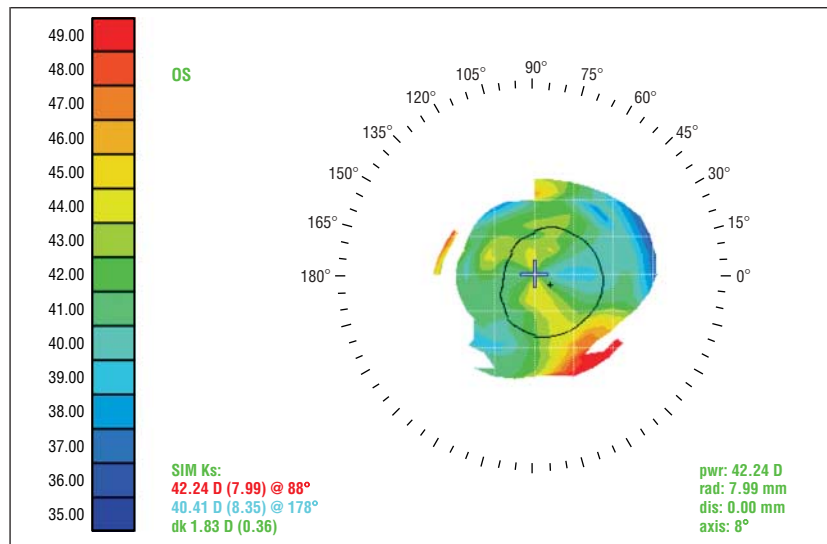
Patient No.	1	2	3	4	5	6	7	8
UCVA	20/200	20/100	20/60	HM	20/100	20/60	20/50	20/200
BCVA	20/60	20/60	20/40	20/200	20/60	20/50	20/40	20/100
Spherical equivalent, D	-1.75	-1.25	-0.5	-8.5	-1.5	+0.75	-0.5	-1.0
Refractive astigmatism, D	2.25	1.5	1.0	4.0	3.0	2.0	1.0	2.75
Mean keratometry reading, D	44.5	43.0	42.5	40.5	41.25	41.0	42.75	42.5

Abbreviations: BCVA, best-corrected visual acuity; D, diopters; HM, hand motions; UCVA, uncorrected visual acuity.

**Table 3. Data Collected 1 Month After Suture Removal From Patients Undergoing Modified Penetrating Keratoplasty Surgery**

Patient No.	1	2	3	4	5	6	7	8
UCVA	20/100	20/200	20/50	HM	20/100	20/60	20/50	20/100
BCVA	20/60	20/60	20/40	20/200	20/40	20/30	20/25	20/100
Spherical equivalent, D	-2.25	-1.5	-0.5	-7.5	-1.75	+1.0	-1.0	-1.0
Refractive astigmatism, D	2.5	1.75	0.75	4.0	3.0	1.5	1.0	2.25
Mean keratometry reading, D	44.75	43.0	43.0	40.5	42.0	41.0	43.0	42.5

Abbreviations: BCVA, best-corrected visual acuity; D, diopters; HM, hand motions; UCVA, uncorrected visual acuity.



**Figure 5.** Computerized analysis of the corneal topography of patient 6 in this series, performed 1 month after suture removal, shows the presence of a low-degree, regular astigmatism.

bolt principle. The diameters of both the full-thickness component and peripheral wing could be varied to achieve different purposes. The former could be cut smaller to reduce the possibility of immunologic rejection through contact with peripheral corneal neovascularization, whereas the latter could be made larger to increase the amount of endothelial cells transplanted. Patients undergoing the procedure described in this article received more of the donor endothelium (surface diameter, 9.0 mm) than patients who receive the conventional PK technique usually do (surface diameter, 7.5-8.5 mm). In contrast, smaller grafts may be used in patients with keratoconus (as little as 5.5 mm for the anterior surface and 7.5 mm for the posterior surface) to leave the reservoir of endothelial cells in the recipient peripheral cornea as large as possible. Also, the dimensional relationship between the 2 components could be modified: a smaller central part with a larger wing could be fitted with even looser sutures or perhaps stabilized with the use of biologic glue, achieving a sutureless PK. Finally, discrepancies between trephination of the donor button and recipient bed may further improve the results compared with those obtained with the present technique. The diameter of the full-thickness part of the donor button, for example, could be slightly smaller than the trephination of the recipient bed; the surgical wound would still be watertight owing to the internal tam-

ponade of the peripheral wing, and scar tissue would fill up the small space between the donor and recipient corneas, thus preventing graft distortion.

In conclusion, our preliminary data show that a lamellar wound construction based on the nut-and-bolt concept may optimize postkeratoplasty refractive error while substantially speeding up visual recovery. To fit specific indications, the amount of endothelium transplanted can be varied by changing the diameter of the posterior surface of the donor button. No expensive or particular instrumentation is needed if whole globes are available, and a relatively inexpensive artificial anterior chamber may be used with excised corneas. Although postoperative follow-up of these patients was relatively short, the data were obtained 1 month after suture removal; no substantial changes in refraction are usually seen after this point with conventional PK surgery. Despite the limited number of patients, the preliminary data suggest that this technique holds great promise. However, the initial positive results obtained in this series require confirmation in a much larger population with a follow-up period of several years.

*Submitted for publication May 2, 2002; final revision received July 11, 2002; accepted August 6, 2002.*

*I thank Stefano Ferrari and Mario Carta from Emmeci Quattro SRL*

(Parma, Italy) for providing equipment essential to carry out this study.

*Corresponding author and reprints: Massimo Busin, MD, Via Sisa 33, 47100 Forlì, Italy (e-mail: mbusin@alinet.it).*

## REFERENCES

- McNeill JI, Kaufman HE. A double running suture technique for keratoplasty: earlier visual rehabilitation. *Ophthalmic Surg.* 1977;8:58-61.
- Davison JA, Bourne WM. Results of penetrating keratoplasty using a double running suture technique. *Arch Ophthalmol.* 1981;99:1591-1595.
- McNeill JI, Wessels IF. Adjustment of single continuous suture to control astigmatism after penetrating keratoplasty. *Refract Corneal Surg.* 1989;5:216-223.
- Musch DC, Meyer RF, Sugar A, Soong HK. Corneal astigmatism after penetrating keratoplasty. *Ophthalmology.* 1989;96:698-703.
- Van Meter WS, Gussler JR, Solomon KD, Wood TO. Postkeratoplasty astigmatism control. *Ophthalmology.* 1991;98:177-183.
- Assil KK, Zarnegar SR, Schanzlin DJ. Visual outcome after penetrating keratoplasty with double continuous or combined interrupted and continuous suture wound closure. *Am J Ophthalmol.* 1992;114:63-71.
- De Molfetta V, Brambilla M, De Casa N, et al. Residual corneal astigmatism after perforating keratoplasty. *Ophthalmologica.* 1980;179:316-321.
- Perlman EM. An analysis and interpretation of refractive errors after penetrating keratoplasty. *Ophthalmology.* 1981;88:39-45.
- Samples JR, Binder PS. Visual acuity, refractive error, and astigmatism following corneal transplantation for pseudophakic bullous keratopathy. *Ophthalmology.* 1985;92:1554-1560.
- Musch DC, Meyer RF, Sugar A. The effect of removing running sutures on astigmatism after penetrating keratoplasty. *Arch Ophthalmol.* 1988;106:488-492.
- Binder PS. The effect of suture removal on postkeratoplasty astigmatism. *Am J Ophthalmol.* 1988;105:637-645.
- Lin DTC, Wilson SE, Reidy JJ, et al. Topographic changes that occur with 10-0 nylon suture removal following keratoplasty. *Refract Corneal Surg.* 1990;6:21-25.
- Mader TH, Yuan R, Lynn MJ, et al. Changes in keratometric astigmatism after suture removal more than one year after penetrating keratoplasty. *Ophthalmology.* 1993;100:119-127.
- Davis EA, Azar DT, Jakobs FM, Stark WJ. Refractive and keratometric results after triple procedure: experience with early and late suture removal. *Ophthalmology.* 1998;105:624-630.
- Binder PS, Abel R, Polack FM, Kaufman HE. Keratoplasty wound separations. *Am J Ophthalmol.* 1975;80:109-115.
- Farley MK, Pettit TH. Traumatic wound dehiscence after penetrating keratoplasty. *Am J Ophthalmol.* 1987;104:44-49.
- Rehany U, Rumelt S. Ocular trauma following penetrating keratoplasty. *Arch Ophthalmol.* 1998;116:1282-1286.
- Tseng SH, Lin SC, Chen FK. Traumatic wound dehiscence after penetrating keratoplasty. *Cornea.* 1999;18:553-558.
- Melles GR, Lander F, Van Dooren BT, Pels E, Beekhuis WH. Preliminary clinical results of posterior lamellar keratoplasty through a sclerocorneal pocket incision. *Ophthalmology.* 2000;107:1850-1856.
- Busin M, Arffa RC, Sebastiani A. Endokeratoplasty as an alternative to penetrating keratoplasty for the surgical treatment of diseased endothelium. *Ophthalmology.* 2000;107:2077-2082.
- Goldman KN, McNeill JI. The McNeill-Goldman ring. *Ophthalmology.* 1978;85:883-884.