Paraffin Embedding Technique for Specimens Obtained by Vitrectomy

Histologic and immunohistochemical preparation of pathologic fluids containing cellular material is difficult, because the techniques are limited by the amount of cellular material. Similar problems limit the preparation of vitrectomized material. Cytopreparatory techniques, including millipore filter and celloidin bag cell block, have been introduced since 1980 for diagnostic vitrectomies.[1,2] These techniques are limited by the fact that the specimens cannot be stained using different histologic and immunohistochemical techniques. A second disadvantage of these techniques is that long-term storage of obtained material for later histologic evaluation is not possible. Direct paraffin embedding of vitrectomized specimens is possible, but specimens with low cell numbers are difficult to prepare.[3,4]

Kawan et al[5] introduced a brush cell block technique for diagnosis of bronchial neoplasms, in which histologic evaluation of the tissue can be performed with a small amount of aspirated cells. Herein, we introduce a modification of the technique by Kawan et al[5] to embed vitrectomized material in paraffin.

Methods. Eyes from 101 patients underwent vitrectomy for different pathologic indications (**Table 1**). The operating technique was similar in all patients.[6] Diluted vitreous material was obtained from the receptacle attached to the aspiration line at the end of a pars plana vitrectomy and then centrifuged at 3000 revolutions per minute for 10 minutes. The collected pellet was mixed with sodium citrate plasma (1:1, Ci-Trol; Dade Behring, Vienna, Austria). Afterward, the same amount of thromboplastin (Thromborel S; Dade Behring) was added to the pellet. The material was then coagulated to a fibrin block and the block centrifuged at 3000 revolutions per minute for 5 minutes and fixed in 10% buffered formaldehyde for 1 hour (**Figure 1**). The block was embedded in paraffin wax with a melting point of 58°C to 60°C (Histosec; Merck, Vienna, Austria). Five-micrometer sectioning was performed. Routine hematoxylin-eosin, periodic acid–Schiff, and Masson trichrome staining was performed in all cases. Depending on the clinical diagnosis, immunohistochemical staining for CD3, CD20, CD45, S100, and HMB45 (**Table 2**) was performed. This latter technique has been previously described.[7]

Table 1. Clinical Diagnoses of the Patients Undergoing Vitrectomy

Clinical Diagnosis	No. (n = 101)
Vitreous hemorrhage due to diabetic retinopathy	56
Retinal detachment	16
Diabetic retinopathy without hemorrhage	11
Uveal melanoma	3
Macular pucker	3
Endophthalmitis	8
Chorioretinitis	4

Figure 1. Vitreous specimen as a fibrin block (arrow) in 10% buffered formaldehyde.

Table 2. Antibodies Used for Immunohistochemical Staining

Antigen*	Pretreatment	Concentration
CD3	EDTA	1:100
CD20	Sodium citrate buffer	1:25
CD45	Trypsin	1:50
S100	Trypsin	1:25
HMB45	Trypsin	1:25

*DakoCytomation Norden A/S, Glostrup, Denmark.

Results. Examples of routine histologic and immunohistochemical staining are shown in **Figures 2**, **3**, **4**, and **5**. Paraffin embedding of vitrectomy material was performed easily in all cases. The tissue may be prepared and sectioned within hours.

Routine histologic examination following hematoxylin-eosin, periodic acid–Schiff, and Masson trichrome staining demonstrated excellent morphologic differentiation of the vitrectomized cells. Immunohistochemical staining showed good staining quality and morphologic delineation. Using the appropriate antibody concentration, background staining was not observed.

Comment. The paraffin embedding technique of vitrectomized material introduced herein is an easy and fast method for paraffin embedding of intraocular fluids, even with a small number of cells. The technique enables ophthalmic pathologists who are not experienced with vitreous samples to handle this material easily.

©2004 American Medical Association. All rights reserved.
Downloaded From: https://jamanetwork.com/ on 02/24/2022

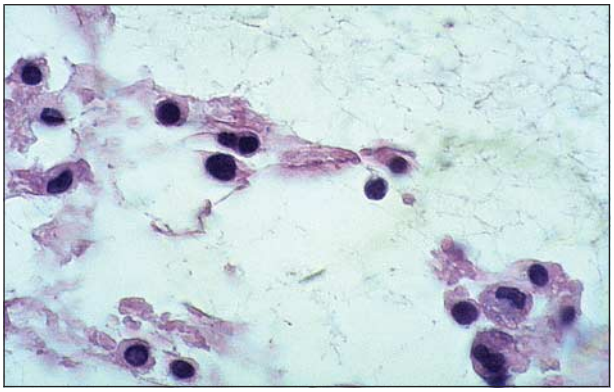

Figure 2. Vitrectomy specimen from a patient with chorioretinitis showing few lymphocytes and neutrophils (hematoxylin-eosin, original magnification ×250).

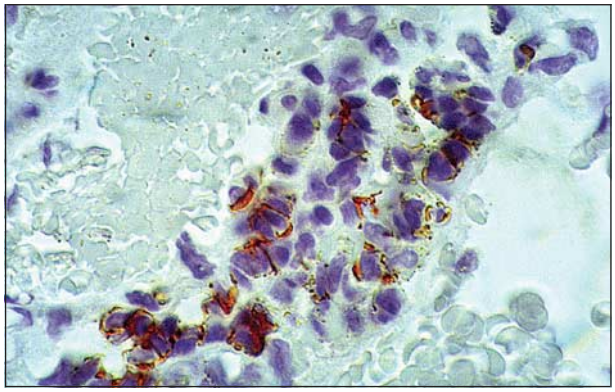

Figure 4. Positive staining of melanoma cells for HMB45 from a patient with uveal melanoma (streptavidin-biotin, original magnification ×250).

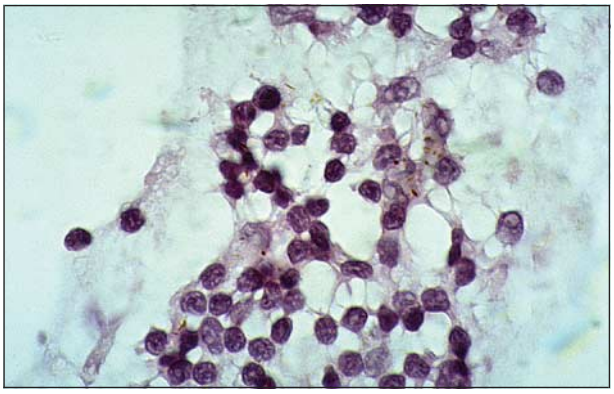

Figure 3. Vitrectomy material from the same patient in Figure 2 showing cells of the nuclear layer of the retina (hematoxylin-eosin, original magnification ×250).

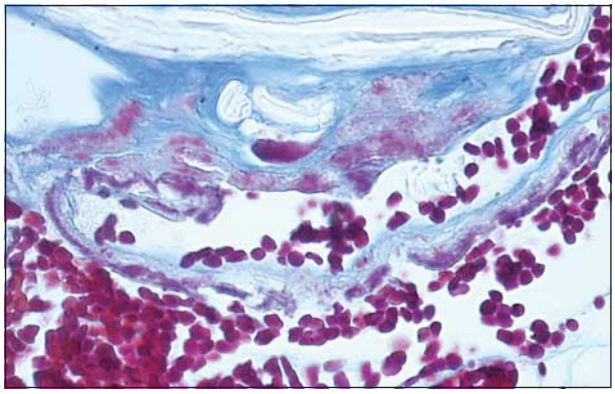

Figure 5. Vitrectomy specimen from a patient with diabetic retinopathy showing erythrocytes and fibrotic tissue (Masson trichrome, original magnification ×100).

In contrast, direct paraffin embedding of vitrectomized specimens requires a large number of cells, as in cases of vitreous hemorrhage, endophthalmitis, or diabetic retinopathy. In these instances, a considerable amount of cells will be lost.[3,4]

Paraffin embedding of vitrectomized intraocular fluids using the fibrin and paraffin method has the following important advantages. Specimens with small numbers of cells from patients with macular pucker or retinal detachment without hemorrhage can be analyzed using all histologic techniques, including immunohistochemical analysis, which is not possible with cytopreparation techniques. The second major advantage is the possibility of archiving specimens for future studies.

Navid Ardjomand, MD
Anna M. Theisl, MTA
Jürgen Faulborn, MD

The authors have no relevant financial interest in this article.

We thank Arthur Fu, MD, Moorfields Eye Hospital, London, England, for critical reading of the manuscript.

Correspondence: Dr Ardjomand, Department of Ophthalmology, Medical University Graz, Auenbruggerplatz 4, 8036 Graz, Austria (navid.ardjomand@meduni-graz.at).

1. Bussolati G. A celloidin bag for the histological preparation of cytologic material. *J Clin Pathol.* 1982;35:574-576.
2. Engel HM, Green WR, Michels RG, Rice TA, Erozan YS. Diagnostic vitrectomy. *Retina.* 1981;1:121-149.
3. Martin F, Pastor JC, Saornil MA, et al. Comparison of different techniques for cytologic analysis of vitreous specimens [in Spanish]. *Arch Soc Esp Oftalmol.* 2001;76:723-730.
4. Rodriguez De La Rua E, Martin F, Saornil MA, Fernandez N, Pastor JC. Efficacy of direct paraffin embedding in cytological analysis of vitreous from proliferative vitreo-retinopathy (PVR) [in Spanish]. *Arch Soc Esp Oftalmol.* 2001;76:655-660.
5. Kawan E, Ulrich W, Redtenbacher S, Schreiber B, Zwick H. Kawan bronchial brush/cell block technique: facilitation of the routine diagnosis of bronchial neoplasms. *Acta Cytol.* 1998;42:1409-1413.
6. Haritoglou C, Gass CA, Schaumberger M, et al. Long-term follow-up after macular hole surgery with internal limiting membrane peeling. *Am J Ophthalmol.* 2002;134:661-666.
7. Ardjomand N, Ardjomand N, Schaffler G, Radner H, El-Shabrawi Y. Expression of somatostatin receptors in uveal melanomas. *Invest Ophthalmol Vis Sci.* 2003;44:980-987.

Pleomorphic Adenoma of the Lacrimal Gland in a Child After Treatment of Acute Lymphoblastic Leukemia

Among all orbital masses in children, tumors and related lesions of the lacrimal gland are very uncommon (1.8%-2.4%). Most of these prove to be nongranulomatous or granulomatous chronic dacryoadenitis, with only a few being neoplasms.[1]

Pleomorphic adenoma (benign mixed tumor) of the lacrimal gland (PALG) is a benign tumor that

©2004 American Medical Association. All rights reserved.
Downloaded From: https://jamanetwork.com/ on 02/24/2022