

# Detection and Quantification of Retinal Nerve Fiber Layer Thickness in Optic Disc Edema Using Stratus OCT

Giacomo Savini, MD; Costantino Bellusci, MD; Michele Carbonelli, MD; Maurizio Zanini, MD; Valerio Carelli, MD, PhD; Alfredo A. Sadun, MD, PhD; Piero Barboni, MD

**Objective:** To investigate the ability of optical coherence tomography (OCT) to assess changes in retinal nerve fiber layer (RNFL) thickness in optic disc edema.

**Methods:** Prospective observational case series in a private eye clinic (Centro Salus). Twelve consecutive eyes (9 patients) with optic disc edema were analyzed, including 6 patients with anterior ischemic optic neuropathy, 1 patient with multiple sclerosis-associated papillitis, and 2 patients with bilateral papilledema. Peripapillary scans of the RNFL were obtained using Stratus OCT (software version 3.0; Carl Zeiss Meditec, Dublin, Calif). Repeated measurements were performed in 7 patients during a follow-up ranging from 8 to 30 weeks. The main outcome was RNFL thickness measurement.

**Results:** Optical coherence tomography detected and quantified diffuse thickening of the RNFL. Compared with eyes in a control group of 75 healthy subjects, eyes with optic disc edema showed a significant increase in the mean RNFL thickness in all quadrants (temporal,  $P = .002$ ; superior,  $P < .001$ ; nasal,  $P < .001$ ; and inferior,  $P < .001$ ). In patients who were followed up, progressive thinning was observed as the disease evolved toward optic atrophy or clinical resolution.

**Conclusions:** Optical coherence tomography can identify and measure RNFL edema. This ability of OCT may help elucidate pathophysiological mechanisms in optic disc edema and provide a valuable aid to clinicians.

*Arch Ophthalmol.* 2006;124:1111-1117

QUANTIFICATION OF THE peripapillary retinal nerve fiber layer (RNFL) thickness can provide clinicians with objective information about the optic nerve in different pathologic conditions. Several imaging techniques can be used to obtain such a measurement; most recently, optical coherence tomography (OCT) has demonstrated several merits. This technology has been used extensively to quantify RNFL thickness in atrophic diseases such as glaucoma, Leber hereditary optic neuropathy, traumatic optic neuropathy, and band atrophy.<sup>1-4</sup> In all of these pathologic conditions, OCT has demonstrated an ability to clearly identify reductions in RNFL thickness; however, few studies<sup>5,6</sup> have used OCT to investigate optic neuropathies in which RNFL thickening occurs due to optic disc edema. Such RNFL thickening has not been fully evaluated or thoroughly defined using other instruments, such as scanning laser polarimetry (SLP) or confocal scanning laser ophthalmoscopy. Results of the only 2 studies<sup>7,8</sup> per-

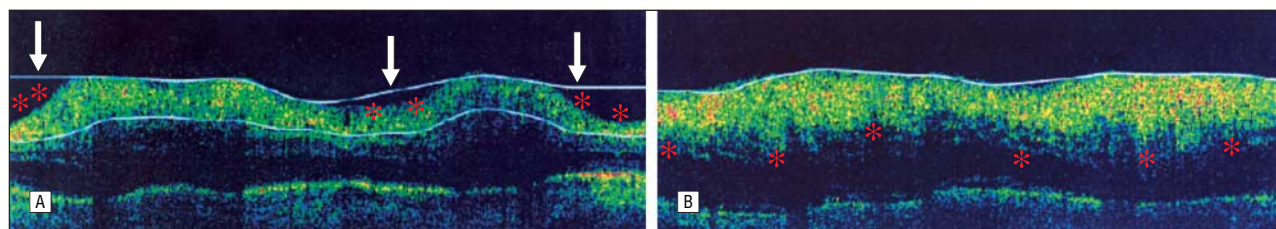
formed using SLP suggest that this technology may, indeed, be unable to detect increases in RNFL thickness during the acute phase of optic neuritis or anterior ischemic optic neuropathy (AION). Conversely, confocal scanning laser ophthalmoscopy has been shown to accurately detect optic nerve changes in papilledema, but investigations using this instrument have focused more on optic disc volume than on RNFL thickness.<sup>9-11</sup>

Quantification of RNFL changes is likely to enhance our knowledge about the pathogenesis and natural history of optic neuropathies that have an RNFL swelling component and may be a useful tool to assess the efficacy of treatments aimed at decreasing RNFL edema. Hence, the main objective of this study was to determine whether OCT is able to identify and measure peripapillary RNFL thickening in patients with optic disc edema arising from different causes.

## METHODS

This was a prospective observational case series study performed in a private eye clinic

**Author Affiliations:** Centro Salus (Drs Savini, Bellusci, Zanini, and Barboni), and Dipartimento di Scienze Neurologiche, Università di Bologna (Dr Carelli), Bologna, Italy; Fondazione G. B. Bietti-IRCCS, Rome, Italy (Dr Carbonelli); and Doheny Eye Institute and Department of Ophthalmology, Keck School of Medicine, University of Southern California, Los Angeles (Dr Sadun).



**Figure 1.** Analysis artifacts caused by Stratus OCT software version 3.0 (Carl Zeiss Meditec, Dublin, Calif). A, Misidentification of the outer profile of the retinal nerve fiber layer (RNFL) (arrows); asterisks indicate the true outer edge of the RNFL. B, Failure to identify the inner edge of the RNFL (asterisks). Data from such images were excluded from the study.

**Table 1. Clinical Features and Retinal Nerve Fiber Layer (RNFL) Thickness in Patients With Optic Disc Edema**

Patient No.	Eye	Disease	Visual Acuity at Presentation	Duration of Follow-up, wk	RNFL Thickness at Presentation, $\mu$ m				
					Mean	Temporal	Superior	Nasal	Inferior
1	OS	NAION	20/32	30	316	118	218	171	324
2	OS	NAION	20/200	25	218	134	257	200	278
3	OS	NAION	20/200	NA	240	140	319	242	254
4	OD	NAION	20/40	8	233	159	282	231	255
5	OS	NAION	20/200	12	198	117	231	197	248
6	OD	NAION	20/40	8	147	136	267	86	99
7	OD	MS-associated papillitis	20/200	30	208	313	238	88	191
8	OD	Papilledema	20/200	30	211	103	283	190	262
9	OD	Papilledema	20/32	12	225	366	182	99	249
	OS	Papilledema	20/20	12	201	99	289	202	209
	OD	Papilledema	20/20	21	177	100	231	144	231
	OS	Papilledema	20/20	21	241	201	310	170	281

Abbreviations: MS, multiple sclerosis; NA, not applicable; NAION, nonarteritic anterior ischemic optic neuropathy.

(Centro Salus, Bologna, Italy). All patients with optic disc edema examined between November 1, 2004, and July 20, 2005, were enrolled in the study; the diagnosis of optic disc edema was obtained by fundus ophthalmoscopy and fluorescein angiography. The only reason for exclusion from the study was the presence of pseudopapilledema, as in the case of optic disc drusen. All participants gave their informed consent according to the Declaration of Helsinki. The study was approved by the internal review board of Centro Salus.

The commercially available OCT3 (Stratus OCT, software version 3.0; Carl Zeiss Meditec Inc, Dublin, Calif) was used to measure peripapillary RNFL thickness. Measurements were made along a circle concentric with the optic disc at a radius of 1.73 mm, using a scanning mode that samples 512 data points (RNFL thickness 3.4 acquisition protocol). Repeated measurements were taken for each eye until at least 1 good image of the RNFL was achieved. Image quality was considered good only if the following criteria were satisfied: the fundus image had to be clear enough to see the optic disc and scan circle, color saturation had to be even and dense across the entire scan, and RNFL edges (as identified by the instrument software) had to correspond to those visually determined by the operator (**Figure 1**).

Patients underwent OCT at the first visit; during a follow-up of 8 to 30 weeks, the examination was repeated in 7 of 9 patients several times according to the individual clinical course. On each occasion, OCT was performed in parallel with a computerized visual field (VF) test (full threshold, 30°, Humphrey field analyzer; Carl Zeiss Meditec Inc).

Retinal nerve fiber layer thickness values of the study population were compared with measurements obtained from a control group of 75 healthy volunteers showing no evidence of optic disc or retinal disease. This control group has been previously described.<sup>1</sup>

Statistical analyses were performed using GraphPad InStat (version 3a for Macintosh; GraphPad Software, San Diego, Calif). An unpaired *t* test was used to calculate the 2-tailed *P* value between the study population and the control group. Values of *P* < .05 were considered statistically significant.

## RESULTS

We examined 12 eyes in 9 patients (6 men and 3 women [mean  $\pm$  SD age, 55.4  $\pm$  19.6 years]) with optic disc edema who had been recruited for the study: 6 patients with AION (unilateral in 5 patients and bilateral in 1 patient), 1 patient with unilateral multiple sclerosis-associated papillitis, and 2 patients with bilateral papilledema (**Table 1**). At initial examination, the mean visual acuity was 20/40 (reference range, 20/200 to 20/20). Using OCT, we were able to visualize a thickened and slightly hyporeflective RNFL in all cases (representative patients 1, 7, and 8 in Table 1 are discussed herein); OCT also correctly identified RNFL boundaries in all eyes. Retinal nerve fiber layer thickness values for each quadrant and the 360° mean measurements are given in Table 1. The mean RNFL thickness was statistically higher in the study group than in the control group in all quadrants and in the 360° mean measurement (**Table 2**).

In addition to RNFL thickening, peripapillary circular OCT scans showed a hyporeflective space above the retinal pigment epithelium (**Figure 2, A**). This space could also be visualized using linear scans crossing the optic nerve head: in this case, the hyporeflective space

**Table 2. Comparison of Retinal Nerve Fiber Layer (RNFL) Thickness in Patients and Control Subjects\***

Group	RNFL Thickness at Presentation, $\mu\text{m}$				
	Mean	Temporal	Superior	Nasal	Inferior
Patients	217.9 $\pm$ 40.9 (191.9-243.9)	165.5 $\pm$ 86.8 (110.3-220.7)	258.9 $\pm$ 40.3 (233.3-284.5)	168.3 $\pm$ 53.4 (134.3-202.3)	240.0 $\pm$ 56.0 (204.4-205.7)
Control subjects	100.8 $\pm$ 12.7 (97.8-103.7)	65.1 $\pm$ 11.8 (62.3-67.8)	126.1 $\pm$ 18.3 (121.8-130.3)	84.9 $\pm$ 17.7 (80.8-89.9)	126.9 $\pm$ 19.5 (122.4-131.3)

\*Data are given as mean  $\pm$  SD (95% confidence interval).  $P = .002$  for the temporal quadrants and  $P < .001$  for the remaining measurements.

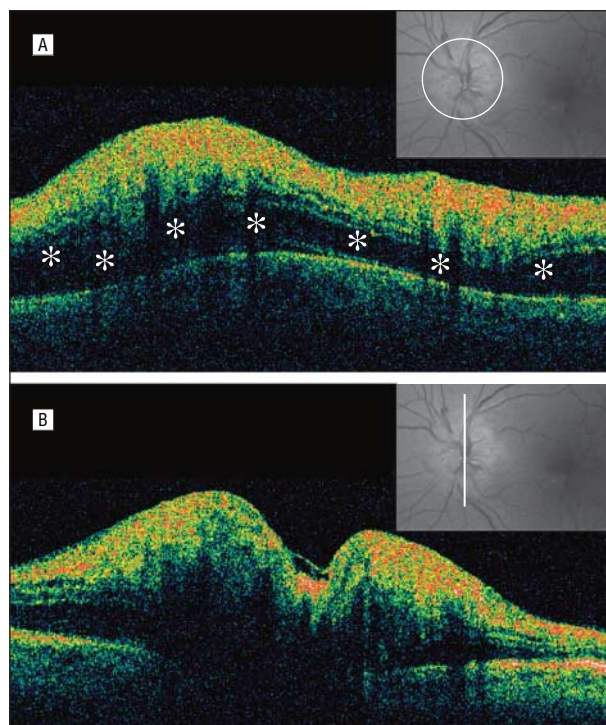
revealed a triangular shape with the apex pointing away from the optic nerve (Figure 2, bottom).

In the 7 patients with adequate follow-up (range, 2-7 months), OCT detected a progressive thinning in the RNFL toward normal or atrophic values. Representative patients 1, 7, and 8 in Table 1 are described in the next section.

### REPORT OF CASES

#### NONARTERITIC AION (PATIENT 1)

A 70-year-old man had a 1-week history of visual loss, which had suddenly occurred in his left eye shortly after awakening. A diagnosis of nonarteritic AION was easily reached as he had already been diagnosed as having nonarteritic AION in the right eye in 1984. The patient was under treatment for hypertension, and on both occasions he experienced visual loss shortly after undergoing heart surgery. Examination of the left eye revealed a visual acuity of 20/32 and a swollen and mildly hyperemic optic disc (**Figure 3**). The clinical history and inflammation markers were not suggestive of giant cell arteritis. Optical coherence tomography visualized diffuse thickening of the RNFL, and the Humphrey VF test showed an altitudinal hemifield defect. Optical coherence tomography also revealed a thickened hyporeflective space between the RNFL and the retinal pigment epithelium. Fluorescein angiography showed diffuse optic disc hyperfluorescence. The Humphrey VF test and OCT were repeated at 2, 3, 4, 6, 8, 12, and 30 weeks after the visual loss onset. Since the first examination, a gradual thinning of the RNFL could be observed in all quadrants. At the 8-week follow-up, the RNFL thickness was slightly lower than that in the control group in each quadrant; subsequent examinations showed further decreases in the RNFL thickness, and the RNFL values at the 30-week follow-up were atrophic not only in the superior sector (which corresponded to the VF area that was affected) but also in the inferior sector of the optic disc (**Figure 4**). This thinning occurred more slowly and to a lesser degree in the inferior quadrant, which showed partial preservation (corresponding to preservation of the superior VF); in the meanwhile, the hyporeflective space disappeared (Figure 3, bottom center). At the last follow-up examination, the visual acuity was 20/25, and the VF test results showed a reduction in the mean defect (10.94 vs 13.56  $\mu\text{m}$ ; Figure 3, bottom right).

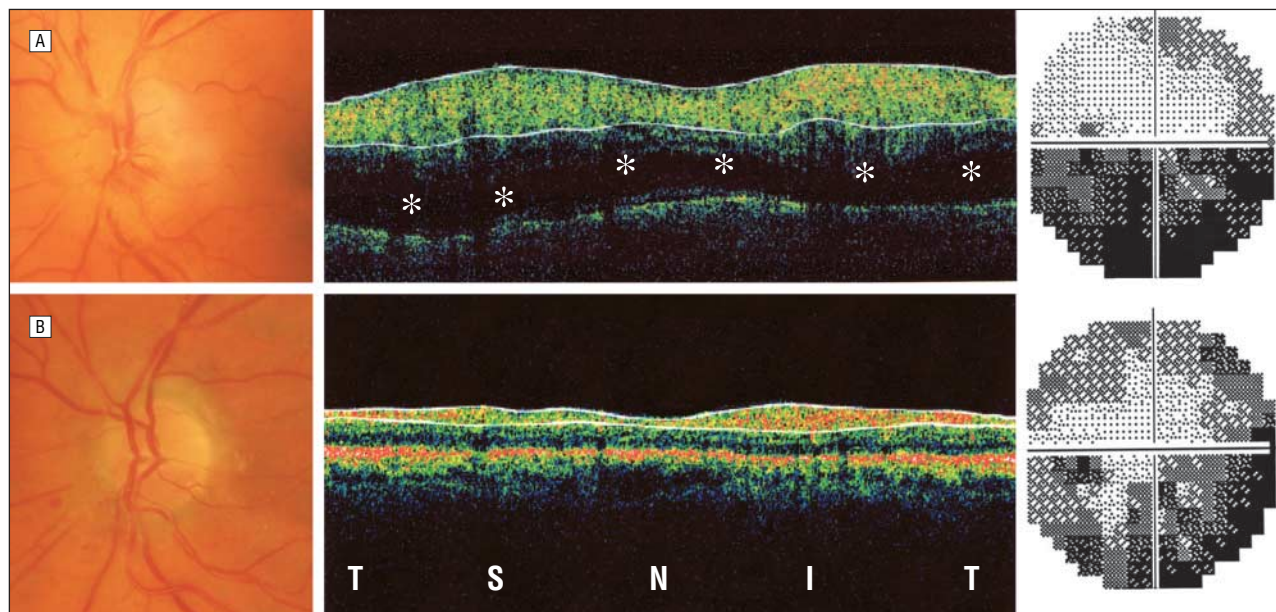


**Figure 2.** Anterior ischemic optic neuropathy. A, Circular peripapillary scan shows a hyporeflective space (asterisks) between the retinal nerve fiber layer (RNFL) and the retinal pigment epithelium. B, Linear scan vertically crossing the optic disc reveals (on both sides of the disc) a triangle-shaped wide hyporeflective space beneath the edematous RNFL. Insets show the corresponding fundus image as viewed through the instrument monitor.

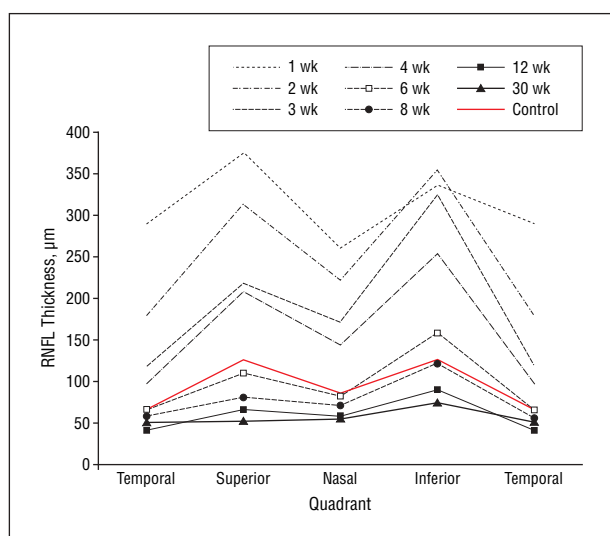
#### MULTIPLE SCLEROSIS-ASSOCIATED PAPILLITIS (PATIENT 7)

A 29-year-old man was referred because of sudden loss of vision in the right eye. The visual acuity was 20/200 OD; an examination of the fundus showed diffuse edema and hyperemia of the optic disc, in which the limits were hard to define (**Figure 5**). A wide defect involving the superior and nasal VFs was observed; OCT revealed diffuse edema of the RNFL in all quadrants and a hyporeflective space between the retinal pigment epithelium and the RNFL, mainly in the superior quadrant. Hyperfluorescence of the optic disc (mainly in the temporal quadrant) was evident on fluorescein angiography. Contrast-enhanced magnetic resonance imaging with gadolinium revealed a localized plaque on the retrolaminar portion of the optic nerve. After a comprehensive workup, including a lumbar puncture, a diagnosis of multiple scler-





**Figure 3.** Nonarteritic anterior ischemic optic neuropathy. A, At initial consultation, the optic disc was swollen (left), Stratus OCT revealed diffuse thickening of the retinal nerve fiber layer (RNFL) and a hyporeflective space (asterisks) between the RNFL and the retinal pigment epithelium (center), and an inferior altitudinal defect is present (right). B, Five months later, the superior half of the optic disc is atrophic (left), the RNFL is diffusely thinned (center), and the perimetric defect (right) shows mild improvement. T indicates temporal; S, superior; N, nasal; and I, inferior.



**Figure 4.** Nonarteritic anterior ischemic optic neuropathy. Progressive thinning toward atrophy can be observed in all quadrants during the follow-up period. Values for the control group were the same as those reported in a previous publication.<sup>1</sup> RNFL indicates retinal nerve fiber layer.

rosis-associated optic neuritis was made. At the last follow-up (30 weeks), the patient had recovered a visual acuity of 20/20 OD, and a small relative scotoma was still evident on the VF examination. Optical coherence tomography demonstrated the RNFLs of the inferior and temporal quadrants to be atrophic.

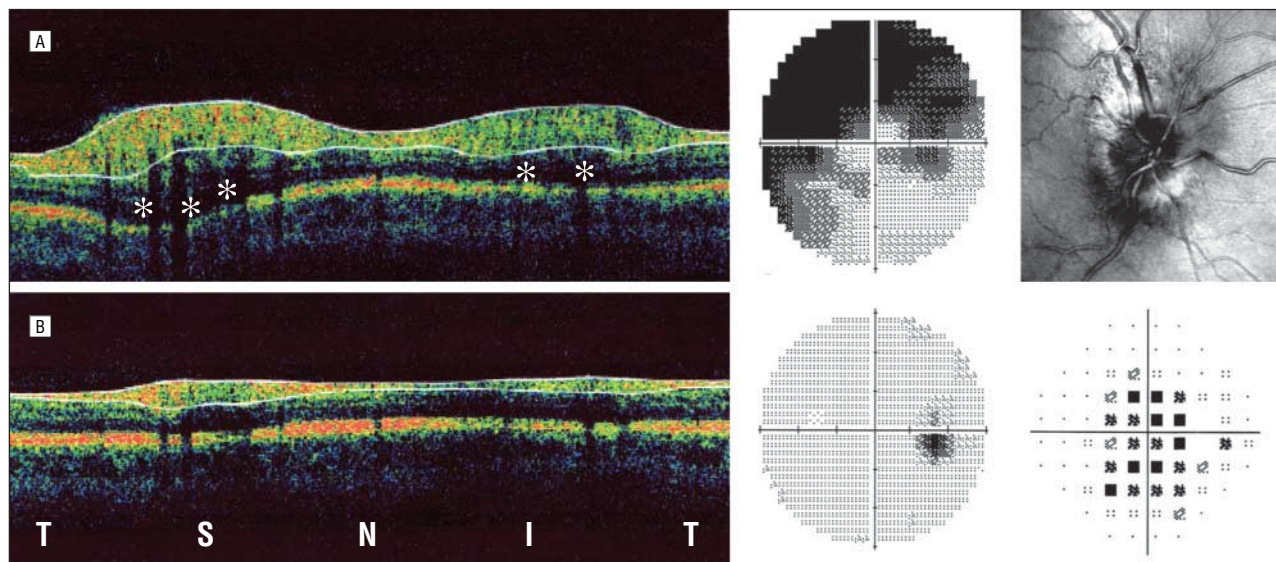
#### BILATERAL PAPILLEDEMA (PATIENT 8)

A 69-year-old man affected with liver carcinoma and multiple metastases was referred because of a 2-week history of progressive visual loss in the right eye. Fundus examination revealed asymmetric bilateral papill-

edema involving the entire optic disc in the right eye and solely the nasal quadrant in the left eye (**Figure 6**); magnetic resonance imaging detected a right cavernous sinus thrombosis. The VF test showed a marked constriction in the right eye and a peripheral superior defect in the left eye; visual acuities were 20/32 OD and 20/20 OS. Retinal nerve fiber layer analysis by OCT revealed diffuse thickening in the right eye and normal values in the left eye. A hyporeflective space under the RNFL was clearly visible in the right eye. Optic disc edema in the right eye was still evident at the 3-week follow-up examination. At 8 weeks, the optic disc appeared atrophic with well-defined edges; on that occasion, the RNFL thickness (as measured by OCT) was below normal values. The optic disc edema in the left eye progressively increased during the first 2 months; as clearly evidenced by serial OCT, RNFL thickening occurred at the superior and inferior poles. At the last examination, the optic disc edema in the left eye had resolved, and the RNFL thickness was within normal limits, but a diffuse peripheral defect of the VF was detected.

#### COMMENT

This case series study shows that OCT may be helpful in the detection, characterization, and monitoring of RNFL swelling in the event of optic disc edema. Observing and documenting changes in RNFL thickness in retinal and optic nerve diseases can be difficult. It was not until 1972 that Hoyt et al<sup>12</sup> demonstrated the efficacy of red-free direct and indirect ophthalmoscopy for visualizing the RNFL. It was subsequently found that nerve fiber layer photographs taken with blue-green light permit a more careful analysis of RNFL swelling



**Figure 5.** Multiple sclerosis-associated papillitis. A, At the first visit, optical coherence tomography shows a thickened retinal nerve fiber layer (RNFL) in all quadrants and a subretinal hyporeflective space (asterisks) (left), a superior defect of the visual field (middle); and diffuse edema in the optic disc (right). B, At the 30-week follow-up, the evolution toward atrophy is confirmed by reduced thickness of the RNFL in the temporal and inferior quadrants (left), the visual field has improved (middle), and only a relative central scotoma persists (right). T indicates temporal; S, superior; N, nasal; and I, inferior.

and thinning.<sup>13</sup> More recently, sophisticated methods such as OCT, SLP, and confocal scanning laser ophthalmoscopy have been developed for this purpose. Most studies have focused, however, on atrophic diseases of the optic nerve that lead to axonal loss and, consequently, RNFL thinning. Only a few attempts have been made to visualize and quantify RNFL thickness when RNFL swelling predominates; using OCT, retinal nerve fiber layer thickening was reported in mild papilledema, in eyes with inflammatory optic neuropathies or retinal vein occlusion, and in asymptomatic carriers of Leber hereditary optic neuropathy mitochondrial DNA mutations.<sup>6,7,14</sup> However, this is the first report, to our knowledge, showing the ability of OCT to identify and quantify RNFL thickening in the case of severe edema of the optic disc, as occurs in AION or in papilledema. Quantification of RNFL edema using this technology may provide a useful objective index for following the clinical course of these diseases. In addition, *in vivo* imaging by OCT may help to elucidate the pathogenesis of optic disc edema in general and these optic neuropathies in particular. The information acquired would be complementary to the data obtained from histopathologic studies, in which collection of large samples is difficult and longitudinal observations are impossible.

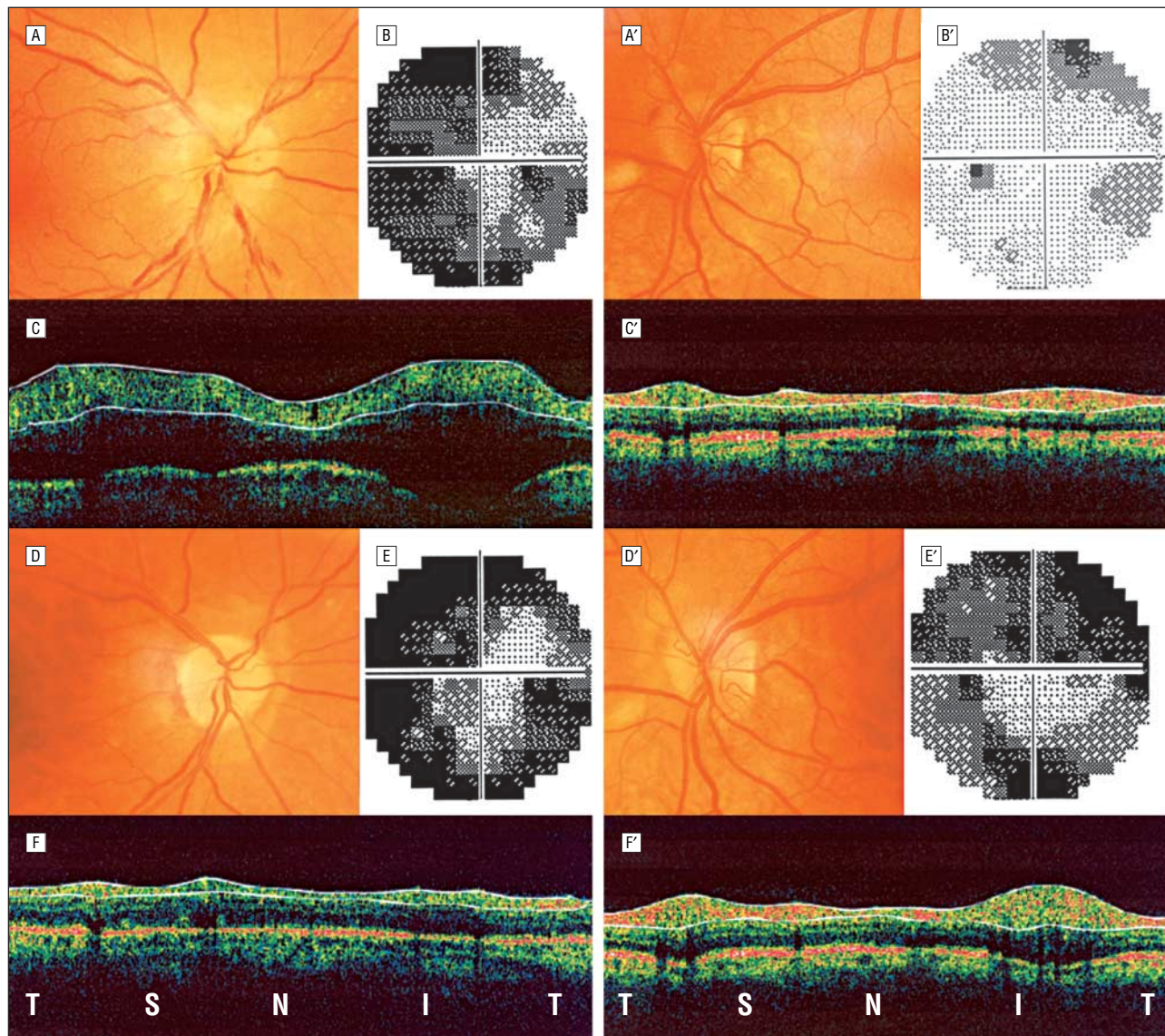
The small sample size of this study does not allow us to generalize our findings to delineate profiles for each of the optic neuropathies that produce optic disc edema. However, we offer a few observations that we believe deserve further attention. Patient 1 went on to show not only resolution of RNFL swelling but also further thinning of the nerve fibers in all quadrants. Although there was a greater degree of thinning in the superior quadrant (which corresponded with the sector of AION involvement and inferior VF loss), loss also occurred in the inferior quadrant. This suggests (1) that in AION there is also damage to the so-called uninvolved sector

(which explains why the entire optic disc swells) and (2) that the residual surviving fibers in the less involved sector are sufficient for an intact VF. This latter observation supports the hypothesis by Quigley and Green<sup>15</sup> that there is sufficient redundancy in the optic nerve to preclude a VF defect until more than 50% of the fibers are lost.

Another unexpected and interesting finding of OCT was common to all of the cases of optic disc edema examined, namely, a hyporeflective subretinal space (possibly representing subretinal fluid) above the retinal pigment epithelium. Meridian scans of the optic nerve disclosed this space as having a triangular shape (Figure 2, bottom). The widest part of the triangle abutted the side of the optic nerve head; the tapered apex pointed away. Although the clinical and pathogenetic significance remains to be explained, there are a couple of intriguing hypotheses. The first hypothesis is that extensive swelling of the optic nerve head pushes the nerve fibers overlying the disc anteriorly, and as these fibers are attached to the RNFL over the retina, they are drawn forward. This produces an upward traction that generates a space below the retina. The resulting hydrostatic force counters the osmotic forces, allowing for fluid accumulation in the unrestricted subretinal space. The second hypothesis is that subretinal fluid accumulates because of increased tissue and venous pressure caused by venous stasis at the level of the optic nerve head; this has been alluded to in previous OCT investigations.<sup>16</sup>

Our findings agree with those of Menke et al,<sup>6</sup> who demonstrated the ability of Stratus OCT to identify peripapillary RNFL thickening in optic disc edema; however, their sample differed from ours because they did not include any case of AION or papilledema but only evaluated eyes with retinal vein occlusion and inflammatory optic neuropathies. This difference is likely to





**Figure 6.** Papilledema. First row, Optic nerve appearance and visual field of the right eye (A and B) and left eye (A' and B') at the first examination, revealing an asymmetric papilledema. Second row, On the same day, Stratus OCT (software version 3.0; Carl Zeiss Meditec, Dublin, Calif) shows diffuse thickening of the retinal nerve fiber layer (RNFL) in the right eye (C) and normal thickness in the left eye (C'). Third row, Two months later, the optic disc is pale in the right eye (D), and the corresponding visual field (E) remains constricted, while in the left eye the superior and inferior poles of the optic disc are mildly hyperemic (D'), and the corresponding visual field shows a lower sensitivity (E'). Fourth row, At the same time, the RNFL is markedly thinned in the right eye (F), and a thickening of the superior and inferior poles is observed in the left eye (F'). T indicates temporal; S, superior; N, nasal; and I, inferior.

account for the higher mean  $\pm$  SD values of RNFL thickness in our study ( $217.9 \pm 40.9$  vs  $122 \pm 23$   $\mu$ m).

As observed by Menke et al,<sup>6</sup> the RNFL thickness measurements obtained using OCT differ considerably from those previously obtained using SLP.<sup>7,8</sup> This discrepancy is probably related to the properties of SLP, which measures form birefringence of the structural elements (neurofilaments and microtubules) within the RNFL and generates the RNFL thickness from such a measurement. Optic disc edema is likely caused not by an increase in the number of neurofilaments and microtubules but rather by intracytoplasmic swelling of ganglion cell axons. The swollen axons are congested with mitochondria, and the microtubules are in disarray.<sup>17</sup> Indeed, this disruption of the alignment of the microtubules within axons has significant implications and likely

decreases their polarization effect, thus giving a false SLP reading of thinning.

The present study has limitations. The small sample size does not allow us to generalize our findings and is insufficient to detect differences among the various types of optic neuropathy producing disc edema as far as RNFL thickening is concerned. Our results must also be evaluated with caution because the reproducibility of RNFL thickness measurements by means of Stratus OCT in the event of optic disc edema has not been formally assessed. Finally, the cases herein were imaged using only OCT (without the use of other technologies such as confocal scanning laser ophthalmoscopy or SLP); hence, any comparison of technologies is premature. These issues can be explored in further studies.

## CONCLUSIONS

The present study illustrates the value of OCT in the assessment of optic disc edema. This is an in vivo quantitative and objective measure that can detect, characterize, and monitor axonal swelling, the core change associated with disc edema. Optical coherence tomography can also be used to follow up the subsequent resolution of axonal swelling and thinning of the RNFL, which are essential aspects of optic atrophy. Future studies using OCT in various optic neuropathies hold the promise of elucidating the reversible and irreversible changes associated with optic disc edema.

**Submitted for Publication:** November 7, 2005; final revision received February 14, 2006; accepted February 19, 2006.

**Correspondence:** Giacomo Savini, MD, Centro Salus, via Saffi 4/H, 40131 Bologna, Italy (giacomo.savini@alice.it).  
**Financial Disclosure:** None reported.

## REFERENCES

1. Barboni P, Savini G, Valentino ML, et al. Retinal nerve fiber layer evaluation by optical coherence tomography in Leber's hereditary optic neuropathy. *Ophthalmology*. 2005;112:120-126.
2. Kanamori A, Nakamura M, Matsui N, et al. Optical coherence tomography detects characteristic retinal nerve fiber layer thickness corresponding to band atrophy of the optic discs. *Ophthalmology*. 2004;111:2278-2283.
3. Medeiros FA, Moura FC, Vessani RM, Susanna R Jr. Axonal loss after traumatic optic neuropathy documented by optical coherence tomography. *Am J Ophthalmol*. 2003;135:406-408.
4. Medeiros FA, Zanfwill LM, Bowd C, Weinreb RN. Comparison of the Gdx VCC scanning laser polarimeter, HRT II confocal scanning laser ophthalmoscope, and Stratus OCT optical coherence tomography for the detection of glaucoma. *Arch Ophthalmol*. 2004;122:827-837.
5. Karam EZ, Hedges TR. Optical coherence tomography of the retinal nerve fibre layer in mild papilloedema and pseudopapilloedema. *Br J Ophthalmol*. 2005;89:294-298.
6. Menke MN, Fekke GT, Trempe CL. OCT measurements in patients with optic disc edema. *Invest Ophthalmol Vis Sci*. 2005;46:3807-3811.
7. Banks MC, Robe-Collignon NJ, Rizzo FJ III, Pasquale LR. Scanning laser polarimetry of edematous and atrophic optic nerve heads. *Arch Ophthalmol*. 2003;121:484-490.
8. Colen TP, van Everdingen JA, Lemij HG. Axonal loss in a patient with anterior ischemic optic neuropathy as measured with scanning laser polarimetry. *Am J Ophthalmol*. 2000;130:847-849.
9. Salgarello T, Falsini B, Tedesco S, Galan ME, Colotto A, Scullica L. Correlation of optic nerve head tomography and visual field sensitivity in papilledema. *Invest Ophthalmol Vis Sci*. 2001;42:1487-1494.
10. Trick GL, Bhatt SS, Dahl D, Skarf B. Optic disc topography in pseudopapilledema: a comparison to pseudotumor cerebri. *J Neuroophthalmol*. 2001;21:240-244.
11. Mulholland DA, Craig JJ, Rankin SJ. Use of scanning laser ophthalmoscopy to monitor papilloedema in idiopathic intracranial hypertension. *Br J Ophthalmol*. 1998;82:1301-1305.
12. Hoyt WF, Rios-Montenegro EN, Behrens MM, Eckelhoff RJ. Homonymous hemioptic hypoplasia: fundoscopic features in standard and red-free illumination in three patients with congenital hemiplegia. *Br J Ophthalmol*. 1972;56:537-545.
13. Sadun AA, Martone JF, Muci-Mendoza R, et al. Epidemic optic neuropathy in Cuba: eye findings. *Arch Ophthalmol*. 1994;112:691-699.
14. Savini G, Barboni P, Valentino ML, et al. Retinal nerve fiber layer evaluation by optical coherence tomography in unaffected carriers with Leber's hereditary optic neuropathy mutations. *Ophthalmology*. 2005;112:127-131.
15. Quigley HA, Green WR. The histology of human glaucoma cupping and optic nerve damage: clinicopathologic correlation in 21 eyes. *Ophthalmology*. 1979;86:1803-1830.
16. Hoye VJ III, Berrocal AM, Hedges TR III, Amaro-Quireza ML. Optical coherence tomography demonstrates subretinal macular edema from papilledema. *Arch Ophthalmol*. 2001;119:1287-1290.
17. Sadun AA. Optic atrophy and papilledema. In: Jakobiec F, Albert D, eds. *Principles of Ophthalmology*. Philadelphia, Pa: WB Saunders Co; 1993:2529-2538.