

RESEARCH LETTERS

Posterior Microphthalmos as a Genetically Heterogeneous Condition That Can Be Allelic to Nanophthalmos

Posterior microphthalmos (PM) is a rare developmental defect in which affected eyes display vitreous chamber foreshortening, normal or nearly normal anterior chamber depth, and papillomacular retinal folds.¹ While membrane-type frizzled-related protein gene (*MFRP* [RefSeq NM_031433]) mutations have been reported to cause severe hyperopia that resembles PM, the resulting phenotype is better characterized as nan-

ophthalmos owing to the involvement of the anterior chamber.^{2,3} Therefore, a genetic cause for PM remains elusive. Herein, we report the molecular analysis of 7 families with PM, which, in addition to narrowing a previously reported locus, establishes for the first time to our knowledge *MFRP* mutations as a cause of PM.

Methods. Human Subjects. Patients were evaluated by 2 of us (S.R.N. and A.O.K.). To qualify, patients had to have an abnormally short axial length of the globe as determined by standardized ultrasonography, normal corneal diameters and anterior segment appearance, high hyperopia, and an abnormal papillomacular retinal fold on ophthalmoscopy. Institutional review board–approved written informed consent was obtained from all patients.

Molecular Studies. Following DNA extraction from whole blood, the Affymetrix 250K SNP Chip platform

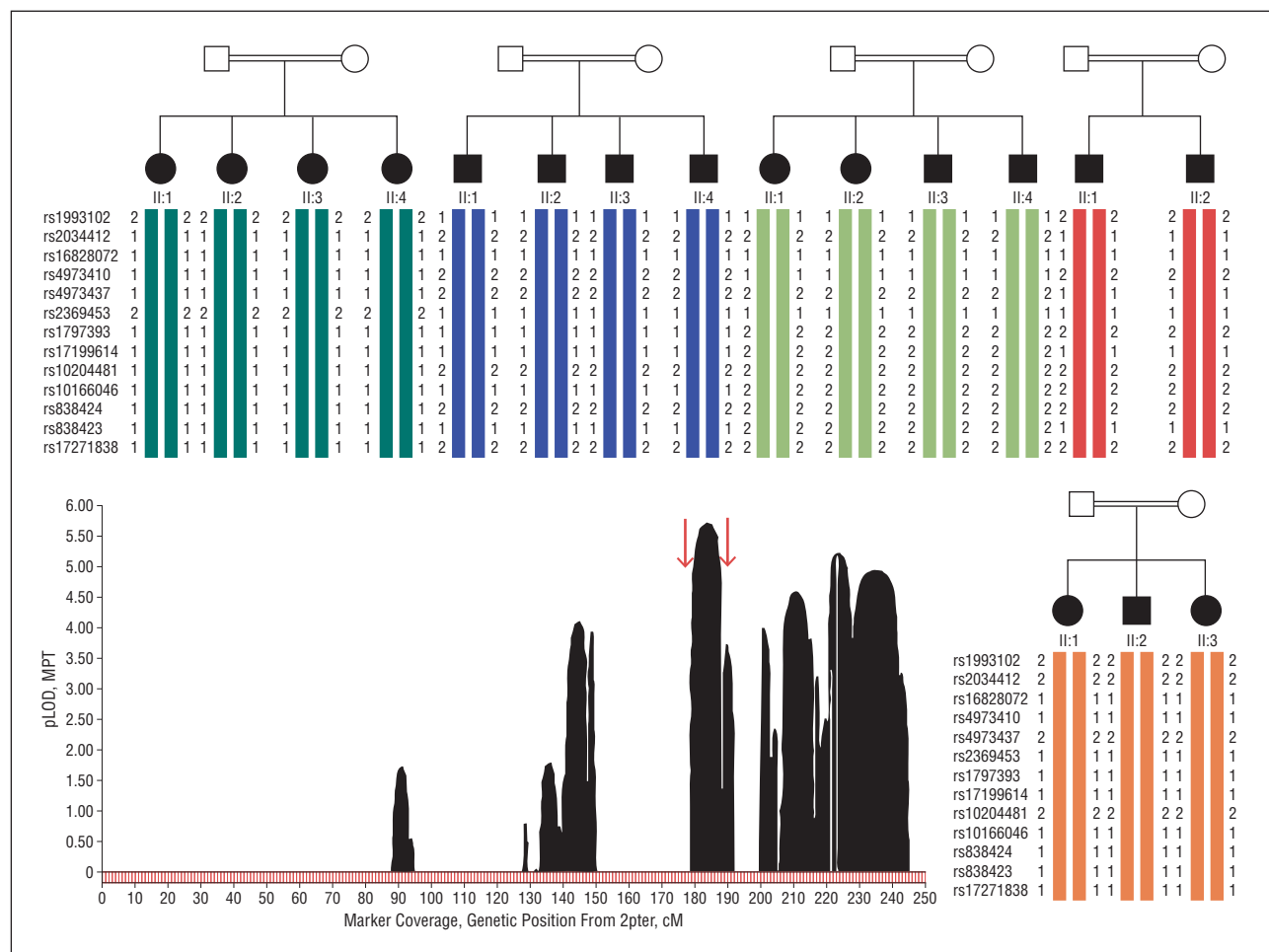


Figure 1. Linkage analysis output from 5 consanguineous families is shown in the middle (arrows indicate the recombination events defining the minimal linkage interval at rs6716235 and rs13009438) surrounded by haplotype analysis. Note that different haplotypes are displayed by the 5 families in the minimal area of overlap of runs of homozygosity. Squares indicate males; circles, females; open symbols, unaffected; solid symbols, affected; pLOD, parametric logarithm of odds; and MPT, multipoint test.

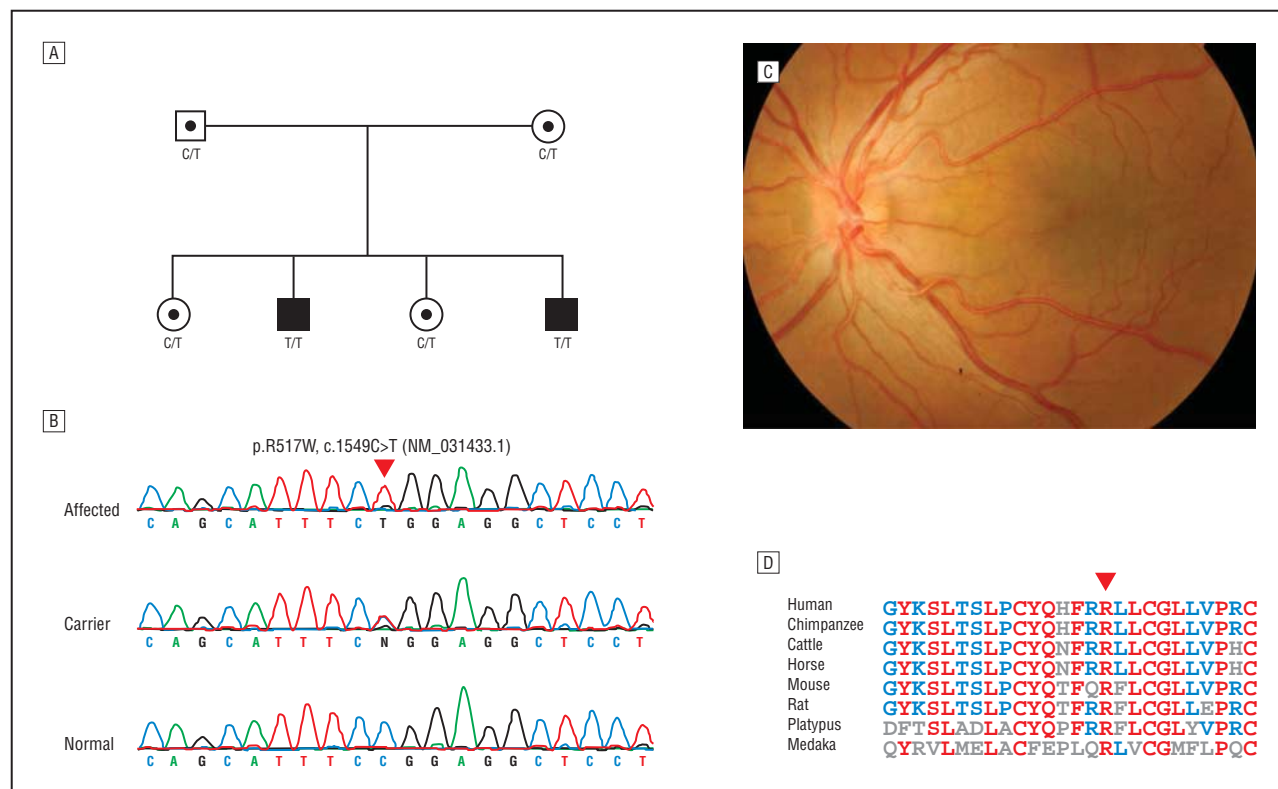


Figure 2. Pedigree, sequence chromatogram, fundus photograph, and cross-species alignment. A, Pedigree and segregation pattern of a novel *MFRP* mutation in 2 siblings with the classic posterior microphthalmos phenotype from a South African family of Indian ancestry. Squares indicate males; circles, females; open symbols with dots, carrier status; and solid symbols, affected. B, Sequence chromatogram of the mutation (arrowhead). C, Fundus photograph from 1 of the 2 siblings, depicting a typical funnel-shaped papillomacular fold. D, Cross-species alignment showing strong conservation of the residue affected by the mutation (arrowhead).

(Affymetrix, Santa Clara, California) was used for genotyping as per the manufacturer's protocol. The easyLINKAGE package (Institute of Human Genetics, Charité Virchow Campus Berlin, Berlin, Germany, and Medical Clinic IV, Friedrich-Alexander University Erlangen-Nuremberg, Erlangen and Nuremberg, Germany) was used to calculate the logarithm of odds score, and Genotyping Console software (Affymetrix) was used to compute runs of homozygosity.⁴ Microsatellite markers were used to confirm the identified locus.

Primers were designed to amplify and sequence the entire reading frame of all genes contained within the minimal linkage interval. In addition, complementary DNA was synthesized from venous blood collected in PAXGene tubes followed by polymerase chain reaction (PCR) covering the entire transcript for these genes.

Results. Detailed phenotypic analysis will be published elsewhere. Briefly, 22 patients (representing 6 consanguineous unrelated Saudi families and 1 nonconsanguineous South African family of Indian ancestry) who were diagnosed as having PM were enrolled. None had evidence of other developmental eye or systemic defects.

Linkage to *MFRP* was excluded in all 6 consanguineous families. Only 1 run of homozygosity was shared between 5 of the 6 families, and linkage to this locus on chromosome 2q37 was confirmed with a logarithm of odds score of 5.73 (**Figure 1**). The locus (17.2 megabases) is flanked by single-nucleotide polymorphisms

rs6716235 and rs13009438. Interestingly, alignment of the run of homozygosity in the 5 families followed by PCR confirmation of the flanking single-nucleotide polymorphisms revealed a much narrower interval of 894 965 base pairs (chr2:232,012,660-232,907,624) bordered by rs6753112 and rs2697798 (eFigure, <http://www.archophthalmol.com>). Haplotype analysis of the minimal run of homozygosity suggested that a common founder mutation was unlikely (**Figure 1**). No pathogenic sequence variants were identified in any of the 8 genes (*NCL*, *C2orf52*, *NMUR1*, *C2orf57*, *PTMA*, *PDE6D*, *COPS7B*, and *NPPC*) contained within this interval. Reverse transcription-PCR revealed normal splicing, and sequencing of the transcripts further ruled out the presence of coding mutations. Linkage to *MFRP* and to this locus was excluded in family 6. Interestingly, a novel homozygous missense mutation in *MFRP* (c.1549C>T, p.R518W) was identified in the South African family, which displayed the typical PM phenotype (**Figure 2**). The PolyPhen Web tool (<http://genetics.bwh.harvard.edu/pph/>) predicted that this mutation, which replaces a highly conserved arginine residue, is probably damaging with a score of 2.495.

Comment. In this study we have identified a PM locus on chromosome 2q37.1 that represents an independent validation and significant narrowing of the very recently reported locus.⁵ Surprisingly, we have failed to uncover the disease-causing mutation despite sequencing

the entire reading frame of all 8 genes in this locus. This is unlikely to be explained on the basis of deep intronic mutations or regulatory element mutations given the normal results of reverse transcription–PCR. Normal reverse transcription–PCR results also rule out the possibility of gene rearrangement as a potential cause. Therefore, the causative mutation must reside in an as yet unannotated gene or intergenic regulatory element within the minimal linkage interval. Capture of this interval for subsequent next-generation sequencing is an attractive strategy that we are actively pursuing.

Mutations in *MFRP* were first reported in patients with severe hyperopia.² While severe hyperopia is a major feature of PM, the anterior segment involvement in patients with *MFRP* mutations indicates that the phenotype is best described as nanophthalmos.³ In addition, another *MFRP* mutation was described in patients who, in addition to PM, have retinitis pigmentosa, foveoschisis, and optic disc drusen.⁶ Therefore, our finding of a novel mutation in 2 patients with the classic nonsyndromic PM phenotype represents the first evidence to date that *MFRP* is a bona fide nonsyndromic PM gene. While it is premature to draw any meaningful genotype–phenotype correlation for *MFRP*-related PM, it is noteworthy that our missense mutation is milder than the truncating mutations that characterize the mutational spectrum of nanophthalmos and syndromic PM.

Two other findings are worth highlighting. First, exclusion of linkage to *MFRP* and chromosome 2q37.1 in family 6 suggests the presence of yet another locus for this genetically heterogeneous condition. Second, the fact that none of the ethnically Saudi families have linkage to *MFRP* suggests a low frequency for mutations in this gene in this population. Both findings should encourage further research in the genetics of PM in Saudi Arabia, which is likely to identify important effectors of embryonic eye development.

Mohammed A. Aldahmesh, PhD
Sawsan R. Nowilaty, MD
Fatema Alzahrani, BSc
Lama Al-Ebdi, BSc
Jawahir Y. Mohamed, BSc
Mohammed Rajab, BSc
Arif O. Khan, MD
Fowzan S. Alkuraya, MD

Author Affiliations: Department of Genetics, King Faisal Specialist Hospital and Research Center (Drs Aldahmesh, Khan, and Alkuraya, Mss Alzahrani, Al-Ebdi, and Mohamed, and Mr Rajab), Vitreoretinal Division (Dr Nowilaty) and Pediatric Ophthalmology Division (Dr Khan), King Khaled Eye Specialist Hospital, and Department of Pediatrics, King Khalid University Hospital and College of Medicine, King Saud University and Department of Anatomy and Cell Biology, College of Medicine, Alfaisal University (Dr Alkuraya), Riyadh, Saudi Arabia.

Correspondence: Dr Alkuraya, Department of Genetics, King Faisal Specialist Hospital and Research Center, MBC 03, PO Box 3354, Riyadh 11211, Saudi Arabia (falkuraya@kfshrc.edu.sa).

Financial Disclosure: None reported.

Funding/Support: This study was funded in part by grant 08-MED497-20 from King Abdulaziz City for Science and Technology (Dr Alkuraya).

Online-Only Material: The eFigure is available at <http://www.archophthalmol.com>.

Additional Contributions: We thank all of the families for their cooperation.

1. Spitznas M, Gerke E, Bateman JB. Hereditary posterior microphthalmos with papillomacular fold and high hyperopia. *Arch Ophthalmol*. 1983;101(3):413-417.
2. Sundin OH, Leppert GS, Silva ED, et al. Extreme hyperopia is the result of null mutations in *MFRP*, which encodes a Frizzled-related protein. *Proc Natl Acad Sci U S A*. 2005;102(27):9553-9558.
3. Khan AO. Posterior microphthalmos vs nanophthalmos. *Ophthalmic Genet*. 2008;29(4):189.
4. Aldahmesh MA, Safieh LA, Alkuraya H, et al. Molecular characterization of retinitis pigmentosa in Saudi Arabia. *Mol Vis*. 2009;15:2464-2469.
5. Hmani-Aifa M, Ben Salem S, Benzina Z, et al. A genome-wide linkage scan in Tunisian families identifies a novel locus for non-syndromic posterior microphthalmia to chromosome 2q37.1. *Hum Genet*. 2009;126(4):575-587.
6. Ayala-Ramirez R, Graue-Wiechers F, Robredo V, Amato-Almanza M, Horta-Diez I, Zenteno JC. A new autosomal recessive syndrome consisting of posterior microphthalmos, retinitis pigmentosa, foveoschisis, and optic disc drusen is caused by a *MFRP* gene mutation. *Mol Vis*. 2006;12:1483-1489.

Subclinical Facioscapulohumeral Muscular Dystrophy Masquerading as Bilateral Coats Disease in a Woman

Coats disease is a nonhereditary retinal vasculopathy that typically occurs unilaterally in young males. We describe a unique case of a woman with bilateral Coats disease–like retinal changes and subclinical facioscapulohumeral disease (FSHD).

Report of a Case. A 39-year-old woman with an unremarkable medical and ocular history had a routine eye examination. She denied any family history of hereditary systemic or ocular disease. Visual acuity was 20/20 OU. The slitlamp examination results and intraocular pressures were normal. Funduscopy examination of the right eye revealed a normal posterior pole with subtle sheathing of retinal vessels without exudation in the far inferotemporal periphery (**Figure, A**). Funduscopy examination of the left eye also revealed a normal posterior pole with an area of fibrovascular tissue surrounded by lipid exudation in the far temporal periphery (**Figure, B**). The patient underwent wide-field fluorescein angiography (Optos P200, Optos PLC, Dunferline, Scotland) to obtain superior images from the far periphery (**Figure, C and D**). The wide-field fluorescein angiogram showed bilateral temporal retinal telangiectasia, aneurysms, and peripheral nonperfusion with leakage and staining of the fibrovascular lesion in the left eye (**Figure, C and D**). Results of a comprehensive medical workup for infectious and inflammatory causes were negative. Owing to reports of a relationship between bilateral Coats disease–like retinal vascular changes and FSHD, the patient underwent genetic testing for this muscular dystrophy. Genetic testing demonstrated a deletion in chromosome 4q35 and resulted in 27-kilobase (kb) and 24-kb band fragments following diges-