

Consensus Statement on the Classification and Terminology of Neck Dissection

K. Thomas Robbins, MD; Ashok R. Shaha, MD; Jesus E. Medina, MD; Joseph A. Califano, MD; Gregory T. Wolf, MD; Alfio Ferlito, MD; Peter M. Som, MD; Terry A. Day, MD; for the Committee for Neck Dissection Classification, American Head and Neck Society

Objective: To update the guidelines for neck dissection terminology, as previously recommended by the American Head and Neck Society.

Participants: Committee for Neck Dissection Classification, American Head and Neck Society; representation from the Committee for Head and Neck Surgery and Oncology, American Academy of Otolaryngology–Head and Neck Surgery (T.A.D.).


Evidence: Review of current literature on neck dissection classification.

Consensus Process: Semiannual face-to-face meetings of the Committee for Neck Dissection Terminology and e-mail correspondence.

Conclusions: Standardization of terminology for neck dissection is important for communication among clinicians and researchers. New recommendations have been made regarding the following: boundaries between levels I and II and between levels III/IV and VI; terminology of the superior mediastinal nodes; and the method of submitting surgical specimens for pathologic analysis.

Arch Otolaryngol Head Neck Surg. 2008;134(5):536-538

THE AMERICAN HEAD AND Neck Society (AHNS), in cooperation with the Committee for Head and Neck Surgery and Oncology of the American Academy of Otolaryngology–Head and Neck Surgery, has made recommendations for neck dissection classification over the past 2 decades.^{1,2} The current system has been accepted widely, thus allowing data to be reported without ambiguity and promoting an ease of communication among health care providers who treat patients with head and neck cancer.

 **CME available online at www.jamaarchivescme.com and questions on page 469**

In the later publication,² the recommended modifications were intended to add refinements to the original system. Included was the use of the hyoid bone and the cricoid cartilage as markers to define the boundary between levels II and III and levels III and IV, respectively, to allow radiologists to accurately localize nodal lesions within the defined levels of the neck. Another modification was to identify and define the boundaries of subzones in levels I, II, and V in response to the increasing awareness of specific sublevels having lower or higher risk for nodal metastases within a sublevel compared with the remaining region within the same zone. This change was intended

to heighten awareness of the nuances of the patterns of lymph node metastases based on the site of disease origin and to refine treatment accordingly.

The third modification was intended to encourage a more uniform terminology for selective neck dissection, one that more accurately represents the specific levels of neck contents removed. For example, in the case of a patient with a T2N0 squamous cell carcinoma located on the lateral border of the oral surface of the tongue who was undergoing surgery to remove sublevels IB and IIA and levels III and IV, clinicians were encouraged to define the neck dissection procedure as *selective neck dissection (sublevels IB and IIA and levels III and IV)*. While the committee members recognized the term *extended supraomohyoid neck dissection* as the traditional name, there was agreement that it was less precise than the definition by levels and sublevels. Similarly, in the case of a patient with a T1N0 squamous cell carcinoma of the supraglottic larynx who was undergoing an endoscopic resection and neck dissection to remove sublevel IIA and level III on each side, the recommended term for this lymphadenectomy would be *bilateral selective neck dissection (sublevel IIA and level III)* rather than *bilateral lateral neck dissection*. Practitioners were encouraged to use the term *selective neck dissection* with specific notation of the levels or sublevels removed and to rely less on historical terms that were less precise.

Author Affiliations are listed at the end of this article.

Group Information: Drs Robbins, Shaha, Medina, Califano, Wolf, Ferlito, Som, and Day comprise the Committee for Neck Dissection Classification, American Head and Neck Society.

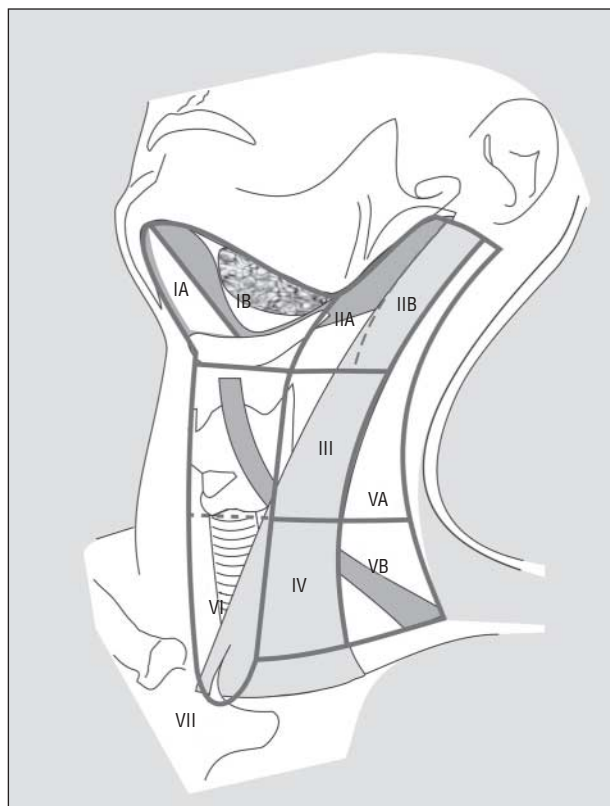


Figure. Anatomic diagram of the neck depicting the boundaries of the 6 neck levels and 3 neck sublevels.

The Neck Dissection Classification Committee of the AHNS has continued to review issues of terminology and definitions in several meetings over the past 3 years to address perceived shortcomings of the current system. Herein, we summarize some of the changes agreed on by general consensus among the members, and we encourage our colleagues to adopt these additional modifications.

ALTERNATE NOMENCLATURE FOR THE RADICAL AND MODIFIED RADICAL NECK DISSECTION

A recent proposal by the Japan Neck Dissection Study Group is to use the term *total neck dissection* when all 5 levels are removed and the term *selective neck dissection* when fewer than 5 levels are removed.³ The AHNS has accepted the terms *radical neck dissection* and *modified radical neck dissection* when all 5 levels are removed. However, we realize that the terms are more cumbersome than what the Japanese have proposed. Other terms such as *comprehensive neck dissection* or even *full neck dissection* are also less cumbersome. While we do not endorse any term, we strongly recommend that the introduction of an alternate name for *radical neck dissection* or *modified radical neck dissection* should precisely describe the procedure to avoid any potential for misinterpretation. Also, the new term should include a clear denotation of nonlymphatic structures, as is implied by the traditional terms *radical neck dissection* and *modified radical neck dissection*.

REDEFINING THE BOUNDARY BETWEEN SUBLEVELS IB AND IIA

Currently, the boundary that separates sublevel IB from sublevel IIA is defined as the border of the stylohyoid muscle. While this anatomic landmark can be recognized during a neck dissection procedure, it is not a very practical marker during clinical examination, nor can it be identified by the radiologist on imaging studies.⁴ Therefore, based on consultations with our radiology colleagues, we propose adopting their recommendation for an alternative border between levels I and II: the vertical plane defined by the posterior edge of the submandibular gland (**Figure**). For the radiologist, lymph nodes that lie anterior (or medial) to this plane are defined as occupying level I, whereas those lying posterior (or lateral) to it are defined as occupying level II. In the case of nodes that transgress this plane, the determination will be based on whether more than half of the node volume is located medial or lateral to the plane. While this system may occasionally result in the identification of a postglandular node being categorized to sublevel IIA rather than sublevel IB, the frequency of this situation is likely to be low and far outweighed by the advantage of being compatible for radiological interpretation. From the viewpoint of the surgeon removing level II while preserving level I, the dissection plane typically used to separate the 2 levels is along the fascia overlying the posterior aspect of the submandibular gland.

INCORPORATING A RADIOLOGIC LANDMARK TO SEPARATE LEVELS III AND IV FROM LEVEL VI

The anatomic boundary that separates the medial border of levels III and IV from the lateral border of level VI has traditionally been the lateral border of the sternohyoid muscle. However, this is not a landmark that radiologists can discern easily. Therefore, based on the recommendations of our consulting radiologist (P.M.S.), we agree that the medial aspect of the common carotid artery is an acceptable alternate landmark for separating these levels when viewing the neck in an axial plane, as is the case with computed tomography and magnetic resonance imaging evaluation. Intraoperatively, surgeons may still want to use the border of the sternohyoid muscle to define the medial extent of the neck dissection when removing levels III and IV because the targeted nodes are usually more superficial to the carotid artery, which is often not exposed in the operative field.

DEFINING LYMPH NODE GROUPS LOCATED OUTSIDE THE TRADITIONAL BOUNDARIES OF NECK DISSECTION, WITH PARTICULAR REFERENCE TO THE SUPERIOR MEDIASTINAL NODES

The traditional boundaries of the radical neck dissection encompass levels I through V. However, the original description of the level system by the surgeons at Memorial Hospital in New York also included levels VI and VII.⁵ The Neck Dissection Classification Committee of the AHNS previously recommended the use of *level VI* to define the anterior central compartment of the neck but did not recommend the use of *level VII* because it defined a region outside

the typical boundaries of the neck. The committee believed that lymph node groups located outside the boundaries of the neck should be denoted by the anatomic name used for the group. This policy was intended to discourage the use of many new levels to define other lymph node groups and avoid a more complex number system. However, the use of *level VII* in many publications continues to be the preferred method for delineating nodes as the superior mediastinal group. In essence, most of these nodes represent an extension of the paratracheal lymph node chain extending inferiorly below the suprasternal notch along each side of the cervical trachea to the level of the innominate artery. However, some superior mediastinal nodes extend below the innominate artery to the level of the aortic arch. Removal of such nodes usually requires a transmanubrial approach, whereas the typical case of superior mediastinal lymphadenopathy can be managed through a cervical approach only. Therefore, we recommend that if the term *level VII* is to be used, it should refer to the extension of the chain of paratracheal nodes below the suprasternal notch (the dividing line between levels VI and VII) to the level of the innominate artery only. Alternatively, these nodes might be defined as the *superior mediastinal lymph nodes* above the level of the innominate artery.

SUBMITTING THE NECK DISSECTION SPECIMEN FOR PATHOLOGIC ANALYSIS

The physician must be aware of the presence and extent of cancer involving the regional lymph nodes to determine whether ancillary treatment is necessary. Therefore, the surgical specimen should be submitted to the pathologist in the manner most appropriate to determine the maximum amount of information, including the total number of lymph nodes in each level and sublevel, the number of lymph nodes with evidence of metastases, and whether there is any evidence of extracapsular extension. Therefore, we recommend that the neck dissection specimen be divided into levels and sublevels by the surgeon while in the operating room immediately after the specimen is removed from the patient. This should be done on a separate back table using instruments that will no longer be used in the operative procedure. To minimize the risk of the pathologist and the processing team identifying the neck levels incorrectly, we strongly recommend that each neck level be submitted to the laboratory in separate containers and carefully labeled by the staff in the operating room under the direct supervision of the surgeon. When possible, all of the sublevels that are removed should be submitted in separate containers as well. In current surgical practice, most neck dissections are of the selective type, and specimens typically lack anatomic landmarks that historically allowed pathologists to orient specimens; therefore, we believe that this exercise of separating and labeling the neck contents by each level and sublevel is of paramount importance.

CONCLUSIONS

The Neck Dissection Committee of the AHNS will continue to review and recommend modifications for neck dis-

section terminology and classification. The changes outlined herein represent a consensus among a working group that has kept abreast of the emerging concepts and modifications being promoted worldwide. We believe that our committee has responded to the changes in a manner that acknowledges progress while maintaining consistency and respect for the existing culture of communication. We believe that our role in analyzing and responding to such changes will continue as new discoveries are made and alternative approaches developed.

Submitted for Publication: June 6, 2007; final revision received August 21, 2007; accepted August 28, 2007.

Author Affiliations: Division of Otolaryngology, Southern Illinois University School of Medicine, Springfield (Dr Robbins); Head and Neck Service, Memorial Sloan-Kettering Cancer Center, New York, New York (Dr Shaha); Department of Otolaryngology, University of Oklahoma Health Sciences Center, Oklahoma City (Dr Medina); Department of Otolaryngology–Head and Neck Surgery, Johns Hopkins University School of Medicine, Baltimore, Maryland (Dr Califano); Department of Otolaryngology–Head and Neck Surgery, University of Michigan, Ann Arbor (Dr Wolf); Department of Surgical Sciences, Otorhinolaryngologic Clinic, University of Udine, Udine, Italy (Dr Ferlito); Department of Radiology, Mount Sinai Medical Center, New York, New York (Dr Som); and Department of Otolaryngology–Head and Neck Surgery, Medical University of South Carolina, Charleston (Dr Day).

Correspondence: K. Thomas Robbins, MD, SimmonsCooper Cancer Institute, Southern Illinois University School of Medicine, PO Box 19677, Springfield, IL 62794-9677 (trobbins@siumed.edu).

Author Contributions: Dr Robbins had full access to all the data in the study and takes responsibility for the integrity of the data and the accuracy of the data analysis. *Study concept and design:* Robbins, Medina, Califano, and Day. *Analysis and interpretation of data:* Shaha, Califano, Wolf, Ferlito, and Som. *Drafting of the manuscript:* Robbins, Califano, Som, and Day. *Critical revision of the manuscript for important intellectual content:* Shaha, Medina, Califano, Wolf, and Ferlito. *Administrative, technical, and material support:* Robbins and Califano. *Study supervision:* Robbins, Wolf, Ferlito, Som, and Day. *Development of Consensus:* Shaha.

Financial Disclosure: None reported.

REFERENCES

1. Robbins KT, Medina JE, Wolfe GT, Levine PA, Sessions RB, Pruet CW. Standardizing neck dissection terminology: official report of the Academy's Committee for Head and Neck Surgery and Oncology. *Arch Otolaryngol Head Neck Surg.* 1991; 117(6):601-605.
2. Robbins KT, Clayman G, Levine PA, et al. Neck dissection classification update: revisions proposed by the American Head and Neck Society and the American Academy of Otolaryngology–Head and Neck Surgery. *Arch Otolaryngol Head Neck Surg.* 2002;128(7):751-758.
3. Hasegawa Y, Saikawa M, Hayasaki K, et al. A new classification and nomenclature system for neck dissections: a proposal by the Japan Neck Dissection Study Group. *Jpn J Head Neck Cancer.* 2005;31(1):71-78.
4. Som PM, Curtin HD, Mancuso AA. Imaging-based nodal classification for evaluation of neck metastatic adenopathy. *AJR Am J Roentgenol.* 2000;174(3):837-844.
5. Shah JP, Strong E, Spiro RH, Vikram B. Surgical grand rounds: neck dissection: current status and future possibilities. *Clin Bull.* 1981;11(1):25-33.