

# Paraglottic Space in Supracricoid Laryngectomy

Min-Sik Kim, MD; Dong-Il Sun, MD; Kyung-Ho Park, MD; Kwang-Jae Cho, MD;  
Young-Hak Park, MD; Seung-Ho Cho, MD

**Background:** Paraglottic space (PGS) is a connective tissue compartment of the larynx and is important in the extension of laryngeal cancer. It communicates with the preepiglottic space superiorly and with the extralaryngeal region inferiorly through the gap within the cricothyroid membrane. Transglottic cancer of the larynx, which spreads within PGS, is characterized by a high incidence of laryngeal skeleton invasion and of cervical metastasis. Determining the correct stage of transglottic cancer of the larynx is difficult, leading to therapeutic failure of partial laryngectomy in some cases.

**Objective:** To clinically confirm a pathologically complete resection of PGS from the piriform sinus mucosa by supracricoid partial laryngectomy in laryngeal cancers involving PGS.

**Materials and Methods:** Eight patients with transglottic cancer whose cancer was confirmed clinically and

pathologically at stages T2b or higher underwent supracricoid partial laryngectomy. During supracricoid partial laryngectomy, we performed a sharp dissection of PGS from the piriform sinus mucosa to obtain a complete resection margin while preserving the piriform sinus mucosa. Microscopic evaluation of the specimens was made for the invasion of PGS and the safe margin distance from the piriform sinus mucosa.

**Results:** Pathological cancer invasion of PGS was confirmed in 7 of 8 patients and a sufficient pathological margin from tumor invasion to the piriform sinus mucosa was obtained. The average safety margin was 10.3 mm.

**Conclusion:** Supracricoid partial laryngectomy could be considered a safe surgical modality for cancers not extending to PGS.

*Arch Otolaryngol Head Neck Surg.* 2002;128:304-307

**P**ARAGLOTTIC SPACE (PGS) is a connective tissue compartment of the larynx and was first described in 1962 by Tucker and Smith.<sup>1</sup> They reported that PGS borders the thyroid cartilage anterolaterally, the conus elasticus interoinferiorly, the ventricle and quadrangular membrane inferiorly, and the piriform sinus mucosa dorsally. Paraglottic space is also connected with the preepiglottic space superiorly and with the extralaryngeal space inferiorly through the gap in the cricothyroid membrane.<sup>1,2</sup> Kirchner and Cornog<sup>3</sup> described transglottic cancer as laryngeal cancer invading both sides of the false vocal cord and true vocal cord across the ventricle, and reported that the extension of laryngeal cancer is achieved through PGS. Transglottic cancer invading PGS is characteristically known to show a high incidence of laryngeal skeleton invasion and cervical metastasis.<sup>4,5</sup> Determining the accurate stage of transglottic cancer is difficult preoperatively,<sup>5</sup> leading to failure of

partial laryngectomy in some cases.<sup>6,7</sup> Laryngeal cancer invading PGS was treated in the past with total laryngectomy; however, patients who undergo this procedure lose their voice, resulting in social and emotional problems. The development of partial laryngectomy in recent years has led to the development of surgical methods that preserve the maximal physiological function of the larynx while totally removing the primary site. Supracricoid partial laryngectomy (SCPL) is one of the methods reported that can be used in laryngeal cancer cases needing total laryngectomy by resecting the tumor with PGS.<sup>6-8</sup> However, pathological verification in this procedure has not been established because the tumor is removed completely from the piriform sinus where no barrier is present from laryngeal cancer cases. Thus, we tried to confirm whether a tumor can be resected safely by separating PGS from the piriform sinus mucosa SCPL in locally advanced laryngeal cancer cases with preoperative PGS invasion of stage T2b or higher.

From the Department of Otolaryngology—Head and Neck Surgery, College of Medicine, The Catholic University of Korea, Seoul, Korea.

## PATIENTS AND METHODS

The study was conducted with 8 patients who were diagnosed as having transglottic cancer at stage T2b or higher with radiologically suspected invasion of PGS and decreased or fixed movement of the vocal cords. These patients underwent SCPL at the Department of Otolaryngology–Head and Neck Surgery, Kangnam St Mary's Hospital, College of Medicine, and The Catholic University of Korea, from March to December 1999. All cases were squamous cell carcinoma, and the primary lesion was glottic cancer in 7 cases (9 sides) and supraglottic cancer in 1 case. The study included 2 patients with stage T4 cancer where the vocal cord invasion of both sides was present (**Table**). There were 3 cases of T2b, 3 cases of T3, and 2 cases of T4 cancer; 6 cases underwent cricohyoidoepiglottopexy; 1, tracheocricohyoidoepiglottopexy; and 1, cricohyoidopexy. All patients were male with an average age of 63.6 years.

### SURGERY METHODS

Supracricoid partial laryngectomy described by Laccourreye et al<sup>8,9</sup> was performed according to tumor location. After dissecting the superior and nontumor-bearing side of PGS tissue during surgery according to tumor invasion by

the conventional method, the lesion side of PGS was completely dissected from the piriform sinus mucosa. To expose the piriform sinus mucosa, an index finger was inserted in the piriform sinus, pulling it anterolaterally while pulling the other side of the larynx in the opposite direction. The remaining PGS tissue, not including the piriform sinus mucosa, was sharply dissected completely and the PGS tissue was removed from the piriform sinus mucosa with a sharp knife (**Figure 1**).

### TISSUE TREATMENT

The resected tissue was fixed in 10% formaldehyde, decalcified in 8% formic acid for 4 days, and embedded in paraffin. After cutting 4-mm horizontal sections from the top, middle, and bottom sections of PGS, the supraglottic paraglottic region, glottic region, and infraglottic region of PGS (by observing the embedded tissue), the invasion of PGS was determined visually in each section. When invasion of PGS was present, the distance between the resection margin of the piriform sinus and tumor mass was measured, and the tissue slides were prepared from the site nearest the tumor mass and stained with hematoxylin-eosin. The distance between the tumor mass to the piriform sinus mucosa was then measured and the average distances of the 3 sites were calculated (**Figure 2**).

**Paraglottic Space Invasion and Safety Margin From Tumor to Piriform Sinus Mucosa\***

Patient No.	Tumor Site	Tumor Stage	Paraglottic Space Invasion		Safety Margin, mm			Average Margin, mm
			Clinical	Pathologic	Superior	Middle	Inferior	
1	G	T2b NO MO	+	–	17	15	13	15
2	SG	T3 NO MO	+	+	3	2	9	5
3	G	T3 NO MO	+	+	12	5	5	7
4	G	T2b NO MO	+	+	19	17	13	17
5	G	T3 N2b MO	+	+	9	8	4	7
6	G	T4 NO MO	+	+	15 (R), 11 (L)	5 (R), 6 (L)	7 (R), 7 (L)	9 (R), 8 (L)
7	G	T2b NO MO	+	+	14	5	9	9
8	G	T4 N1 MO	+	+	8 (R), 11 (L)	14 (R), 16 (L)	15 (R), 14 (L)	12 (R), 14 (L)

\*G indicates glottic; SG, supraglottic; plus sign, invasion present; minus sign, no invasion; R, right side; and L, left side.

## RESULTS

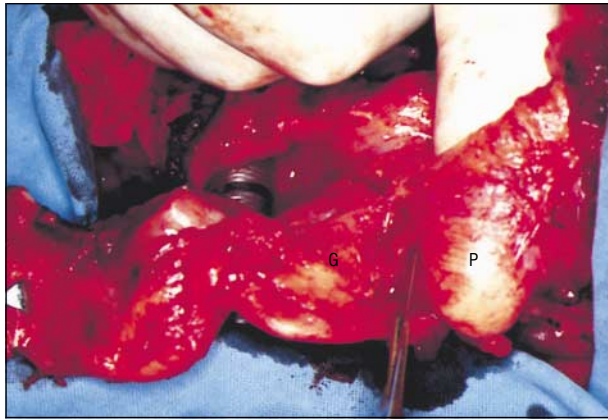
Paraglottic space invasion was confirmed histologically in 7 (9 sides) of 8 cases (10 sides) of clinically suspected PGS invasion. The safety margin from the tumor mass to the piriform sinus mucosa in the supraglottis was 3 mm in supraglottic cancer and 9 to 19 mm in glottic cancer. The invasion was mainly present in supraglottic cancer and the safety margin was maintained but was too close. Although the invasion was present in the glottic area with the safety margin of 2 mm in supraglottic cancer and 5 to 17 mm in glottic cancer, the safety margin was sufficient in most cases. The safety margin from the middle of the tumor was 15 and 17 mm in 2 of 3 cases with initial PGS invasion; 5 mm in 1 case with confirmed PGS invasion; and 2 mm, 5 mm, and 8 mm in 3 cases of T3 tumors. In 2 cases (4 sides) of T4 tumors,

the safety margin was 5 mm in the right side and 6 mm in the left side in 1 case and 14 mm in the right side and 16 mm in the left side in the other case. Among these, the closest safety margin was 2 mm from the superior glottic region to the piriform sinus in the T3 transglottic tumor originated from the supraglottis (**Figure 3**).

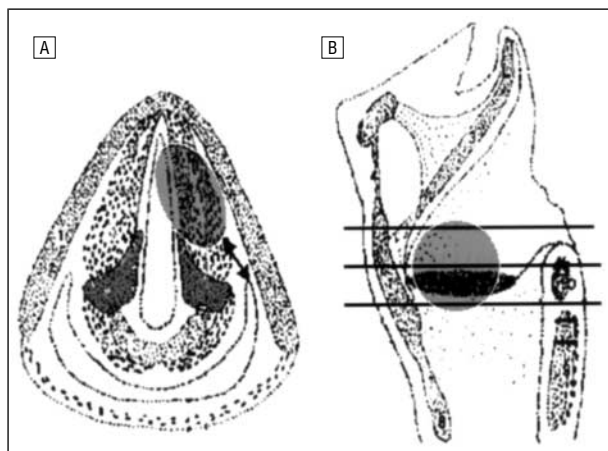
In all 8 cases, PGS could be dissected from the piriform sinus mucosa with a sufficient surgical margin; the average distance between the tumor to the piriform sinus mucosa was 10.3 mm. No postoperative aspiration or dysphagia was present in any of the patients (Table).

## COMMENT

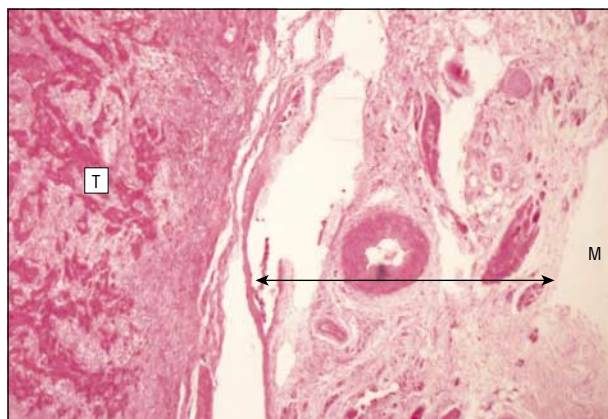
The concept of compartmentalization of the larynx was introduced by Pressman et al,<sup>10</sup> who detected that the flow of a dye injected under the supraglottis mucosa stops at



**Figure 1.** Surgical method of supracricoid partial laryngectomy. Surgeon's left index finger is placed under the patient's right piriform sinus mucosa (P) pulling it anterolaterally while pulling the other side of the larynx in the opposite direction. The remaining paraglottic space tissue (G) is dissected using a No. 15 cold blade while preserving the piriform sinus mucosa.



**Figure 2.** Planes of section. A, The distance (safety margin) of the horizontal section of the larynx at the level of glottis between the tumor and piriform sinus mucosa (arrow). B, Median section of larynx shows horizontal section of tumor from upper, middle, and lower margins (3 lines).



**Figure 3.** An approximate 2-mm safety margin (arrow) was noted between piriform sinus mucosa (M) and the tumor mass (T) invading paraglottic space (hematoxylin-eosin, original magnification  $\times 40$ ).

the inferior margin of the false vocal cord. The authors also determined that the ventricle functions as an anatomical barrier. After the introduction of the compartmentalization concept of the larynx, Tucker and Smith<sup>1</sup> reported

that the PGS is a compartment in the larynx composed of connective tissue; it borders the thyroid cartilage anterolaterally, the conus elasticus inferomedially, the ventricle and quadrangular membrane superomedially, and the piriform sinus dorsally. The PGS connected to the preepiglottic space superiorly, to the extralaryngeal space through the gap in the cricothyroid membrane inferiorly, and included the thyroarytenoid muscle.<sup>1,2</sup> However, Maguire and Dayal<sup>11</sup> defined PGS as a small space composed of fat tissue bordering the thyroarytenoid muscle medially, the thyroid cartilage laterally, and the piriform sinus dorsally; the thyroarytenoid muscle from PGS was excluded. Sato et al<sup>12</sup> reported similar results. Thus, defining the exact area of PGS is still debatable. The inferior PGS located between the medial thyroarytenoid muscle and lateral thyroarytenoid muscle plays an important role in decreasing the vocal cord and arytenoid movements as the route of glottic cancer extension.<sup>13</sup> In other words, a decrease in the vocal cord movement represents the invasion of a tumor into the medial or lateral thyroarytenoid muscle through PGS in supraglottic cancer, and invasion into PGS of a tumor through the medial thyroarytenoid muscle in glottic cancer. In the present study, we confirmed that of 8 patients with suspected tumor invasion into PGS clinically and radiologically, 7 patients experienced tumor invasion into PGS histologically.

Transglottic cancer is laryngeal cancer invading the false vocal cord and true vocal cord across the ventricle. The origin of this tumor could be glottic cancer progressing superiorly, supraglottic cancer extending inferiorly, or a tumor originating from the ventricle extending into both directions. Clinical characteristics of this cancer are submucosal extension of the false vocal cord, PGS invasion, cartilage invasion, and cervical lymph node metastasis in about 30% to 40% of cases.<sup>14</sup> Hao et al<sup>15</sup> compared a T3 tumor invading only the true vocal cord with T3 transglottic cancer and reported that transglottic cancer showed more cervical lymph node metastasis, with 27% compared with 17% in the T3 tumor; there was more extracapsular spread in transglottic cancer with 43% compared with 27%.<sup>15</sup> Also, Biller and Lawson<sup>14</sup> reported that vertical partial laryngectomy could result in incomplete resection in transglottic cancer and could cause a high rate of recurrence. Transglottic cancer extends usually through PGS; thus, total laryngectomy was performed to completely remove PGS when a tumor invaded the PGS due to a high failure rate with past conventional methods of partial laryngectomy. However, total laryngectomy results in loss of voice and creates serious emotional and social problems for the patient. Therefore, it is important to accurately determine the presence or absence of PGS invasion preoperatively for the selection of treatment method and operative results.

Zbären et al<sup>16</sup> reported that PGS invasion can be diagnosed accurately in 86% of cases with computed tomography and in 89% with magnetic resonance imaging. We clinically determined the presence or absence of PGS invasion using computed tomography when the vocal cord movement was decreased or fixed. Laccourreye et al<sup>8,9</sup> recently reported on SCPL to remove PGS, epiglottis, and preepiglottic space, including thyroid cartilage. Different from total laryngectomy, this procedure not only avoids



losing the physiological function of voice and a permanent tracheotomy, but is also most effective in removing PGS as the partial laryngectomy that could replace the conventional total laryngectomy in cases of transglottic cancer invading PGS.<sup>10,17,18</sup> In the surgical method of SCPL completely resecting PGS, the most important aspect is preserving the piriform sinus mucosa that forms the dorsal margin of PGS and anteromedial margin of the hypopharynx. Moreover, since PGS is situated closely to the piriform sinus, PGS could be the route of laryngeal cancer extending to the hypopharynx or hypopharyngeal cancer extending to the larynx.<sup>19</sup> Although Laccourreye et al<sup>8,9</sup> reported that PGS could be completely resected using SCPL, not many studies reported on the surgical procedures that could resect PGS while safely preserving the piriform sinus (the posterior border of PGS). Thus, we tried to remove PGS as much as possible from the piriform sinus mucosa by inserting an index finger into the piriform sinus mucosa while pulling laterally to easily confirm the piriform sinus mucosa and pulling the rest of the larynx tissue to the opposite direction so that the removal of the other tissue was achieved. A surgical knife was used while confirming the piriform sinus mucosa. As a result, we could remove PGS from the piriform sinus mucosa in all 8 cases while giving a sufficient surgical margin. We histologically confirmed that the surgical margin was safe in all cases, especially in the cases where the surgical margin was more than 5 mm of localized stage T2b tumors. The average surgical margin was 8.9 mm in tumors in stages T3 and T4. Caution was needed in 1 case of supraglottic cancer where the tumor invasion was 2 mm from the surgical margin, possibly because the distance between the piriform sinus mucosa and PGS in the supraglottis is anatomically close.<sup>20</sup> Thus, SCPL used in the present study needs to be performed with more caution in transglottic cancer in dissecting PGS. A relatively safe surgical margin could be obtained in the rest of the cases. The patients are being followed up in an outpatient setting, with no sign of recurrence 1 year after surgery; no postoperative dysphagia or other complications due to the surgery were present.

## CONCLUSIONS

Supracricoid partial laryngectomy is a procedure that permits a safe en bloc dissection of a tumor including PGS when the tumor is confined within the PGS and could be used more effectively by safely separating PGS from the piriform sinus mucosa while managing to preserve the piriform sinus mucosa. This procedure needs to be performed after more prudent evaluation and selection in patients with transglottic cancer originating from the supraglottis.

Accepted for publication August 24, 2001.

This study was presented as a poster at the annual meeting of the American Head and Neck Society, Palm Desert, Calif, May 14-16, 2001.

Corresponding author and reprints: Min-Sik Kim, MD, Department of Otolaryngology-Head and Neck Surgery, Kangnam St Mary's Hospital, The Catholic University of Korea, Seoul, Korea 137-040 (e-mail: entkms@cmc.cuk.ac.kr).

## REFERENCES

1. Tucker GF, Smith HR. A histological demonstration of the development of laryngeal connective tissue compartments. *Trans Am Acad Ophthalmol Otolaryngol.* 1962;66:308-318.
2. Tucker G. Some clinical inferences from the study of serial laryngeal sections. *Laryngoscope.* 1963;73:728-748.
3. Kirchner JA, Cornog JL, Holmes RE. Transglottic cancer. *Arch Otolaryngol.* 1974;99:247-251.
4. Welsh LW, Welsh JJ, Rizzo TA. Internal anatomy of the larynx and the spread of cancer. *Ann Otol Rhinol Laryngol.* 1989;98:228-234.
5. Mittal B, Marks JE, Ogura JH. Transglottic carcinoma. *Cancer.* 1984;53:151-161.
6. Biller HF, Lawson W. Partial laryngectomy for transglottic cancers. *Ann Otol Rhinol Laryngol.* 1984;93:297-300.
7. Kirchner FA. Pathways and pitfalls in partial laryngectomy. *Ann Otol Rhinol Laryngol.* 1984;93:301-305.
8. Laccourreye H, Laccourreye O, Weinstein G, Menard M, Brasnu D. Supracricoid laryngectomy with cricohyoidoepiglottopexy: a partial laryngeal procedure for glottic carcinoma. *Ann Otol Rhinol Laryngol.* 1990;99:421-426.
9. Laccourreye H, Laccourreye O, Weinstein G, Menard M, Brasnu D. Supracricoid laryngectomy with cricohyoidoepiglottopexy: a partial laryngeal procedure for supraglottic and transglottic carcinomas. *Laryngoscope.* 1990;100:735-741.
10. Pressman JJ, Simon MB, Monell C. Anatomical studies related to the dissemination of cancer of the larynx. *Trans Am Acad Ophthalmol Otolaryngol.* 1960;64:628-638.
11. Maguire A, Dayal VS. Supraglottic anatomy: the pre- or the periepiglottic space? *Can J Otolaryngol.* 1974;3:432-445.
12. Sato K, Kurita S, Hirano M. Location of the preepiglottic space and its relationship to the paraglottic space. *Ann Otol Rhinol Laryngol.* 1993;102:930-934.
13. Rucci L, Gammarota L, Simonetti L, Cirri MBB. TNM glottic: role of the vocal muscle, arytenoid cartilage, and inferior paraglottic space in impaired vocal cord mobility (T2): an embryological and clinical study. *Ann Otol Rhinol Laryngol.* 1998;107:1038-1045.
14. Biller HF, Lawson W. Partial laryngectomy for transglottic cancers. *Ann Otol Rhinol Laryngol.* 1984;93:297-300.
15. Hao SP, Myers EN, Johnson JT. T3 glottic carcinoma revisited: transglottic vs pure glottic carcinoma. *Arch Otolaryngol Head Neck Surg.* 1995;121:166-170.
16. Zbären P, Becker M, Läng H. Pretherapeutic staging of laryngeal carcinoma: clinical findings, computed tomography, and magnetic resonance imaging compared with histopathology. *Cancer.* 1996;77:1263-1273.
17. Vincentiis M, Minni A, Gallo A. Supracricoid laryngectomy with cricohyoidopexy (CHP) in the treatment of laryngeal cancer: a functional and oncologic experience. *Laryngoscope.* 1996;106:1108-1114.
18. Laccourreye O, Laccourreye L, Muscatello L, Weinstein G, Brasnu D. Local failure after supracricoid partial laryngectomy: symptoms, management, and outcome. *Laryngoscope.* 1998;108:339-344.
19. Reidenbach MM. Borders and topographic relationships of the paraglottic space. *Eur Arch Otorhinolaryngol.* 1997;254:193-195.
20. Reidenbach MM. The paraglottic space and transglottic cancer: anatomic consideration. *Clin Anat.* 1996;9:244-251.