

The Value of Partial Splenic Autotransplantation in Patients With Portal Hypertension

A Prospective Randomized Study

Hongwei Zhang, MD; Jisheng Chen, MD; Gernot M. Kaiser, MD; Obetien Mapudengo, MD; Jie Zhang, MD; Michael S. Exton, PhD; Erwei Song, MD, PhD

Hypothesis: Splenic autotransplantation plays a role in preserving immune function of the spleen in patients with portal hypertension and liver cirrhosis.

Design: Prospective randomized study.

Setting: University hospital.

Patients: Twenty patients (19 men and 1 woman; aged 33-80 years) suffering from portal hypertension and liver cirrhosis were randomly allocated into 2 groups. Each group consisted of 10 patients.

Interventions: All patients underwent modified Sugiura operation. In the control group, splenectomy was performed, while partial splenic autotransplantation into the retroperitoneal space was additionally completed in the splenic autotransplantation group.

Main Outcome Measures: Serum tuftsin and IgM were measured preoperatively and 2 months after surgery. Dynamic scintigraphy with technetium Tc 99m-labeled heat-

damaged erythrocytes was performed at 2-month intervals during the 8-month follow-up.

Results: There was no statistical difference in the mortality of the groups. The preoperative levels of serum tuftsin and IgM showed no statistical difference between groups. However, although these measures had decreased remarkably in the control group 2 months after operation ($P < .001$ for serum tuftsin; $P = .04$ for serum IgM), they remained stable in the splenic autotransplantation group ($P = .25$ for serum tuftsin; $P = .12$ for serum IgM). Four patients within the splenic autotransplantation group showed positive scanning of the transplanted splenic fragment during follow-up, whereas there was no positive scanning in the control group.

Conclusion: Our results suggest that partial splenic autotransplantation can preserve immune function of the spleen, as measured by serum levels of tuftsin and IgM, in patients with portal hypertension and liver cirrhosis.

Arch Surg. 2002;137:89-93

From the Department of General Surgery, Sun Yat-Sen Memorial Hospital, Sun Yat-Sen University of Medical Sciences, Guangzhou, Peoples Republic of China (Drs H. Zhang, Chen, Mapudengo, J. Zhang, and Song); and Departments of General Surgery and Transplantation (Drs H. Zhang and Kaiser) and Medical Psychology (Dr Exton), University Hospital Essen, Essen, Germany.

IT HAS BEEN well established that the spleen is an important immune organ, serving as a large phagocytic filter and a major site of antibody production. The IgM-specific antibody, generated primarily in the spleen,¹ promotes opsonized phagocytosis by activating various complement fragments, and thus contributes to the early immune response to pathogens. In addition, the spleen produces tuftsin, which is a tetrapeptide regulating the activity and migration responses of phagocytic cells.²

Splenectomy impairs normal immune function by reducing phagocytic activity, lowering serum IgM and tuftsin levels, and diminishing suppressor T-cell numbers.³ Hence, patients with splenectomy have been shown to bear a higher risk of overwhelming postsplenectomy infection.^{4,5} This provokes interest in developing alternative operative methods for splenic preservation. Autotransplantation of splenic fragments after splenec-

tomy has been advocated as a method of retaining normal splenic immune function in the treatment of massive splenic trauma or splenomegaly caused by hematologic disorders.⁶⁻⁹ However, it remains equivocal whether splenic autotransplantation may help maintain splenic immune function in patients with portal hypertension and cirrhosis.

Therefore, we conducted a prospective randomized study to evaluate the influence of autologous splenic transplantation in patients with portal hypertension and cirrhosis on splenic immune function, as assessed by levels of serum IgM and tuftsin.

RESULTS

MORBIDITY AND MORTALITY

An 80-year-old patient from the splenic autotransplantation group, who had had severe chronic obstructive pulmonary disease for more than 30 years, died of

PATIENTS AND METHODS

PATIENTS

From July 1, 1999, to August 31, 2000, 20 patients (19 men and 1 woman; age range, 33-80 years) with liver cirrhosis complicated with portal hypertension and hypersplenism underwent surgical treatment at the Department of General Surgery, Sun Yat-Sen Memorial Hospital of the Sun Yat-Sen University of Medical Sciences, Guangzhou, People's Republic of China. The diagnosis of portal hypertension was confirmed by the presence of esophageal varices on endoscopy, and hypersplenism was assessed by pancytopenia. The liver function of these patients was graded as either Child class A (n=13) or B (n=7).

The patients were randomly allocated into 2 groups: splenic autotransplantation (n=10), in which patients underwent splenectomy with retroperitoneal splenic autotransplantation and gastroesophageal devascularization (modified Sugiura operation), and control (n=10), in which only splenectomy and gastroesophageal devascularization were performed. All treatments were carried out after approval by the university teaching hospital ethics committee and informed consent of the patient.

OPERATIVE TECHNIQUE

All operations were performed under elective conditions. Briefly, the abdomen was entered through a left subcostal incision and portal pressure was monitored from an omental vein. After exposure of the surrounding splenic ligaments, all short gastric vessels were ligated except the branch that was close to the splenic pedicle. After the ligation of the splenic vessels, splenectomy was performed and a fragment (7 × 5 × 1 cm) of the spleen was preserved near the splenic pedicle. Then, the posterior peritoneum just above the left kidney was cut open, and a bed in the retroperitoneal space to accommodate the splenic fragment, which had been marked with silver clips on its surface, was prepared by blunt dissection of the surrounding tissues. After the splenic fragment was adjusted at its appropriate site, a few stitches were added close to the posterior peritoneal incision. Finally, gastroesophageal devascularization was performed, followed by truncation and anastomosis of the lower esophagus with a 25-mm stapler (Proximate ILS CDH; Ethicon Endo-Surgery, Inc, Johnson & Johnson Inc, Cincinnati, Ohio).

PERIPHERAL BLOOD CELL COUNT AND MEASUREMENT OF SERUM IgM

Erythrocytes, leukocytes, and platelets were counted in venous blood in ethylenediaminetetraacetic acid before the operation and during the postoperative follow-up, and

serum IgM was measured (Beckman Array 360 Chemistry Analyzer; Global Medical Instrumentation Inc, Clearwater, Minn) preoperatively and 2 months after surgery.

MEASUREMENT OF SERUM TUFTSIN

Serum tuftsin was detected preoperatively and 2 months after operation by means of reverse-phase high-performance liquid chromatography, as described by Naim et al.¹⁰ Briefly, 5 mL of peripheral blood from each subject was collected in a nonsiliconized tube. Serum was isolated by centrifugation, and aliquots were frozen at -70°C for future assay. To release tuftsin from its carrier molecule subfraction IV of IgG, 1 mL of serum was diluted with 3 mL of 0.1N ammonium carbonate and digested with 1 mg of type I trypsin (Sigma-Aldrich Corp, St Louis, Mo). The digest was incubated at 37°C for 1 hour, and 17.5 mL of 95% ethyl alcohol was added. The mixture was then heated to 85°C for 15 minutes and cooled on ice before centrifugation at 3000 rpm for 30 minutes. The supernatant containing tuftsin was decanted into a 50-mL conical-bottom tube and evaporated overnight under a vacuum. The sample was then stored at -20°C until use.

A 5-octadecylsilyl column (25 cm × 4.6 nm) (Whatman; Yilite Scientific Instrumentation Inc, Dalian, China) was used for reverse-phase high-performance liquid chromatography. The mobile phase was 0.0023M heptafluorobutyric acid (Pierce Chemical Co, Rockford, Ill) in 22% acetonitrile and 78% water. The flow rate was 1 mL/min, and the UV detector (Waters 486, Waters Co, Milford, Mass) was set at 210 nm at 0.01 AUFS (absorbance units full scale), with an injection volume of 20 µL. A pump (Waters 510; Waters Co) and a data module systems controller integrator (Waters 721; Waters Co) were used. Under these experimental conditions, the retention time of synthetic tuftsin (Sigma-Aldrich Corp) was 5.1 minutes.

DYNAMIC SCINTIGRAPHY OF TRANSPLANTED SPLENIC FRAGMENT

From week 2 to 32 after surgery, dynamic scintigraphy of the transplanted splenic fragment engaging technetium Tc 99m (^{99m}Tc)-labeled heat-damaged erythrocytes was performed in all patients at 8-week intervals, with the use of methods described by Nielsen et al.¹¹

STATISTICAL ANALYSIS

Data are expressed as mean ± SD. The levels of serum tuftsin and IgM before and after surgery were compared by a paired 2-group *t* test, and the mortality rate as well as the positive rate of scintigraphy were compared between the 2 groups by χ^2 test. Significance levels were set at *P* < .05.

pulmonary failure on the sixth day after surgery. All other patients survived the perioperative period, with the mortality rate between both groups not statistically different (*P* = .33). No anastomotic leakage or obstruction and no postoperative hemorrhage occurred in either group during hospitalization. In addition, no deterioration in liver function was observed after surgery.

During follow-up, 1 patient in the control group experienced rehemorrhage 1 month after surgery and was readmitted to the hospital. The bleeding was controlled by nonsurgical treatment. All other surviving patients benefited from the operation, and no obvious changes of liver function were observed in either group during the observation period.

Peripheral Blood Cell Counts Before and 2 Weeks After Surgery*

Group	Erythrocytes, $\times 10^9/\mu\text{L}$		Leukocytes, $\times 10^3/\mu\text{L}$		Platelets, $\times 10^3/\mu\text{L}$	
	Preoperative	Postoperative	Preoperative	Postoperative	Preoperative	Postoperative
Autologous splenic transplantation	3.46 ± 0.78	3.82 ± 0.72	3.25 ± 1.27	$14.2 \pm 5.71^\dagger$	39.2 ± 22.6	$242 \pm 127^\dagger$
Control	3.76 ± 0.59	3.97 ± 0.59	3.07 ± 0.57	$10.9 \pm 4.13^\dagger$	47.1 ± 17.1	$269 \pm 140^\dagger$
P value		.61		.17		.67

*Data are presented as mean \pm SD (n = 10 per group).

$^\dagger P < .05$ as compared with preoperative value.

PERIPHERAL BLOOD CELL COUNTS

To evaluate the influence of autologous splenic transplantation on the correction of pancytopenia, we compared peripheral blood cell counts in both groups before and 2 weeks after transplantation (**Table**). As shown in the Table, leukopenia and a reduced platelet count were corrected in both groups 2 weeks after surgery, and there was no difference in terms of postoperative erythrocyte, leukocyte, and platelet counts between the 2 groups ($P > .05$).

DYNAMIC SCINTIGRAPHY OF TRANSPLANTED SPLENIC FRAGMENT

To visualize the transplanted splenic fragments, we used dynamic scintigraphy. Positive scanning of the splenic fragment was found in 4 cases from the autologous splenic transplantation group. Two patients showed positive scanning at 2 and 6 months postoperatively, and the other 2 did not show positive scanning until 8 months after surgery. As expected, no positive scanning was found in the control group. An example of a scintigram of a transplanted splenic fragment is shown in **Figure 1**.

SERUM TUFTSIN AND SERUM IgM LEVELS

The effects of the transplanted splenic fragments on host immune function were further assessed by serum tuftsin and IgM levels. Two months after surgery, serum tuftsin (**Figure 2**) and IgM (**Figure 3**) levels were markedly decreased in the control group as compared with the preoperative assessment ($P < .05$), whereas they remained unchanged in the splenic autotransplantation group ($P > .05$). In addition, although comparable preoperatively, serum tuftsin and IgM levels were significantly higher postoperatively in the splenic autotransplantation compared with the control group ($P < .05$). Within the splenic autotransplantation group, serum tuftsin and IgM levels were independent of the dynamic scintigraphy of splenic fragments (data not shown).

COMMENT

The spleen is an important organ of the immune system and has a prominent role in the generation of opsonins and IgM-specific antibodies.¹ Splenectomy induces a series of important alterations in the immune response, which may result in susceptibility to overwhelming post-splenectomy infection.^{3,12,13} This has led to the develop-

ment of alternative surgical techniques to preserve the spleen when possible. Autotransplantation of splenic fragments after splenectomy has been advocated as a method of retaining normal splenic immune function in the treatment of splenic trauma or splenomegaly caused by hematologic disorder.⁶⁻⁹ However, it is unclear whether preservation of splenic tissue with splenomegaly will be beneficial to the patients with portal hypertension and cirrhosis. The results of our randomized controlled study show that modified Sugiura surgery plus splenic autotransplantation is a safe procedure in patients with portal hypertension and cirrhosis. In the splenic autotransplantation group, 1 patient died of pulmonary failure at the sixth day after operation. However, as the pulmonary function of this patient had been poor before surgery, postoperative death could not be ascribed to the autotransplantation procedure. All other patients survived well without postoperative complications. Neither rehemorrhage, nor jaundice or ascites, occurred in the period of observation. Serum examination indicated no deterioration in liver function.

A difficulty within the current approach is deciding the appropriate assessment of immune function of transplanted splenic tissue. Among the indicators used to evaluate humoral immune function of the spleen, tuftsin is considered a sensitive marker. Since Najjar and Nishioka¹⁴ first discovered and characterized the natural phagocytosis-stimulating tetrapeptide tuftsin (threonine-lysine proline arginine) from IgG,¹⁴ it has been found that the circulating levels of tuftsin are reduced in hosts after splenectomy.¹⁵ Tuftsin has been demonstrated to increase phagocytosis of bacteria in vitro and to improve bacterial clearance and killing in vivo.¹⁶⁻¹⁸ Lower levels of tuftsin or its inhibition should thereby lead to a greater susceptibility to infections. Experimentally, tuftsin deficiency plays a role in postsplenectomy sepsis, and treatment with synthetic tuftsin protects the hosts after splenectomy against pneumococcal septic death.¹⁹ In our study, the levels of serum tuftsin decreased remarkably in the control group 2 months after surgery ($P < .05$), whereas concentrations remained stable in the splenic autotransplantation group ($P > .05$). These results indicate that splenic autotransplantation plays a role in preserving tuftsin activity after splenectomy. Interestingly, it has been shown that tuftsin activity correlates with the volume of reimplanted splenic tissue.²⁰ Some authors suggested that 30 to 100 g of splenic tissue should be reimplanted in the omentum after splenectomy in splenic trauma.^{7,21,22} However, the optimal mass of the transplanted splenic fragment to maintain tuftsin activity in

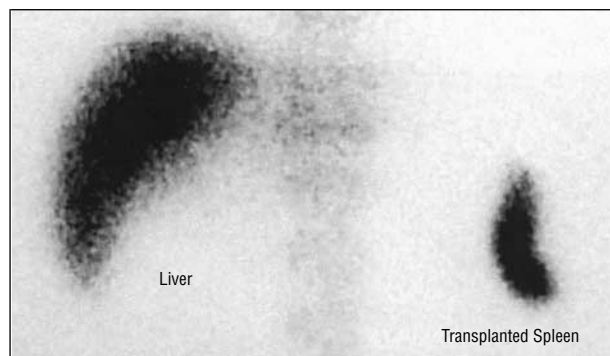


Figure 1. Scintigraphic scan of a transplanted splenic fragment 2 months after surgery with the use of technetium Tc 99m-labeled heat-damaged erythrocytes.

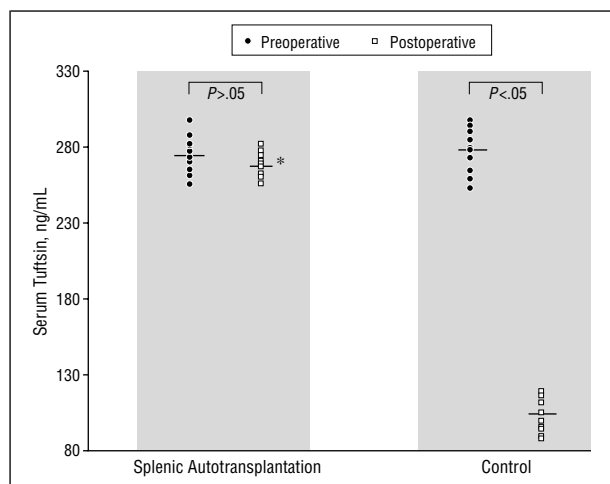


Figure 2. Serum tuftsin detection in splenic autotransplantation and control groups before and after surgery. The level bar denotes the median value of the group. Asterisk indicates a significant difference ($P < .001$) in comparison with the control group.

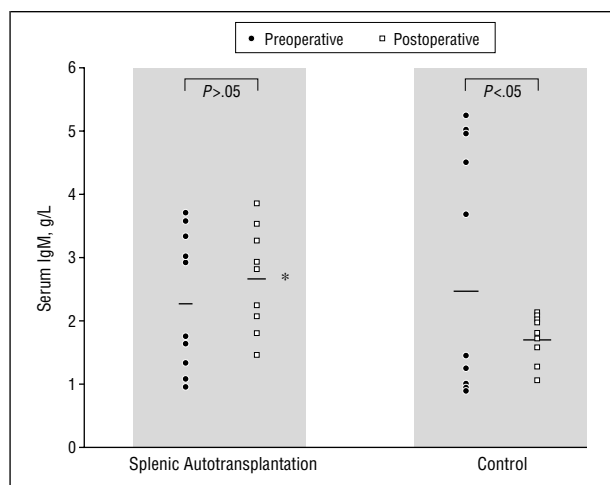


Figure 3. Serum IgM detection in splenic autotransplantation and control groups before and after surgery. The level bar denotes the median value of the group. Asterisk indicates a significant difference ($P = .02$) in comparison with the control group.

humans remains unknown. On the basis of our results, it appears that a 35-cm³ volume of transplanted splenic tissue can preserve tuftsin activity in patients with portal hypertension and cirrhosis after splenectomy.

The spleen is also the site of IgM production. Splenectomy leads to a reduction of IgM in peripheral blood.³ In clinical trials, splenic autotransplantation maintains normal IgM levels after splenectomy.^{6,23} Similarly, in our study, the levels of serum IgM significantly decreased in the splenectomy group after operation, whereas levels remained normal in the autotransplantation group. These data demonstrate that splenic autotransplantation can help maintain normal humoral immune function.

Dynamic scintigraphy with heat-damaged radioisotope-labeled erythrocytes aids visualization of transplanted splenic fragments and seems superior to the use of isotope-labeled colloid, as the isotope uptake by the spleen was constantly higher than uptake by the liver.¹¹ In our study, we detected the transplanted splenic tissue with ^{99m}Tc-labeled heat-damaged erythrocytes. Radioisotope scans demonstrated functional splenic tissue in 4 of the 9 patients who received autotransplants. The relatively low positive scintigraphy rate may be explained by the following facts. First, vascularization of the postperitoneum region, although high in portal hypertension, differs among individuals, and scintigraphy with radioisotope-labeled erythrocytes relies on high vascularization because of its low sensitivity. Hence, those with relatively poor vascularization in this region may not show positive scanning. Additionally, the degree of heat damage of the red blood cell membrane is crucial for positive scanning, as an excess may result in overt hemolysis, whereas too little will prevent sufficient trapping of the labeled cells in the splenic tissue. Both cases may also contribute to the low rate of positive results of scintigraphy of the transplanted splenic tissue in the present study. However, serum tuftsin and IgM levels, which reflect the immune function of the transplanted splenic fragments, did not differ in reference to the scintigraphy, indicating that scintigraphy of the splenic fragments did not represent the immune function of the splenic tissue.

In conclusion, modified Sugiura surgery plus splenic autotransplantation can preserve partial immune function of the spleen in patients with portal hypertension and cirrhosis. As a caveat, this randomized controlled study of 20 cases requires further investigation and more experience so as to establish the surgical procedure.

We thank Karl J. Oldhafer, MD, at University Hospital Essen, Essen, Germany, for his helpful suggestions and discussion in preparing the manuscript.

Corresponding author: Hongwei Zhang, MD, c/o Gernot M. Kaiser, MD, Department of General Surgery and Transplantation, University Hospital Essen, Hufeland Str 55, 45122 Essen, Germany (e-mail: hongweizhang67@hotmail.com).

REFERENCES

1. Lockwood CM. Immunological functions of the spleen. *Clin Haematol*. 1983;12:449-465.
2. Bohnsack JF, Brown EJ. The role of the spleen in resistance to infection. *Annu Rev Med*. 1986;37:49-59.
3. Timens W, Leemans R. Splenic autotransplantation and the immune system: adequate testing required for evaluation of effect. *Ann Surg*. 1992;215:256-260.

4. Deodhar HA, Marshall RJ, Barnes JN. Increased risk of sepsis after splenectomy. *BMJ*. 1993;307:1408-1409.
5. Martin LW. Autologous splenic transplantation. *Ann Surg*. 1994;219:223-224.
6. Patel J, Williams JS, Shmigel B, Hinshaw JR. Preservation of splenic function by autotransplantation of traumatized spleen in man. *Surgery*. 1981;90:683-688.
7. Mizrahi S, Bickel A, Haj M, Lunski I, Shtamler B. Posttraumatic autotransplantation of spleen tissue. *Arch Surg*. 1989;124:863-865.
8. Leemans R, Manson W, Snijder JA, et al. Immune response capacity after human splenic autotransplantation: restoration of response to individual pneumococcal vaccine subtypes. *Ann Surg*. 1999;229:279-285.
9. Leemans R, Harms G, Rijkers GT, Timens W. Spleen autotransplantation provides restoration of functional splenic lymphoid compartments and improves the humoral immune response to pneumococcal polysaccharide vaccine. *Clin Exp Immunol*. 1999;117:596-604.
10. Naim JO, Desiderio DM, Trimble J, Hinshaw JR. The identification of serum tuftsin by reverse-phase high-performance liquid chromatography and mass spectrometry. *Anal Biochem*. 1987;164:221-226.
11. Nielsen JL, Ellegaard J, Marqversen J, Hansen HH. Detection of splenosis and ectopic spleen with ^{99m}Tc-labelled heat damaged autologous erythrocytes in 90 splenectomized patients. *Scand J Haematol*. 1981;27:51-56.
12. Corazza GR, Zoli G, Massai G, Mule P, Beltrandi E, Gasbarrini G. Changes in peripheral blood lymphocytes and immune complexes in splenectomized patients: lack of correlation with residual splenic function. *J Clin Lab Immunol*. 1990;31:33-38.
13. Liende M, Santiago-Delpin EA, Lavergne J. Immunobiological consequences of splenectomy: a review. *J Surg Res*. 1986;40:85-94.
14. Najjar VA, Nishioka K. "Tuftsin": a natural phagocytosis stimulating peptide. *Nature*. 1970;228:672-673.
15. Krivit W, Giebink GS, Leonard A. Overwhelming postsplenectomy infection. *Surg Clin North Am*. 1979;59:223-233.
16. Najjar VA. Biological and biochemical characteristics of the tetrapeptide tuftsin, Thr-Lys-Pro-Arg. *Adv Exp Med Biol*. 1979;121:131-147.
17. Baker CC, Chaudry IH, Gaines HO, Baue AE. Evaluation of factors affecting mortality rate after sepsis in a murine cecal ligation and puncture model. *Surgery*. 1983;94:331-335.
18. Martinez J, Winternitz F. Bactericidal activity of tuftsin. *Mol Cell Biochem*. 1981;41:123-136.
19. Chu DZ, Nishioka K, El-Hagin T, Hopfer R, Romsdahl MM. Effects of tuftsin on postsplenectomy sepsis. *Surgery*. 1985;97:701-706.
20. Zoli G, Corazza GR, D'Amato G, Bartoli R, Baldoni F, Gasbarrini G. Splenic autotransplantation after splenectomy: tuftsin activity correlates with residual splenic function. *Br J Surg*. 1994;81:716-718.
21. Durig M, Landmann RM, Harder F. Lymphocyte subsets in human peripheral blood after splenectomy and autotransplantation of splenic tissue. *J Lab Clin Med*. 1984;104:110-115.
22. Nicholson S, Hutchinson GH, Hawkins T, Venables CW. Successful splenosis following autologous splenic implantation. *J R Coll Surg Edinb*. 1986;31:67-71.
23. Moore FA, Moore EE, Moore GE, Millikan JS. Risk of splenic salvage after trauma: analysis of 200 adults. *Am J Surg*. 1984;148:800-805.