

# The Value of Color Flow Doppler Ultrasonography of the Superior Thyroid Artery in the Surgical Management of Graves Disease

Shih-Ming Huang, MD; Nan-Haw Chow, MD; Hwei-Ling Lee, PhD; Ta-Jen Wu, MD

**Hypothesis:** The factors affecting blood flow within the hypervascular thyroid gland and the effect of vascularization on the preparation for thyroidectomy as treatment for Graves disease can be documented.

**Design:** Blood flow through the superior thyroid arteries of patients with Graves disease, maintained in a euthyroid status, was measured by color flow Doppler ultrasonography. The microvessel density was assessed immunohistochemically using the level of expression of factor VIII in tissue sections. Both the thyroid gland's weight and blood loss volume were measured during the operation.

**Setting:** Tertiary care teaching hospital.

**Patients:** Fifty-two patients with Graves disease undergoing thyroidectomy.

**Results:** The blood flow rate was significantly correlated with thyroid weight ( $P < .01$ ), thyroid microvessel density ( $P < .001$ ), and histopathologic microscopic pat-

tern ( $P < .001$ ). The relation between these factors could be expressed as follows: Blood flow (mL/min) =  $\{[0.0158 + 0.00136] \times (\text{weight (g)} \times \text{microvessel density})\}^{1/2}$  ( $R^2 = 0.64$ ,  $P < .001$ ). Diffuse microfollicular hyperplastic thyroid tissue had a significantly higher blood flow and vascular density than tissue having an inactive colloid pattern ( $P < .01$ ). Ten patients having a blood loss exceeding 200 mL during thyroidectomy showed a higher preoperative blood flow rate and microvessel density ( $P < .01$ ). Of 8 patients whose blood flow was more than 0.15 L/min, 6 (75%) had blood loss in excess of 200 mL during surgery.

**Conclusions:** The blood flow of the superior thyroid artery is positively related to intrathyroid microvessel density, glandular weight, and histopathologic microscopic pattern. Preoperative color flow Doppler ultrasonography may help in identifying patients with Graves disease who are liable to bleed intraoperatively during thyroidectomy.

*Arch Surg.* 2003;138:146-151

From the Department of Endocrine Surgery, Buddhist Tzu Chi University Hospital, Hualien, Taiwan (Dr Huang), the Departments of Pathology (Dr Chow) and Internal Medicine (Dr Wu), College of Medicine, and the Department of Public Health (Dr Lee), National Cheng Kung University Hospital, Tainan, Taiwan.

THE DEGREE of vascularization was widely applied in various physiological and pathologic conditions such as diabetic retinopathy, tumor formation, and autoimmune diseases.<sup>1,2</sup> Although the histopathologic microvessel density (MD) using an immunohistochemical technique is the current "gold standard" to characterize vascularization,<sup>2</sup> it may not be the ideal tool for clinical purposes because it needs to be performed on biopsy specimens. Noninvasive assessment of vascularity is possible in vivo using color flow Doppler ultrasonography (CFDS), dynamic contrast-enhanced magnetic resonance imaging, and positron emission tomography.<sup>3-6</sup> These methods may be preferable to histological assay because they are noninvasive, survey the entire organ, reflect

both anatomical and physiologic characteristics, and may be useful to monitor the treatment.

## See Invited Critique at end of article

With CFDS in vivo vascularity can be assessed rapidly and noninvasively. The technique has been successfully applied in distinguishing between the vascularity in benign and malignant tumors<sup>7</sup> and in correlating the biological properties of human cancer.<sup>8</sup> Various thyroid disorders, including Graves disease, can modify thyroid blood flow, which was conspicuously correlated with levels of free triiodothyronine<sup>9</sup> and iodine uptake.<sup>10</sup> Color flow Doppler ultrasonography has found higher intrathyroidal blood flow<sup>11-14</sup> and in

creased peak systolic velocity<sup>11</sup> and blood velocity<sup>14</sup> in patients with Graves disease. The aims of the present study were to examine the factors affecting blood flow through the hypervascular thyroid glands of patients with Graves disease to determine the usefulness of CFDS in determining blood flow in diseased thyroid glands, and to evaluate the value of this assessment in the management of patients with Graves disease.

## METHODS

### PATIENTS

A total of 52 patients (3 men and 49 women; age range, 19-43 years; mean age, 30.5 years) with Graves disease were enrolled in this prospective study between June 1, 1999, and December 31, 2000. In all cases, the diagnosis was based on the usual clinical criteria and laboratory test results of the following: free thyroxine level, triiodothyronine level, thyrotropin level, thyrotropin-receptor autoantibody level, and anti-thyroid peroxidase antibody level.


### PROCEDURE

The standard treatment protocol was as follows: all patients received methimazole and propranolol hydrochloride (Inderal) preoperatively. Patients received surgical intervention when euthyroidism had been achieved. Color flow Doppler ultrasonography (SSA-340A; Toshiba, Tochigi-ken, Japan) using a 10-MHz linear transducer was done for all patients in the morning of the operative day. Fifty-two age- and sex-matched healthy medical staff volunteers were also measured using CFDS; they served as healthy control subjects. The superior thyroid artery on each side of the neck was located first, then measurements of the time-averaged blood velocity, vessel diameter, and the angle between the ultrasound beam and vessel axis were taken and entered into the computer that then calculated the blood flow rate of the superior thyroid artery in milliliters per minute.

The operative procedure (total thyroidectomy of 1 lobe together with subtotal thyroidectomy of the other) was performed by the same surgeon (S.-M.H.). The weight of the resected gland was measured during operation. Three grams of thyroid remnant, estimated by using 3 g of weighed tissue from the contralateral resected thyroid, was preserved in situ. The total weight of the thyroid gland was the weight of resected gland plus 3 g. The volume of blood loss (expressed in milliliters), measured as the amount of blood in the suction bottle and absorbed by the gauze, was recorded for each patient.

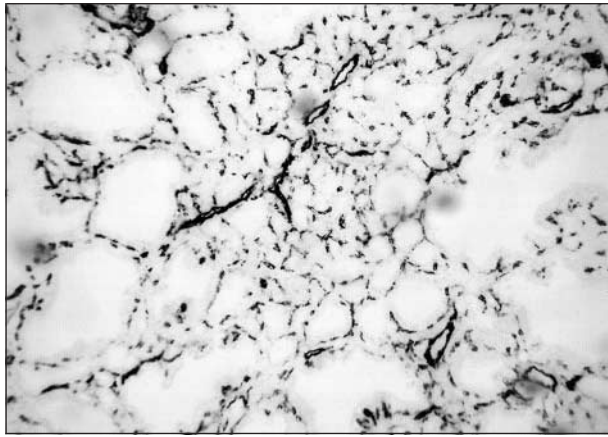
Thyroid gland specimens were examined by 1 of us (N.-H.C.) without knowledge of the CFDS findings. The histopathologic changes were classified into 3 types of microscopic pattern. Those cases having apparent diffuse microfollicular hyperplastic follicles were categorized histopathologically as the compact pattern (**Figure 1A**); the colloid pattern (**Figure 1B**) was composed predominantly of cystically dilated follicles with flattened epithelial lining; and the mixed pattern (**Figure 1C**) was composed of the compact and colloid patterns.

The MD was assessed by immunohistochemical expression of factor VIII in thyroid biopsy specimens because it correlates well with patient outcome and it is comparable with immunohistochemical expression of the CD34 molecule.<sup>15</sup> Immunohistochemical staining was performed as described in detail by Yamamoto et al.<sup>15</sup> Briefly, monoclonal anti-factor VIII antibody (diluted 1:100; Calbiochem, Cambridge, Mass) was incubated with thyroid gland tissue. Sections were washed for 5 minutes with a buffered-saline solution followed by incubation

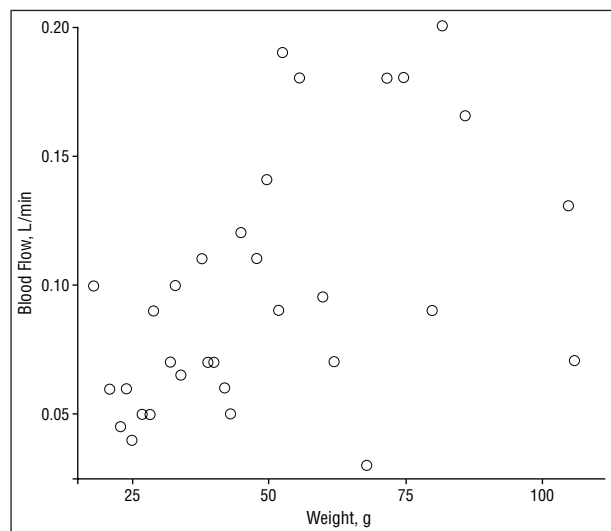


**Figure 1.** Histopathologic features of the thyroid gland from patients with Graves disease showing the compact pattern (A), which consists of diffuse microfollicular hyperplastic follicles; the colloid pattern (B), which consists predominantly of cystically dilated follicles with flattened epithelial lining; and the mixed pattern (C), which consists of the combined compact and colloid patterns (hematoxylin-eosin, original magnification  $\times 100$ ).

with 3% hydrogen peroxide at room temperature. Then the sections were covered with 3% normal horse serum for 15 minutes. Next, the second antibody was incubated with these sections at 4°C overnight. A commercially available kit (LSAB2; Dako Co, Carpinteria, Calif) was used to detect the immune complex, and the activity was visualized using the aminoethyl carbazole substrate solution kit (Zymed Laboratory, Inc, San Francisco, Calif) according to the manufacturer's directions. Finally, sections were counterstained with hematoxylin-eosin. Negative control sections were incubated with nonimmune rabbit IgG instead of primary antibody. The number of



**Figure 2.** Thyroid gland section immunohistochemically stained by the avidin-biotin complex method with anti-factor VIII revealing microvessels with intensely stained endothelial cell cytoplasm (original magnification  $\times 100$ ).



**Figure 3.** Relationship between blood flow and the weight of the thyroid gland in Graves disease. The blood flow rate was positively correlated with thyroid weight ( $P=.03$ , Pearson product moment correlation).

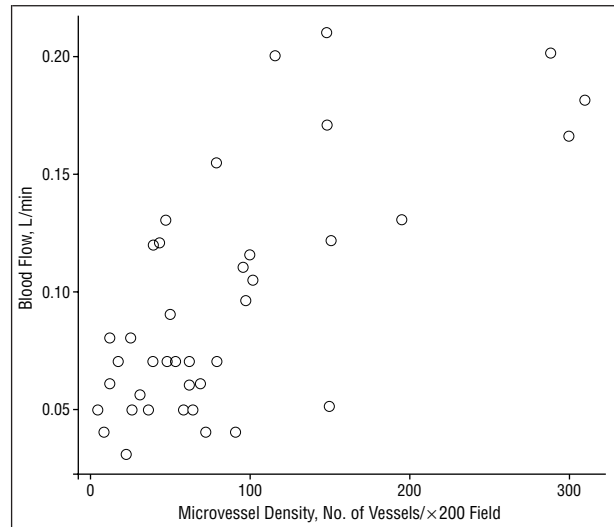
microvessels highlighted by factor VIII expression was counted in a total of 20 high-power fields (or entire slide) for each patient. The density of positive staining (vessels per high-power field [ $\times 200$ ]) was determined from the total vessel numbers divided by the number of high-power fields (**Figure 2**).

#### STATISTICAL ANALYSIS

Results were analyzed by 1-way analysis of variance (ANOVA), 2-sample  $t$  test ANOVA, regression analysis, and the Pearson product moment correlation. All values are expressed as mean (SD).

#### RESULTS

The blood flow rate of the superior thyroid artery of patients with Graves disease is significantly higher than that of the healthy controls (97.5 [52.7] mL/min vs 20.1 [5.7] mL/min,  $P<.001$ ). In Graves disease, blood flow rate was positively correlated with thyroid gland weight (**Figure 3**,  $P=.03$ ) or MD (**Figure 4**,  $P<.01$ ) using the Pearson prod-



**Figure 4.** Relationship between blood flow and microvessel density in Graves disease. The blood flow rate shows a positive correlation with microvessel density ( $P<.01$ , Pearson product moment correlation).

uct moment correlation. Regression analysis was performed on the relation expressed as follows:

$$\text{Blood Flow (mL/min)} = \{[0.0158 + 0.00136] \times (\text{Weight [g]} \times \text{MD})^{1/2}\} \\ (R^2=0.64, P<.001).$$

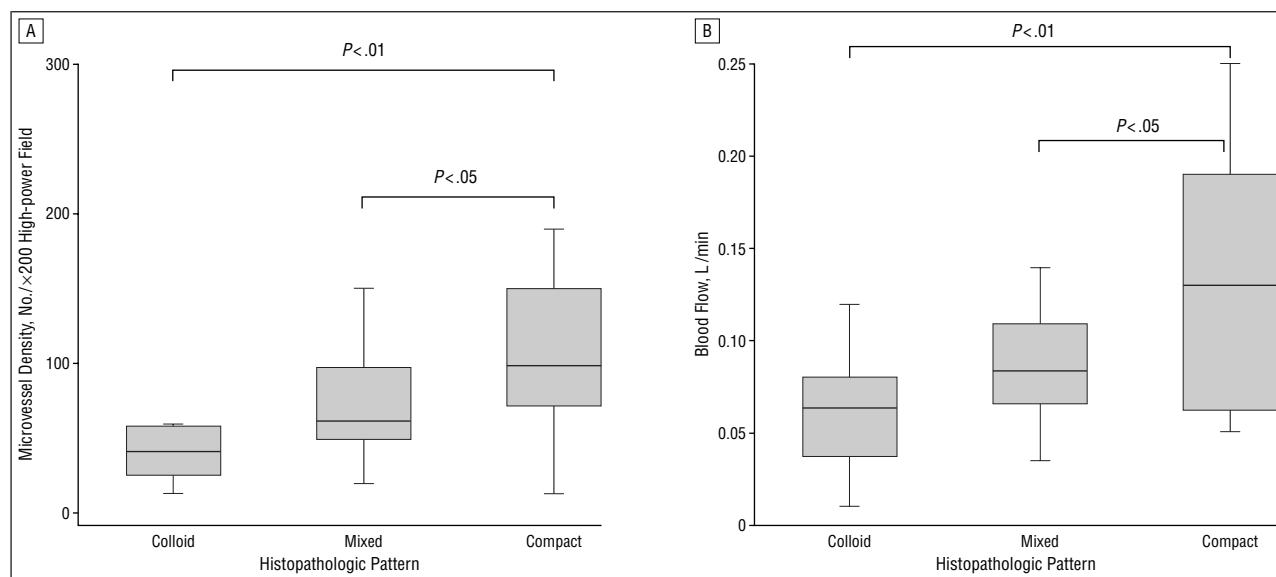
Histopathologic change and vascularization were examined only in the surgical specimens from patients with Graves disease; wide variation was noted in each case. Microvessel density showed a positive correlation with histopathologic patterns ( $P<.01$ ) by ANOVA. The relationship of histopathologic pattern distribution to MD and blood flow are shown in **Figure 5**. Diffuse hyperplastic thyroid tissue (compact pattern) had significantly higher vascular density and blood flow than did either of the other 2 types.

Interestingly, 10 patients having a blood loss exceeding 200 mL during thyroidectomy showed a higher preoperative blood flow rate (**Figure 6**) and vascular density (**Figure 7**) ( $P<.01$ ) than those with less blood loss ( $n=42$ ). Of the 8 patients whose blood flow was more than 0.15 L/min, 6 (75%) had a blood loss exceeding 200 mL during surgery and 1 patient who had a 1000-mL blood loss needed a blood transfusion (**Figure 8**).

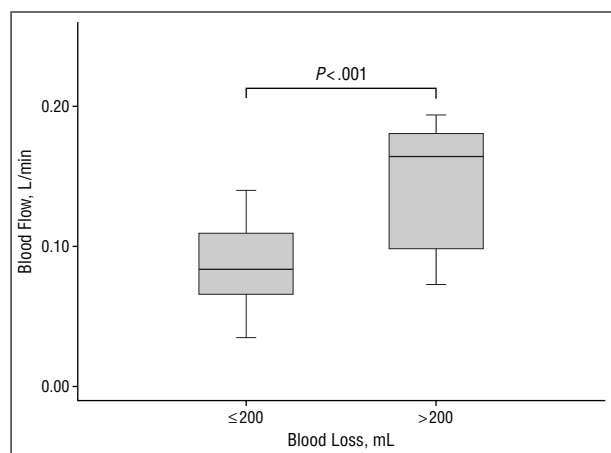
#### COMMENT

Graves disease is a genetically determined autoimmune disorder characterized by hyperthyroidism. The laboratory diagnosis is based on the finding of high levels of serum thyroid hormones and undetectable serum thyrotropin associated with circulating antibodies to thyrotropin receptor and thyroperoxidase. Untreated patients have a hypervascular gland accompanied by bruit and thrill. Consistent with this notion are prior reports<sup>11-14</sup> in which higher intrathyroidal blood flow and increased peak systolic velocity were detected in association with Graves disease using CFDS. The present study

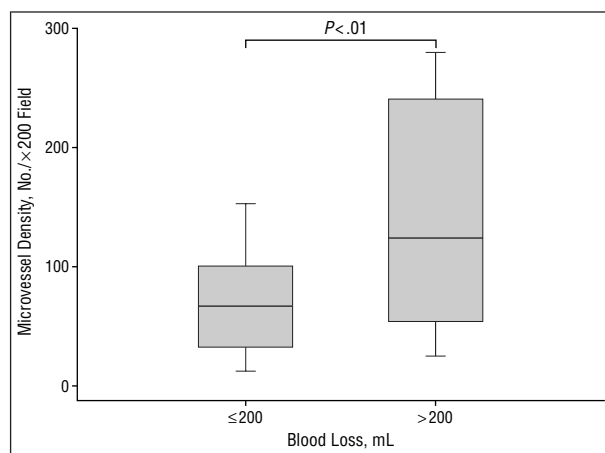




**Figure 5.** A, The association of microvessel density with thyroid gland histopathologic features. The compact pattern thyroid tissue (n=19) had a significantly higher vascular density than that of either the colloid pattern (n=10,  $P<.01$ ) or the mixed pattern (n=23,  $P<.05$ ). Box plot of the microvessel density shows the median (horizontal line in the bar). The lower and upper ends of the shaded bars indicate first and third quartiles, respectively; the lower and upper portions, minimum and maximum, respectively. B, Relationship between blood flow in and thyroid gland histopathologic features. The compact pattern thyroid tissue (n=19) had a significantly higher blood flow rate than that of either the colloid pattern (n=10,  $P<.01$ ) or the mixed pattern (n=23,  $P<.05$ ). Box plot of the blood flow shows the median (horizontal line in the bar). The lower and upper ends of the shaded bars indicate first and third quartiles, respectively; the lower and upper portions, minimum and maximum, respectively.



**Figure 6.** Comparison of preoperative blood flow with the intraoperative blood loss. Patients having blood loss exceeding 200 mL during thyroidectomy (n=10) had a higher preoperative blood flow rate than those with blood loss less than 200 mL (n=42,  $P<.001$ ). Box plot of blood flow shows the median (horizontal line in the bar). The lower and upper portions of the I bars indicate first and third quartiles, respectively; the lower and upper ends of the I bars, minimum and maximum, respectively.



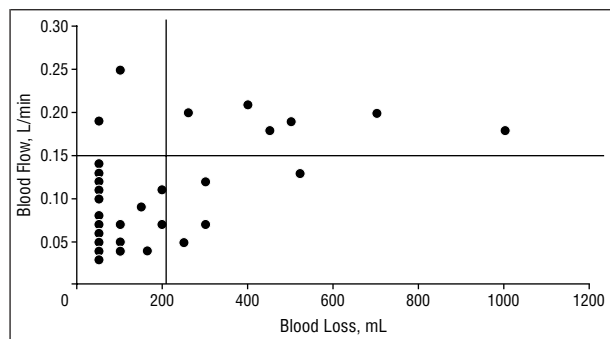
**Figure 7.** Relationship between microvessel density and intraoperative blood. Patients having blood loss exceeding 200 mL during thyroidectomy (n=10) had a higher vascular density than those with blood loss less than 200 mL (n=42,  $P<.01$ ). Box plot of microvessel density shows the median (horizontal line in the bar). The lower and upper portions of the I bars indicate first and third quartiles, respectively; the lower and upper portions of the I bars, minimum and maximum, respectively.

of the blood flow of the superior thyroid artery and intrathyroid MD further supports this concept.

Previous studies reported that thyroid artery blood flow correlated remarkably with the levels of free triiodothyronine,<sup>9</sup> whereas others did not find a correlation between CFDS findings and serum thyroid hormone levels.<sup>14</sup> We found that CFDS-monitored blood flow through the superior thyroid artery was associated with intrathyroid MD, as Castagnone et al<sup>12</sup> previously reported. Of particular interest was the significant correlation between blood flow rate and histopathologic microscopic patterns. The blood flow rates on CFDS

were higher in those with persistent hyperplastic histopathologic conditions than in patients with changes in thyroid colloid. This finding is similar to observations noted by Nagura et al<sup>2</sup> and Morosini et al.<sup>16</sup> Nagura et al<sup>2</sup> and Iitaka et al<sup>3</sup> found that increasing vascular density positively correlated with vascular endothelial growth factor expression in hyperplastic follicular cells and serum vascular endothelial growth factor levels, respectively. Those findings may support the association of angiogenesis with disease activity of Graves disease.

Both the histopathologic features of the thyroid gland and vascular density differed considerably even



**Figure 8.** The distribution of preoperative blood flow in relation to intraoperative blood loss. Of 8 patients whose blood flow was over 0.15 L/min (horizontal line indicates 0.15 L/min), 6 patients (75%) had blood loss exceeding 200 mL during thyroidectomy (right upper quadrant).

though euthyroidism had been achieved. The findings seem to imply that a mechanism, other than the protirelin-thyrotropin-thyroxine-axis, is functioning during the development of follicular hyperplasia and increased vascularity of Graves disease. Although Castagnone et al<sup>12</sup> found that those with higher blood flow (in Graves disease remission due to antithyroid drug therapy) had a higher rate of recurrence, hyperthyroidism has not recurred in our patients so far, irrespective of the histopathologic condition of the thyroid gland and blood flow. Nonrecurrence might be explained by the relatively small size of the remnant tissue (3 g).

Both surgical dissection and hemostasis are 2 major concerns for surgeons during thyroidectomy. Graves disease is characterized histologically by thyroid friability and vascularization. We found that patients with a higher preoperative blood flow (>150 mL/min) are at risk of intraoperative blood loss exceeding 200 mL. The result seems rational since the bleeding rate from cut vessels can be expected to increase when blood flow is higher. The oozing increases when the MD is higher. Although radioiodine therapy is the most common treatment for Graves disease and surgery has become uncommon in the United States, recent articles<sup>17,18</sup> have emphasized the advantages of surgery; moreover, surgery still plays an important role in Asia and Europe.<sup>19,20</sup> If surgery is indicated for treatment of Graves disease, our findings suggest that preoperative CFDS may be useful in the preoperative assessment of intraoperative bleeding and in identifying patients who should undergo preoperative autodonation of blood or be cross-matched for banked blood in this era of limited elective blood supply.

Chang et al<sup>21</sup> directly demonstrated that blood flow in patients with Graves disease was reduced within the superior thyroid arteries after administering Lugol potassium iodide solution. Ansaldo et al<sup>22</sup> also revealed a decrease in arterial resistance after administering Lugol potassium iodide solution. Because of the bleeding risks associated with cutting and dissection for such a hypervascular disorder, the routine preoperative use of Lugol potassium iodine solution is recommended for all patients with Graves disease; furthermore, the use of more sophisticated hemostatic instruments, such as bipolar or ultrasonic cauterization,<sup>23,24</sup> is also a rational approach, especially for those patients with higher superior thyroid artery blood flows.

## CONCLUSIONS

We demonstrate that the blood flow through the superior thyroid artery positively correlates with intrathyroid MD, glandular weight, and the histopathologic microscopic pattern. Patients with diffuse hyperplastic glands or who have more blood loss during thyroidectomy have significantly higher blood flow and higher MD. Preoperative CFDS may aid in identifying those patients who are liable to bleed intraoperatively during thyroidectomy.

Accepted for publication October 5, 2002.

Corresponding author and reprints: Shih-Ming Huang, MD, Department of Endocrine Surgery, Buddhist Tzu Chi General Hospital and Tzu Chi University, 707, Chung Yan Rd, Section 3, Hualien, Taiwan (e-mail: smhuang@mail.tcu.edu.tw).

## REFERENCES

1. Folkman J. Angiogenesis in cancer, vascular, rheumatoid and other disease. *Nature Med.* 1995;1:27-31.
2. Nagura S, Katoh R, Miyagi E, Shibuya M, Kawaoi A. Expression of vascular endothelial growth factor (VEGF) and VEGF receptor-1 (Flt-1) in Graves disease possibly correlated with increased vascular density. *Hum Pathol.* 2001;32:10-17.
3. Iitaka M, Miura S, Yamanaka K, et al. Increase serum vascular endothelial growth factor levels and intrathyroid vascular area in patients with Graves' disease and Hashimoto's thyroiditis. *J Clin Endocrinol Metab.* 1998;83:3908-3912.
4. Koda M, Murawaki Y, Kawasaki H. Renovascular resistance assessed by color Doppler ultrasonography in patients with chronic liver disease. *J Gastroenterol Hepatol.* 2000;15:1424-1429.
5. Grandin CB, Duprez TP, Smith AM, et al. Usefulness of magnetic resonance-derived quantitative measurements of cerebral blood flow and volume in prediction of infarct growth in hyperacute stroke. *Stroke.* 2001;32:1147-1153.
6. Constant EL, de Volder AG, Ivanoiu A, et al. Cerebral blood flow and glucose metabolism in hypothyroidism: a positron emission tomography study. *J Clin Endocrinol Metab.* 2001;86:3864-3870.
7. Emoto M, Iwasaki H, Mimura K, Kawarabayashi T, Kikuchi M. Differences in the angiogenesis of benign and malignant ovarian tumors, demonstrated by analyses of color Doppler ultrasound, immunohistochemistry, and microvessel density. *Cancer.* 1997;80:899-907.
8. Cheng WF, Lee CN, Chu JS, et al. Vascularity index as a novel parameter for the in vivo assessment of angiogenesis in patients with cervical carcinoma. *Cancer.* 1999;85:651-657.
9. Hodgson KJ, Lazarus JH, Wheeler MH, et al. Duplex scan-derived thyroid blood flow in euthyroid and hyperthyroid patients. *World J Surg.* 1988;12:470-475.
10. Arntzenius AB, Smit LJ, Schipper J, van der Heide D, Meinders AE. Inverse relation between iodine intake and thyroid blood flow: color Doppler flow imaging in euthyroid humans. *J Clin Endocrinol Metab.* 1991;73:1051-1055.
11. Ralls PW, Mayekawa DS, Lee KP, et al. Color-flow Doppler sonography in Graves' disease: "thyroid inferno." *AJR Am J Roentgenol.* 1988;150:781-784.
12. Castagnone D, Rivolta R, Rescalli S, Baldini MI, Tozzi R, Cantalamessa L. Color Doppler sonography in Graves' disease: value in assessing activity of disease and predicting outcome. *AJR Am J Roentgenol.* 1996;166:203-207.
13. Bogazzi F, Bartalena L, Brogioni S, et al. Color flow doppler sonography rapidly differentiates type I and type II amiodarone-induced thyrotoxicosis. *Thyroid.* 1997;7:541-545.
14. Bogazzi F, Bartalena L, Brogioni S, et al. Thyroid vascularity and blood flow are not dependent on serum thyroid hormone levels: studies in vivo by color flow Doppler sonography. *Eur J Endocrinol.* 1999;140:452-456.
15. Yamamoto A, Dhar DK, El-Assal ON, Igarashi M, Tabara H, Nagasue N. Thymidine phosphorylase (platelet-derived endothelial cell growth factor), microvessel density and clinical outcome in hepatocellular carcinoma. *J Hepatol.* 1998;29:290-299.
16. Morosini PP, Simonella G, Mancini V, et al. Color Doppler sonography patterns related to histological findings in Graves' disease. *Thyroid.* 1998;8:577-582.
17. Alsanea O, Clark OH. Treatment of Graves' disease: the advantages of surgery. *Endocrinol Metab Clin North Am.* 2000;29:321-337.
18. Soreide JA, van Heerden JA, Lo CY, Grant CS, Zimmerman D, Ilstrup DM. Surgical treatment of Graves' disease in patients younger than 18 years. *World J Surg.* 1996;20:794-799.
19. Miccoli P, Vitti P, Rago T, et al. Surgical treatment of Graves' disease: subtotal or total thyroidectomy? *Surgery.* 1996;120:1020-1024.
20. Yamashita H, Murakami T, Nouguchi S, et al. Postoperative tetany in Graves' disease: important role of vitamin D metabolites. *Ann Surg.* 1999;229:237-245.
21. Chang DC, Wheeler MH, Woodcock JP, et al. The effect of preoperative Lugol's iodine on thyroid blood flow in patients with Graves' hyperthyroidism. *Surgery.* 1987;102:1055-1061.
22. Ansaldo GL, Pretolesi F, Varaldo E, et al. Doppler evaluation of intrathyroid ar-

- terial resistances during preoperative treatment with Lugol's iodide solution in patients with diffuse toxic goiter. *J Am Coll Surg*. 2000;191:607-612.
23. Yoshida H, Wu MH, Kouchi Y, Onuki Y, Shi Q, Sauvage LR. Comparison of the effect of monopolar and bipolar cauterization on skeletonized, dissected internal thoracic arteries. *J Thorac Cardiovasc Surg*. 1995;110:504-510.
24. Barret E, Guillonnet B, Cathelineau X, Validire P, Vallancien G. Laparoscopic partial nephrectomy in the pig: comparison of three hemostasis techniques. *J Endourol*. 2001;15:307-312.

### Invited Critique

Surgery for Graves disease, which was once widely practiced in North America, has become rather uncommon. Because even women of child-bearing age and children are often treated with radioiodine, the current indications for thyroidectomy in Graves disease are limited to the following: patients who have failed antithyroid drug or radioiodine treatment, those who require a rapid and definitive reversal of hyperthyroidism (eg, during pregnancy), or those who have an aversion to irradiation. Finally, thyroidectomy should be used in patients who have Graves disease with a concomitant thyroid nodule that should be removed to rule out a potential malignancy. The shift to radioiodine therapy has occurred because it is less expensive, less invasive, and relatively safe: avoiding the main surgical complications of hyperparathyroidism and recurrent laryngeal nerve injury. Clearly, Huang et al have experience in treating Graves disease that is unmatched by any endocrine surgeon in North America. The ability of Huang and coworkers to amass 52 patients in a 7-month period indicates a major philosophical difference in the management of Graves disease in Asia.

From this large experience, we can learn that thyroidectomy in experienced hands remains a safe and effective therapy for Graves disease. In addition, the vascularity that will be encountered during thyroidectomy can be predicted preoperatively. The noninvasive techniques that can estimate thyroid blood flow include dynamic contrast-enhanced magnetic resonance imaging, positron emission tomography, and CFDS. Color flow Doppler ultrasonography is less expensive and more widely available. The question remains if it is more accurate and, more importantly, if it is reproducible at centers that do not have such a large experience with this radiologic test. This is critical because of the user dependence of CFDS.

Huang et al showed that blood loss exceeding 200 mL during thyroidectomy can be predicted by higher preoperative blood flow in the superior thyroid artery ( $>0.15$  L/min). They suggest this information can identify the need for preoperative autologous blood donation or cross-matching of banked blood. It seems to us that this information could be better used to identify patients who would benefit from preoperative measures to decrease their thyroid blood flow. We routinely pre-treat patients who have Graves disease using Lugol potassium iodide solution. Huang et al used only methimazole and propranolol hydrochloride. Perhaps, there is a difference between biochemical preparation in which thyroid function tests are normalized, and physiologic preparation in which thyroid blood flow is actually decreased. Huang et al can answer this question by adding Lugol potassium iodide solution to their routine preoperative preparation and analyzing blood flow with CFDS before and during the administration of the Lugol potassium iodide solution to see if thyroid blood flow can be reduced to a safer level.

Scott M. Wilhelm, MD  
Richard A. Prinz, MD  
Chicago, Ill