

Neuroendocrine Tumors of the Ampulla of Vater

Biological Behavior and Surgical Management

Jonathan T. Carter, MD; James P. Grenert, MD; Laura Rubenstein, BA; Lygia Stewart, MD; Lawrence W. Way, MD

Objectives: To describe the biological behavior and surgical management of ampullary neuroendocrine tumors in 7 patients.

Design: Case series and literature review.

Setting: University hospital.

Patients: Seven patients with ampullary neuroendocrine tumors.

Main Outcome Measures: Clinical presentation, pathologic findings, and survival.

Results: The patients presented with jaundice (3 patients), anemia (1 patient), gastric outlet obstruction (1 patient), or incidental discovery (2 patients). No patients had neurofibromatosis. Preoperative biopsy was diagnostic in 5 of 6 patients. All of the tumors expressed chromogranin and synaptophysin. Even when the tumor expressed gastrin, vasoactive intestinal peptide, or somatostatin, no patient had a hypersecretion syndrome. Five patients were treated by pancreaticoduode-

nectomy, 4 for low-grade neuroendocrine tumors and 1 for high-grade neuroendocrine carcinoma. The lesions measured 1.0 to 3.5 cm in diameter. Computed tomographic scans failed to detect nodal metastases that were present in 4 patients. One patient with a high-grade malignant neoplasm died after 15 months. The rest were disease-free after 19 to 48 months. Two patients had transduodenal local resections, one for a 1.1-cm paraganglioma (disease-free, 11 years) and the other for a 0.6-cm carcinoid tumor (disease-free, 7 months).

Conclusions: This is one of the largest series of neuroendocrine tumors of the ampulla. Preoperative biopsy was accurate, but computed tomographic scans were insensitive in detecting nodal metastases. Unlike duodenal carcinoid tumors, hypersecretion syndromes were absent and small tumor size did not preclude locoregional metastases. Tumor grade predicted survival. We recommend pancreaticoduodenectomy for this disease, with local resection reserved for mobile, superficial lesions.

Arch Surg. 2009;144(6):527-531

NEUROENDOCRINE tumors of the ampulla of Vater are rare. In an analysis of 13 715 neuroendocrine tumors reported over a 50-year period to the Surveillance, Epidemiology, and End Results Program of the National Cancer Institute, only 360 cases involved the duodenum or ampulla.¹ Fewer than 120 cases of ampullary neuroendocrine tumors have been reported in the literature, mostly as isolated case reports.²⁻⁶ Because they are so rare, significant questions regarding their natural history remain unanswered. For example, the prognostic significance of tumor size, depth of invasion, and regional lymph node metastases is largely unknown. As a result, the merits of radical vs local resection remain uncertain.

In 2000, the World Health Organization (WHO) revised the histopathologic classification system for gastroenteropancreatic neuroendocrine tumors.^{7,8} The term *carcinoid* was replaced with *neuroendocrine tumor*, which connotes a broader spectrum of histologic appearance and behavior and can be further subcategorized into benign, potentially malignant, and malignant. More recently, the European Neuroendocrine Tumor Society (ENETS) proposed a TNM staging and grading system for foregut neuroendocrine tumors.⁹ Nevertheless, the clinical value of the WHO and ENETS systems as applied to ampullary neuroendocrine tumors is still unproven.

In this study, we report a single-center experience of 7 patients with ampullary neuroendocrine tumors and ana-

Author Affiliations:
Departments of Surgery (Drs Carter, Stewart, and Way and Ms Rubenstein) and Pathology (Dr Grenert), University of California, San Francisco.

Table 1. Clinical Characteristics of 7 Patients With Neuroendocrine Tumors of the Ampulla

Case No./Sex/Age, y	Presentation	Operation Performed	ENETS Stage	ENETS Grade	Follow-up, mo	Status
1/M/56	Anemia	Transduodenal ampullectomy	T2NXM0 (IIa)	1	137	Alive, NED
2/M/62	Obstructive jaundice	Pancreaticoduodenectomy	T3N1M0 (IIb)	3	15	Dead
3/M/50	Obstructive jaundice	Pancreaticoduodenectomy	T1N1M0 (IIb)	1	48	Alive, NED
4/F/33	Obstructive jaundice	Pancreaticoduodenectomy	T2N1M0 (IIb)	1	31	Alive, NED
5/F/67	Gastric outlet obstruction	Pancreaticoduodenectomy	T2N0M0 (IIa)	1	25	Alive, NED
6/M/73	Incidental during EGD	Pancreaticoduodenectomy	T2N1M0 (IIb)	1	19	Alive, NED
7/F/44	Incidental during EGD	Transduodenal ampullectomy	T1NXM0 (I)	1	7	Alive, NED

Abbreviations: EGD, esophagogastroduodenoscopy; ENETS, European Neuroendocrine Tumor Society; NED, no evidence of disease at follow-up.

lyze them according to the 2000 WHO classification and the ENETS staging system. We discuss the pros and cons of the current classification and staging systems as they pertain to surgical management.

METHODS

All patients treated for neuroendocrine tumors of the ampulla of Vater at the University of California, San Francisco from 1989 to 2006 were retrospectively analyzed. The data included the age at diagnosis, sex, presenting symptoms, preoperative imaging, preoperative biopsy results, type of operation, and pathologic findings. Preoperative staging consisted of a computed tomographic (CT) scan of the abdomen and endoscopic retrograde cholangiopancreatography, with biopsy in most patients. Endoscopic ultrasonography, octreotide scintigraphy, and serum chromogranin A were not routinely performed before surgery. After the operation, surveillance generally consisted of sequential CT scans, octreotide scintigraphy, or both. For the purposes of this study, we spoke with each surviving patient by telephone.

A single pathologist (J.P.G.) blinded to the patient's clinical outcome reviewed the histologic features of the preoperative biopsy specimen and resected tumor. The following were assessed for each: tumor size, depth of invasion, degree of necrosis, mitotic index (number of mitotic figures per 10 high-power fields), presence of lymphovascular invasion, and regional lymph node metastases. All tumors were immunostained with chromogranin and synaptophysin to confirm the diagnosis of neuroendocrine tumor. Additional hormone staining was performed at the discretion of the primary pathologist.

The primary outcome measure was patient survival. Secondary outcome measures were the accuracy of preoperative biopsy and the relationship between tumor size and nodal metastasis. Our study protocol was approved by the University of California, San Francisco Committee on Human Research.

RESULTS

PATIENT CHARACTERISTICS AND PREOPERATIVE EVALUATION

The clinical characteristics of the 7 patients are listed in **Table 1**. The mean age was 55 years; 4 patients were men and 3 were women. Three presented with obstructive jaundice (the total bilirubin level ranged from 5.0-9.2 mg/dL [to convert to micromoles per liter, multiply by 17.104]), which led to an endoscopic

retrograde cholangiopancreatography being performed and a diagnosis of ampullary tumor. In 2 patients, the tumor was discovered as an incidental mass during upper endoscopy. Another patient with iron-deficiency anemia was found to have an ampullary mass by upper endoscopy. The seventh patient presented with gastric outlet obstruction and a slightly elevated bilirubin level (total bilirubin, 1.6 mg/dL) caused by peritumoral fibrosis. A CT scan showed an ampullary mass and mild dilatation of the common bile duct. Endoscopic retrograde cholangiopancreatography was technically unsuccessful because the endoscope could not be passed into the second portion of the duodenum. No preoperative biopsy was performed.

A biopsy was performed during upper endoscopy in the remaining 6 cases. In 4 cases, it showed neuroendocrine tumor. In the fifth case, atypical cells and necrotic debris that were suspicious for carcinoma were seen. In the sixth case, only reactive inflammatory cells could be discerned. This tumor later proved to be a benign gangliocytic paraganglioma.

A CT scan of the abdomen using a thin-slice pancreatic protocol was performed in all of the patients. Liver metastases and regional lymph node involvement were not detected in any patient. In 4 cases, the primary tumor was visible on the CT scan.

No patient had multiple endocrine neoplasia type 1, von Recklinghausen neurofibromatosis, or symptoms of an endocrine hypersecretion syndrome. In 2 patients, 24-hour urinary 5-hydroxyindoleacetic acid levels were obtained and were normal. One patient had a synchronous T1N0M0 adenocarcinoma of the distal esophagus in a background of long-standing gastroesophageal reflux disease and Barrett metaplasia.

OPERATIVE TREATMENT AND TUMOR CHARACTERISTICS

Operative treatment consisted of a pylorus-sparing Whipple procedure in 5 patients and transduodenal ampullectomy in the remaining 2. Of the latter, 1 presented with iron-deficiency anemia and was found to have a mobile ampullary tumor by upper endoscopy. Biopsy was nondiagnostic. A local resection was performed and the pathologic findings showed a completely resected benign gangliocytic paraganglioma. The second patient presented with dyspepsia, which

Table 2. Pathologic Characteristics of 7 Neuroendocrine Tumors of the Ampulla

Case No.	Tumor Size, cm	Preoperative Biopsy Result	Mitotic Figures/10 HPFs, No.	Muscularis Invasion	Vascular Invasion	Necrosis	Nodal Metastasis	Comments and Immunostaining Results
1	1.1	Reactive inflammation	0	–	–	–	NA	Gangliocytic paraganglioma, somatostatin +
2	3.5	Suspicious for carcinoma	35	+	+	+	+	Large cell type, enolase +, CD56 +, CD57 +, LCA –
3	1.0	Neuroendocrine tumor	1	–	–	–	+	VIP +, gastrin –, glucagon –, somatostatin –, insulin –, serotonin –, pancreatic polypeptide –
4	1.6	Neuroendocrine tumor	0	+	–	–	+	Gastrin +, glucagon –, somatostatin –, insulin –, pancreatic polypeptide –
5	2.5	Neuroendocrine tumor	1	+	–	–	–	Gastrin –, insulin –, glucagon –
6	2.1	None obtained	0	+	–	–	+	No additional IPOX performed
7	0.6	Neuroendocrine tumor	0	–	–	–	NA	Gastrin +

Abbreviations: HPFs, high-power fields; IPOX, immunoperoxidase staining; LCA, leukocyte common antigen; NA, not applicable; VIP, vasoactive intestinal peptide; –, negative; +, positive.

led to an upper endoscopy. This showed a 0.6-cm tumor of the ampulla, and a neuroendocrine tumor was diagnosed with a biopsy. A CT scan and octreotide scan demonstrated the primary tumor but no signs of nodal or distant metastases. Endoscopic ultrasonography showed an early-stage tumor confined to the submucosa (stage T1) without invasion of the muscularis propria. It was locally excised.

The pathologic characteristics of the tumors are listed in **Table 2**, with typical examples shown in the **Figure**. All tumors stained positive for chromogranin and synaptophysin. Size ranged from 0.6 to 3.5 cm. The muscularis propria was invaded by 4 tumors. Only 1 tumor had high-grade features; this was a 3.5-cm large cell neuroendocrine carcinoma that showed marked cellular proliferation (35 mitotic figures/10 high-power fields), necrosis, invasion of the muscularis, and vascular invasion (case 2). Regional lymph node metastases were present in 4 of the 5 patients who had Whipple procedures, 1 of whom had a 1.0-cm primary tumor. Only 1 patient had grossly evident nodal metastases. The primary tumor in this patient was a 2.1-cm, low-grade carcinoma confined to the ampulla (stage T1). Although hormone staining was only sporadically performed, 2 tumors stained positive for gastrin, 1 tumor stained positive for vasoactive intestinal peptide, and 1 tumor stained positive for somatostatin.

PATIENT SURVIVAL

Follow-up was complete for all of the patients. Tumor grade predicted survival, but the ENETS stage did not (Table 1 and Table 2). The 1 patient with a high-grade neuroendocrine carcinoma died of recurrent disease 15 months after pancreaticoduodenectomy. The others, all with grade 1 tumors, remained disease-free from 7 to 137 months after surgery, including 3 who had lymph node metastases (follow-up, 19, 31, and 48 months).

COMMENT

Since they were first described by Oberndorfer in 1907,¹⁰ carcinoid tumors have proven difficult to classify in a way that accurately predicts their malignant potential.¹¹ This stems from their typically indolent course when malignant, morphologic heterogeneity, anatomical diversity, and wide variety of secretory products and syndromes. Progress was made by the 2000 WHO classification, which adopted the neutral terms *neuroendocrine tumor* and *neuroendocrine carcinoma* and created a distinction between well-differentiated (low-grade) and poorly differentiated (high-grade) neuroendocrine carcinomas. Although this distinction could generally be made by assessment of the tumor's proliferative index, invasiveness, anatomical location, and size, the WHO classification system recognized that the malignant potential of some neuroendocrine tumors could not always be determined from the pathologic findings.⁷ Building on the principles of the WHO classification, ENETS recently proposed a grading and TNM staging system for foregut neuroendocrine tumors.⁹

Under the WHO classification system, our series consisted of 1 benign gangliocytic paraganglioma, 1 benign neuroendocrine tumor, 4 low-grade neuroendocrine carcinomas, and 1 high-grade neuroendocrine carcinoma. Under ENETS staging, we had 1 stage I tumor, 2 stage II tumors, and 4 stage III tumors.

Unfortunately, the WHO classification and ENETS staging system have limitations when applied to ampullary neuroendocrine tumors. First, a more advanced stage (ie, a locally invasive primary tumor or the presence of nodal metastasis) does not predict a worse prognosis. For example, our patients with nodal disease (stage III) all survived without evidence of recurrence for up to 48 months. This coincides with a published review of 71 patients that also showed no effect of nodal metastases (present in 39% of patients) on

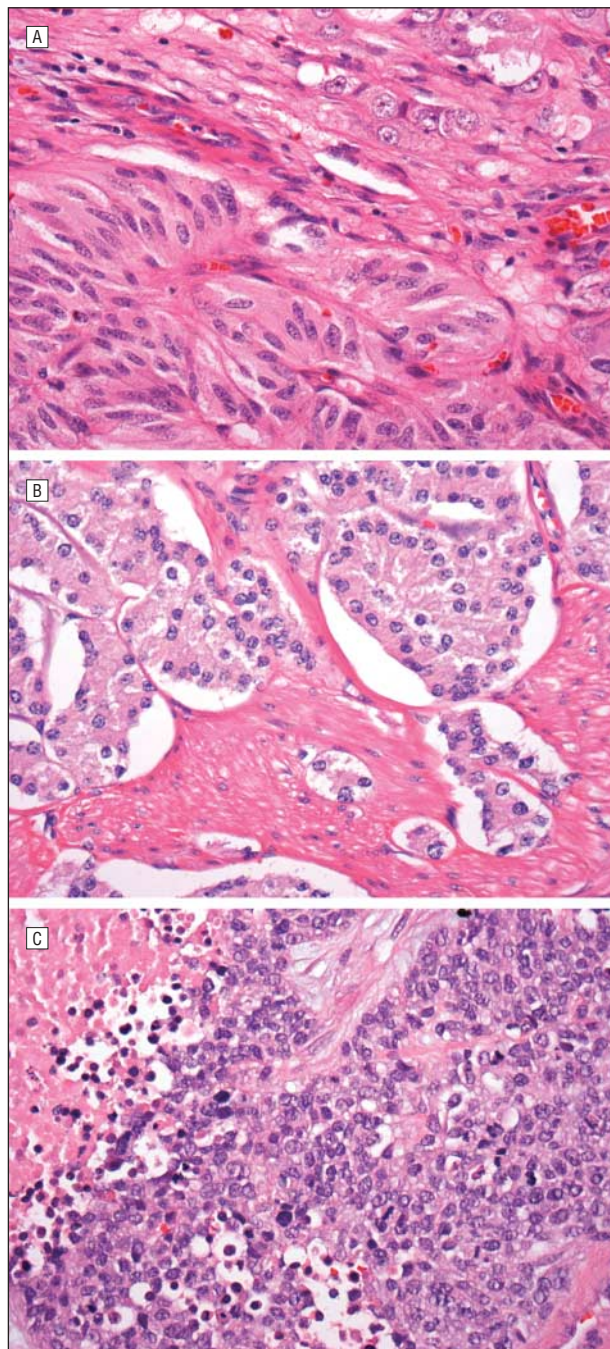


Figure. Histologic features of neuroendocrine tumors of the ampulla (hematoxylin-eosin, original magnification $\times 40$). A, Gangliocytic paraganglioma. These rare tumors occur predominantly in the periampullary duodenum and have a unique histologic appearance with 3 cell types: ganglion cells, spindle cells, and clusters of epithelioid cells. B, Low-grade neuroendocrine carcinoma. The tumor is composed of nests of uniform cells with round nuclei and "salt and pepper" chromatin. This case shows muscularis propria invasion, but mitotic figures and necrosis are absent. C, High-grade, large cell neuroendocrine carcinoma. Compared with the low-grade tumor, this is composed of larger cells with dark nuclei. Mitotic figures are abundant and necrosis is present.

overall survival.² Thus, with regard to ampullary carcinoid tumors, a higher ENETS stage did not predict a worse outcome.

Second, tumor size of 1 cm or smaller does not clearly signify benign disease. In our series, 1 patient with proven

nodal metastases had a 1.0-cm primary tumor. In the review cited earlier, lymph node metastases were present in 3 of 8 ampullary carcinoid tumors (38%) that were 1 cm or smaller.² Indeed, in all publications on this subject to our knowledge, size of the tumor carried no prognostic significance.³

Although the 2000 WHO classification grouped ampullary and duodenal neuroendocrine tumors into 1 category,⁷ there is good evidence that they are truly distinct.¹²⁻¹⁴ In a detailed comparison, Makhoul et al¹² noted that tumor size smaller than 2 cm was associated with a lower rate of metastasis for duodenal but not ampullary neuroendocrine tumors. Additionally, hormone-staining profiles differed, with the majority of duodenal tumors staining positive for gastrin (56%) and the majority of ampullary tumors staining positive for somatostatin (67%).¹² Additionally, 25% of ampullary tumors but no duodenal tumors were associated with von Recklinghausen syndrome.¹²

Despite its limitations, the WHO classification system is useful in that it differentiates high-grade from low-grade neuroendocrine carcinomas by straightforward histologic criteria. Our 1 patient with a high-grade carcinoma experienced rapid tumor progression and death. An aggressive course like this has been described by others for high-grade neuroendocrine carcinomas.^{15,16}

No tumor in our series produced a hypersecretion syndrome, which coincides with data from other reports, where just 2 of 83 patients had hormonal syndromes.^{2,12} Unlike carcinoid tumors elsewhere in the body, small tumor size did not predict the absence of nodal metastasis. Nodal disease was present in 4 of 5 patients in whom lymph nodes were removed and was associated with tumor size as small as 1.0 cm. This too matches the observations by others.^{2,3} Finally, preoperative biopsies were accurate in 4 of 6 of our patients, better than the 14% found in a compilation of the literature.³

Given the propensity of ampullary neuroendocrine tumors to present with nodal metastases, we recommend a Whipple procedure for most cases regardless of tumor size. An opposite conclusion would assume that removal of involved lymph nodes is of no therapeutic benefit. While there is no concrete evidence that survival is better after a Whipple procedure, it makes sense to remove these metastases. Given the current data, only mobile (superficial) tumors seem suitable for a local resection.¹⁷

Accepted for Publication: April 13, 2008.

Correspondence: Jonathan T. Carter, MD, Department of Surgery, University of California, San Francisco, 4 Korret Way, LR-101, Box 0475, San Francisco, CA 94143-0475 (jonathan.carter@ucsfmedctr.org).

Author Contributions: Study concept and design: Carter and Way. Acquisition of data: Grenert, Rubenstein, and Stewart. Analysis and interpretation of data: Grenert, Rubenstein, and Stewart. Drafting of the manuscript: Carter, Grenert, Rubenstein, Stewart, and Way. Critical revision of the manuscript for important intellectual content: Grenert, Rubenstein, and Stewart. Study supervision: Carter, Stewart, and Way.

Financial Disclosure: None reported.

Previous Presentation: This paper was presented as a poster at the 78th Annual Meeting of the Pacific Coast Surgical Society; February 17-20, 2007; Kohala Coast, Hawaii.

REFERENCES

1. Modlin IM, Lye KD, Kidd M. A 5-decade analysis of 13 715 carcinoid tumors. *Cancer*. 2003;97(4):934-959.
2. Hatzitheoklitos E, Buchler MW, Friess H, et al. Carcinoid of the ampulla of Vater: clinical characteristics and morphologic features. *Cancer*. 1994;73(6):1580-1588.
3. Hartel M, Wente MN, Sido B, Friess H, Buchler MW. Carcinoid of the ampulla of Vater. *J Gastroenterol Hepatol*. 2005;20(5):676-681.
4. Waisberg J, de Matos LL, Waisberg DR, dos Santos HV, Fernezlian SM, Capelozzi VL. Carcinoid of the minor duodenal papilla associated with pancreas divisum: case report and review of the literature. *Clinics*. 2006;61(4):365-368.
5. Dixon JM, Chapman RW, Berry AR. Carcinoid tumour of the ampulla of Vater presenting as acute pancreatitis. *Gut*. 1987;28(10):1296-1297.
6. Emory RE Jr, Emory TS, Goellner JR, Grant CS, Nagorney DM. Neuroendocrine ampullary tumors: spectrum of disease including the first report of a neuroendocrine carcinoma of non-small cell type. *Surgery*. 1994;115(6):762-766.
7. Solcia EKG, Sobin LH. *Histological Typing of Endocrine Tumors*. Heidelberg, Germany: Springer; 2000.
8. Klöppel G, Heitz PU, Capella C, Solcia E. Pathology and nomenclature of human gastrointestinal neuroendocrine (carcinoid) tumors and related lesions. *World J Surg*. 1996;20(2):132-141.
9. Rindi G, Klöppel G, Alhman H, et al; Frascati Consensus Conference Participants; European Neuroendocrine Tumor Society (ENETS). TNM staging of foregut (neuro) endocrine tumors: a consensus proposal including a grading system. *Virchows Arch*. 2006;449(4):395-401.
10. Oberndorfer S. Karzinoide Tumoren des Dunndarms. *Frankf Z Pathol*. 1907;1:426-429.
11. Modlin IM, Kidd M, Latich I, Zikusoka MN, Shapiro MD. Current status of gastrointestinal carcinoids. *Gastroenterology*. 2005;128(6):1717-1751.
12. Makhlof HR, Burke AP, Sobin LH. Carcinoid tumors of the ampulla of Vater: a comparison with duodenal carcinoid tumors. *Cancer*. 1999;85(6):1241-1249.
13. Bornstein-Quevedo L, Gamboa-Domínguez A. Carcinoid tumors of the duodenum and ampulla of vater: a clinicomorphologic, immunohistochemical, and cell kinetic comparison. *Hum Pathol*. 2001;32(11):1252-1256.
14. Zyromski NJ, Kendrick ML, Nagorney DM, et al. Duodenal carcinoid tumors: how aggressive should we be? *J Gastrointest Surg*. 2001;5(6):588-593.
15. Nassar H, Albores-Saavedra J, Klimstra DS. High-grade neuroendocrine carcinoma of the ampulla of vater: a clinicopathologic and immunohistochemical analysis of 14 cases. *Am J Surg Pathol*. 2005;29(5):588-594.
16. Cavazza A, Gallo M, Valcavi R, De Marco L, Gardini G. Large cell neuroendocrine carcinoma of the ampulla of vater. *Arch Pathol Lab Med*. 2003;127(2):221-223.
17. Pyun DK, Moon G, Han J, et al. A carcinoid tumor of the ampulla of Vater treated by endoscopic snare papillectomy. *Korean J Intern Med*. 2004;19(4):257-260.